

# Hyperplastic dental follicle: case report

## *Folículo pericoronário hiperplásico: relato de caso*

Vinicius R. Gomes<sup>1</sup>; Maria Carline S. Melo<sup>1</sup>; Helder C. Carnei Jr.<sup>1,2</sup>; João Eudes T. Pinho Filho<sup>1,2</sup>; Murilo A. Teixeira Neto<sup>1</sup>

1. Hospital Batista Memorial de Fortaleza, Fortaleza, Ceará, Brazil. 2. Associação Brasileira de Odontologia, Fortaleza, Ceará, Brazil.

### ABSTRACT

The dental follicle is characterized as a radiolucent area around an impacted tooth. It is believed that these follicles can originate cysts and tumors. The aim of this study was to report a clinical case of a 15-year-old female, normosystemic patient, with an increased dental follicle involving the crown of the tooth 48, which was removed and referred for histopathological examination. The diagnosis hypothesis was dentigerous cyst, but the histopathological report describes a definitive diagnosis of dental follicle. After six months of postoperative follow-up the patient presented no signs of relapse or complaints in the region.

**Key words:** dental sac; dentigerous cyst; mandible.

### RESUMO

*O folículo pericoronário caracteriza-se como uma área radiolúcida em volta de um dente incluso. Acredita-se que esses folículos podem originar cistos e tumores. O objetivo deste trabalho foi relatar o caso clínico de um paciente do gênero feminino, 15 anos de idade, normossistêmica, que apresentava folículo pericoronário aumentado, envolvendo a coroa do dente 48, o qual foi removido e encaminhado para exame histopatológico. A hipótese diagnóstica foi cisto dentífero, mas o laudo histopatológico teve como diagnóstico definitivo folículo pericoronário. A paciente encontra-se com seis meses de pós-operatório sem sinais de recidiva ou queixas na região.*

**Unitermos:** saco dentário; cisto dentífero; mandíbula.

### RESUMEN

*El folículo pericoronario se caracteriza por un área radiolúcida alrededor de un diente no erupcionado. Se cree que eses folículos puedan desarrollar quistes y tumores. El objetivo de este trabajo es reportar el caso clínico de un paciente de género femenino, de 15 años de edad, buen estado general, que presentaba un folículo dilatado, cubriendo la corona del diente 48, lo cual ha sido removido y enviado para estudio histopatológico. La hipótesis diagnóstica fue de quiste dentífero, pero el informe histopatológico logró establecer como diagnóstico definitivo folículo pericoronario. En los primeros seis meses del período postoperatorio, no hay señales de recidiva o quejas en la región.*

**Palabras clave:** saco dental; quiste dentífero; mandíbula.

## INTRODUCTION

Dental follicle is radiographically characterized by a radiolucent area surrounding the crown of an unerupted tooth, which plays a key role in the development and eruption of teeth<sup>(1)</sup>. Follicles with a radiolucent area larger than 2.5 mm in size should be evaluated to rule out possible cysts or tumors<sup>(2)</sup>. Radiographic examination is used to evaluate and planning the surgery of the impacted teeth, as well as to provide additional information, such as the presence or absence of pathology signs in the dental follicles<sup>(3)</sup>. The differential diagnosis of hyperplastic dental follicle includes dentigerous cyst, odontogenic keratocyst and ameloblastoma<sup>(4)</sup>.

## CASE REPORT

J. F. P. T., 15-years-old patient, female, Caucasian, attended in the Surgery and Bucomaxillofacial Traumatology Improvement Training of the Brazilian Dental Association, session Ceará/Brazil, referred by the orthodontist to remove the teeth 18, 28, 38 and 48. During the anamnesis, the person legally responsible denied any morbidity or allergies. At clinical examination, there was no increase in volume or alteration of the lining mucosa. Radiographically, a radiolucent area could be observed around the crown of the tooth, suggestive of pathological alteration (**Figure 1**).

The patient underwent the dental extraction under local anesthesia using 2% mepivacaine with 1:100.000 epinephrine. A distal incision was on tooth 48 and a relaxing incision on the mesial of tooth 37 were performed for access flap, then, distal and buccal osteotomy, using a carbide drill no. 702, dental excision, using straight levers, and curettage of the region. The treatment proposed by our team was excision of the altered tissue along with the tooth were carried out. The initial diagnostic hypothesis presented was dentigerous cyst due to radiographic characteristics, such as the relation of the follicle around the associated tooth crown (**Figure 2**).

In the histopathological examination, loose connective tissue and presence of islands and cords of the odontogenic epithelium were observed without cystic epithelium formation, which asserts the development of a hyperplastic dental follicle (**Figure 3**).

The patient has been under follow-up for six months without signs of relapse (**Figure 4**).

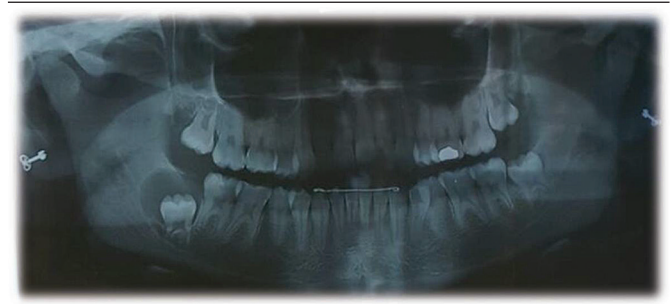


FIGURE 1 – Panoramic radiograph showing radiolucent area around the tooth 48

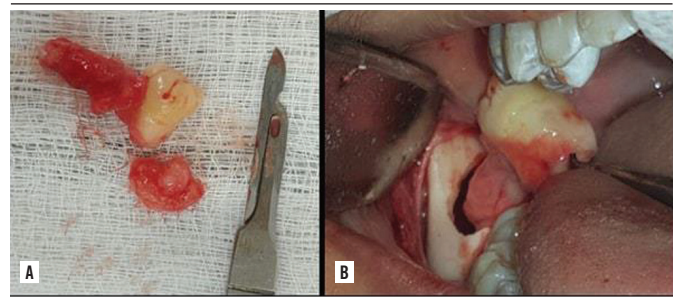


FIGURE 2 – A) image showing the extension of the tissue associated with the dental element; B) intraoral images showing the moment of tooth 48 removal along with the altered tissue

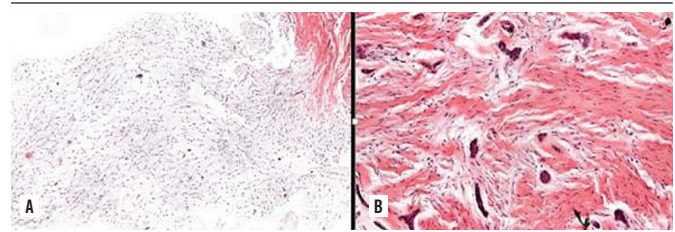


FIGURE 3 – A) histopathological result, evidencing loose connective tissue; B) histopathological result, evidencing cells forming islands and cords of odontogenic epithelium

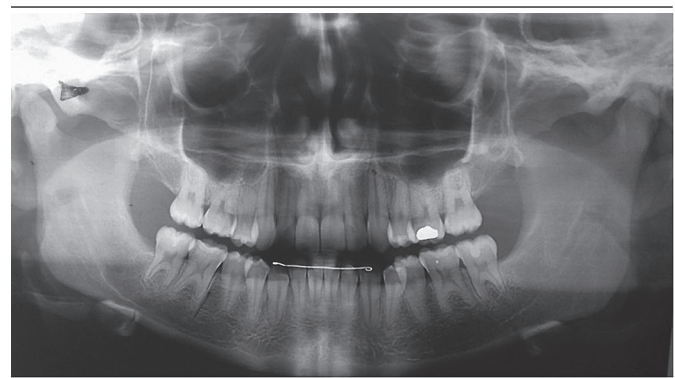

FIGURE 4 – Panoramic radiograph showing bone formation in the area approached

## DISCUSSION

---

Regarding the presented case, our team included dentigerous cyst, odontogenic cyst, keratocyst and ameloblastoma as differential diagnosis, corroborating the differential diagnoses proposed by Haghaniar *et al.* (2014)<sup>(4)</sup>.

The dental follicle with increased characteristics can occur at any age, but the literature reports a higher occurrence in young individuals<sup>(5)</sup>. There is a case report of a hyperplastic follicle in a 14-year-old male patient, and it shows that the relationship between female and male genders is 1:1.4<sup>(6)</sup>.

Radiolucent areas greater than 3 mm may be indicative of alteration in the dental follicle<sup>(2)</sup>. Some authors consider normal a follicle with a maximum thickness of up to 2.5 mm<sup>(4)</sup>. We report in our study a follicle with approximately 3 cm thickness in its largest diameter.

A survey led us to consider that altered dental follicles affected the unerupted mandibular first and second molars<sup>(7)</sup>. But there are other studies on hyperplastic follicle involving the

crown of tooth 47<sup>(6)</sup>. In the present case, we report a follicular increase associated with impacted tooth 48.

Regarding the radiographic characteristics, we present the case of a radiolucent area around the crown of the impacted tooth 48, with a radiopaque halo around the lesion. The dental follicle presents as a well circumscribed radiolucent area with sclerotic borders around an impacted tooth<sup>(8)</sup>.

In 2014, a report of an increased follicle in the dental 47 region was described in the literature, for which marsupialization treatment was chosen<sup>(6)</sup>. Regarding the treatment proposed, the literature presents marsupialization as a definitive treatment, but in this study enucleation treatment was selected because of the limited size of the lesion and the well-defined circumscribed radiolucent area.

## FINAL CONSIDERATIONS

---

When the specimens obtained around the dental elements present data suggestive of alterations, they must be sent to histopathological examination. The dentist needs to be prepared to evaluate and diagnose the potential changes in the jaws.

## REFERENCES

---

1. Honda MJ, Imaizumi M, Tsuchiya S, Morszeck C. Dental follicle stem cells and tissue engineering. *J Oral Sci.* 2010; 52(4): 541-52.
2. White SC, Pharoah MJ. *Oral radiology principles and interpretation.* Elsevier. 6<sup>th</sup> ed. 2009. p. 388-419.
3. Jamshidi S, Zargarani M, Mohtasham N. Multiple calcifying hyperplastic dental follicle (MCHDF): a case report. *J Dent Res Dent Clin Dent Prospects.* 2013; 7(3): 174-6. doi:10.5681/joddd.2013.028.
4. Haghaniar S, Moudi E, Seyedmajidi M, et al. Can the follicle-crown ratio of the impacted third molars be a reliable indicator of pathologic problem? *J Dent (Shiraz).* 2014; 15(4): 187-91.
5. O'Connell S, Davies J, Smallridge J, Vaidyanathan M. Amelogenesis imperfecta associated with dental follicular-like hamartomas and generalised gingival enlargement. *Eur Arch Paediatr Dent.* 2014; 15(5): 361-8. doi: 10.1007/s40368-013-0106-8.
6. Schmitz LB, Bravo-Calderón DM, Soares CT, Oliveira DT. Hyperplastic dental follicle: a case report and literature review. *Case Rep Dent.* 2014; 2014: 251892. doi: 10.1155/2014/251892.
7. Nikitakis NG, Parashar P, Terezides A, Sarlani E. Dental follicular hamartomas in the opercula of teeth delayed in eruption: a case report and review of the literature. *Oral Oncol Extra.* 2006; 42(3): 129-32.
8. Walker LM, Wood AJ, McDonald A, Carpenter W. Unerupted mandibular second primary molar with an unusual histopathological finding: a case report. *J Dent Child (Chic)* 2004; 71: 77-9.

## CORRESPONDING AUTHOR

---

Vinicius Rodrigues Gomes  0000-0001-8095-9710  
e-mail: viniustoc17@hotmail.com



This is an open-access article distributed under the terms of the Creative Commons Attribution License.