

Clinical-pathological aspects of oral lymphoepithelial cyst: case report

Aspectos clinicopatológicos de cisto linfoepitelial oral: relato de caso

Lourival C. O. N. Rocha; Gabriel G. Silva; Mariana C. Xerez; Caio César S. Barros; Juliana C. Pinheiro; Laudence L. Pereira; Antônio L. L. Costa

Universidade Federal do Rio Grande do Norte (UFRN), Natal, Rio Grande do Norte, Brazil.

ABSTRACT

Oral lymphoepithelial cyst (OLEC) is an uncommon lesion whose pathogenesis remains poorly understood. The purpose of this paper is to report a case of OLEC. Female patient, white, 62 years old, presented asymptomatic nodular swelling of soft consistency in the lateral border of the tongue. Under the clinical hypothesis of lymphoid tissue hyperplasia, an excisional biopsy was performed. Histopathological examination revealed a pathological epithelial-lined cavity and a cystic connective tissue capsule containing lymphoid tissue. The diagnosis of OLEC was established and the patient showed no signs of recurrence after surgical removal of the lesion.

Key words: lymphoid tissue; oral diagnosis; cysts.

RESUMO

O cisto linfoepitelial oral (CLEO) é uma lesão incomum, cuja patogênese ainda é pouco elucidada. O objetivo deste estudo é relatar um caso de CLEO. Paciente do sexo feminino, leucoderma, 62 anos, apresentou aumento de volume nodular assintomático de consistência amolecida, em borda lateral da língua. Sob a hipótese clínica de hiperplasia de tecido linfoide, biópsia excisional foi realizada. O exame histopatológico revelou cavidade patológica revestida por epitélio e uma cápsula cística de tecido conjuntivo, contendo tecido linfoide. O diagnóstico de CLEO foi estabelecido. A paciente não apresentou sinais de recidiva após a remoção cirúrgica da lesão.

Unitermos: tecido linfoide; diagnóstico bucal; cistos.

RESUMEN

El quiste linfoepitelial (QLE) oral es una lesión infrecuente, cuya patogénesis es aún poco conocida. El objetivo del presente estudio es reportar un caso de QLE oral. Mujer blanca de 62 años presentó un crecimiento nodular asintomático de consistencia blanda, en borde lateral de la lengua. Bajo la hipótesis clínica de hiperplasia del tejido linfoide, se realizó una biopsia excisional. El examen histopatológico reveló cavidad patológica revestida de epitelio y una cápsula quística de tejido conectivo, conteniendo tejido linfoide. Se estableció el diagnóstico de QLE oral. La paciente no ha presentado recidiva tras extirpación quirúrgica de la lesión.

Palabras clave: tejido linfoide; diagnóstico bucal; quistes.

INTRODUCTION

The oral lymphoepithelial cyst (OLEC) is an uncommon lesion, the pathogenesis of which is still poorly elucidated⁽¹⁾. Most cases are diagnosed between the second and sixth decades of life. Clinically, they appear as a mobile, asymptomatic nodule, with a color ranging from yellow-white to pink, occasionally transparent or translucent. These lesions are small and have an evolution time that can vary from two weeks to 10 years^(1,2).

Histologically, OLECs exhibit a pathological cavity covered by stratified squamous epithelium, which may be non-keratinized or orthokeratinized. The cystic lumen exhibits a variable amount of desquamated epithelial cells and inflammatory cells, and the epithelial-conjunctive interface is flat. The fibrous capsule shows an intense lymphocytic infiltrate, which can completely or partially circumscribe the epithelial lining and, in general, does not extend to the surrounding tissues. The lymphocytic infiltrate is the main component of the lesion and, normally, germinal centers are observed⁽³⁾. Rarely, oral lymphoepithelial cysts can appear in association with other cystic lesions, such as the epidermoid cyst⁽⁴⁾.

The treatment of choice for OLEC is conservative surgical excision, and the quality of life of patients during the follow-up period is considered satisfactory^(1,2).

The objective of the present work is to report a case of OLEC, as well as to discuss the theories of this lesion to arise and its clinical and histopathological characteristics.

CASE REPORT

Female patient, white, 62 years old, attended the Oral Diagnostic Service of the Faculty of Dentistry of the Federal University of Rio Grande do Norte (UFRN) showing an asymptomatic nodular volume increase, with a slightly yellowish color and softened consistency, on the posterior right lateral border of the tongue, measuring approximately 0.5 cm (**Figure 1**). The patient was unable to accurately report the evolution time. Under the clinical hypothesis of lymphoid hyperplasia, an excisional biopsy was performed. Histopathological examination revealed a pathological cavity covered by parakeratinized stratified squamous epithelium and a cystic capsule of dense fibrous connective tissue, containing lymphoid tissue, which completely circumscribed the lining cystic epithelium (**Figure 2A, 2B, and 2C**). Additionally, the presence of secondary lymphoid follicles with prominent germinal centers distributed throughout the cystic capsule was observed (**Figure 2A and 2D**). Based on the microscopic findings, the definitive diagnosis

of OLEC was established. The patient showed no signs of recurrence after the surgical removal of the lesion.

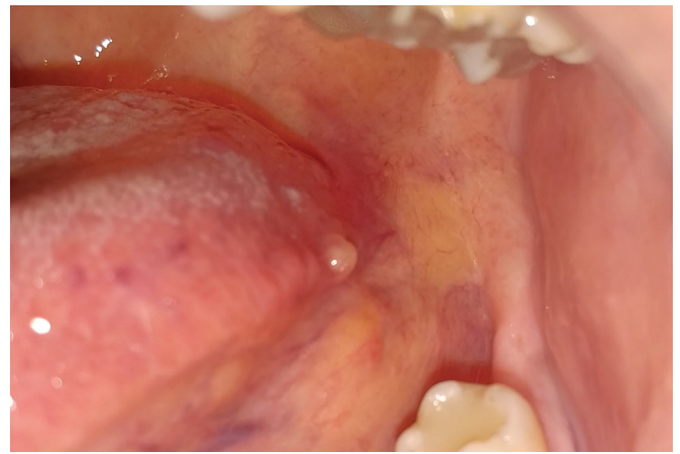

FIGURE 1 – Intraoral clinical aspect: yellowish nodular lesion, measuring 0.5 cm on the right posterior lateral border of the tongue

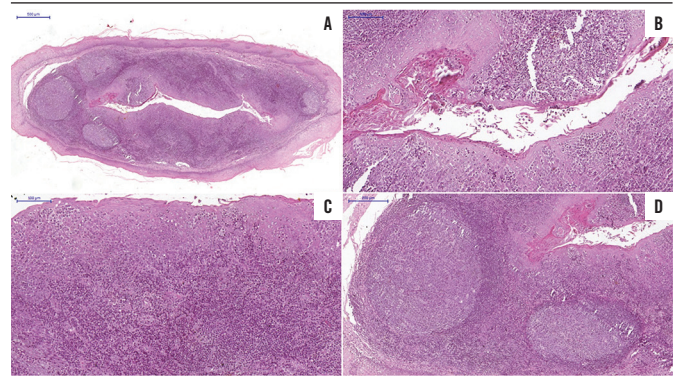


FIGURE 2 – Microscopic aspects, HE

A) 500 µm: pathological cavity lined by epithelium and dense fibrous connective tissue capsule with lymphoid tissue completely circumscribing the lining epithelium; B) 100 µm: cystic cavity covered by parakeratinized stratified squamous epithelium and presence of keratin in the cystic lumen; C) 100 µm: lymphoid tissue in the cystic capsule circumscribing the lining epithelium; D) 200 µm: secondary lymphoid follicles with prominent germinal centers amid the cystic capsule.

HE: hematoxylin and eosin.

DISCUSSION

OLEC is a rare lesion and was initially reported by Bhaskar and Bernier (1959)⁽⁵⁾, it was inserted in the group of branchial cysts. Later, Gold (1962)⁽⁶⁾ located it in the oral mucosa and classified it as a fissured branchial cyst. This lesion can affect several parts of the body, but the parotid glands are most frequently affected. When it affects the oral region, it is considered OLEC, an uncommon developmental cyst in the entire world population^(1,2,7,8). Most cases of OLEC are diagnosed between the third and sixth decades of life^(1,2).

The most accepted theory to explain the etiopathogenesis of this lesion was postulated by Knapp (1970)⁽⁹⁾, who states that OLECs are pseudocysts and do not arise from lymph nodes, but they originate from lymphoid aggregates located inside the mucosa of the floor of the mouth, on the ventral surface of the tongue and the soft palate and in other regions of the oral cavity and oropharynx, forming the so-called mucosa-associated lymphoid tissue (MALT)⁽⁹⁾. Bhaskar (1966)⁽¹⁰⁾ corroborates the possibility that these lesions originating from excretory ducts of minor salivary glands and that the lymphocytic infiltrate represents only a secondary immune response⁽¹¹⁾. The oral cavity, the nasopharynx, and the ocular conjunctiva are portals for different types of antigens that enter the head and neck region. This region is rich in lymphoid tissue strategically positioned, composing a chain of multiple regional lymph nodes, which form the so-called Waldeyer ring, in addition to MALT, so that both play an important role in searching and eliminating potentially dangerous antigens^(8, 12). For this reason, these clinical entities may appear in the oral cavity, whose lymphoid component is the main finding; in the case of OLEC, it is present in the cystic wall.

In the oral cavity, the most frequent sites are the floor of the mouth and the lateral border of the tongue. In these locations, nodules are usually painless, normally yellow to pink in color and soft to firm in consistency. They usually measure less than 1 cm and are transparent or translucent^(2, 7).

Sykara *et al.* (2017)⁽⁷⁾ conducted a study with 26 cases diagnosed over 37 years in an oral pathology service in Greece and found a slight predilection for females: 14 female patients (56%) and 11 male (44%). Pinheiro *et al.* (2018)⁽⁸⁾ diagnosed 16 cases of OLEC in a Brazilian population: 13 (81.2%) in females and three (18.8%) in males, corroborating the findings by Sykara *et al.* In a study conducted by Yang *et al.* (2012)⁽²⁾, 120 cases of OLEC were analyzed, based on findings in the world literature. From these patients, 37 were male and 83 were female, and male-female ratio was 1:2.24. Most cases diagnosed as OLEC (70%) manifested between the fourth and sixth decades of life; these findings are similar to those by Sykara *et al.* and Pinheiro *et al.* In our study, the patient is female and 62 years old.

In the study by Sykara (2017)⁽⁷⁾, 26 OLEC cases were diagnosed with clinical presentation of nodules (92%) of soft (24%) or firm (76%) consistency, showing a pink (20%), yellow (32%) color or white tones (20%), on the tongue (69.23%) or on the floor of the mouth (30.77%), lasting from 20 days to five years. In the 120 cases analyzed by Yang *et al.* (2012)⁽²⁾, the size of the lesions ranged from 0.2 to 2 cm (mean: 0.8 cm); 96.7% of the lesions were smaller than 1 cm. The most frequent anatomical sites were the tongue (50%) and the floor of the mouth (38.3%); these were also the sites most

affected by OLEC^(1, 3, 7, 8). Similar to the literature report, our case presented a volume increase of asymptomatic nodule, with a slightly yellow color and soft consistency, on the posterior lateral border of the tongue, measuring approximately 0.5 cm. The patient was unable to report precisely when the lesion had arisen.

Due to the wide variety of clinical characteristics that OLEC may present, it is possible to perform a differential clinical diagnosis with other benign lesions, such as mucocele, lipoma, fibroma, sialolithiasis, sublingual gland cyst, and dermoid cyst. For the correct diagnosis of OLEC, biopsy is essential⁽²⁾.

Microscopically, OLECs are characterized by the presence of a pathological cavity (which may contain fragments of keratin) covered by parakeratinized stratified squamous epithelium, which exhibits a flat interface with the lamina propria. The cystic fibrous connective tissue capsule is usually thick and has a large amount of lymphocytes, sometimes showing the development of germinal centers⁽³⁾. In the study by Sykara *et al.* (2017)⁽⁷⁾, the majority of OLECs were coated with parakeratinized (92.31%) or non-keratinized (7.69%) epithelium, exhibiting desquamated epithelial cells in their lumen. They also observed that the lymphoid tissue circumscribed the epithelium completely (65.38%) and partially (34.62%), often in a follicular pattern, presenting secondary lymphoid follicles with prominent germinal centers in 53.85%. Lymphoid follicles are classified as primary, when they do not have germinal centers, and as secondary when the germinal centers are present⁽⁸⁾. The germinal centers are activated centers, where B lymphocytes are stimulated by antigens and helper T lymphocytes to generate memory cells⁽¹³⁾. In the present case, the histological examination shows a cystic lesion covered by stratified squamous epithelium with the presence of lymphoid tissue in the capsule, completely circumscribing the epithelium, showing secondary lymphoid follicles formation with prominent germinal centers.

In general, OLEC is treated by surgical excision and presents reports of neoplastic transformation or recurrence after excision^(1, 2). In the study by Yang *et al.* (2012)⁽²⁾ and Bhaskar (1966)⁽¹⁰⁾, complete surgical resection of the lesion was the treatment of choice. There were no reports of recurrence after the lesions were treated. Our patient also did not show recurrence of the lesion after the excisional biopsy.

FINAL CONSIDERATIONS

OLEC is a lesion of uncommon lymphoid origin, of indolent nature, which usually affects more females and can be confused

with other lesions with similar clinical characteristics. Thus, the clinical findings and the history of the lesion can lead the clinician to a consistent diagnostic hypothesis. The dentist must

be prepared to diagnose significant increases in volume in the oral cavity, in order to properly manage the patient, establishing the best treatment.

REFERENCES

1. Juliasse LER, Resende ACM, Maia AP, Nonaka CFW, Galvão HC, Pinto LP. Oral lymphoepithelial cyst: report of 4 cases and review of 119 cases reported in the literature. *J Bras Patol Med Lab.* 2010; 46(2): 129-134.
2. Yang X, Ow A, Zhang C, Wang L, Yang W, Hu Y, Zhong L. Clinical analysis of 120 cases of intraoral lymphoepithelial cyst. *Oral Surg Oral Med Oral Pathol Oral Radiol.* 2012; 113(4): 448-52.
3. Castro JG, Ferreira GM, Mendonça EF, Castro LA. A rare occurrence of lymphoepithelial cyst in the palatine tonsil: a case report and discussion of the etiopathogenesis. *Int J Clin Exp Pathol.* 2015; 8(4): 4264-8.
4. Epivatianos A, Zaraboukas T, Antoniadis D. Coexistence of lymphoepithelial and dermoid cysts on the floor of the mouth: report of a case. *Oral Dis.* 2005; 11: 330-3.
5. Bhaskar SN, Bernier JL. Histogenesis of branchial cysts: a report of 468 cases. *Am J Pathol.* 1959; 35: 407-23.
6. Gold C. Branchial cleft cyst located in the floor of the mouth. Report of a case. *Oral Surg Oral Med Oral Pathol.* 1962; 15: 1118-20.
7. Sykara M, Ntovas P, Kalogirou EM, Tosios KI, Sklavounou A. Oral lymphoepithelial cyst: a clinicopathological study of 26 cases and review of the literature. *J Clin Exp Dent.* 2017; 9(8): e1035-43.
8. Pinheiro JC, da Silva Barros CC, Rolim LSA, Pereira Pinto L, de Souza LB, de Andrade Santos PP. Oral lymphoid lesions: a 47-year clinicopathological study in a Brazilian population. *Med Mol Morphol.* 2019; 52(3): 123-34.
9. Knapp MJ. Pathology of oral tonsils. *Oral Surg Oral Med Oral Pathol.* 1970; 29: 295-304.
10. Bhaskar SN. Lymphoepithelial cysts of the oral cavity: report of twenty-four cases. *Oral Surg Oral Med Oral Pathol.* 1966; 21: 120-8.
11. Buchner A, Hansen LS. Lymphoepithelial cysts of the oral cavity: a clinicopathologic study of thirty-eight cases. *Oral Surg.* 1980; 50: 441-9.
12. Victora GD, Nussenzweig MC. Germinal center. *Annu Rev Immunol.* 2012; 30: 429-57.
13. Giunta J, Cataldo E. Lymphoepithelial cysts of the oral mucosa. *Oral Surg.* 1973; 35: 77-84.

CORRESPONDING AUTHOR

Juliana Campos Pinheiro  0000-0001-5687-7635
e-mail: juliana.patologia92@gmail.com



This is an open-access article distributed under the terms of the Creative Commons Attribution License.