








# Longitudinal analyses of composite resin restoration on erosive lesions: effect of dentin treatment with a chitosan nanoformulation containing green tea

Renato Gonçalves dos Reis<sup>1</sup> , Antônio Cláudio Tedesco<sup>2</sup> , Fabiana Almeida Curylofo-Zotti<sup>1</sup> , Thiago Vinicius Cortez<sup>1\*</sup> , Hiago Salge Borges<sup>2</sup> , Aline Evangelista Souza-Gabriel<sup>1</sup> , Silmara Aparecida Milori Corona<sup>1</sup> 

<sup>1</sup> Department of Restorative Dentistry, Ribeirão Preto School of Dentistry, University of São Paulo, Ribeirão Preto, SP, Brazil.

<sup>2</sup> Department of Chemistry, Center of Nanotechnology and Tissue Engineering, Photobiology and Photomedicine Research Group, Faculty of Philosophy, Sciences and Letters of Ribeirão Preto, University of São Paulo, Ribeirão Preto, SP, Brazil.

## Corresponding author:

Thiago Vinicius Cortez  
School of Dentistry of Ribeirão Preto  
University of São Paulo  
Avenida do Café, s/n, Ribeirão  
Preto, SP, Brazil, 14040-904  
Phone: +55-16-33154075  
e-mail: thiago.cortez@usp.br

**Editor:** Dr. Altair A. Del Bel Cury

**Received:** August 30, 2021

**Accepted:** September 23, 2022

**Aim:** To evaluate the influence of the biomodification of erosive lesions with a chitosan nanoformulation containing green tea (NanoCsQ) on the clinical performance of a composite resin. **Methods:** The study was performed in a split-mouth, randomized and double-blinded model with 20 patients with 40 erosive lesions. The patient's teeth were randomized into two groups (n=20) according to the surface treatment: 1) Without biomodification (control), and 2) Biomodification with NanoCsQ solution (experimental). The lesions were restored with adhesive (Tetric N-bond, Ivoclar) and composite resin (IPS Empress Direct, Ivoclar). The restorations were polished and 7 days (baseline), 6 months, and 12 months later were evaluated according to the United States Public Health Service (USPHS) modified criteria, using clinical exam and photographs. Data were analyzed by Friedman's and Wilcoxon signed-rank tests. **Results:** No significant differences were found between the control and experimental groups ( $p=0.423$ ), and also among the follow-up periods (baseline, six months, and 12 months) ( $p=0.50$ ). Regarding the retention criteria, 90% of the restoration had an alpha score in the control group. Only 10% of the restorations without biomodification (control) had a score charlie at the 12-month follow-up. None of the patients reported post-operative sensitivity. **Conclusion:** The NanoCsQ solution did not negatively affect the performance of the composite resin restorations after 12 months.

**Keywords:** Clinical trials as topic. Tea. Chitosan. Tooth erosion. Nanoparticles.



## Introduction

Tooth erosion starts with the softening of the surface by acidic materials. It can be caused by both intrinsic (acid gastric regurgitation) and/or extrinsic (acidic drinks and food) acids, and is modified by changes in salivary flow and constituents. The dentine is more susceptible to erosion than enamel because the crystals in dentine are much smaller than those of enamel and the carbonate content of dentine is greater than in enamel<sup>1</sup>.

The enamel prisms of the tooth with erosion are dissolved, which creates a surface with fissures that resembles a honeycomb. The progression of the lesion affects the peri and inter-tubular dentin, enlarging the dentin tubules<sup>1</sup>. Erosive dentin lesions are heterogeneous, highly permeabilized, have high crystallinity, and partially denatured collagen. Altogether, these structural alterations negatively impact the longevity of restorative treatments performed on eroded dental tissues<sup>2,3</sup>.

The organic matrix of the eroded dentin hinders the adhesive penetration due to its high content of water and fibers and because might be already collapsed, which affects the hybridization and increases the adhesive interface degradation<sup>4</sup>. In this context, the use of protective substances, such as chitosan, might improve the mechanical bond resistance of collagen fibrils, which are the scaffold to the adhesive interface<sup>5,6</sup>.

Chitosan is a hydrophile biopolymer of chitin composed of reactive groups, a linear polycation of high density and charge, and hydrogen bonds<sup>5,6</sup>. Such hydrogen bonds are arranged in parallel, ensuring high resistance<sup>7</sup>. Chitosan is biocompatible and non-toxic to human cells, promotes bio-adhesion, biodegradability, and presents antimicrobial activity<sup>8-12</sup>.

The use of chitosan straightens<sup>13,14</sup> and stabilizes<sup>15,16</sup> the dentin collagen, increasing the number of cross-links among the collagen's fibers. Chitosan neutralizes the matrix metalloproteinases, creating collagen arrangements with better mechanical properties<sup>17</sup>. The chitosan bonds are formed by the union of molecules through covalent linkages<sup>5,18</sup>, a process used to stabilize biological tissues<sup>19</sup>.

*Camellia sinensis* (*C. sinensis*) as chitosan, another biomodifier has been investigated in dentistry, is a rich polyphenol, extract containing epicatechin (EC), epigallocatechin (EGC), and Epigallocatechin-3-gallate (EGCg)<sup>20</sup>. *C. sinensis* extract had an inhibitory effect over enzymes that degrade dentin collagen<sup>21</sup>. The catechins, mainly EGCg, can induce cross-linking of fibers, impeding the access of the collagenases to the active sites<sup>22</sup>. In vitro tests showed that the EGCg is effective in preserving the bond resistance of the resin-dentin for 6 months<sup>23</sup>.

Due to the multiple aromatic rings in the structure of EGC, this molecule has higher antioxidative activity than non-phenolic or mono-phenolic compounds<sup>24</sup>. EGC also has antimicrobial activity, affecting acid production, and the metabolisms of *Streptococcus mutans* enzymes such as glycosyltransferases<sup>25</sup>. EGC also inhibits the synthesis of extracellular polysaccharides (EPS), reducing microbial cellular adhesion and biofilm formation<sup>26</sup>.

There is a lack of studies on the biomodification of the eroded dentin surface. This study evaluated the influence of the biomodification of erosive lesions with a chitosan nanoformulation containing green tea (NanoCsQ) on the clinical performance of a composite resin. The hypotheses tested were that there is no correlation between the longevity of restorations and the application of the experimental solution considering retention, marginal discoloration, marginal adaptation of the resin restorations, secondary caries, and post-operative sensitivity.

## Material and methods

### Experimental design

The sample was composed of 20 patients (n=20) aged between 20 to 50 years old who had non-carious erosive lesions of medium to a deep depth at the buccal, palatal/lingual, or incisal/occlusal faces. The study was performed in a split-mouth, randomized, and double-blinded model. The teeth of each participant were received one of the dentin treatments: 1) Control (without biomodification); 2) NanoCsQ - Biomodification with a nanoformulation of chitosan containing green tea extract (*C. sinensis*). The response variables were: 1) Longitudinal evaluation of the restorative treatment through a clinical examination using the modified USPHS criteria at 7 days, 6-months, and 12-months; 2) Photographic evaluation of the restorative treatment at the same time points of the clinical follow-up. All CONSORT guidelines were followed (Figure 1).

### Ethical and legal aspects and sample size calculation

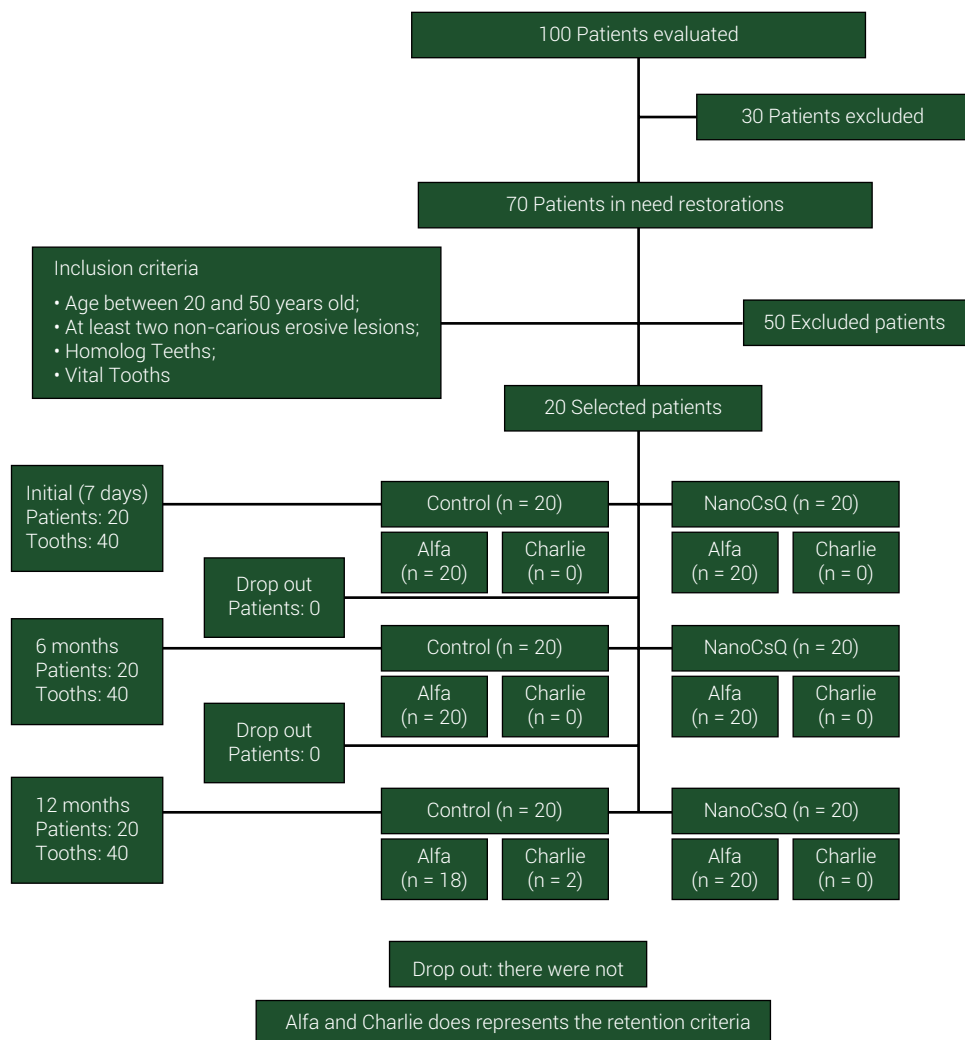
This study was approved by our local ethics committee (CAAE: 23972619.8.0000.5419) and registered on the Brazilian Platform of Clinical Trials Registration (ReBEC) (UTN: 1111-1245-1517). A consent form was signed by each participant.

The website [www.sealedenvelope.com](http://www.sealedenvelope.com) was used to calculate the sample size of this study. The parameters were set to  $\alpha=5\%$ , 90% of power, 98% of success to the experimental and control groups, and an equivalence limit of 15%. The tests pointed to required 19 participants. The calculation values were carried out considering the possibility of dropouts during the experiment and based on a previous clinical study<sup>27</sup>.

### Selection and preparation of the participants

Male and female patients aged from 20 to 50 years old underwent a clinical examination performed during the activities of the restorative dentistry clinics. Patients received professional teeth cleaning with pumice-water slurry with rotating rubber cup and brushes at low-speed handpiece. The clinical examination was performed on dried surface under adequate light exposure.

The participants received diet and dental hygiene instructions, and information about dental erosion. The inclusion criteria were the presence of at least two non-carious erosive lesions of medium to deep depth at the buccal/lingual/palatal or incisal/occlusal faces of two restored teeth. All teeth must have a positive response to thermic stimuli, which was performed using Endo-frost (Roeko, Langenau, Germany).



**Figure 1.** CONSORT flow chart.

All patients who had spontaneous pain, sensitivity, fistulae, or edema were excluded from this study. The teeth of the participants that were not selected for this investigation but needed intervention were adequately treated. The anamnesis regarding the participant's general health and odontogram charting of the patients were filled.

### Preparation of the chitosan nanoformulation containing green tea extract (NanoCsQ)

Low-molecular-weight chitosan nanoparticles (75-85% of deacetylation) (Sigma-Aldrich, Saint Louis, MO, EUA) were dissolved in 0.33% (vol/vol) glacial acetic acid for a stock solution of 2 mg/mL. The pH was adjusted to 5 using 0.1 N sodium hydroxide. Under mild stirring, TPP solution (1 mg/mL) was slowly added, drop by drop, to chitosan solution. The proportion of chitosan to TPP was 5:1.

A 0.3% extract of *C. sinensis* (Green Tea Extract 400mg, NOW Supplements, USA) was submitted to ultrasound bath for 10 min and centrifuged at 10,000 rpm for 15 min. The supernatants were pooled. Under constant stirring, supernatants were added to chitosan solution, drop by drop continuously and slowly. After 30 min of stirring, the TPP was added to the solution, following the same method of our previous *in vitro* study<sup>28</sup>.

## Clinical procedures

The randomization of the participants was done using a sheet of random number generation available at <http://randomnumbergenerator.intemodino.com/pt/>. The participants were codified with numbers to organize the order of the treatments. Participants' teeth were randomly separated according to the treatment to be applied on dentin: control or NanoCsQ, using the coin tossing method, patients and operator were blinded as to the type of treatment. The two teeth of each patient were treated at the same dental visit by a single operator.

Before the treatment, initial photographs were taken (Canon EOS Rebel T2i 18.0 Megapixels, Cannon, Japan). The color selection of the composite resin (IPS Empress Direct, Ivoclar Vivadent, Liechtenstein, Germany) was performed using the Vita 3D color scale (Wilcos do Brazil Indústria e Comércio Ltda, Petrópolis, RJ, Brazil).

All teeth were treated under rubber dam (Madeitex, São José dos Campos, SP, Brazil) and dental clamps were chosen according to the dental anatomy (Duflex, SSWhite, Rio de Janeiro, RJ, Brazil).

All teeth received selective acid conditioning with 35% phosphoric acid for 30 seconds applied only on the enamel. After the acid conditioning, the cavity was washed with water for 1 minute to ensure that acid was removed from the surface. Then, the excess water was removed with a suction cannula and the surface was dried with cotton.

In the experimental group NanoCsQ. Solution actively applied with a brush (KGBrush, KG Sorensen, Cotia, SP, Brazil) for 1 minute. Then the surface was dried with absorbent paper<sup>29</sup>.

A layer of the adhesive system (Tetric N-bond, Ivoclar Vivadent, Liechtenstein, Germany) was actively applied for 20 seconds using a micro brush (KGBrush, KG Sorensen, Cotia, SP, Brazil). Then, the adhesive was light-cured for 10 seconds with Radium-cal LED light curing device (1200 mW/cm<sup>2</sup>) (SDI, Bayswater, Australia) previously measured with a radiometer. This procedure was performed in the all-treated teeth following the manufacturer's recommendations.

To restore erosive dental lesions, the IPS resin (Ivoclar Vivadent) was used in the incremental filling technique. Each increment up to 2 mm in depth, was cured for 20 seconds (Radium-cal LED curing, SDI), restoring dental anatomy. The adjacent teeth were protected with polyester straps.

Once finished, the rubber dam was removed and occlusal adjustments were done with carbon paper (Angelus, Londrina, PR, Brazil). The dental premature con-

tacts and occlusal interferences were removed using diamond-finishing burs (KG Sorensen, Cotia, SP, Brazil). Diamond-finishing burs (KG Sorensen, Cotia, SP, Brazil) and Sof-Lex discs (3M ESPE, St Paul, MN, USA) were used for finishing the restorations. The patients returned 7 days later for a final polishing using impregnated abrasive burs and discs (Enhance, Dentsply Industria e Comercio Ltda, Petropolis, RJ, Brazil).

## Clinical and photographic assessment of dental restorations

The restored teeth were assessed by a clinical and photographic examination seven days after the clinical procedures (after polishing - baseline), 6 and 12 months.

The clinical examination was performed by three examiners, following the Cvar&Ryge modified USPHS criteria<sup>30</sup>, which include the analyses of retention, marginal discoloration, secondary caries, marginal adaptation, and postoperative sensitivity (Table 1), the different raters were previously calibrated.

**Table 1.** Modified USPHS criteria used to the clinical evaluation of the restorative treatments.

| Category                   | Score          | Criteria   |
|----------------------------|----------------|--|
| Retention                  |                |  |
|                            | <i>Alpha</i>   | Loss of restorative material not detected                                    |
|                            | <i>Charlie</i> | Loss of restorative material detected  |
| Marginal discoloration     |                |  |
|                            | <i>Alpha</i>   | Marginal discoloration not detected  |
|                            | <i>Bravo</i>   | Minor marginal discoloration without axial penetration                       |
|                            | <i>Charlie</i> | Axial discoloration with axial penetration                                   |
| Secondary caries           |                |  |
|                            | <i>Alpha</i>   | Secondary caries not detected  |
|                            | <i>Charlie</i> | Secondary caries detected  |
| Marginal adaptation        |                |  |
|                            | <i>Alpha</i>   | The restoration adapts closely to the tooth and there are no visible margins |
|                            | <i>Bravo</i>   | There are visible yet clinically acceptable margins                          |
|                            | <i>Charlie</i> | There is no marginal adaptation. Clinical failure.                           |
| Post-operative sensitivity |                |  |
|                            | <i>Alpha</i>   | No post-operative sensitivity detected                                       |
|                            | <i>Charlie</i> | Post-operative sensitivity detected  |

Intraoral photographs of restored teeth were taken with a digital camera (Canon EOS Rebel T2i 18.0 megapixels, Canon, Japan), intraoral mirror, and circular flash, standardized as best as possible. The photographs evaluation was blindly and individually carried out by three examiners by visualization of the photographs

in a laptop screen under the same environmental and light conditions, including the analyses of color, marginal pigmentation, and anatomical shape of the dental restorations<sup>30</sup> (Table 2).

**Table 2.** Modified USPHS criteria used to the photographic evaluation of the restorative treatments.

| Category              | Score          | Criteria  |
|-----------------------|----------------|---|
| Color                 |                |   |
|                       | <i>Alpha</i>   | The color of the restoration corresponds to the tooth structure in terms of color and translucency    |
|                       | <i>Bravo</i>   | There are minor alterations in the color, hue, and translucency between the restoration and the tooth |
|                       | <i>Charlie</i> | There is a clear alteration in the color and translucency of the restoration                          |
| Marginal pigmentation |                |   |
|                       | <i>Alpha</i>   | There is no pigmentation on the margin between the restoration and the tooth                          |
|                       | <i>Bravo</i>   | There is minor pigmentation between the restoration and the tooth                                     |
|                       | <i>Charlie</i> | There is pigmentation between the restoration and the tooth   |
| Anatomy               |                |   |
|                       | <i>Alpha</i>   | There is continuity with the tooth anatomy  |
|                       | <i>Bravo</i>   | There is no continuity with the tooth anatomy   |
|                       | <i>Charlie</i> | There is loss of restorative material exposing dentin or the restoration inner layers                 |

## Data

Statistical Package for the Social Sciences (SPSS v 25.0 Chicago, IL, USA) software was used for data analyses at a significance level of 5%. Data analyses were based on inferential and descriptive statistics. Descriptive statistics described the frequency and distribution of USPHS modified scores, including the percentage of dental restorations with failures. The analyses of inferential statistics used Friedman's non-parametric test and Wilcoxon signed-rank test for the different time points (baseline, 6 and 12 months) and interactions between treatment and period of analysis. Cohen's kappa test was used to compare inter-examiner and intra-examiner reliability.

## Results

Patients' age ranged between 20 to 50 years old (mean age ~ 30 years old) for both genders. Regarding the restored teeth, 12 anterior and 28 posterior teeth were restored, totaling 40 teeth. The percentage of surface erosion found was 60% buccal/lingual/palatal and 40% incisal/occlusal.

**Table 3.** Data obtained upon clinical examination based on the modified USPHS criteria.

| Treatment                                     | Time point |               | Retention |   |    | Discoloration |   |   | Secondary caries |   |   | Marginal adaptation |   |   | Post-operative sensitivity |   |   |
|---|------------|---------------|-----------|---|----|---------------|---|---|------------------|---|---|---------------------|---|---|----------------------------|---|---|
|   |            |               | A         | B | C  | A             | B | C | A                | B | C | A                   | B | C | A                          | B | C |
| Control<br>(Without<br>biomodifying<br>agent) | Baseline   |               |           |   |    |               |   |   |                  |   |   |                     |   |   |                            |   |   |
|   | (7 days)   | n = 20<br>(%) | 20        | - | -  | 20            | - | - | 20               | - | - | 20                  | - | - | 20                         | - | - |
|   | (6 months) | n = 20<br>(%) | 20        | - | -  | 20            | - | - | 20               | - | - | 20                  | - | - | 20                         | - | - |
|   | (1 year)   | n = 20<br>(%) | 18        | - | 2  | 20            | - | - | 20               | - | - | 20                  | - | - | 20                         | - | - |
|   |            |               | 90        | - | 10 | 100           | - | - | 100              | - | - | 100                 | - | - | 100                        | - | - |
| Biomodification<br>with NanoCsQ               | Baseline   |               |           |   |    |               |   |   |                  |   |   |                     |   |   |                            |   |   |
|   | (7 days)   | n = 20<br>(%) | 20        | - | -  | 20            | - | - | 20               | - | - | 20                  | - | - | 20                         | - | - |
|   | (6 months) | n = 20<br>(%) | 20        | - | -  | 20            | - | - | 20               | - | - | 20                  | - | - | 20                         | - | - |
|   | (1 year)   | n = 20<br>(%) | 20        | - | -  | 20            | - | - | 20               | - | - | 20                  | - | - | 20                         | - | - |
|   |            |               | 100       | - | -  | 100           | - | - | 100              | - | - | 100                 | - | - | 100                        | - | - |

## Clinical examination

The intra-examiner kappa index equaled 1.0 for the same examiner (A compared to A, B compared to B, C compared to C). The inter-examiner index (A and B and C) equaled 0.98.

As for the retention criteria, an alpha score of 100% was achieved after 6 and 12 months after dental restoration with NanoCsQ (n=20). In the control group (without NanoCsQ pre-treatment), the alpha score was found in 100% (n=20) of the restorations 6 months later. After 12 months, the alpha score was found in 90% of the restorations (n=18), and 10% (n=2) had the charlie score. Only two restorations from the control group obtained charlie score for the criteria retention upon 12-month follow-up and were replaced by new ones.

The statistical analyses regarding the criterion "retention" did not show a significant difference between groups (green tea-containing chitosan nanoformulation versus no treatment) ( $p=0.432$ ). Also, no significant difference between time points (baseline, 6 and 12 months) ( $p=0.500$ ) and the interaction treatment between time points ( $p=0.126$ ).

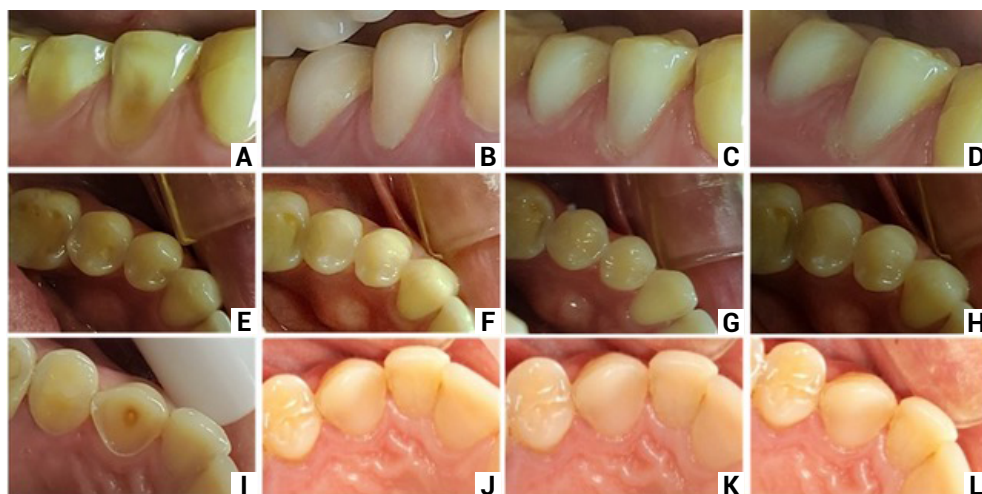
Regarding the remaining criteria analyzed in this study (marginal discoloration, secondary caries, marginal adaptation, and post-operative sensitivity), no changes were observed for the scores at the different time points for both groups (control and experimental group), so that all restorations maintained the alpha score.

## Photographic evaluation

Within 12 months, 100% of the dental restorations with NanoCsQ received alpha scores for all the photographic criteria analyzed: restoration color, marginal pigmentation, and anatomical shape. In the control group, (without biomodification), 90% of



the restorations received an alpha score of 90% and 10% of them received a charlie score for the criteria anatomic shape (Figure 2 and Table 4).



**Figure 2.** A. Initial clinical aspect of the teeth 44 and 45; B. Baseline (7 days); C. 6-month follow-up of; D. 12-month follow-up; E. Initial clinical aspect of the teeth 34 and 35; F. Baseline (7 days) G. 6-month follow-up; H. 12-month follow-up; I. Initial clinical aspect of the teeth; J. Baseline (7 days); K. 6-month follow-up; L. 12-month follow-up.

**Table 4.** Data obtained from photographic analyses based on the modified USPHS criteria.

| Treatment                                     | Time point |               | Color of restoration |        |        | Marginal pigmentation |        |        | Anatomic shape |        |        |
|---|------------|---------------|----------------------|--------|--------|-----------------------|--------|--------|----------------|--------|--------|
|   |            |               | A                    | B      | C      | A                     | B      | C      | A              | B      | C      |
| Control<br>(Without<br>biomodifying<br>agent) | Baseline   |               | A                    | B      | C      | A                     | B      | C      | A              | B      | C      |
|   | (7 days)   | n = 20<br>(%) | 20<br>100            | -<br>- | -<br>- | 20<br>100             | -<br>- | -<br>- | 20<br>100      | -<br>- | -<br>- |
|   | (6 months) | n = 20<br>(%) | 20<br>100            | -<br>- | -<br>- | 20<br>100             | -<br>- | -<br>- | 20<br>100      | -<br>- | -<br>- |
|   | (1 year)   | n = 20<br>(%) | 20<br>100            | -<br>- | -<br>- | 20<br>100             | -<br>- | -<br>- | 18<br>90       | -<br>- | 2<br>- |
| Biomodification<br>with NanoCsQ               | Baseline   |               | A                    | B      | C      | A                     | B      | C      | A              | B      | C      |
|   | (7 days)   | n = 20<br>(%) | 20<br>100            | -<br>- | -<br>- | 20<br>100             | -<br>- | -<br>- | 20<br>100      | -<br>- | -<br>- |
|   | (6 months) | n = 20<br>(%) | 20<br>100            | -<br>- | -<br>- | 20<br>100             | -<br>- | -<br>- | 20<br>100      | -<br>- | -<br>- |
|   | (1 year)   | n = 20<br>(%) | 20<br>100            | -<br>- | -<br>- | 20<br>100             | -<br>- | -<br>- | 20<br>100      | -<br>- | -<br>- |

## Discussion

Dental erosion is a complex process characterized by mineral dissolution that exposes the organic matrix to bacterial and enzymatic degradation, such as metallo-proteinases (MMPs)<sup>31,32</sup>.

Biomodifying substances such as chitosan and green tea have potential against erosive dentin lesions<sup>6,33</sup>. Chitosan has been used to improve the mechanical resistance of collagen, thereby, increasing its resistance to the degradation of its fibrils, which are used as support to the establishment of an adhesive interface obtained during restorative procedures with dental composites<sup>5,6</sup>. Benefits were demonstrated through the use of chitosan on the dentin such as the increase of surface resistance of the dentin<sup>16</sup> and the mechanical resistance of dental restorations, contributing to less hydrolytic degradation of collagen fibrils by collagenases<sup>14</sup>. Chitosan also promotes collagen preservation and efficacy in preventing and treating dentin erosion<sup>34,35</sup>, factors that can contribute to the clinical longevity of dental restorations in erosive lesions.

The protective effects of chitosan on the collagen fibrils<sup>34,35</sup> and the increase of the bond resistance of adhesive restorations when green tea was used<sup>36,37</sup>. Could have contributed to the longevity of the restorations. The possible explanation for absence of statistical difference for control group is the short period of clinical evaluation. The literature is lacking in studies on the efficacy of green tea in chitosan nanoformulations to improve adhesive restorations, especially in eroded substrate.

Among the MMPs inhibitors, green tea, a natural inhibitor of MMPs, as well as its active components had therapeutic potential along with EGCG, a polyphenol found in the green tea. EGCG when applied on the dentin has satisfactory results, for example, protective effect against dentin erosion<sup>33</sup> and improvement in the adhesive resistance when used combined with resin composites<sup>37</sup>.

In our study, clinical and photographic evaluations of the baseline-, 6-, and 12-month time points showed no significant difference for both clinical (retention, marginal discoloration, secondary caries, marginal adaptation, and post-operative sensitivity) and photographic criteria (restoration color, marginal pigmentation, and anatomic shape). The main limitations of this study were the "n" of samples that meet the inclusion criteria although adequate was relatively low, and the heterogeneity of erosive lesions. A possible explanation for the outcomes is the restorative materials' quality, such as the Tetric N-Bond adhesive (Ivoclar), IPS Empress Direct composite (Ivoclar), as well as the careful clinical protocol. The selective enamel etching can be another factor that collaborated with the final results in this study once, the retention rates observed here were satisfactory<sup>38,39</sup>. The use of selective enamel etching increases the bond resistance of the enamel<sup>40</sup>, which might have contributed to the low loss index of restorations we observed.

As for the polymerization of the composite resin, the light-curing unit used had its power previously measured (1200 mW/cm<sup>2</sup>) and was fully charged. The increments were standardized in 2 mm and the light source was really close to the dental surface. Literature demonstrates that the constant use of the light-curing for more than 25 times without previous loading reduces the polymerization intensity<sup>41</sup>. In this study, only two restorations were performed per each appointment, to avoid possible overload or radiant power loss.

Two dental restorations from the control group obtained charlie score for the criteria retention upon 12 months and needed to be replaced by new ones. One of them

was done in the maxillary central incisor (palatal face) and the other was done in the vestibular face of a mandibular pre-molar. During 12 months of follow-up, no failure regarding retention was observed in the experimental group, the one that underwent biomodification of the dental surface, we can thus accept the two hypotheses raised initially. *In vitro*<sup>33,37</sup> and *situ*<sup>42</sup> studies highlight that green tea has a promising protective effect against dentin erosion<sup>33</sup>, as well as it improves the adhesive resistance in restorative procedures that involve the dentin<sup>36,37</sup>, and increased the microhardness of dentin<sup>28</sup>.

In corroboration with the present study, Souza et al.<sup>27</sup>(2021) noted that the application of 2.5% chitosan nanoformulation on eroded dentin did not increase failures of resin restorations after 1 year and it can be used as a pre-treatment solution. Vailati et al.<sup>3</sup> (2013) found that restorations of erosive lesions had marginal integrity and absence of infiltration 6 years after the clinical procedure. Wilder et al.<sup>2</sup> (2009) observed that the retention rates after 12 years were approximately 93% in the group that underwent selective enamel etching and 84% in the group subjected to non-selective etching, with a retention rate of 89%, the restorations in both groups had classification "alpha" of 88% or above in all the categories of clinical evaluation, except for marginal coloration.

The outcomes of our study showed that overall, the use of a green tea-containing chitosan nanoformulation did not affect the performance of dental composite restorations after 12 months. Due to the promising results found in the literature concerning the use of these modifying agents on the eroded dentin, more studies need to be conducted to indicate this protocol on clinical practice.

## Acknowledgments

The authors acknowledge the National Council for Scientific and Technological Development for the funding concession (#130194/2019-0).

F.A.C.Z. and S.A.M would like to thank the São Paulo Research Foundation (FAPESP) for the scholarships [#2017/11582-1 and #2019/04807-2] awarded.

A.C.T thank (CNPq) for the grants support #404416/2021-7 and #441673/2020-1.

## Author Contribution

**Study conception and design:** Antônio Cláudio Tedesco, Hiago Salge Borges, Fabiana Almeida Curylofo-Zotti, Silmara Aparecida Milori Corona;

**Data collection:** Renato Gonçalves dos Reis, Thiago Vinicius Cortez;

**Analysis and interpretation of results:** Renato Gonçalves dos Reis, Fabiana Almeida Curylofo-Zotti, Aline Evangelista Souza-Gabriel, Silmara Aparecida Milori Corona.

**Author; draft manuscript preparation:** Renato Gonçalves dos Reis, Thiago Vinicius Cortez, Aline Evangelista Souza-Gabriel.

All authors actively participated in the discussion of the manuscript's findings, and have revised and approved the final version of the manuscript.

---

## References

1. Warreth A, Abuhijleh E, Almaghribi MA, Mahwal G, Ashawish A. Tooth surface loss: a review of the literature. *Saudi Dent J.* 2020 Feb;32(2):53-60. doi: 10.1016/j.sdentj.2019.09.004.
2. Wilder AD Jr, Swift EJ Jr, Heymann HO, Ritter AV, Sturdevant JR, Bayne SC. A 12-year clinical evaluation of a three-step dentin adhesive in noncarious cervical lesions. *J Am Dent Assoc.* 2009 May;140(5):526-35. doi: 10.14219/jada.archive.2009.0220.
3. Vailati F, Gruetter L, Belser UC. Adhesively restored anterior maxillary dentitions affected by severe erosion: up to 6-year results of a prospective clinical study. *Eur J Esthet Dent.* 2013;8(4):506-30.
4. Zimmerli B, De Munck J, Lussi A, Lambrechts P, Van Meerbeek B. Longterm bonding to eroded dentin requires superficial bur preparation. *Clin Oral Invest.* 2012 Oct;16(5):1451-61. doi: 10.1007/s00784-011-0650-8.
5. de Souza Costa CA, Hebling J, Scheffel DL, Soares DG, Basso FG, Ribeiro AP. Methods to evaluate and strategies to improve the biocompatibility of dental materials and operative techniques. *Dent Mater.* 2014 Jul;30(7):769-84. doi: 10.1016/j.dental.2014.04.010.
6. Fakhri E, Eslami H, Maroufi P, Pakdel F, Taghizadeh S, Ganbarov K, et al. Chitosan biomaterials application in dentistry. *Int J Biol Macromol.* 2020 Nov;162:956-74. doi: 10.1016/j.ijbiomac.2020.06.211.
7. Muzzarelli C, Muzzarelli RA. Natural and artificial chitosan-inorganic composites. *J Inorg Biochem.* 2002 Nov;92(2):89-94. doi: 10.1016/s0162-0134(02)00486-5.
8. Pimenta JA, Zapparoli D, Pécora JD, Cruz-Filho AM. Chitosan: effect of a new chelating agent on the microhardness of root dentin. *Braz Dent J.* 2012;23(3):212-7. doi: 10.1590/s0103-64402012000300005.
9. Husain S, Al-Samadani KH, Najeeb S, Zafar MS, Khurshid Z, Zohaib S, et al. Chitosan biomaterials for current and potential dental applications. *Materials (Basel).* 2017 May;10(6):602. doi: 10.3390/ma10060602.
10. Elsaka SE, Elnaghy AM. Antibacterial activity of calcium hydroxide combined with chitosan solutions and the outcomes on the bond strength of Real Sealer sealer to radicular dentin. *J Biomed Res.* 2012 May;26(3):193-9. doi: 10.7555/JBR.26.20110136.
11. Rabea EI, Badawy ME, Stevens CV, Smagghe G, Steurbaut W. Chitosan as antimicrobial agent: applications and mode of action. *Biomacromolecules.* 2003 Nov-Dec;4(6):1457-65. doi: 10.1021/bm034130m.
12. Silva PV, Guedes DF, Pecora JD, Cruz-Filho AM. Time-dependent effects of chitosan on dentin structures. *Braz Dent J.* 2012;23(4):357-61. doi: 10.1590/s0103-64402012000400008.
13. Profeta AC, Mannocci F, Foxton RM, Thompson I, Watson TF, Sauro S. Bioactive effects of a calcium/sodium phosphosilicate on the resin-dentine interface: a micro tensile bond strength, scanning electron microscopy, and confocal microscopy study. *Eur J Oral Sci.* 2012 Aug;120(4):353-62. doi: 10.1111/j.1600-0722.2012.00974.x.
14. Fawzy AS, Nitisusanta LI, Iqbal K, Daood U, Beng, LT, Neo J. Chitosan/Riboflavin-modified demineralized dentin as a potential substrate for bonding. *J Mech Behav Biomed Mater.* 2013 Jan;17:278-89. doi: 10.1016/j.jmbbm.2012.09.008.
15. Bedran-Russo AK, Pereira PN. The application of crosslinkers to dentin collagen enhances the ultimate tensile strength. *J Biomed Mater Res B Appl Biomater.* 2007 Jan;80(1):268-72. doi: 10.1002/jbm.b.30593.
16. Shrestha A, Friedman S, Kishen A. Photodynamically crosslinked and chitosan-incorporated dentin collagen. *J Dent Res.* 2011 Nov;90(11):1346-51. doi: 10.1177/0022034511421928.

17. Dash M, Chiellini F, Ottenbrite RM, Chiellini E. Chitosan-A versatile semi-synthetic polymer in biomedical applications. *Prog Polym Sci*. 2011 Aug;36(8):981-1014. doi: 10.1016/j.progpolymsci.2011.02.001.
18. Tjäderhane L, Nascimento FD, Breschi L, Mazzoni A, Tersariol IL, Geraldini S, et al. Optimizing dentin bond durability: strategies to prevent hydrolytic degradation of the hybrid layer. *Dent Mater*. 2013 Oct;29(10):999-1011. doi: 10.1016/j.dental.2013.07.016.
19. Amaral RC, Solari, HP. Collagen crosslinking for the treatment of keratoconus. *Rev Bras Oftalmol*. 2009;68(6):359-64. doi: 10.1590/S0034-72802009000600008.
20. Nishimura M, Ishiyama K, Watanabe A. Determination of theaflavins including methylated theaflavins in black tea leaves by solid-phase extraction and HPLC analysis. *J Agric Food Chem*. 2007 Sep;55(18):7252-7. doi: 10.1021/jf070312m.
21. Aguiar TR, Vidal CM, Phansalkar RS. Dentin biomodification potential depends on the polyphenol source. *J Dent Res*. 2014 Apr;93(4):417-22. doi: 10.1177/0022034514523783.
22. Chu C, Deng J, Man Y, Qu Y. Green Tea Extracts Epigallocatechin-3-gallate for Different Treatments. *Biomed Res Int*. 2017;2017:5615647. doi: 10.1155/2017/5615647.
23. Santiago SL, Osorio R, Neri JR, Carvalho RM, Toledano M. Effect of the flavonoid epigallocatechin-3-gallate on resin-dentin bond strength. *J Adhes Dent*. 2013 Dec;15(6):535-40. doi: 10.3290/j.jad.a29532.
24. Shpigelman A, Cohen Y, Livney YD. Thermally-induced b-lactoglobulin-EGCG nanovehicles: loading, stability, sensory and digestive-release study. *Food Hydrocoll*. 2012 Oct;29(1):57-67. doi: 10.1016/j.foodhyd.2012.01.016.
25. Sasaki H, Matsumoto M, Tanaka T, Maeda M, Nakai M, Hamada S, et al. Antibacterial activity of polyphenol components in oolong tea extract against *Streptococcus* mutants. *Caries Res*. 2004 Jan-Feb;38(1):2-8. doi: 10.1159/000073913.
26. Xu Z, Neoh KG, Lin CC, Kishen A. Biomimetic deposition of calcium phosphate minerals on the surface of partially demineralized dentine modified with phosphorylated chitosan. *J Biomed Mater ResB Appl Biomater*. 2011 Jul;98(1):150-9. doi: 10.1002/jbm.b.31844.
27. Souza JC, Tedesco AC, Takahashi LAU, Curylofo-Zotti FA, Souza-Gabriel AE, Corona SAM. Influence of nanoparticulated chitosan on the biomodification of eroded dentin: clinical and photographic longitudinal analysis of restorations. *J Mater Sci Mater Med*. 2021 Jan;32(1):11. doi: 10.1007/s10856-020-06487-2.
28. Curylofo-Zotti FA, Tedesco AC, Lizarelli GTC, Takahashi LAU, Corona SAM. Effect of green tea-loaded chitosan nanoparticles on leathery dentin microhardness. *Odontology*. 2021 Oct;109(4):860-7. doi: 10.1007/s10266-021-00611-6.
29. Ururahy MS, Curylofo-Zotti FA, Galo R, Nogueira LF, Ramos AP, Corona SA. Wettability and surface morphology of eroded dentin treated with chitosan. *Arch Oral Biol*. 2017 Mar;75:68-73. doi: 10.1016/j.archoralbio.2016.11.017.
30. Cvar JF, Ryge G. Reprint of criteria for the clinical evaluation of dental restorative materials. 1971. *Clin Oral Investig*. 2005 Dec;9(4):215-32. doi: 10.1007/s00784-005-0018-z.
31. Cruz JB, Bonini G, Lenzi TL, Imparato JCP, Raggio DP. Bonding stability of adhesive systems to eroded dentin. *Dent Mater*. 2015;29:S1806-83242015000100284. doi: 10.1590/1807-3107BOR-2015.vol29.0088.
32. Tjäderhane L, Buzalaf MAR, Carrilho M, Chaussain C. Matrix metalloproteinases and other matrix proteinases in relation to cariology: the era of 'dentin degradomics'. *Caries Res*. 2015;49(3):193-208. doi: 10.1159/000363582.
33. Passos VF, Melo MAS, Lima JPM, Marçal FF, Costa CAGA, Rodrigues LKA, et al. Active compounds and derivatives of *camellia sinensis* responding to erosive attacks on dentin. *Braz Oral Res*. 2018 May;32:e40. doi: 10.1590/1807-3107bor-2018.vol32.0040.

34. Beltrame APCA, Suchyta D, Abd Alraheam I, Mohammed A, Schoenfish M, Walter R, et al. Effect of phosphorylated chitosan on dentin erosion: an in vitro study. *Caries Res.* 2018;52(5):378-86. doi: 10.1159/000486521.
35. Souza BM, Machado PF, Vecchia LR, Magalhães AC. Effect of chitosan solutions with or without fluoride on the protection against dentin erosion in vitro. *Eur J Oral Sci.* 2020 Dec;128(6):495-500. doi: 10.1111/eos.12740.
36. Souza-Gabriel AE, Sousa-Neto MD, Scatolin RS, Corona SAM. Durability of resin on bleached dentin treated with antioxidant solutions or lasers. *J Mech Behav Biomed Mater.* 2020 Apr;104:103647. doi: 10.1016/j.jmbbm.2020.103647.
37. Macedo FAA, Souza NO, Lemos MVS, De-Paula DM, Santiago SL, Feitosa VP. Dentin bonding and physicochemical properties of adhesives incorporated with epigallocatechin-3-gallate. *Odontology.* 2019 Jan;107(1):23-28. doi: 10.1007/s10266-018-0367-0.
38. Van Landuyt KL, Peumans M, De Munck J, Lambrechts P, Van Meerbeer B. Extension of a one-step self-etch adhesive into a multi-step adhesive. *Dent Mater.* 2006 Jun;22(6):533-44. doi: 10.1016/j.dental.2005.05.010.
39. Muñoz MA, Luque I, Hass V, Reis A, Loguercio AD, Bombarda NH. Immediate bonding properties of universal adhesives to dentine. *J Dent.* 2013 May;41(5):404-11. doi: 10.1016/j.jdent.2013.03.001.
40. Perdigão J, Dutra-Corrêa M, Saraceni CH, Ciaramicoli MT, Kiyam VH, Queiroz CS. Randomized clinical trial of four adhesion strategies: 18-month results. *Oper Dent.* 2012 Jan-Feb;37(1):3-11. doi: 10.2341/11-222-C.
41. André CB, Nima G, Sebold M, Giannini M, Price RB. Stability of the light output, oral cavity tip accessibility in posterior region and emission spectrum of light-curing units. *Oper Dent.* 2018 Jul/Aug;43(4):398-407. doi: 10.2341/17-033-L.
42. Magalhães AC, Wiegand A, Rios D, Hannas A, Attin T, Buzalaf MA. Chlorhexidine and green tea extract reduce dentin erosion and abrasion in situ. *J Dent.* 2009 Dec;37(12):994-8. doi: 10.1016/j.jdent.2009.08.007.