

## **BULBAR URETHROPLASTY USING THE DORSAL APPROACH: CURRENT TECHNIQUES**

GUIDO BARBAGLI, ENZO PALMINTERI, GIORGIO GUAZZONI, ANDRE CAVALCANTI

*Center for Urethral and Genitalia Reconstructive Surgery, Arezzo, Italy, and Ospedale  
ed Università "Vita e Salute – San Raffaele", Milan, Italy*

### **ABSTRACT**

**Introduction:** The use of flaps or grafts is mandatory in patients with longer and complex strictures. In 1995-96 we described a new dorsal onlay graft urethroplasty. Over time, our original technique was better defined and changed. Now this procedure (also named Barbagli technique) has been greeted with a fair amount of enthusiasm in Europe and in the United States.

**Surgical Technique:** The patient is placed in normal lithotomy position, and a midline perineo-scrotal incision is made. The bulbar urethra is then free from the bulbo-cavernous muscles, and is dissected from the corpora cavernosa. The urethra is completely mobilized from the corpora cavernosa, it is rotated 180 degrees, and is incised along its dorsal surface. The graft (preputial skin or buccal mucosa) or the flap is fixed and quilted to the tunica albuginea of the corporal bodies. The right mucosal margin of the opened urethra is sutured to the right side of the patch-graft. The urethra is rotated back into its original position. The left urethral margin is sutured to the left side of the patch graft and to the corporal bodies, and the grafted area is entirely covered by the urethral plate. The bulbo-cavernous muscles are approximated over the grafted area. A 16F silicone Foley catheter is left in place.

**Comments:** Dorsal onlay graft urethroplasty is a versatile procedure that may be combined with various substitute materials like preputial skin, buccal mucosa grafts or pedicled flaps.

**Key words:** urethra; urethral stricture; reconstructive surgical procedures; tissue transplantation

**Int Braz J Urol. 2003; 29: 155-61**

### **INTRODUCTION**

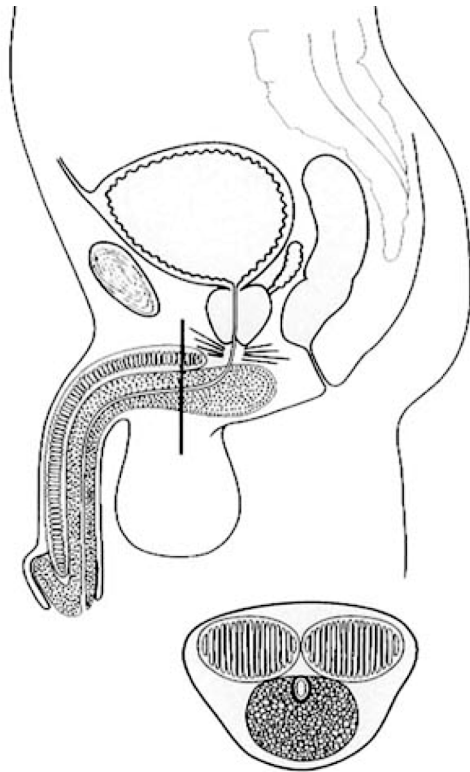
A wide array of techniques is used in reconstructive surgery for bulbar urethral stricture diseases, and modifications are continuously added to them. Stricture excision and anastomotic repair is appropriate only for short and untreated lesions of traumatic origin, following a blunt perineal trauma. End-to-end urethroplasty for bulbar adult-urethral stricture has greater than 95% durable cure rates and low complication rates (1). The use of flaps or grafts is mandatory in patients with longer and complex strictures.

In 1995-96 we described a new dorsal onlay graft urethroplasty (2-4): an external longitudinal

urethrotomy is created in the dorsal urethral surface, the graft (skin or buccal mucosa) is sutured and quilted over the corpora cavernosa, and the urethra is sutured over the graft (5). Over time, our original technique was better defined and new changes were added to it (6). Now, this procedure (also named Barbagli technique) has been greeted with a fair amount of enthusiasm in Europe and in the United States (7-12).

### **Anatomical Remarks**

The male urethra can be divided into 2 different portions: the posterior urethra, which includes the membranous and the prostatic regions, and the anterior urethra. The anterior urethra includes



*Figure 1 - Anatomy of penile and bulbar urethra.*

navicularis, penile and bulbous regions, and is surrounded by the corpus spongiosum soft tissue. In the bulbar urethra the relationship between the spongiosum tissue and the mucosal membrane is quite different from the relationship in the penile region: the corpus spongiosum is thick in the ventral urethral surface and thin in the dorsal urethral surface. Furthermore, the urethral lumen is located dorsally and not centrally (Figure-1).

## SURGICAL TECHNIQUE

### Preparation of the Bulbar Urethra

The patient is placed in normal lithotomy position, and a midline perineo-scrotal incision is made. The bulbo-cavernous muscles are separated in the midline and, in patients with proximal bulbar urethral stricture, the central tendon of the perineum is dissected. The bulbar urethra is then free from the bulbo-cavernous muscles, and it is dissected from the corpora cavernosa (Figure-2, A). The urethra is completely mobilized from the corpora cavernosa, it

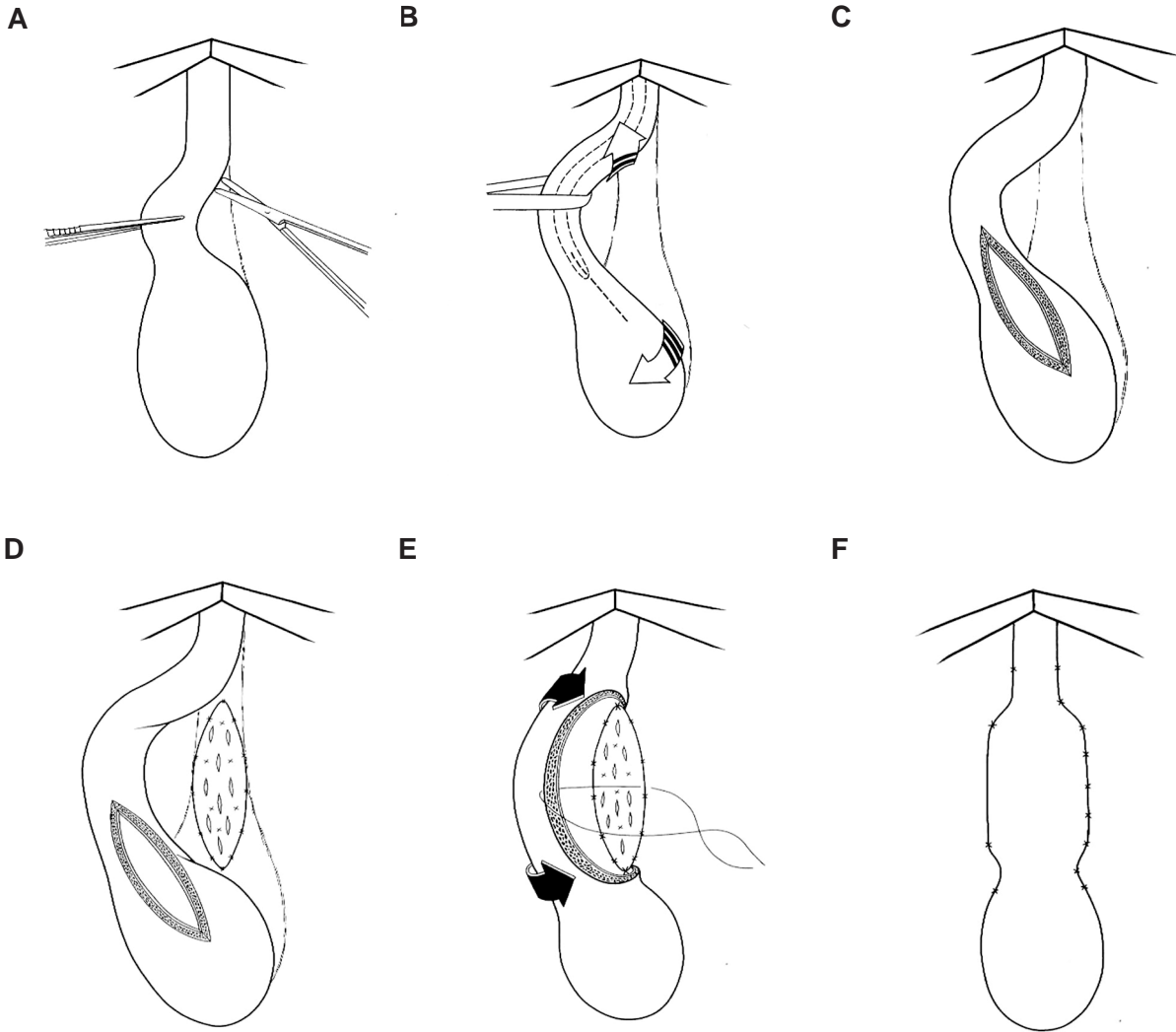
is rotated 180 degrees, and is incised along its dorsal surface (Figure-2, B). The stricture is opened along its whole length (Figure-2, C).

### Preparation and Suture of the Graft (Skin or Buccal Mucosa)

In patients with a shorter than 4 cm stricture, an ovoid strip of ventral penile skin is outlined for harvesting. In patients with a longer than 4 cm stricture, a double circumferential subcoronal incision is made for harvesting a longer preputial skin strip. When local epithelial foreskin is unavailable or when the patient does not agree with harvesting from the prepuce, the buccal mucosa is preferred to other various types of extra-genital free grafts because of its qualities. We choose the inner cheek over the lip as a donor site, because the width of the lip limits the size of the graft. Moreover, the buccal mucosa is thicker and more resistant in the cheek than the buccal mucosa from the lip. Buccal mucosa harvesting increases operative time by 1 hour. Thus, a 2-team approach should be used. The perineal team exposes and calibrates the strictured tract, while another team simultaneously harvests the graft from the mouth. This procedure also increases sterilization of the surgical field. Reduced operative time offers remarkable advantages and may prevent troublesome complications due to prolonged lithotomy position.

The fenestrated ovoid preputial skin or buccal mucosa graft is spread-fixed and quilted to the overlying tunica albuginea of the corporal bodies (Figure-2D). The right mucosal margin of the opened urethra is sutured to the right side of the patch graft, spaying open the strictured tract to the new roof, which is the spread, fixed graft (Figure-2E). The urethra is rotated back into its original position (Figure-2E). The left urethral margin is sutured to the left side of the patch graft and to the corporal bodies, and the grafted area is entirely covered by the urethral plate (Figure-2F). The bulbo-cavernous muscles are approximated over the grafted area. A small suction drain is placed, and an indwelling 16F silicone Foley catheter is left in place. Suprapubic cystostomy is unnecessary.

In patients with a stricture that requires a complete removal of the scar, the urethra is com-



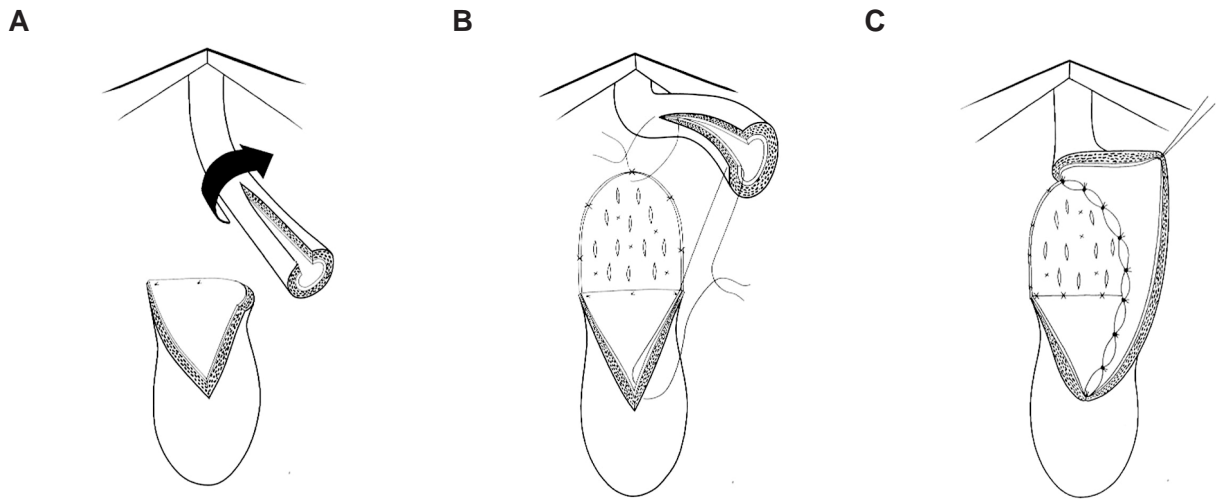
**Figure 2 (A to F)** - Preparation of the bulbar urethra and dorsal onlay urethroplasty using skin or buccal mucosa graft: standard technique.

pletely transected. The distal urethra is mobilised from the underlying corpora cavernosa. The proximal mucosal edge is spatulated and spayed over the corpora cavernosa, and the mobilised distal urethra is widely opened along its dorsal surface (Figure-3, A). The skin or buccal mucosa graft is spread-fixed and quilted to the underlying corpora, and its lower margin is sutured to the proximal mucosal edge of the urethra (Figure-3, B). The left mucosal margin of the opened distal urethra is sutured to the left side of

the graft (Figure-3, C). The urethra is rotated back over the grafted area, sutured to the proximal mucosal edge and to the right corpora cavernosa. The bulbo-cavernous muscles are sutured over the bulbar urethra, and the perineal closure is made as described.

#### **Preparation and Suture of the Flap**

In patients with a stricture that recurred after urethroplasty, or in patients who have serious is-



*Figure 3 (A to C) - Augmented roof strip anastomotic urethroplasty.*

chemic urethral disease or damage, it may be useful the use of a pedicled flap owing to improved graft take and neovascularization. A midline perineal incision is made, and a longitudinal ventral penile skin island is outlined in the penile shaft (Figure-4, A). The bulbar urethra is circumferentially mobilized from the corpora cavernosa and rotated 180 degrees (Figure-4, B). The longitudinal penile skin island carried on the ventral dartos fascial pedicle (Figure-4, B). The fascial pedicle is extensively dissected and mobilized to allow the transposition of the skin island into the perineum, using a finger-made tunnel (Figure-4, B). The bulbar urethra is opened along its dorsal surface; the skin island is sutured to the corpora cavernosa (Figure-4, C). The urethra is rotated back over the island flap, and the grafted area is covered by the urethral plate.

### **Postoperative Course**

On the day after the surgery the drain is removed, and the patient is discharged from hospital. Three weeks later, the bladder is filled with contrast medium, the Foley catheter is removed and a voiding cystourethrography is obtained. Uroflowmetry and urine culture is repeated every 4 months during the first year and yearly thereafter. Radiological stud-

ies are repeated when uroflowmetry is less than 14 mL per second. Clinical outcome was considered a failure in any case postoperative instrumentation was needed, including dilatation.

### **Intraoperative, Perioperative and Postoperative Complications**

In patients who have undergone repeated internal urethrotomies it may be difficult or impossible to separate the urethra from the corpora cavernosa, and the tunica albuginea may be opened or injured. In this case it is important to realise that there is damage on the corpora cavernosa and the opening must be repaired immediately. If it is difficult to free the urethra from the corpora, a lateral or ventral opening can be made into the urethral lumen. In this case, it might be better to use buccal mucosa instead of prepu-tial skin as a graft.

In patients who have undergone an augmentation urethroplasty for a longer than 6 cm stricture, the presence of an urethral fistula or an extravasation of the contrast medium can be observed during the first radiological investigation. In this case a 14F Foley silicone catheter should be left in place, and a new radiological study should be performed 2 weeks later.

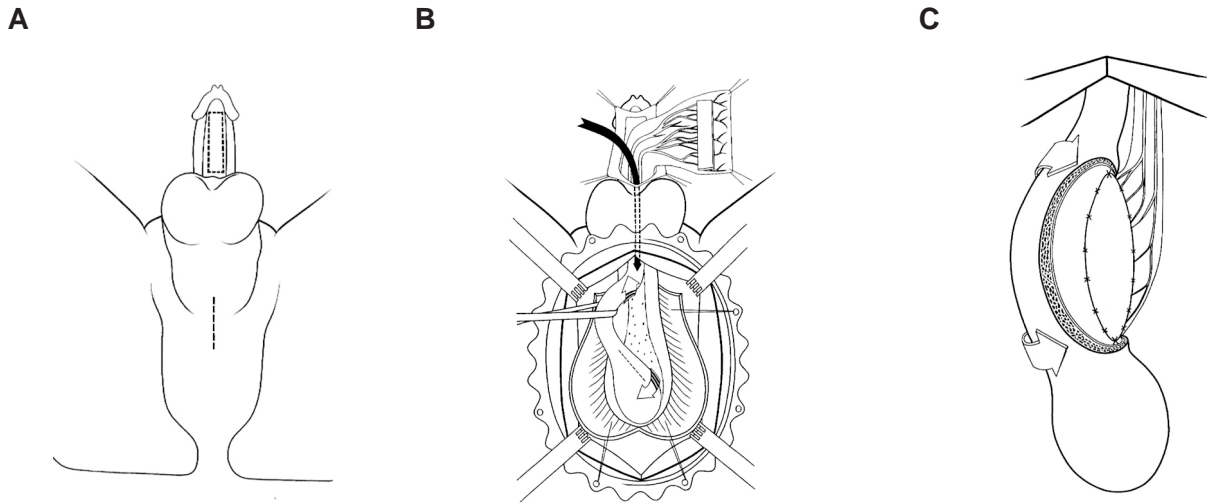


Figure 4 (A to C) - Dorsal onlay urethroplasty using a ventral penile fascial flap with a longitudinal skin island.

**Long-term Results and Attrition Rate of Dorsal Onlay Graft Urethroplasty**

Table-1 summarizes the results from 5 different series of a total of 176 patients with a follow-up of 19 to 43 months (8-10,13,14). The overall success rate ranged from 85% to 97% (8-10,13,14). Any patient who required postoperative instrumentation - including periodic dilation – was considered a treatment failure.

In 1998, we reported our results in 37 patients who had undergone dorsal onlay procedures with prepuce (n = 31) or buccal mucosa (n = 6) (13). With a mean follow-up of 21.5 months, the procedure was classified as successful in 34 (92%) patients (13). In 2001, with a mean follow-up pf 21.5 to 48 months in

40 patients with preputial grafts, the success rate declined to 85% (14). The latter series did not include patients who had a buccal mucosa graft because the follow-up period was insufficient in these cases (14).

**COMMENTS**

Surgical repair of bulbar urethral strictures is based on anastomotic repair for short lesions, while free grafts (preputial skin or buccal mucosa) or pedicled flaps are suggested for longer and complex strictures.

Current techniques adopt graft or flap apposition on the ventral surface of the urethra, but this graft often lacks the mechanical support of a fixed

Table 1 - Results of dorsal onlay techniques.

Authors	Year	No. patients	Follow-up (months)	Success rate (%)
Barbagli et al.	1998	37	21.5	92
Iselin & Webster	1999	28	19	97
Guralnick & Webster	2001	29	28	93
Barbagli et al.	2001	40	43	85
Andrich et al.	2001	42	36	95



**Table 2 - Advantages of dorsal onlay techniques.**

- 
- Simple and quick to perform
  - Does not increase the risk of punch formation and postmicturition dribble.
  - Does not increase the risk of fistula or patch necrosis.
  - Reduces the chance of graft shrinkage and sacculation.
  - Decreases the risk of spongiosal bleeding.
  - Versatile procedure, which may be combined with a pedicled flap or an augmented roof anastomotic repair.
  - Attractive in reoperative cases in which a ventral onlay had been previously used.
  - Does not require extensive training in reconstructive procedures using tissue transfer techniques.
- 

bed, which allows it to fold on itself, reducing the opportunity of neovascularization, and decreasing the calibre of the reconstructed urethra (8). Moreover, sacculation at the graft side may occur, causing post voiding dribbling and ejaculatory failure. Sequestration of semen and residual infected urine inside the pseudodiverticulum may further compromise the state of the adjacent urethra and facilitate recurrent stricture disease (8,15-19).

Recently, buccal mucosa grafts have been used instead of preputial skin in a wide series of patients who were treated with ventral onlay patch urethroplasty. The incidence of mechanical weakening of the buccal mucosa graft is actually unknown. Buccal mucosa is thicker and has a higher density of elastic fibres than preputial skin; it is probably more resistant to mechanical weakening over time. A long-term follow-up of these cases is mandatory.

The dorsal approach to strictures of the bulbar urethra is anatomically simpler than the ventral one, requiring less extensive opening of the spongy tissue since the urethral lumen is located dorsally in this region (Figure-1) (5). Using this approach, significant bleeding from the corpus spongiosum is avoided and the mechanical weakening of the graft is unlikely. A serious complication of free graft urethroplasty is the necrosis of the patch, caused by vascularization failure from its bed. When this occurs in ventrally placed grafts, an urethro-perineal fistula of considerable size is inevitable; this effect did not occur in patients treated with dorsal graft apposition (3). The dorsal placement of the graft provides a better opportunity for roof-strip epithelial regeneration,

according to the principles described by different authors (20-24). The reported experience with dorsal onlay graft urethroplasty shows that graft take is also adequate in the corporal bodies, although the opened corpus spongiosum may contribute to vascularization on both sides of the graft (2-14).

The Barbagli procedure has many advantages (Table-2). Dorsal onlay graft urethroplasty is a versatile procedure which may be combined with various substitute materials like preputial skin, buccal mucosa grafts or pedicled flaps. Other substitute materials like human urethral mucosa from corpses or collagen matrix will be possible in the future.

Long-term results of a wide series of patients showed a final success rate of 92% to 97%. Any substitution urethroplasty deteriorates over time. In our series of patients the success rate of dorsal onlay graft urethroplasty decreased from 92% to 85% with an extended follow-up from 21.5 to 43 months.

With regard to substitute material concerns (buccal mucosa versus preputial skin), a long-term follow-up is mandatory to establish whether buccal mucosa is superior to foreskin as an urethral substitute material.

At present we currently use both according to the patient's preference, to the status of the genital tissues or to stricture characteristics.

## REFERÊNCIAS

1. Santucci RA, Mario LA, McAninch JW: Anastomotic urethroplasty for bulbar urethral stricture: analysis of 168 patients. *J Urol.* 2002; 167: 1715-9.

## BULBAR URETHROPLASTY

2. Barbagli G, Menghetti I, Azzaro F: A new urethroplasty for bulbar urethral strictures. *Acta Urol Ital.* 1995; 9: 313-7.
3. Barbagli G, Selli C, di Cello V, Mottola A: A one-stage dorsal free graft urethroplasty for bulbar urethral strictures. *Br J Urol.* 1996; 78: 929-32.
4. Barbagli G, Selli C, Tosto A, Palminteri E: Dorsal free graft urethroplasty. *J Urol.* 1996; 155: 123-6.
5. Iselin CE, Webster GD: Dorsal onlay graft urethroplasty for repairs of bulbar urethral stricture. *J Urol.* 1999; 161: 815-8.
6. Palminteri E, Lazzeri M, Guazzoni G, Turini D, Barbagli G: New 2-stage buccal mucosa graft urethroplasty. *J Urol.* 2002; 167: 130-2.
7. Jordan GH: Anterior urethral reconstruction: concepts and concerns. *Cont Urol.* 1998; 10: 80-96.
8. Iselin C, Webster GD: Dorsal onlay graft urethroplasty for repair of bulbar urethral strictures. *J Urol.* 1999; 161: 815-8.
9. Guralnick ML, Webster GD: The augmented anastomotic urethroplasty: indications and outcome in 29 patients. *J Urol.* 2001; 165: 1496-501.
10. Andrich DE, Leach CJ, Mundy AR: The Barbagli procedure gives the best results for patch urethroplasty of the bulbar urethra. *BJU Int.* 2001; 88: 385-9.
11. Andrich DE, Mundy AR: Surgery of urethral stricture disease. *Cont Urol.* 2001; 13: 32-44.
12. Barbagli G, Palminteri E, Lazzeri M: Dorsal onlay techniques for urethroplasty. *Urol Clin North Am.* 2002; 29: 389-95.
13. Barbagli G, Palminteri E, Rizzo M: Dorsal onlay graft urethroplasty using penile skin or buccal mucosa in adult bulbo-urethral strictures. *J Urol.* 1998; 160: 1307-9.
14. Barbagli G, Palminteri E, Lazzeri M, Guazzoni G, Turini D: Long-term outcome of urethroplasty after failed urethrotomy versus primary repair. *J Urol.* 2001; 165: 1918-9.
15. Barbagli G, Selli C, Tosto A: reoperative surgery for recurrent strictures of the penile and bulbous urethra. *J Urol.* 1996; 156: 76-7.
16. Pansadoro V, Emiliozzi P: Wich urethroplasty for wich results? *Curr Opin Urol.* 2002; 12: 223-7.
17. Morey AF, Duckett CP, McAninch JW: Failed anterior urethroplasty: guidelines for reconstruction. *J Urol.* 1997; 158: 1383-7.
18. Mundy AR: Results and complications of urethroplasty and its future. *Br J Urol.* 1993; 71: 322-5.
19. Webster GD, Robertson CN: The vascularized skin island urethroplasty: its role and results in urethral stricture management. *J Urol.* 1985; 133: 31-3.
20. Browne D: An operation for hypospadias. *Proc Roy Soc Med.* 1949; 42: 466-8.
21. Weaver RG, Schulte JW: Experimental and clinical studies of urethral regeneration. *Surg Gynec Obst.* 1962; 115: 729-36.
22. Weaver RG, Schulte JW: Clinical aspects of urethral regeneration. *J Urol.* 1965; 93: 247-54.
23. Moore CA: One-stage repair of stricture of bulbous urethra. *J Urol.* 1963; 90: 203-7.
24. Monseur J: L'élargissement de l'urètre au moyen du plan sou-urètral. *J Urol.[Paris]* 1980; 6: 439-42.

*Received: August 8, 2002*

*Accepted after revision: November 2, 2002*

### **Correspondence address:**

Dr. André Guilherme Cavalcanti  
Av. N.S. de Copacabana, 1066 / 1109  
Rio de Janeiro, RJ, 22060-010, Brazil  
Fax: + 55 21 2521-0893  
E-mail: andre70211@hotmail.com