

Surgical Technique Using AdVance™ Sling Placement in the Treatment of Post-Prostatectomy Urinary Incontinence

David E. Rapp, W. Stuart Reynolds, Alvaro Lucioni, Gregory T. Bales

Section of Urology, Department of Surgery, University of Chicago Pritzker School of Medicine, Chicago, Illinois, USA

ABSTRACT

Objectives: To describe and illustrate a new minimally invasive approach to the treatment of male stress urinary incontinence following prostatectomy.

Surgical Technique: Our initial experience consisted of four patients treated with the Advance sling for post-prostatectomy urinary incontinence. Sling placement involves the following steps: 1. Urethral dissection and mobilization, 2. Identification of surgical landmarks, 3. Placement of needle passers through the obturator foramen, 4. Mesh advancement, 5. Mesh tensioning and fixation, 6. Incision closure.

Comments: Based on our initial experience, we believe that the Advance Male Sling System may be a safe technique for the treatment of male stress urinary incontinence. This technique is easy to perform and may offer a reproducible, transobturator approach. Further patient accrual is ongoing to assess the safety and reproducibility of this technique. Also, additional study will focus on efficacy standards and complication rates.

Key words: prostatectomy; urinary incontinence; stress; prostheses and implants; suburethral slings
Int Braz J Urol. 2007; 33: 231-7

INTRODUCTION

The rate of post-prostatectomy incontinence (PPI) ranges between 3 and 60% (1). The treatment of PPI is often difficult and many patients ultimately require surgical intervention for symptom alleviation. Although the artificial urinary sphincter (AUS) remains the standard for post-prostatectomy incontinence surgery, it has several limitations. Foremost, the AUS can be associated with infection or the need for revision and is costly (1). Alternative techniques include bulking agent injection (collagen, Coaptite®, Macroplastique®), balloon urethral compression devices (ProAct®), and the male urethral sling.

The male sling has been reported in the literature with increasing frequency, and several different techniques have been described (2-4). Although encouraging results have been reported by many using the male sling, the variety in technique and lack of long-term outcomes have limited the widespread use of this surgical option. Further, outcome variability remains problematic (2).

The AMS AdVance Male Sling is a new mesh system developed for the treatment of male stress urinary incontinence. This system is provided in a single kit and is deployed in a transobturator approach using a trochar system similar to mesh systems widely used in the treatment of female stress urinary

incontinence. Accordingly, surgeon familiarity and procedure reproducibility may be optimized. The aim of this report is to describe the surgical technique for repair of post-prostatectomy incontinence using the AdVance system.

SURGICAL TECHNIQUE

The AMS AdVance Male Sling is a polypropylene mesh system developed for the treatment of male stress urinary incontinence. Our initial experience consisted of patients treated with the Advance sling for post-prostatectomy urinary incontinence. Men were selected based on the presence of documented stress incontinence. Per study protocol, all patients are evaluated in the office with a full history, physical examination, and urinalysis. One hour and 24-hour pad tests are performed. Subjective evaluation includes completion of the three following questionnaires: the International Consultation of Incontinence (ICI) questionnaire, the Incontinence Quality of Life (IQOL) questionnaire, and the UCLA/RAND questionnaire. All patients subsequently undergo cystoscopy to rule out the presence of stricture or other defined etiology of urinary incontinence. Finally, all patients undergo complete urodynamic evaluation.

AMS Advance Male Sling System Description

The AMS Advance Male Sling System is comprised of two needle passers and a mesh sling (Figure-1A). The sling mesh is constructed of polypropylene monofilament mesh that is precut to 1.2 cm arm width and 3.55 cm center width. Two absorbable tensioning sutures are threaded into the length of the mesh to spread fixate the mesh, allowing for flat coaptation of the urethra (Figure-1B). Further, these tensioning sutures allow for maintenance of mesh tension following placement. Plastic sheaths are placed over the mesh arms to provide ease in placement.

Surgical Technique

Appropriate anesthesia is established using general anesthesia; however, spinal anesthetic may also be used. Patients are positioned in the extended dorsal lithotomy position. A 16F Foley catheter is

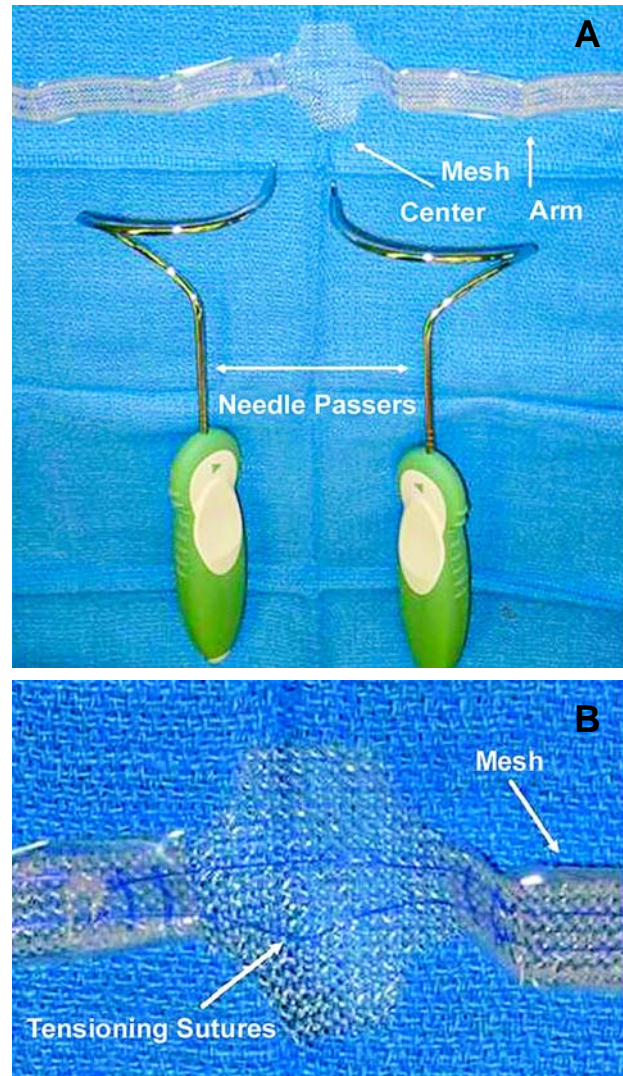


Figure 1 – AdVance™ Male Urethral Sling System. A) Two needle passers and mesh sling. B) The sling mesh is precut to 1.2 cm arm width and 3.55 cm center width. Two absorbable tensioning sutures are threaded into the length of the mesh.

placed to drain the bladder. Peri-operative antibiotics are administered, comprising Ampicillin and Gentamicin, preferred in our experience for cases involving foreign body insertion.

A vertical incision is made to the perineum approximately 1-2 cm inferior to the penoscrotal junction and carried 1 cm anterior to the rectum. Dissection is continued through Colles' fascia and the underlying bulbocavernosus muscle. Sharp dissection

is continued until the spongiosal bulb has been freely dissected. The perineal body is identified and dissection is continued proximally approximately 4 cm.

Attention is then focused on identification and marking of the anatomical landmarks for placement of the surgical passers. Initially, the adductor longus tendon is identified and marked (Figure-2, solid arrow). Each of the two trocar insertion sites are then marked, such that insertion is performed just lateral to the inferior pubic ramus (Figure-2, broken arrow). The insertion site is generally 2 cm below the adductor longus tendon such that insertion is performed at a point one third below the cephalad peak of the obturator foramen. Accordingly, a 45° angle between insertion and exit sites (at the level of the perineal body) is maintained.

Following marking, the skin sites are incised and surgical passer placement is begun. The surgeon's finger is placed inside the perineal dissection and again identifies the inferior pubic ramus where the passer will exit. Under manual guidance, the passer is advanced through the medial aspect of the obturator foramen, exiting at the level of the perineal body lateral to the spongiosal bulb (Figure-3). Care is taken to maintain a 45° angle during passage, which is aided by keeping the surgeon's hand close to the buttock and completing the trocar rotation. The passer is then hooked to the respective sling arm, which are then pulled through the obturator foramen to exit via the skin incision. This maneuver brings the mesh in place. The mesh is checked at this point to ensure that twisting has not occurred. Subsequently, the opposite passer is placed in a similar manner and the sling is pulled into place.

Attention is now focused on sling positioning and tension. The central mesh anchor is sutured into place, with the posterior aspect fixed to the spongiosal tissue at the most proximal aspect of the bulbar dissection. The distal anchor is then sutured to the spongiosal tissue, each performed with 3-0 vicryl suture (Figure-4A). Tensioning of the sling is now performed, by pulling the mesh arms such that the bulb of the corpus spongiosum is brought cephalad by the sling. Sling tensioning is increased until 3-4 cm of proximal urethral movement is obtained. Bulbar suspension is confirmed by measuring proximal movement from the initial point

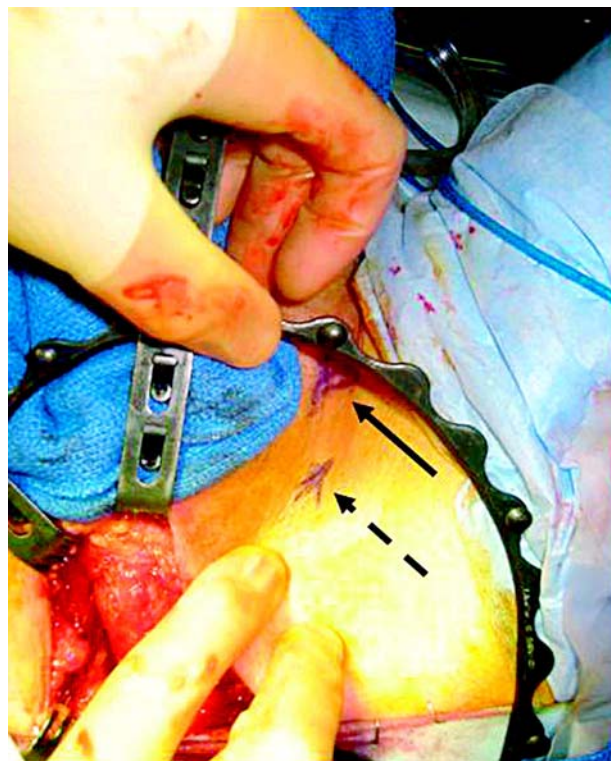

Figure 2 – Needle Passer Insertion Site. Adductor longus tendon landmark (solid arrow). Needle passer insertion sites (dotted arrow).

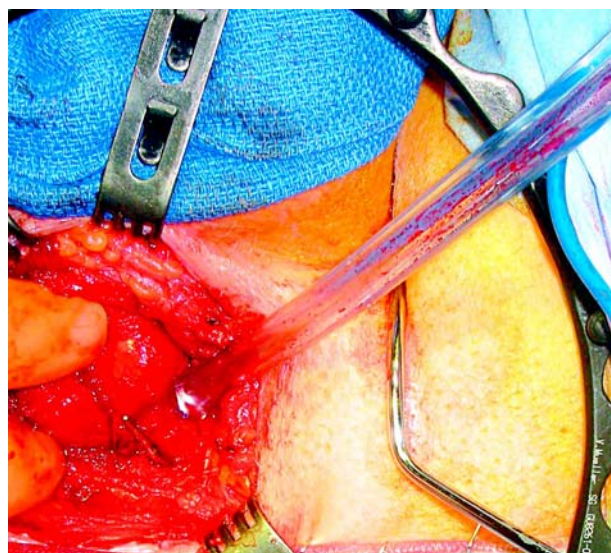


Figure 3 – Needle Passer Insertion. The needle passer is advanced through the medial aspect of the obturator foramen, exiting lateral to the spongiosal bulb at the level of the perineal body.

of fixation to the perineal body (Figure-4B). Cystourethroscopy is performed to rule out urethral or bladder injury. The arms of the mesh are cut below skin level and skin incisions closed with Dermabond (Ethicon, Somerville, NJ). The perineal dissection is then closed with a standard 3-layer closure with absorbable suture.

In our experience, patients may be discharged home immediately after surgery or admitted for overnight observation. The Foley catheter is maintained overnight. Patients discharged home following surgery are given instructions enabling them to remove the catheter at home. All patients receive five days of appropriate oral antibiotic coverage.

Surgical Experience

Since August 2006, a total of 4 patients have undergone AdVance sling placement. The mean patient age was 62 years. Mean 1-hour and 24-hour pad test weight were 5.3 and 38 grams, respectively. Average daily pad use was 3 pads/day. Stress incontinence was confirmed with urodynamic evaluation in all patients. Mean Valsalva leak point pressure was 101 cm H₂O. Mean pre-operative IQOL-SF score was 16.

Mean estimated blood loss was 142 mL and mean surgical time was 97 minutes. Significant urethral coaptation following sling placement was confirmed using cystourethroscopy in all patients. There were no intra-operative complications. All patient but one underwent Advance placement as an outpatient procedure, with the remaining patient being discharged home the following morning. All Foley catheters were removed the morning of POD one.

COMMENTS

The use of fixed urethral compression for the treatment of male stress urinary incontinence has been reported over the last four decades. The modern era of fixed urethral compression procedures has been marked primarily by the male urethral sling. Although various sling procedures exist, two general techniques have been reported with greatest frequency. In the first, periurethral compression bolsters are anchored over the rectus fascia via a separate abdominal incision (3).

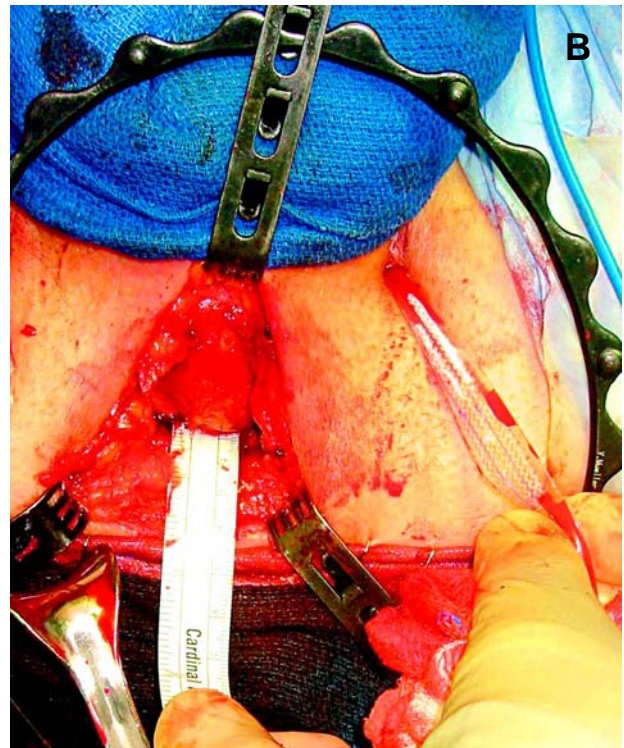
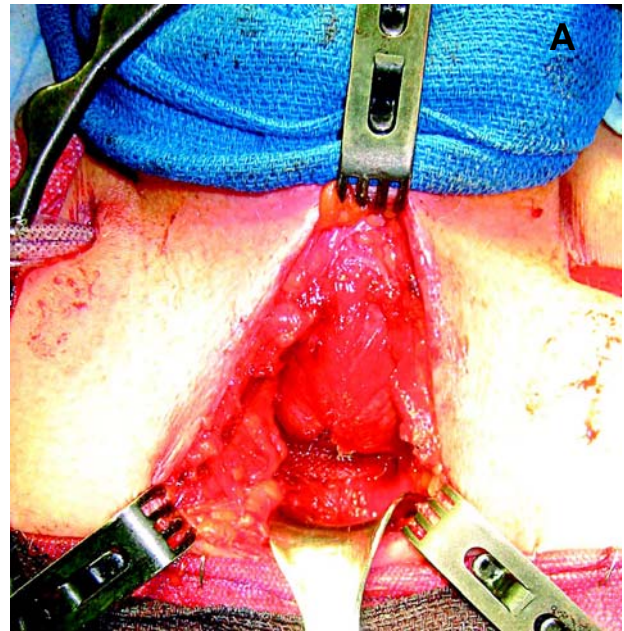


Figure 4 – Mesh Sling Placement. A) The center mesh is sutured to the spongiosal tissue with 3-0 prolene suture. B) Following tensioning of the sling, approximately 2-4 cm of proximal urethral movement is observed.

Alternatively, the use of bone screws to secure a periurethral mesh has been described in order to avoid a separate abdominal incision (2,4).

Short-term outcomes using these techniques have been favorable. However, result variability may exist based on surgeon, technique used, and definition of success (2,4). Certainly, the variation of reported results raises concerns about the reproducibility of these procedures. A second concern specific to the latter technique surrounds the placement of bone anchors, which may be associated with osseous complications such as infection or pain (4).

Concurrently, a greater experience has been reported using both the transobturator approach and mesh synthetics in the treatment of female stress urinary incontinence. Accordingly, multiple experiences demonstrate that midurethral sling placement using the transobturator approach is associated with excellent success rates and minimal complications (5). In addition, the use of synthetic mesh has gained greater popularity owing to its availability, consistent quality, inert properties, and low cost. The use of synthetic mesh has also been associated with an improved success rate in perineal male sling experience when compared to absorbable materials (e.g. dermis, fascia lata, SIS) (2).

We believe that the transobturator male sling placement represents an evolution in the treatment of male stress urinary incontinence. Foremost, this procedure restores physiologic voiding in a minimally invasive fashion using mesh, and is less expensive when compared to the AUS. The AdVance is placed via a transobturator approach, which has become popularized in the placement of midurethral slings, owing to its ease, reproducibility, and low rate of complications. Accordingly, surgeon familiarity is high, which may improve procedure reproducibility when compared to the variety of alternative male sling procedures. In addition, this approach allows for avoidance of bone anchors and related issues.

CONCLUSIONS

Based on our initial experience, we believe that the Advance Male Sling System may be a safe technique

for the treatment of male stress urinary incontinence. This technique is easy to perform and may offer a reproducible, transobturator approach. Further patient accrual is ongoing to assess the safety and reproducibility of this technique. Also, additional study will focus on efficacy standards and complication rates.

CONFLICT OF INTEREST

None declared.

REFERENCES

1. Migliari R, Pistolesi D, Leone P, Viola D, Trovarelli S: Male bulbourethral sling after radical prostatectomy: intermediate outcomes at 2 to 4-year followup. *J Urol.* 2006; 176: 2114-8.
2. Onur R, Rajpurkar A, Singla A: New perineal bone-anchored male sling: lessons learned. Onur R, Rajpurkar A, Singla A. *Urology.* 2004; 64: 58-61.
3. Stern JA, Clemens JQ, Tiplitsky SI, Matschke HM, Jain PM, Schaeffer AJ: Long-term results of the bulbourethral sling procedure. *J Urol.* 2005; 173: 1654-6.
4. Madjar S, Jacoby K, Giberti C, Wald M, Halachmi S, Issaq E, et al.: Bone anchored sling for the treatment of post-prostatectomy incontinence. *J Urol.* 2001; 165: 72-6.
5. Waltregny D, Reul O, Mathantu B, Gaspar Y, Bonnet P, de Leval J: Inside out transobturator vaginal tape for the treatment of female stress urinary incontinence: interim results of a prospective study after a 1-year minimum followup. *J Urol.* 2006; 175: 2191-5.

*Accepted after revision:
December 14, 2006*

Correspondence address:

Dr. David E. Rapp
Section of Urology
Univ Chicago Pritzker School of Medicine
MC 6038, 5841 S. Maryland Ave.
Chicago, IL 60637, USA
E-mail: derapp@yahoo.com

EDITORIAL COMMENT

Post-prostatectomy urinary incontinence is a problem for which there is currently no satisfactory treatment. Although the artificial urinary sphincter is considered the gold standard treatment, it is an expensive and complicated procedure, which is not exempt of short-, medium- and long-term risks.

The author describes the experience of patients treated for post-prostatectomy urinary incontinence using the AdVance™ Male Sling system. The main steps required for the correct use of this technique following the transobturator approach are described in detail, as an alternative to the bulking agent injection and the male urethral sling approaches. At this point, it is worth mentioning that there are other alternative treatments for male incontinence such as the implant of a silicone balloon (ProACT), the use of an adjustable external me-

chanical regulator (ReMeEx) and specially the implantation of an adjustable bulbourethral sling (Argus). In this matter, we would like to comment that as opposed to female incontinence, the treatment of post-prostatectomy male urinary incontinence must pursue to obtain maximum tension and we doubt this is achieved using the transobturator approach as effectively as adjustable and regulatable systems.

It would be advisable that the author clarifies the number of patients he has treated and his experience with respect to initial results even if these were only short term.

However, his description of the technique and visual aids are outstanding and we encourage the author to continue carry on his hard work and to publish his results as soon as possible.

Dr. Jesús Moreno Sierra

*Department of Urology
Hospital Clinico San Carlos
Complutense University
Madrid, Spain*

E-mail: dr_jmoreno@hotmail.com

EDITORIAL COMMENT

The worldwide experience with the use of suburethral slings for the treatment of post-radical prostatectomy stress urinary incontinence is growing, and clearly showing its efficacy and reproducibility, also on the long run (1,2). The different surgical techniques employed may vary on the “scaffold” used to secure the sling, either the rectus fascia or the pubic rami (3, 4). However, share the concept of suspension and compression they ensure to the bulbar urethra, allowing physiological voiding, taking into account changes in abdominal pressure and impaired manual dexterity, which could be, on the other hand, an important issue when the artificial urinary sphincter is considered (5).

The article published in the present issue of the International Braz J Urol by Rapp and co-workers is

quite interesting as it seems to show promise that good results can be also achieved passing and fixing the sling through the obturator foramen, as other authors have already shown (6). Although the number of patients studied is still too low and no follow-up is provided yet, this approach must be viewed with great interest because of the transobturator approach used, which could definitely become the standard one, for its ease, reproducibility and low complications rate, provided it will stand the proof of time.

REFERENCES

1. Stern JA, Clemens JQ, Tiplitski SI, Matschke HM, Jain PM, Schaeffer AJ: Long-term results of the bulbourethral sling procedure. J Urol. 2005; 173: 1654-6.

2. Migliari R, Pistoiesi D, Leone P, Viola D, Trovarelli S: Male bulbourethral sling after radical prostatectomy: intermediate outcomes at 2 to 4-year followup. *J Urol.* 2006; 176: 2114-8.
3. Schaeffer AJ, Clemens JQ, Ferrari M, Stamey TA: The male bulbourethral sling procedure for post-radical prostatectomy incontinence. *J Urol.* 1998; 159: 1510-5.
4. Madjar S, Jacoby K, Giberti C, Wald M, Halachmi S, Issaq E, et al.: Bone anchored sling for the treatment of post-prostatectomy incontinence. *J Urol.* 2001; 165: 72-6.
5. Raz S, Gousse AE: The male bulbourethral sling procedure for post-radical prostatectomy incontinence: editorial comment. *J Urol.* 1998; 159: 1515-6.
6. Palma PC, Dambros M, Thiel M, Romano V, Griguol O, Ricetto CL, et al.: Readjustable transobturator sling: a novel sling procedure for male urinary incontinence. *Urol Int.* 2004; 73: 354-6.

Dr. Domenico Viola

Dr. Sergio Leoni

U.O.C. Urologia

Arcispedale Santa Maria Nuova

Azienda Ospedaliera di Reggio Emilia

Reggio Emilia, Italy

E-mail: domenico.viola@asmn.re.it