

# Improving Outcome from Plastibell™ Circumcisions in Infants

Anies Mahomed, Indre Zaparackaite, Sam Adam

*Department of Paediatric Surgery, Royal Alexandra Children's Hospital, Brighton, United Kingdom*

---

## ABSTRACT

Circumcisions are among the most frequently performed operations in children and numerous techniques are employed often with varying results. Use of the Plastibell™ (Hollister Incorporated, Illinois, USA), under local anesthetic, is popular for cultural and religious circumcisions but is not without its problems. Complications of Plastibell™ (slippage, migration, bleeding and serious infection) have been reported. Described is a prospective series of cases in which modifications to the standard Plastibell™ technique were utilized to improve outcomes, in particular, the risk of bleeding.

**Key words:** *circumcision; infant; complications*

**Int Braz J Urol. 2009; 35: 310-4**

---

## INTRODUCTION

The authors have undertaken cultural circumcisions under local anesthetic in infants for several years utilizing different techniques. From our earlier experience of the classic Plastibell™ technique (unpublished) where the string tie, which is packaged with the device was used, complications of Plastibell™ slippage with consequent bleeding was encountered (1). Over the last 4 years, an amended approach has been adopted as the procedure of choice. Described are details of the technical modifications and the resultant outcome.

## MATERIALS AND METHODS

A retrospective analysis of a prospectively held database containing details of infant cultural circumcisions performed under local anesthetic between 04/05 and 01/09 was undertaken. Three senior surgeons at a university affiliated tertiary pediatric institution were involved and a standard operative approach was utilized in all cases. Demographic

and outcome parameters were studied to assess the impact of the technical amendments on patient performance.

## CIRCUMCISION TECHNIQUE

The operation is performed by a surgeon and assistant standing at opposite ends of the patient who is placed across the operating table. The assistant abducts the hips and the external genitalia area is cleansed with an antiseptic solution. A standard ring block with 0.5% lignocaine in a dose of 1 mg/kg is applied to the base of the penis. Once anaesthetized, the foreskin is comprehensively freed from the underlying glans, which is calibrated with an appropriately sized Plastibell™ device (PD), Figure-1. Sizes between 1.2 and 1.7 cm were utilized.

The foreskin is returned to its anatomical position then grasped between 2 hemostatic clips to either side of the dorsal midline before the intervening foreskin is crushed and divided to a depth of 1 cm. This maneuver widens the preputial opening and facilitates placement of the PD. To prevent proximal

displacement of the internal (preputial) layer by the PD it is important for the two layers at the apex of the cut to be approximated with a suture (4/0 silk) (Figure-2). This suture is left to a 6 cm length and held on a hemostat to aid later retraction of the foreskin over the PD.

A pre-moistened PD is introduced through the widened foreskin opening until it cups the glans. The orientation of the device should be with the handles at 90 degrees to the penile frenulum to minimize injury to this structure during detachment from the ring.

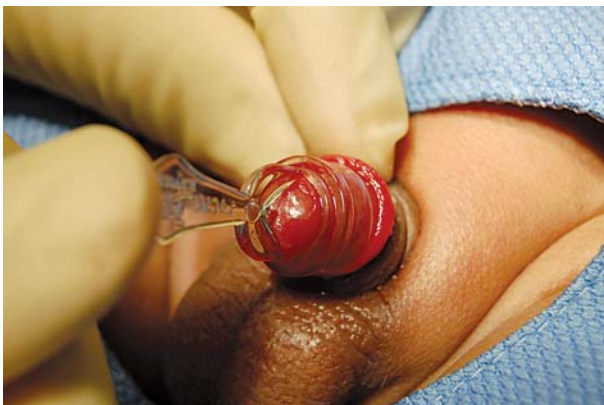The next step draws an appropriate amount of foreskin over the PD and is achieved with a bimanual manoeuvre involving forward traction on the 3 hemostats with simultaneous gentle downward pressure on the handle of the PD (Figure-3). The surgical assistant applies two sequential silk 0 ligatures around the neck of the PD taking care to avoid knot overlap.

Finally, a check confirming position and integrity of the ligatures is performed after which the foreskin is divided approximately 2 mm distal to the ring (Figure-4).

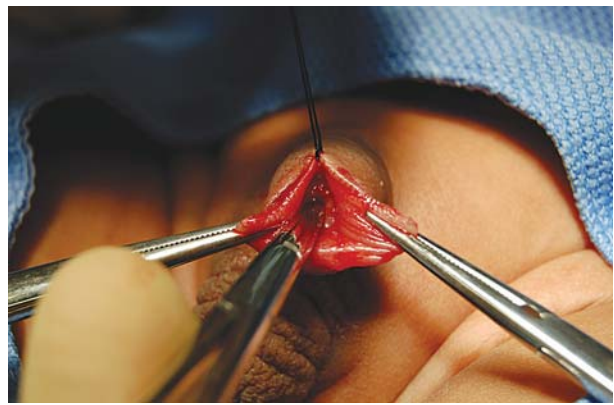
Hemostasis is checked just prior to discharge about 30 minutes later. Parents are sent home with a pack containing surgeon contact details, advice on analgesia and information on commonly encountered problems. To save on costs, routine postoperative visits are not scheduled.

## RESULTS

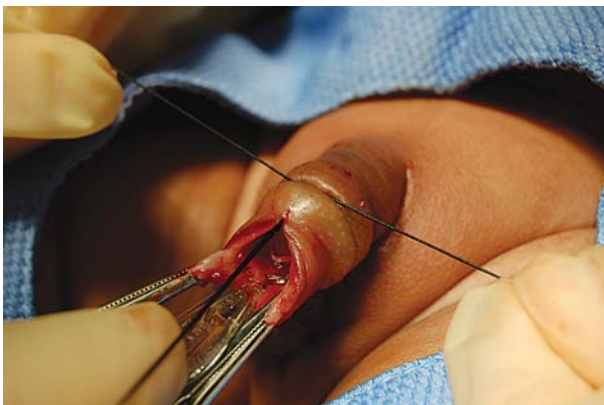
Between 04/2005 and 01/2009, 130 infants underwent cultural circumcision by the modified Plastibell™ technique. Age ranged from 4 to 359 days



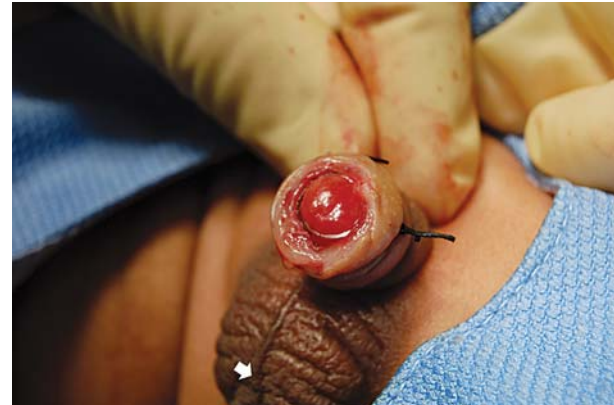**Figure 1** – Calibration of glans with Plastibell™.



**Figure 2** – Approximating internal and external layers at the apex of dorsal slit.



**Figure 3** – Ligature placement when an appropriate amount of foreskin is drawn over the Plastibell.



**Figure 4** – Following application of a double suture, the foreskin is divided 2 mm distal to the ring.

with a mean of 82.37 days. There were no instances of post circumcision bleeding or infection requiring hospitalization however, 2 cases with suspected infections were reviewed and the diagnosis excluded. Three further cases were admitted within a month of the procedure for retained PD requiring removal. Two of these were managed in the Accident and Emergency Department and one required removal under a short general anesthetic. A single case where parents were unhappy with the completeness of circumcision had a revision under a general anesthetic within a year of initial surgery.

## COMMENTS

One of the commonest complications of cultural circumcisions is bleeding and rates as high as 35% have been quoted in the literature (2). Outcomes from Plastibell™ circumcisions are reported to be better although bleeding is still a significant problem (3-6). From the authors earlier experience with the classic Plastibell™ approach bleeding was problematic and therefore a series of subtle modifications were introduced to reduce this risk. The most significant of these was substitution of the pre-packed string tie with silk 0 ligatures. Neither Plastibell™ slippage nor bleeding were encountered in the current series and we are of the opinion that silk 0 ligatures offer superior knotting and hemostatic qualities as compared to the string. Furthermore, it is likely that application of a double ligature and the avoidance of knot overlap afforded protection against Plastibell™ slippage. Although ring separation times were not specifically studied in this series, it is our opinion that the caliber of silk 0 is such that it allows for a gradual separation of the ring. This tended to occur anytime between 5 to 12 days post application allowing adequate time for sealing of the circumcision margins. It is also possible that the use of finer sutures might predispose to wound dehiscence, retraction and sepsis from premature separation.

Another potential source of bleeding with the standard Plastibell™ technique is from the inner/preputial layer at the apex of the dorsal slit especially when this is forced proximally by the PD.

This problem can be averted by a stitch applied to this point to approximate internal and external layers of foreskin. If the suture is left to adequate length, the apex of the cut can be retracted over the ring and distal to the hemostatic ligature hence excluding this as a cause for bleeding.

A less critical reason for hemorrhage is injury to the frenulum by the sharp edges of the handle of the PD when detaching from the ring. This hazard is minimized by ensuring that PD orientation is such that the handle is perpendicular to the frenulum when applying the hemostatic ligatures.

Adequate foreskin excision is fundamental to a successful circumcision and suboptimal excision will result in parental dissatisfaction and certain come back. It is often the case that too little rather than too much is taken. However, the problem can be minimized if at the time of ligature application, adequate foreskin is drawn over the PD. The technique of applying opposing pressure to the handle of the PD and the hemostats works well as the operator is able to adjust the length of foreskin to be sacrificed. Surgeons working solo may have serious difficulty with ensuring adequate circumcision as critical to this step is the application of the ligatures by a skilled assistant when instructed to do so by the operator. Rarely, despite this manoeuvre, instances of incomplete circumcision as was our experience with one case may occur. At particular risk are patients with a large amount of prepubic fat with partially recessed penises and mature judgment here is vital to a satisfactory outcome. Clearly where there is doubt on the amount of skin to be excised cases should be deferred until later in life or alternatively performance under a general anesthetic might be considered. Absolute contraindications to cultural circumcisions include; buried penis, hypospadias and epispadias.

Ring retention around the corona was the most frequent complication in this series and has been documented by others (6). We suspect that this may be due to the application of excessive tension on the foreskin during PD placement and in combination with this and contrary to the opinion of others, to be due to a selection of a smaller rather than a larger PD (7,8). Calibration with a suitably sized PD device is therefore crucial and erring on a slightly larger than

smaller device would seem sensible. The PD usually detaches within 12 days and a surgical assessment is mandatory if separation has not occurred by day 15. Retained rings can be removed under sedation by simply applying traction on the device. However, if this fails it may be necessary to divide the ring with a pair of strong scissors. Very rarely this may require a general anesthetic.

With this series, we have demonstrated that with modifications to the original Plastibell™ technique that infant circumcision can be offered with relatively few complications. The most frequent of these is post circumcision bleeding which can be reduced substantially.

## CONFLICT OF INTEREST

None declared.

## REFERENCES

1. Hollister Plastibell: Available from: <http://www.circlist.com>.
2. Williams N, Kapila L: Complications of circumcision. *Br J Surg.* 1993; 80: 1231-6.
3. Shah T, Raistrick J, Taylor I, Young M, Menebhi D, Stevens R: A circumcision service for religious reasons. *BJU Int.* 1999; 83: 807-9.
4. Manji KP: Circumcision of the young infant in a developing country using the Plastibell. *Ann Trop Paediatr.* 2000; 20: 101-4.
5. Holman JR, Lewis EL, Ringler RL: Neonatal circumcision techniques. *Am Fam Physician.* 1995; 52: 511-8, 519-20.
6. Lazarus J, Alexander A, Rode H: Circumcision complications associated with the Plastibell device. *S Afr Med J.* 2007; 97: 192-3.
7. Sørensen SM, Sørensen MR: Circumcision with the Plastibell device. A long-term follow-up. *Int Urol Nephrol.* 1988; 20: 159-66.
8. Mousavi SA, Salehifar E: Circumcision Complications Associated with the Plastibell Device and Conventional Dissection Surgery: A Trial of 586 Infants of Ages up to 12 Months. *Adv Urol.* 2008: 606123.

---

*Accepted after revision:  
February 5, 2009*

---

## Correspondence address:

Dr. Anies Mahomed  
Department of Paediatric Surgery  
Royal Alexandra Children's Hospital  
Eastern Road, Brighton  
BN2 5BE, United Kingdom  
Fax: + 1273 523-120  
E-mail: [anies.mahomed@bsuh.nhs.uk](mailto:anies.mahomed@bsuh.nhs.uk)

## EDITORIAL COMMENT

Circumcision performed by Plastibell™ method is a well-proven method, which compares well with standard open circumcision with respect to results and complications. This is an interesting paper with modifications of standard Plastibell tech-

nique. The authors should be commended of such low complication rates

The application of suture to the apex of the cut seems to be a practical technique where the inner layer has some chance of bleeding. This is a reason-

able modification to reduce bleeding complications. The author's claim for silk sutures to have superior knotting techniques and allows more secure hemostasis is probably true but should be substantiated by evidence.

I do not think the slippage of the ring was a major problem in the largest Plastibell series and though tying two silk ligatures theoretically should provide additional safety - it is probably unnecessary.

There are few important distinctions when comparing this paper with one of the largest series from Bradford - firstly the procedure was performed by nurses with consultant urologist available in Hospital in case of any problem. Secondly, the maximum age in that series was 14 weeks (the present series max age is 359 days). Penile block was used along with ring block for local anesthesia whereas only ring block was used in the present series.

***Dr. Victor Palit***

*Yorkshire Deanery*

*Royton, Oldham, Lancashire*

*United Kingdom*

*E-mail: victorpalit@yahoo.co.uk*