



# A prospective evaluation of plastibell® circumcision in older children

José Murillo Bastos Netto, José Gonçalves de Araújo Jr., Marcos Flávio de Almeida Noronha, Bruno Rezende Passos, Humberto Elias Lopes, José de Bessa Jr., André Avarese Figueiredo

*Division of Urology, Department of Surgery Federal University of Juiz de Fora (JMBN, JGA, MFAN, BRP, HEL, AAF), MG and Division of Urology, Department of Surgery State University of Feira de Santana (JB Jr), BA, Brazil*

## ABSTRACT

**Introduction and Objective:** Circumcision is one of the oldest surgical procedures and one of the most frequently performed worldwide. It can be done by many different techniques. This prospective series presents the results of Plastibell® circumcision in children older than 2 years of age, evaluating surgical duration, immediate and late complications, time for plastic device separation and factors associated with it.

**Materials and Methods:** We prospectively analyzed 119 children submitted to Plastic Device Circumcision with Plastibell® by only one surgeon from December 2009 to June 2011. In all cases the surgery was done under general anesthesia associated with dorsal penile nerve block. Before surgery length of the penis and latero-lateral diameter of the glans were measured. Surgical duration, time of Plastibell® separation and use of analgesic medication in the post-operative period were evaluated. Patients were followed on days 15, 45, 90 and 120 after surgery.

**Results:** Age at surgery varied from 2 to 12.5 ( $5.9 \pm 2.9$ ) years old. Mean surgical time was  $3.7 \pm 2.0$  minutes (1.9 to 9 minutes). Time for plastic device separation ranged from 6 to 26 days (mean:  $16 \pm 4.2$  days), being 14.8 days for children younger than 5 years of age and 17.4 days for those older than 5 years of age ( $p < 0.0001$ ). The diameter of the Plastibell® does not interfere in separations time ( $p = 0.484$ ). Late complications occurred in 32 (26.8%) subjects, being the great majority of low clinical significance, especially prepuce adhesions, edema of the mucosa and discrete hypertrophy of the scar, all resolving with clinical treatment. One patient still using diaper had meatus stenosis and in one case the Plastibell® device stayed between the glans and the prepuce and needed to be removed manually.

**Conclusions:** Circumcision using a plastic device is a safe, quick and an easy technique with low complications, that when occur are of low clinical importance and of easy resolution. The mean time for the device to fall is shorter in children under 6 years of age and it is not influenced by the diameter of the device.

## ARTICLE INFO

### Key words:

Child; Prospective Studies; Circumcision; Phimosis

**Int Braz J Urol. 2013; 39: 558-64**

Submitted for publication:  
January 30, 2013

Accepted after revision:  
July 01, 2013

## INTRODUCTION

Although in the last decades many authors have advocated the use of topical steroids

as an alternative treatment of phimosis (1-3), with success rate ranging from 67 to 90% (4,5), circumcision is still the “gold standard” treatment for phimosis, and although not always performed for

medical reasons, it is one of the most frequently performed surgery around the world (6). Circumcision is one of the oldest surgical procedures performed today and in the majority of time done in younger children.

Many techniques have been described for the treatment of phimosis and there is no consensus which procedure has better results. Besides dissection surgery and prepuceplasty, many devices have been used, such as Gomco Clamp, Mogen Clamp and plastic devices (6), and recently a novel plastic clamp have been described (7). The first two are used more often for neonates. Plastic devices although more frequently used in the first year of life can also be applied to older children, being an alternative technique for circumcision in this population. Plastibell® device has been first reported for circumcision in 1956 (8) and since then there has been a widespread of the technique with satisfactory results (9-12) although there are some reports showing severe complications with its use (13,14).

Most of the studies on Plastibell® circumcision are related to its complications. We found few reports on the time for separation of the plastic® device and none regarding its relationship to the age of the child and found no reports correlating the size of the glans and diameter of the device. Recently, Samad et al., 2010, published a series of circumcisions with Plastibell® device showing low complication rates (15).

Herein, we describe our experience with the use of Plastibell® device, demonstrating its relationship with the size of the glans and correlating the age of the child with the time for separation of the Plastibell®, and complications.

## MATERIALS AND METHODS

This is a prospective consecutive series of 119 children older than two years of age and with medical indication for circumcision, operated using a plastic device (Plastibell®), by the same surgeon at University Hospital of the Federal University of Juiz de Fora, Brazil, from December 2009 to June 2011. The study protocol was approved by the hospital ethical committee and all parents of the involved children signed an informed

consent. After evaluating the child, the indication for surgery and Kayaba's classification of the prepuce (16) were recorded.

All surgeries were performed under general anesthesia with dorsal penile block (17). After the anesthesia, the foreskin was completely retracted freeing the adhesions from the glans and the length of the penis under maximum traction and diameter of the glans were measured. Children with lateral-lateral diameter of the glans that a Plastibell® device could not be placed were not included in the study. The duration of the circumcision was recorded, initiating after the penile block and finishing after the dressing was done. In all children the frenulum was sectioned with electric cauterization.

The surgical technique applied was as follow: after sectioning the frenulum, the foreskin was pulled up and the Plastibell® device placed between the prepuce and the glans. The size of the device was chosen according to the size of the glans. A non-absorbable string was tightly tied around the device and the prepuce distally to it was excised. Dressing was made with bacitracin cream and a gauze covering it (12).

After waking from anesthesia the patients were sent home with the prescription of paracetamol to be used every 6 hours on the day of surgery and only if necessary on the following days. Parents were told to write down in a proper sheet how many times they gave the medicine each day for the first three days separately and then, if there was still need for the medication, after those three days until the first post-operative clinic visit. Follow-up was done in days 15, 45 and 90 after surgery. After Plastibell® separation all parents were oriented to do a repetitive traction of the prepuce twice a day to avoid adhesions and retraction of the surgical scar. The date of separations of the plastic device was recorded as well as the immediate and late post-operative complications.

Categorical variables were described by their absolute values and proportions, while numeric variables were described by median and interquartile range or means and standard deviation as appropriate. Correlation between quantitative variables was verified through Pearson's coefficient estimative. The unpaired t test, Mann-Whitney, ANOVA or Kruskal-Wallis tests were used to compare con-

tinuous variables while categorical variables were compared using the chi-squared or Fisher's exact test. All tests were two-sided, and p values < 0.05 were considered significant. Statistical analysis was performed using the GraphPad Prism 5.03 software. (San Diego, CA, USA).

## RESULTS

The mean age of the boys was  $5.9 \pm 2.9$  (range 2 to 12.5) years. The mean length of the penis was  $7.3 \pm 1.1$  cm (3.9 to 11 cm) and the mean lateral-lateral diameter of the glans was  $1.4 \pm 0.2$  cm (1.1 to 1.9 cm). All children with indications for circumcision were included in the study.

Surgical indications and the pattern of foreskin retraction according Kayaba classification (16) are described in the Table-1.

The mean surgical time was  $3.7 \pm 2.0$  minutes (1.9 to 9 minutes). The use of pain medication decreased along with time for the first three days after surgery. In the first day after surgery 57.1% of the boys needed at least one dose of paracetamol, on the second day, 37.8%, on the third day 24.4%. After the third post-operative day we found a little increase on the use of the pain medication with 32.6% of the patients needing at least one dosage of paracetamol.

The overall mean time for Plastibell® separation was  $16.2 \pm 4.2$  days and this time correlated with age of the children. As younger the boys, the shorter the time for the plastic device to fall off ( $r = 0.367$ ) ( $p < 0.001$ ) (Figure-1). Similarly, when divided into two groups, we observed that in those less than five years of age, the median time was three days lower than in older children, respectively, 14 [12-18] and 17 [14-20] days ( $p = 0.011$ ). In the other hand, the diameters of the plastic device were not a predictor for earlier fall ( $p = 0.484$ ) (Figure-2).

Immediate complications occurred only in 7 boys (5.9%) and were hemorrhagic in 3 patients, one of them needing to return to the operating room for review and suture of the foreskin (conversion to dissection technique). The other two had only a small hematoma that resolved with local compression. Three boys had severe edema of the prepuce after circumcision that also resolved spontaneously, and one boy had urinary retention for more than 12

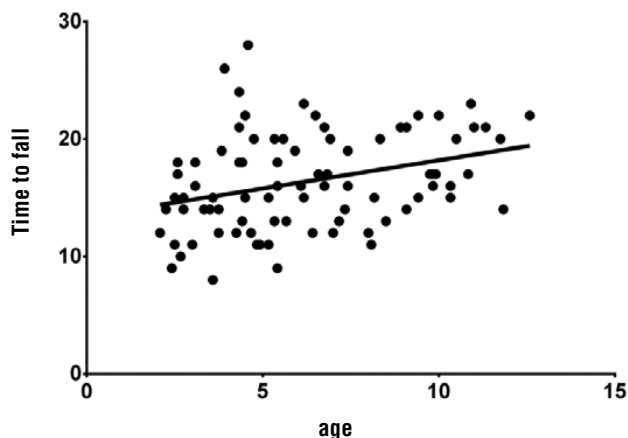
**Table 1 - Kayaba Classification and Surgical Indications.**

Kayaba Classification	Number of Boys
I	47
II	23
III	13
IV	25
V	11
Surgical Indications	
Complain of Discomfort or Pain	51
True Phimosis	41
Redundant Prepuce	39
Balanopostitis	37
Parental Desire	16
Urinary Tract Infection	15
Hydronephrosis and Reflux	4
Paraphimosis	1
Others	10

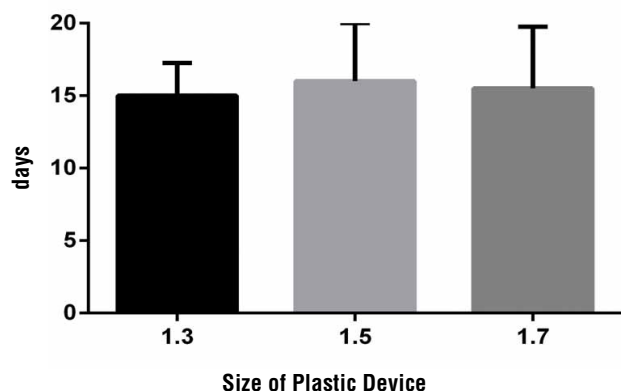
hours but ended up voiding spontaneously, with no need for bladder drainage.

Late complications occurred in 32 (26.8%) and most of these were with low clinical significance. The most frequent late complications were post-operative adhesions of the prepuce to the glans, which occurred in 18 (15.1%) boys. Four boys (3.4%) presented with a fibrotic scar forming a constrictive ring on the prepuce, which resolved with topical steroid (0.1% mometasone fuorate). One of them had paraphimosis that resolved with manual reduction. Three boys (2.5%) had severe edema of the prepuce that resolved spontaneously. There was one case of meatal stenosis in a boy still in diapers that needed meatoplasty. One boy had late bleeding due to a crust where previously was observed an adhesion.

**Figure 1 - Correlation between time for the plastic device to fall off and age of the child.**



**Figure 2 - Comparison between time to fall off and size of the plastic device. Data are shown as medians and maximum time.**



Complications related directly to the Plastibell® device occurred in only 6 (5.4%) boys. Five of them complained greater pain on the days proceeding the fall off of the plastic device and in only one case the Plastibell® device was retained and needed manual removal, which was done as an office procedure with no need for anesthesia (Table-2).

The complication rates did not correlate with the size of the devices and were similar in the two age groups ( $p = 0.782$ ) (Figure-3).

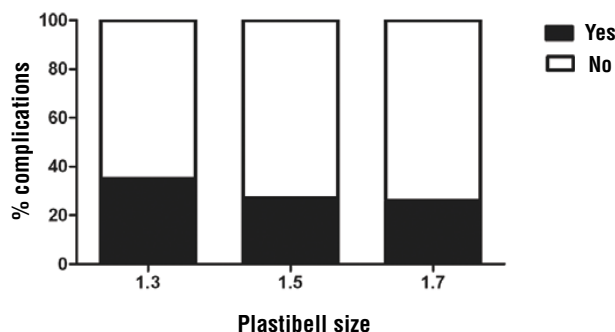
**DISCUSSION**

Routine neonatal circumcision has been previously contra indicated by the American Aca-

**Table 2 - Complications of Plastic Device Circumcision.**

Complications	Number of Patients (%)
Early Complications	7 (5.8%)
Edema	3 (2.5%)
Hematoma	2 (1.6%)
Hemorrhage	1 (0.8%)
Urinary Retention	1 (0.8%)
Late Complications	32 (26.8%)
Adhesions	18 (15.1%)
Pain for device expulsion	5 (4.2%)
Fibrotic scar (constrictive ring)	4 (3.3%)
Paraphimosis	1 (0.8%)
Edema of Prepuce	3 (2.5%)
Meatal Estenosis	1 (0.8%)
Late bleeding due to crust	1 (0.8%)
Plastibell® retention	1 (0.8%)

demy of Pediatrics (AAP) (18,19), although in recent publication they advocate that evidences indicate that the health benefits of newborn male circumcision outweigh the risks; furthermore, the benefits of newborn male circumcision justify access to this procedure for families who choose it (20). In our country, neonate circumcision is rarely indicated and most of the children are operated due to medical indications or willing of the parents, usually after they are off diapers, therefore we circumcise our children in an older age. The mean age in our group of patients was 70.86 months (5.9 years of age), corresponding to an older age compared to the majority of studies published on plastic device circumcision (9,11,15,21,22). In the study of Marwat et al., 2010 (22), 83% of the children were younger than one year of age and had fewer complications than the older children (between 1 and 5 years

**Figure 3 - Complications according to the size of Plastibell.**

old). Their overall complications were 2.5% for younger children and 21.21% for older children.

The use of plastic devices for circumcision is not accepted by many authors specially due to reports on complications associated with it (9,14,23-26). Although we present a series of only 119 boys we had no serious complications. Only 5.88% of the boys presented immediate complications, being two hematomas that resolved with local compression and two edemas of the penis and prepuce, most probably related to the anesthetic puncture for the penile block and that also resolved spontaneously. Another boy had urinary retention but ended up urinating after 12 hours and was due to fear of urinating, and not an obstruction by the device. The most severe immediate complication we observed was one boy that bled due to dislocation of the plastic device right after the surgical procedure. This boy needed to be sent back to the operating room to remove the device and conversion to a dissection circumcision suturing the prepuce. The incidence of early complications in plastic device circumcision have been reported by our group to be similar to those of dissection circumcision (12).

Marwat et al., 2010, evaluating 780 children submitted to plastic device circumcision described only 1.51% hematoma and 2.27% of bleeding in children between 1 and 5 years of age (22). In another study by Sørensen & Sørensen, 1988, hemorrhage was present in 5% while dysuria was described in up to 56% (27). A low incidence of

immediate complications was also reported by Samad et al., 2010, with 0.2% of bleeding and 0.2% of urinary retention (15). Bleeding was also the most common early complication with only 3% of children in the study by Palit et al., 2007 (21). If in our series we excluded the edemas, which were caused by the local anesthesia puncture, and urinary retention, that resolved spontaneously, we would have only 2.5% complications which were all hemorrhagic. Bleeding usually occurs due to inappropriate tying of the string around the device, predisposing to a displacement of the plastic ring with retraction of the inner prepuce, which leads to release of the compression over the prepuce vessels and consequent hemorrhage. A careful placement of the plastic device, observing the position of the inner prepuce and a tight ligature is mandatory in the prevention of these complications. Another possible early complication, urinary retention, has been reported as caused by constriction of the urethra by the device in neonates (28), which occurs by an incorrect selection of the size of the plastic device which was not the case in our child that had urinary retention.

Plastic device circumcision can be done in a very short period of time (mean:  $3.7 \pm 2.0$  minutes) with low trauma to the prepuce and penis. This surgical time is significantly shorter than dissection circumcision as we have previously demonstrated (12). Post-operative discomfort and pain were rare and the use of pain medication (paracetamol) was low in the first days after surgery and increased in the two days proceeding the fall off the device. This occurs due to the edema and inflammatory process related to necrosis and expulsion of the plastic ring.

Late complications were present in 32 children (26.8%) being most of them not of serious consequences. There was only one case of meatal stenosis needing meatoplasty and one boy who presented with paraphimosis due to a tight scar that after manual reduction and use of topical steroid had complete resolution. The most frequent late complication was adhesion of the prepuce to glans, that occurred even with all parents being oriented to retract the prepuce after the fall of the plastic device. This is related to previous adhesion, and was left untreated because it is known that it

resolves with time (29). Many authors would not report this fact as complication. If we excluded those boys who had adhesions the complication rate will decrease to 11.7% and also those who suffered from pain prior to the fall of the device the rate of late complications decreases even more to 7.5%. We have previously shown that adhesions are most common in patients submitted to circumcision with the sleeve technique than to plastic device (12).

Only 4.2% percent of the boys complain of greater pain during the process of falling off of the plastic device and we had only one Plastibell® retention, that was removed manually and as an office procedure, different from the majority of series in which retention of the device was the most frequent reported complication (11,15,21,22,26). These findings go against those contrary to the use of plastic device in older children, whose arguments are that it has a large rate of impactions, which was not found in our study with patients up to 12 years of age.

The complications described herein were not correlated with the size of the plastic device, therefore one may speculate that as long the right size of the ring is chosen the chance of complications is the same for each diameter of Plastibell®.

Observing the facts that were involved in Plastibell® separation we found that only the age of the patients were related to it. When analyzing this group of 119 boys we noted that the separation occurs in a shorter time in younger boys and as the children grow older the time for separation increases. If we divide the boys in groups by age we can observe that in those younger than 5 years of age the device would fall in a shorter time (mean of 14 days) than those older than 5 years of age (mean of 17 days), which is similar to that reported by Samad et al., 2010, who observed a period of 16.8 days for the Plastibell® separation in children older than 5 years of age and 8.7 days for children younger than 3 months of age (15). Although the size of the penis and, therefore, a small necrosis area could be a reason for a shorter period for separation of the device, we found no correlation between the size of the Plastibell® and time for separation. These observations induce to a thought that it's not the size of the plastic device

but the age of the child that has the greatest influence in this process. As younger the child, the thinner and softer is his foreskin and this may facilitate the scarring process and allows an earlier separation of the Plastibell®.

There are some limitations to our study. Although we evaluated a large series of boys (119), our series is shorter than the majority of series reported in the literature. We also did not report on the aesthetical aspects of the prepuce after surgery, however cosmetics is something personal and we had no complains from the families.

## CONCLUSIONS

Plastic device circumcision is a fast procedure with low complication rates that can be made safely in older children. The time to the plastic device fall off correlates with age and does not correlate with the size of the device.

## CONFLICT OF INTEREST

None declared.

## REFERENCES

1. Elmore JM, Baker LA, Snodgrass WT: Topical steroid therapy as an alternative to circumcision for phimosis in boys younger than 3 years. *J Urol.* 2002; 168: 1746-7; discussion 1747.
2. Pileggi Fde O, Vicente YA: Phimotic ring topical corticoid cream (0.1% mometasone furoate) treatment in children. *J Pediatr Surg.* 2007; 42: 1749-52.
3. Garcia de Freitas R, Nobre YD, Demarchi GT, Hachul M, Macedo A Jr, Srougi M, et al.: Topical treatment for phimosis: time span and other factors behind treatment effectiveness. *J Pediatr Urol.* 2006; 2: 380-5.
4. Monsour MA, Rabinovitch HH, Dean GE: Medical management of phimosis in children: our experience with topical steroids. *J Urol.* 1999; 162: 1162-4.
5. Orsola A, Caffaratti J, Garat JM: Conservative treatment of phimosis in children using a topical steroid. *Urology.* 2000; 56: 307-10.
6. Hirji H, Charlton R, Sarmah S: Male circumcision: a review of the evidence. *JMHG.* 2005; 2: 21-30.
7. Senel FM, Demirelli M, Pekcan H: Mass circumcision with a novel plastic clamp technique. *Urology.* 2011; 78: 174-9.
8. Kariher DH, Smith TW: Immediate circumcision of the newborn. *Obstet Gynecol.* 1956; 7: 50-3.

9. al-Samarrai AY, Mofiti AB, Crankson SJ, Jawad A, Haque K, al-Meshari A: A review of a Plastibell device in neonatal circumcision in 2,000 instances. *Surg Gynecol Obstet.* 1988; 167: 341-3.
10. Fraser IA, Allen MJ, Bagshaw PF, Johnstone M: A randomized trial to assess childhood circumcision with the Plastibell device compared to a conventional dissection technique. *Br J Surg.* 1981; 68: 593-5.
11. Mousavi SA, Salehifar E: Circumcision complications associated with the Plastibell device and conventional dissection surgery: a trial of 586 infants of ages up to 12 months. *Adv Urol.* 2008; 606; 123.
12. Bastos Netto JM, de Araújo JG Jr, de Almeida Noronha MF, Passos BR, de Bessa J Jr, Figueiredo AA: Prospective randomized trial comparing dissection with Plastibell® circumcision. *J Pediatr Urol.* 2010; 6: 572-7.
13. Bliss DP Jr, Healey PJ, Waldhausen JH: Necrotizing fasciitis after Plastibell circumcision. *J Pediatr.* 1997; 131: 459-62.
14. Cilento BG Jr, Holmes NM, Canning DA: Plastibell complications revisited. *Clin Pediatr (Phila).* 1999; 38: 239-42.
15. Samad A, Khanzada TW, Kumar B: Plastibell circumcision: a minor surgical procedure of major importance. *J Pediatr Urol.* 2010; 6: 28-31.
16. Kayaba H, Tamura H, Kitajima S, Fujiwara Y, Kato T, Kato T: Analysis of shape and retractability of the prepuce in 603 Japanese boys. *J Urol.* 1996; 156: 1813-5.
17. Salgado Filho MF, Gonçalves HB, Pimentel Filho LH, da Silva Rodrigues D, Palitot da Silva I, Avarose de Figueiredo A, et al.: Assessment of pain and hemodynamic response in older children undergoing circumcision: Comparison of eutectic lidocaine/prilocaine cream and dorsal penile nerve block. *J Pediatr Urol.* 2012; 13; [Epub ahead of print].
18. [No authors listed]: Circumcision policy statement. American Academy of Pediatrics. Task Force on Circumcision. *Pediatrics.* 1999; 103: 686-93.
19. American Academy of Pediatrics: Policy Statement--AAP publications retired and reaffirmed. *Pediatrics.* 2009; 124: 845.
20. American Academy of Pediatrics Task Force on Circumcision: Circumcision policy statement. *Pediatrics.* 2012; 130: 585-6.
21. Palit V, Menebhi DK, Taylor I, Young M, Elmasry Y, Shah T: A unique service in UK delivering Plastibell circumcision: review of 9-year results. *Pediatr Surg Int.* 2007; 23: 45-8.
22. Marwat AA, Hashmi ZA, Waheed D: Circumcision with Plastibell Device: An Experience with 780 Children. *Gomal J Med Sci.* 2010; 8: 30-3.
23. Johnsonbaugh RE: Complication of a circumcision performed with a plastic disposable circumcision device: long-term follow-up. *Am J Dis Child.* 1979; 133: 438.
24. Datta NS, Zinner NR: Complication from Plastibell circumcision ring. *Urology.* 1977; 9: 57-8.
25. Cilento BG Jr, Holmes NM, Canning DA: Plastibell complications revisited. *Clin Pediatr (Phila).* 1999; 38: 239-42.
26. Bode CO, Ikhisemojie S, Ademuyiwa AO: Penile injuries from proximal migration of the Plastibell circumcision ring. *J Pediatr Urol.* 2010; 6: 23-7.
27. Sörensen SM, Sörensen MR: Circumcision with the Plastibell device. A long-term follow-up. *Int Urol Nephrol.* 1988; 20: 159-66.
28. Mak YLM, Cho SC, Fai MW: Childhood circumcision: conventional dissection or Plastibell device - a prospective randomized trial". *The Hong Kong Practitioner.* 1995; 17: 101-5.
29. Ponsky LE, Ross JH, Knipper N, Kay R: Penile adhesions after neonatal circumcision. *J Urol.* 2000; 164: 495-6.

---

**Correspondence address:**

Dr. José Murillo B. Netto  
 Division of Urology,  
 Department of Surgery  
 Federal University of Juiz de Fora  
 Av. Rio Branco, 2985/605  
 Juiz de Fora, MG, 36010-012, Brazil  
 E-mail: jmbnetto@me.com