



The importance of the gubernaculum in testicular migration during the human fetal period

Luciano A. Favorito¹, Suelen F. Costa¹, Helce R. Julio-Junior¹, Francisco J. B. Sampaio¹

¹*Urogenital Research Unit, State University of Rio de Janeiro, Brazil*

ABSTRACT

Objectives: The objective of this review is to study the role of the gubernaculum in the testicular migration process during the human fetal period.

Materials and Methods: We performed a descriptive review of the literature about the role of the gubernaculum in testicular migration during the human fetal period.

Results: In the first phase of testicular migration, the gubernaculum enlarges to hold the testis near the groin and in the second phase the gubernaculum migrates across the pubic region to reach the scrotum. The proximal portion of the gubernaculum is attached to the testis and epididymis and the presence of multiple insertions in the distal gubernaculum is extremely rare. The presence of muscle and nerves in the human gubernaculum is very poor. The gubernaculum of patients with cryptorchidism has more fibrous tissue and less collagen and when the patients are submitted to hormonal treatment, the gubernaculum components alter significantly.

Conclusions: The gubernaculum presents significant structural modifications during testicular migration in human fetuses.

ARTICLE INFO

Key words:

Testicular Diseases;
Cryptorchidism; Embryology;
Fetus; Testis

Int Braz J Urol. 2014; 40: 722-9

Submitted for publication:
June 20, 2014

Accepted after revision:
October 31, 2014

INTRODUCTION

Testicular migration is a complex process of relevant importance for the comprehension of cryptorchidism. During the human fetal period, the testes migrate from the abdomen to the scrotum, traversing the abdominal wall and the inguinal canal between the 15th and the 28th week post-conception (WPC) (1-4). Several theories have been developed to explain testicular migration. The most accepted ones are: (a) the increase in the intra-abdominal pressure (5); (b) the development of the epididymis, spermatic vessels, deferent ducts and inguinal canal (6-8); (c) the stimulus originating in the genito-femoral nerve (9); (d) the hormonal stimulus originating in the placental gonadotrophin and the testosterone produced by the fetal testes (10); and (e) the

gubernaculum's development (1, 11). The gubernaculum seems to be the most important anatomical structure in the testicular migration process, by means of contraction and shortening, thus imposing traction strength on the testis (1).

The objective of this review is to study the role of the gubernaculum in the process of testicular migration during the human fetal period.

MATERIAL AND METHODS

In this study we carried out a review of the Pubmed, Embase and Scielo databases about the role of the gubernaculum in testicular migration published in the past 40 years by using the key expressions "gubernaculum testis" and "testicular migration". We found several papers in these databases and we included only papers

in English and excluded case reports, editorials and opinions of specialists.

RESULTS

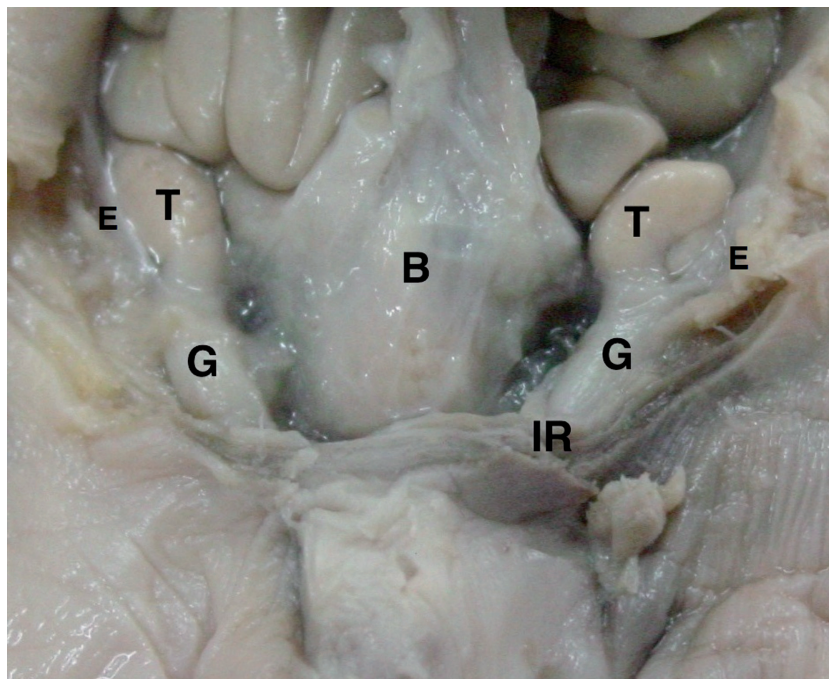
Testicular migration happens in two distinct phases: the first phase corresponds to the testicular migration from the abdomen to the internal inguinal ring, and the second phase corresponds to the transition of the testes through the inguinal canal until their definitive arrival at the scrotum (1-3). In the first phase, the gubernaculum enlarges to hold the testes near the groin, regulated by insulin-like 3 (INSL-3) (12, 13). INSL-3 is secreted by the Leydig cells and controls gubernaculum swelling via its receptor, LGR8 (leucine-rich repeat containing G protein-coupled receptor 8, also known as GREAT or relaxin receptor 2), a process resulting in thickening of the gubernaculum because of increases in water, glycosaminoglycan and hyaluronic acid content (11-14) (Figure-1).

In the second phase of testicular migration, the gubernaculum migrates across the pubic

region to reach the scrotum. The androgens stimulate growth and differentiation of the muscular part of the gubernaculum bulb, which facilitates the movement of the gubernaculum through the inguinal region by the traction resulting from this growth (6, 12, 15, 16). The gubernaculum has its own nerve supply, the genito-femoral nerve (GFN), descending on the anteromedial surface of the psoas muscle from L1-L2 segments (17). The second phase of testicular descent is regulated by androgens and calcitonin gene-related peptide (CGRP), released by the sensory nucleus of the genitofemoral nerve (GFN) (10, 18). In rodents, the active proliferation of the gubernacular tip and cremaster muscle, the muscle's rhythmic contraction, and the chemotactic gradient provided by the CGRP together result in migration of the testes into the scrotum. The importance of this mechanism is corroborated by experimental models where the sectioning of the genitofemoral nerve leads to cryptorchidism (1, 15, 18).

The moment when testicular migration begins is controversial. Backhouse (2) reported that

Figure 1 - Image of a male fetus aged 22 weeks post-conception with both testes situated in the abdomen. The abdominal wall was dissected to show the position of the testis (T) above the internal ring (IR). The figure shows the gubernaculum (G) and the bladder (B).



this process starts at about the 24th week post-conception, while Heyns (3) and Sampaio & Favorito (4) described cases where the migration process started as early as the 17th week. An aspect that various authors report is that the passage of the testis through the inguinal canal occurs very quickly (2-4). Heyns (3) found only 2.6% of the testes examined in his sample located in the inguinal canal, while Sampaio & Favorito (4), in a sample of 71 human fetuses, found 20.5% of the testes located there. Furthermore, 73.3% of these testes were in fetuses with ages between 21 and 25 WPC, indicating that in this period the migration through the inguinal canal intensifies. In the same study, all the fetuses older than 30 weeks already showed the testes in the scrotum. Other authors, however, report that the testicular migration is only completed after the 32nd week post-conception (1-3).

Gubernaculum Testis

The gubernaculum starts to develop in the human fetus during the sixth week of gestation, the same period when the germinative cells are arriving at the genital ridge (1, 19).

In the eighth week of gestation, the testis and mesonephros are linked to the posterior abdomen wall by a peritoneal fold. As the mesonephros degenerates, the portion of this fold cranial to the testis, called the diaphragmatic ligament, also degenerates, turning into the cranial portion of the gonadal mesentery. This structure is called the caudal gonadal ligament, which gives rise to the gubernaculum testis (3, 19).

Cranially, the gubernaculum approaches the mesonephric duct, while distally it approaches the inguinal region. At this moment, the future inguinal canal is still only a space in the musculature of the anterior abdominal wall, where only mesenchyme tissue exists. In this region, the genital branch of the genitofemoral nerve crosses the abdominal wall and descends to the scrotum where it will innervate the cremaster muscle, and subsequently, in the caudal to cranial direction, will provide the nerve supply to the gubernaculum (1, 2, 6, 19).

Around the eighth week of gestation, a portion of the epithelium starts a small invagination from the coelomic cavity, across from the

gubernaculum, slowly penetrating its mesenchymal substance. This invagination occurs bilaterally and is considered as the start of the vaginal process. Some authors consider this phenomenon to be “active”, involving the invasion of the gubernaculum by mesothelial cells (19), while others advocate that this phenomenon is “passive” and secondary to the increase in intra-abdominal pressure (6, 20).

The growth of the vaginal process divides the gubernaculum into three parts: (a) the main gubernaculum, which corresponds to the portion covered by the visceral layer of the peritoneum of the vaginal process; (b) the vaginal gubernaculum, which corresponds to the portion that externally surrounds the parietal portion of the vaginal process, and (c) the infra-vaginal gubernaculum, that corresponds to the caudal region of the gubernaculum, which has not been invaded by the vaginal process (19-21).

Both the gubernaculum and vaginal process change in harmony during testicular migration. The maintenance of this undifferentiated mesenchyme along the inguinal canal and scrotum is essential for the downward extension of the vaginal process to occur, during which it follows the pathway created by dilation of the gubernaculum, forming the canal through which the testis will reach the scrotum (1, 2, 19, 21).

The gubernaculum is a cylindrical structure, covered by a peritoneum on all sides except the posterior, where the testicular vessels and vas deferens pass. Macroscopically, it looks like the Wharton's jelly of the umbilical cord. Histologically, it is composed of undifferentiated cells with elongated shape, surrounded by a large quantity of extracellular material, where it is impossible to identify smooth or striated muscle cells except in its distal end and in the peripheral portion (22).

Proximal Gubernaculum

The proximal portion of the gubernaculum is adhered to the lower pole of the testis and to the epididymis. During testicular migration, these structures move through the inguinal canal as a single unit (2, 19, 23). According to Johansen & Bloom (24), in this situation the proximal gubernaculum is always adhered to the end of the vaginal

process. Jackson (25), studying 60 boys submitted to orchiopexy, found the gubernaculum adhered to the lower testicular pole in all cases, but did not mention its relationship with the epididymis.

Other studies have shown that changes in the proximal insertion of the gubernaculum are associated with epididymal anomalies and can contribute to the occurrence or cryptorchidism (26). Attah & Hutson (6), in a study with rats, demonstrated the importance of the integrity of the proximal portion of the gubernaculum for proper testicular migration. The proximal portion is important by uniting the scrotal region and serves as a guide for testicular migration. In this experiment, the authors performed transection of the proximal gubernaculum. After this procedure, the testicular migration was only completed in 26 of the 70 rats (37%), and of these animals 24 showed testicular torsion. The results of this study indicate that the proximal gubernaculum is important both to guide testicular migration and to limit the mobility of the testes and prevent testicular torsion.

Abe (27), in a study of 44 patients with cryptorchidism, found an elongated epididymis in 42.5% of the cases. Among the patients with elongated epididymis, alterations in the proximal gubernaculum were found in 73.9% of the cases. In other study of human fetuses, the authors found a low rate of epididymal anomalies (2.75%) (28).

Distal Gubernaculum

The insertion site of the gubernaculum during testicular migration is variable. Studies have shown that in the period before the end of testicular migration, the distal gubernaculum is not firmly attached to the scrotum (1, 5, 18). While the testis is located inside the abdomen, the gubernaculum is firmly attached to the inguinal canal (1,18).

The insertion site of the distal gubernaculum is one of the factors involved in testicular ectopia (29). Several papers have reported that the distal gubernaculum has six extensions: abdominal, pubopenile, femoral, perineal, contralateral scrotal and scrotal (1, 5, 29, 30). It is speculated that these branches of the distal gubernaculum exist during the beginning of fetal development and disappear during testicular migration (1, 3, 29, 30). If any of these extensions of the distal

portion persist, the individual can develop testicular ectopia (30).

Various theories have been proposed to explain testicular ectopia. The most accepted are: (a) failure of the gubernaculum to dilate the inguinal canal, enabling the testis to migrate through other pathways and not reach the scrotum (29); (b) invasion of the gubernaculum by abdominal wall fascias near the inguinal canal, blocking the passage of the testis to the scrotum and diverting it to ectopic sites (1, 30); and (c) the existence of multiple distal insertions of the gubernaculum testis, guiding the testis to the main ectopic sites (1, 2, 30).

The most accepted theory to explain testicular ectopia is the existence of multiple distal insertions of the gubernaculum. According to this theory, proposed by Lockwood in nineteenth century (29), the gubernaculum presents six distal insertion sites, in decreasing order of frequency: scrotal, interstitial (abdominal), femoral, perineal, transverse (contralateral scrotal) and pubopenile.

Multiple distal insertions of the gubernaculum exist at the beginning of fetal development and disappear during testicular migration (1, 29, 30). Pubopenile testicular ectopia is considered the rarest form of this anomaly, but in one study with fetuses, the only two cases of anomalous insertion of the gubernaculum were located in the pubopenile region (31).

Structure of the gubernaculum during testicular migration

The different parts of the gubernaculum undergo varied changes during testicular migration. The vaginal and infra-vaginal portions become proportionally longer as the testis starts to descend to the scrotum. At the same time, their diameter increases, a fact considered by Heyns (3) to be one of the most important mechanisms for dilating the inguinal canal to allow the testis to pass.

The gubernaculum's growth is divided into two phases, triggered by different hormonal stimuli (12, 18). In the first, its volume increases and in the second it decreases in size, coinciding with the complete descent of the testis (32). The cremaster muscle presents structural alterations during this period as well (33). This muscle allows rhythmic contraction to guide the testis into the scro-

tum in rats and in humans, leading to eversion of the distal portion of the gubernaculum and contributing to its migration to the scrotum (33).

The first phase is characterized by pronounced cell multiplication and accumulation of glycosaminoglycans, mainly hyaluronic acid. These substances act as hydrophilic agents and raise the quantity of water. There is also an increase in the amount of extracellular material, explaining the low cell density found at some points (34, 35). The presence of myoblasts intensifies and there are changes in the number and arrangement of the collagen fibers and alterations of the elastic system.

In the second phase, the gubernaculum shrinks, particularly its length, normally accompanied by descent of the testis. This phenomenon appears to be androgen-dependent and brings substantial degradation of the glycosaminoglycans previously accumulated in the extracellular material, with consequent dehydration of this space and condensation of the gubernaculum (22). Although no estimates are available of the degree of shortening, some authors believe this occurs along with other factors, causing the gubernaculum to convey the testis to the scrotum (3, 18).

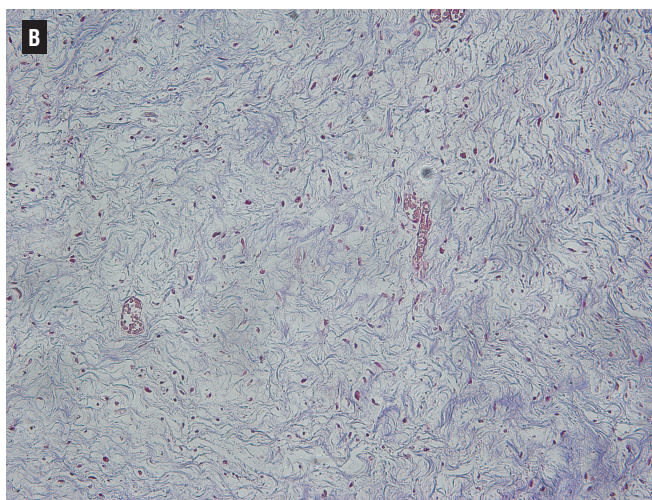
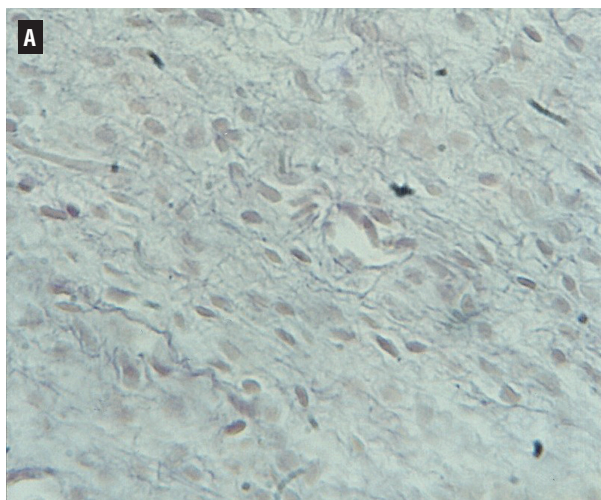
Understanding the relationship between regression of the gubernaculum and descent of the tes-

tis is vital to comprehension of how androgens control testicular migration. Studies have demonstrated an association between androgen deficiency, on the one hand, and failed regression of the gubernaculum and cryptorchidism on the other. In this situation, the gubernaculum appears to act as an obstacle to testicular descent (36, 37).

Differences between the proximal and distal portions of the gubernaculum have been reported. In one study, in fetuses aged 15 to 35 WPC the authors observed a greater number of muscle cells in the distal portion, arranged in isolated groups, while in the proximal portion the muscle tissue was present in smaller quantity and was arranged peripherally. With increasing age, the quantity of muscle tissue was found to decrease. In fetuses between 28 and 29 WPC, the authors observed a large quantity of elastic fibers and almost no muscle fibers in the entire gubernaculum (22).

In the early fetal period (15 and 16 WPC), when the testes are still in the abdomen, the connective tissue is loose and poor in collagen (Figure-2A). As the gestational time increases and the testes migrate from the abdominal cavity, the connective tissue becomes progressively denser and richer in collagen (Figure-2B). In fetuses with 28 to 29 WPC, the gubernaculum presents very dense organization of the

Figure 2 - A) Photomicrograph of a male fetus with 15 weeks post-conception with both testes situated in the abdomen. A low concentration of collagen and elastic fibers in the gubernaculum can be observed (HE, 400x). B) Photomicrograph of a male fetus with 35 weeks post-conception with both testes situated in the scrotum. A condensation of the gubernaculum with a large amount of collagen and elastic fibers can be observed. Masson's trichrome, 200x.



collagen fibers and predominance of fibroblasts, with sharp directional orientation of the fibers and cells (22). Likewise, the reticular fibers, which are arranged more loosely in the gubernaculum at the beginning of the fetal period (15 and 16 WPC) are very dense in the gubernacula of fetuses with 28 and 29 WPC (22).

Changes in the tissue components of the gubernaculum during the fetal period have been reported in various experimental studies (34, 35). The relative presence of muscle tissue appears to be one of the factors that affect the traction the gubernaculum exerts on the testis during its migration (1, 3, 6). At the beginning of the fetal period, a good deal of muscle tissue is present, but it starts to diminish with time, while the elastic tissue, which is sparse at the start, is markedly higher when the fetus reaches 25 WPC. At 28 and 29 WPC, under normal circumstances the testes have already completed their migration and are located in the scrotum. At this point of gestational age, Costa (22) observed very sparse muscle fibers and a large quantity of elastic fibers in the gubernaculum, especially in the distal portion.

The connective tissue of the gubernaculum undergoes remodeling, so that at the end of migration it has essentially become a fibrous structure, rich in collagen and elastic tissue (22). The tissue changes in the gubernaculum testis during the fetal period suggest that it plays an active role in testicular migration.

In summary, the morphological alterations of the extracellular matrix of the gubernaculum likely lead to a reduction of its length and volume. Although there is not sufficient evidence to estimate the degree of shortening, this change probably acts synergistically with other factors, causing the gubernaculum to guide the testis to the scrotum (22). Testicular descent is therefore a complex and multifactor event, and cryptorchidism should be viewed as a disease with multiple etiologies.

One of the factors involved in cryptorchidism is the failure of the gubernaculum to migrate all the way to the scrotum (38). Structural studies conducted in patients with cryptorchidism reveal significant changes in the gubernaculum's structure, with a higher quantity of fibrous tissue and lower concentration of collagen than in the fetal

gubernaculum (39). The influence of fetal androgens on the fetal gubernaculum's development is very important for the alterations of this structure, and the changes in its secretions can be one of the factors involved in cryptorchidism (40). For example, in a study analyzing the structure of the gubernaculum in patients treated with hCG, the authors observed that the gubernacular components change significantly when submitted to hormonal treatment, with an increase in the concentration of elastic and striated muscle fibers and a decrease in the volumetric density of collagen (41).

CONCLUSIONS

In the first phase of testicular migration, the gubernaculum enlarges to hold the testis near the groin and in the second phase the gubernaculum migrates across the pubic region to reach the scrotum.

The proximal portion of the gubernaculum is attached to the testis and epididymis and the presence of multiple insertions in the distal gubernaculum is extremely rare.

The presence of muscles and nerves in the human gubernaculum is very poor.

The gubernaculum presents significant structural modifications during testicular migration in human fetuses.

The gubernaculum of patients with cryptorchidism has more fibrous tissue and less collagen, and when patients are submitted to hormonal treatment, the gubernacular components change significantly.

ACKNOWLEDGMENTS

Supported by grants of CNPQ and FAPERJ.

CONFLICT OF INTEREST

None declared.

REFERENCES

1. Heyns CF, Hutson JM. Historical review of theories on testicular descent. *J Urol*. 1995;153(3 Pt 1):754-67.

2. Backhouse KM. Embryology of testicular descent and maldescent. *Urol Clin North Am.* 1982;9:315-25.
3. Heyns CF. The gubernaculum during testicular descent in the human fetus. *J Anat.* 1987;153:93-112.
4. Sampaio FJ, Favorito LA. Analysis of testicular migration during the fetal period in humans. *J Urol.* 1998;159:540-2.
5. Attah AA, Hutson JM. The role of intra-abdominal pressure in cryptorchidism. *J Urol.* 1993;150:994-6.
6. Hadziselimovi F. Mechanism of testicular descent. *Urol Res.* 1984;12:155-7.
7. Hadziselimovic F, Herzog B. The development and descent of the epididymis. *Eur J Pediatr.* 1993;152(Suppl 2):S6-9.
8. Hadziselimovic F, Kruslin E. The role of the epididymis in descensus testis and the topographical relationship between the testis and epididymis from the sixth month of pregnancy until immediately after birth. *Anat Embryol (Berl).* 1979;155:191-6.
9. Clarnette TD, Hutson JM. The genitofemoral nerve may link testicular inguinoscrotal descent with congenital inguinal hernia. *Aust N Z J Surg.* 1996;66:612-7.
10. Levard G, Laberge JM. The fate of undescended testes in patients with gastroschisis. *Eur J Pediatr Surg.* 1997;7:163-5.
11. Gill B, Kogan S. Cryptorchidism. Current concepts. *Pediatr Clin North Am.* 1997;44:1211-27.
12. Hutson JM, Southwell BR, Li R, Lie G, Ismail K, Harisis G, Chen N. The regulation of testicular descent and the effects of cryptorchidism. *Endocr Rev.* 2013;34:725-52.
13. Nation TR, Balic A, Southwell BR, Newgreen DF, Hutson JM. The hormonal control of testicular descent. *Pediatr Endocrinol Rev.* 2009;7:22-31.
14. Fu P, Layfield S, Ferraro T, Tomiyama H, Hutson J, Otvos L Jr, et al. Synthesis, conformation, receptor binding and biological activities of monobiotinylated human insulin-like peptide 3. *J Pept Res.* 2004;63:91-8.
15. Hutson JM, Hasthorpe S. Abnormalities of testicular descent. *Cell Tissue Res.* 2005;322:155-8.
16. Allnutt B, Buraundi S, Farmer P, Southwell BR, Hutson JM, Balic A. The common fetal development of the mammary fat pad and gubernaculum. *J Pediatr Surg.* 2011;46:378-83.
17. Su S, Farmer PJ, Li R, Sourial M, Buraundi S, Bodemer D, et al. Regression of the mammary branch of the genitofemoral nerve may be necessary for testicular descent in rats. *J Urol.* 2012;188(4 Suppl):1443-8.
18. Husmann DA, Levy JB. Current concepts in the pathophysiology of testicular undescend. *Urology.* 1995;46:267-76.
19. Wensing CJ. The embryology of testicular descent. *Horm Res.* 1988;30:144-52.
20. Frey HL, Rajfer J. Role of the gubernaculum and intraabdominal pressure in the process of testicular descent. *J Urol.* 1984;131:574-9.
21. Ludwig KS. The development of the caudal ligaments of the mesonephros and of the gonads: a contribution to the development of the human gubernaculum (Hunteri). *Anat Embryol (Berl).* 1993;188:571-7.
22. Costa WS, Sampaio FJ, Favorito LA, Cardoso LE. Testicular migration: remodeling of connective tissue and muscle cells in human gubernaculum testis. *J Urol.* 2002;167:2171-6.
23. Beasley SW, Hutson JM. The role of the gubernaculum in testicular descent. *J Urol.* 1988;140(5 Pt 2):1191-3.
24. Johansen TE, Blom GP. Histological studies of gubernaculum testis taken during orchiopexies. *Scand J Urol Nephrol.* 1988;22:107-8.
25. Jackson MB, Gough MH, Dudley NE. Anatomical findings at orchiopexy. *Br J Urol.* 1987;59:568-71.
26. Favorito LA, Sampaio FJ, Javaroni V, Cardoso LE, Costa WS. Proximal insertion of gubernaculum testis in normal human fetuses and in boys with cryptorchidism. *J Urol.* 2000;164(3 Pt 1):792-4.
27. Abe T, Aoyama K, Gotoh T, Akiyama T, Iwamura Y, Kumori K. Cranial attachment of the gubernaculum associated with undescended testes. *J Pediatr Surg.* 1996;31:652-5.
28. Favorito LA, Sampaio FJ. Anatomical relationships between testis and epididymis during the fetal period in humans (10-36 weeks postconception). *Eur Urol.* 1998;33:121-3.
29. Nightingale SS, Al Shareef YR, Hutson JM. Mythical 'Tails of Lockwood'. *ANZ J Surg.* 2008;78:999-1005.
30. Ramareddy RS, Alladi A, Siddappa OS. Ectopic testis in children: experience with seven cases. *J Pediatr Surg.* 2013;48:538-41.
31. Favorito LA, Klodja CAB, Costa SW, Sampaio FJ. Distal insertions of gubernaculum testis and their relationships with testicular ectopia. *J Urol.* 2003; 170:553-4.
32. Fentener van Vlissingen JM, Koch CA, Delpech B, Wensing CJ. Growth and differentiation of the gubernaculum testis during testicular descent in the pig: changes in the extracellular matrix, DNA content, and hyaluronidase, beta-glucuronidase, and beta-N-acetylglucosaminidase activities. *J Urol.* 1989;142:837-45.
33. Lie G, Hutson JM. The role of cremaster muscle in testicular descent in humans and animal models. *Pediatr Surg Int.* 2011;27:1255-65.
34. Heyns CF, Human HJ, De Klerk DP. Hyperplasia and hypertrophy of the gubernaculum during testicular descent in the fetus. *J Urol.* 1986;135:1043-7.
35. Heyns CF, Human HJ, Werely CJ, De Klerk DP. The glycosaminoglycans of the gubernaculum during testicular descent in the fetus. *J Urol.* 1990;143:612-7.
36. Elder JS, Isaacs JT, Walsh PC. Androgenic sensitivity of the gubernaculum testis: evidence for hormonal/mechanical interactions in testicular descent. *J Urol.* 1982;127:170-6.
37. Barthold JS, Kumasi-Rivers K, Upadhyay J, Shekarriz B, Imperato-Mcginley J. Testicular position in the androgen insensitivity syndrome: implications for the role of androgens in testicular descent. *J Urol.* 2000;164:497-501.

38. Hutson JM, Balic A, Nation T, Southwell B. Cryptorchidism. *Semin Pediatr Surg.* 2010;19:215-24.
39. Soito IC, Favorito LA, Costa WS, Sampaio FJ, Cardoso LE. Extracellular matrix remodeling in the human gubernaculum during fetal testicular descent and in cryptorchidic children. *World J Urol.* 2011;29:535-40.
40. Nation T, Balic A, Buraundi S, Farmer P, Newgreen D, Southwell B, et al. The antiandrogen flutamide perturbs inguinoscrotal testicular descent in the rat and suggests a link with mammary development. *J Pediatr Surg.* 2009;44:2330-4.
41. El Zoghbi CS, Favorito LA, Costa WS, Sampaio FJ. Structural analysis of gubernaculum testis in cryptorchid patients submitted to treatment with human chorionic gonadotrophin. *Int Braz J Urol.* 2007;33:223-9; discussion 230.

Correspondence address:

Luciano Alves Favorito, MD, PhD
Rua Professor Gabizo, 104/201
Tijuca, Rio de Janeiro, RJ, 20271-320, Brazil
Fax: +55 21 3872-8802
E-mail: lufavorito@yahoo.com.br