

LINEAR DENSITY ANALYSIS OF BONE REPAIR IN RATS USING DIGITAL DIRECT RADIOGRAPH

ANÁLISE DE DENSIDADE LINEAR PARA REPARO ÓSSEO EM RATOS UTILIZANDO RADIOGRAFIA DIGITAL DIRETA

Ricardo de Oliveira BOZZO¹, Rodney Garcia ROCHA², Francisco HAITER NETO³, Gisela André PAGANINI⁴, Marcelo Gusmão Paraiso CAVALCANTI⁵

1- PhD Student Department of Stomatology, Division of Dentistry Clinics, São Paulo Dental School, FOU SP. Professor Department of Dentistry Clinics, University Center Hermínio Ometto, UNIARARAS.

2- Professor Department of Stomatology, Division of Dentistry Clinics, São Paulo Dental School, FOU SP.

3- Professor Department of Radiology, Piracicaba Dental School, FOP-UNICAMP.

4- Assistant Professor, Department of Radiology, University Center Hermínio Ometto, UNIARARAS.

5- Professor Department of Stomatology, São Paulo Dental School, FOU SP

Adjunct Professor Department of Radiology, College of Medicine, The University of Iowa, USA.

Corresponding address: Dr. Marcelo Cavalcanti - Departamento de Estomatologia - Disciplina de Radiologia, FOU SP
Av. Prof. Lineu Prestes, 2227, FOU SP - Cep.: 05508-900, São Paulo, SP - Email: mgpcaval@usp.br

Received: March 1, 2004 - **Returned for modification:** May 24, 2004 - **Accepted:** July 26, 2004

ABSTRACT

The objective of this study was to assess bone density measurements for analysis of repairing fractures in rats using direct digital radiography under Dexamethasone effects. Thirty (30) young adult male Wistar rats were used, with an average weight of 200g, which were submitted to general anesthetics by ethyl ether. One rib of each animal was fractured by surgical technique. The rats were divided into 2 groups, named Control group - intraperitoneal administration of saline solution 1 hour prior to operation, and Group 1: intraperitoneal administration of Dexamethasone 0.1mg/Kg of weight 1 hour prior to operation, and two postoperative doses every 12 hours. The animals were sacrificed at 2, 3, 4, 7 and 14 days. The parts containing the hemi-thorax with the fractured rib were removed and submitted to direct digital radiography, where the linear density of the two extremities of the fracture were analyzed by the Digora System. The results showed that in the control group and in Group 1 there was a gradual and significant increase in linear density. The method used made it feasible to supply data that were statistically significant in assessing the gain in bone density during the period of time analyzed. In conclusion, direct digital radiograph is useful for bone density analysis for fracture repairing. The dose of Dexamethasone was not sufficient to alter the gain in bone density at the extremities of fracture.

Uniterms: Bone repair; Dexamethasone; Densitometry; Radiography, dental, digital.

RESUMO

O objetivo deste estudo foi analisar densidade linear utilizando o sistema de radiografia digital direta intrabucal para verificar o ganho de densidade óssea em fraturas de ratos sob os efeitos da Dexametasona. Trinta (30) ratos Wistar machos, adultos jovens de 200 g em média foram usados. Os animais foram submetidos à anestesia geral por inalação de éter etílico e 01 costela de cada animal foi fraturada através de técnica cirúrgica. Os ratos foram divididos em grupos de 03 repetições para cada grupo em cada período de tempo: Grupo Controle: administração intraperitoneal de soro fisiológico 01 hora antes da intervenção cirúrgica. Grupo 1: administração intraperitoneal de Dexametasona 0.1mg/Kg de peso 01 hora antes da intervenção e duas doses pós operatórias a cada 12 horas. Os animais foram sacrificados com 02, 03, 04, 07 e 14 dias. As partes contendo o hemi tórax da costela com a fratura foram removidas e submetidas aos raios x, onde as imagens foram analisadas através do sistema Digora. Os resultados mostraram que no grupo Controle e no Grupo 1 houve um ganho gradual na densidade linear. O método utilizado para análise forneceu dados estatisticamente significativos durante o período de tempo analisado. Assim concluímos que o método de radiografia dentária digital pode ser utilizado para análise de densidade linear de fraturas. As doses utilizadas de Dexametasona neste experimento não foram suficientes para alterar a densidade óssea no reparo de fraturas em ratos.

Unitermos: Reparo Ósseo; Dexametasona; Densitometria; Radiografia dentária digital.

INTRODUCTION

Direct digital radiographic image has appeared with the aim of achieving improvement in interpretation with a reduction in the radiation dose, allied furthermore to greater facility in obtaining radiographies, with consequent reduction in working time^{6,7,12,13,20}.

This imaging modality offers a great potential to facilitate the manner of diagnosing and treating dental pathologies^{12,19}. The accuracy of direct digital dental radiography and the assessment of alveolar bone structures for detection of bone defects were described in literature by some authors^{2,10,11,14,15}. However, advances in densitometry analysis using direct dental digital radiograph tools, with a rigorous control of experiment, were not described in the literature.

Thus, the purpose of this study was to assess the usefulness of direct digital radiographic analysis tools, for measurement of bone density for analysis of repairing fractures in rats under Dexamethasone effects.

MATERIAL AND METHODS

The study population consisted of 30 young male adult Wistar rats with an average weight of 220 grams, provided by the by Central Vivarium of the Biomedical Institute of University of São Paulo, following approval by the institutional review committee.

General anesthetics was done by inhalation of ethyl ether, each animal being placed in a closed glass vat containing cotton wool soaked with ethyl ether*. After anesthesia had been induced, it was maintained by placing a test tube containing ethyl ether close to the animal's nose, so that it would be breathed in during the surgical procedure.

The surgical area was decontaminated by application of 4.0% chlorhexidine digluconate, and it was isolated by surgical fields so that there would be no contamination from neighboring areas. An incision of approximately 3.0cm was made in the anterior lateral part of the animal's back using a scalpel with handle number 03 and blade number 15. The tissue was severed by using blunt-nosed scissors, until the animal's rib was exposed. Once exposed the rib was fractured with surgical scissors.

Suturing was done plane by plane with mono nylon 5.0* mounted thread, in order to assure adequate closing of the wound. After surgery was concluded, the region was cleaned with 4% chlorhexidine digluconate.

The animals were divided into groups according to the therapeutic prescription. The drugs were administered intraperitoneally, using insulin syringes* 1 hour before intervention, according to the following posological scheme:

Group C (control) – 15 animals: administration of saline solution IP 1 hour before surgery, in the same volume used for the corticosteroid.

Group 01 – 15 animals: administration of 03 doses of Dexamethasone (DECADRON - PRODOME - Dexamethasone disodium phosphate 1.0ml with 2.0mg) IP 0.1mg/kg of weight; 1 dose preoperatively, one dose 12 hours

after intervention and one dose 24 hours after intervention.

The animals were kept in cages and separated by groups, with food and water ad libitum. They were sacrificed by intoxication with ethyl ether to allow specimens to be obtained referring to periods of time of 2, 3, 4, 7, and 14 days.

Thereafter, the anatomic parts containing the hemi-thorax of each animal were removed. The muscular insertions were removed and each specimen was catalogued and kept individually in 10% buffered formaline.

Bone densitometry was used as the method of analysis. The Digora system (Soredex, Finland) was used, which characteristic is a sensor (phosphorous board) of size and active image area of 30mm x 40mm, similar to a periapical radiographic film. Its matrix (image size) measures 416 x 560 pixels and the size of the pixel is 71 x 71 micrometers having a resolution of 6.1p/mm. The radiographs were taken by placing the specimen on the sensor and using an X-ray machine with 50kVp and 10mA. The focus-film distance was 40cm and the exposure time used was 0.5 seconds. After exposure, the sensor was placed in the Digora scanner for reading and processing. Twenty-four seconds later, the image on the computer screen could be worked on with a linear density reading tool. From the image, the computer mouse was used for determining the line over the fracture stubs (Figure 1). The system presented the maximum and minimum density of this line, as well as the mean density in pixels, the latter being used as the result. From the intensity given by the measurements of the scale in gray color identifiable by the human eye, it was possible to measure the bone density (Figure 1). The maximum degree of density established is 256, which corresponds to white; and the minimum degree of density is zero, which corresponds to

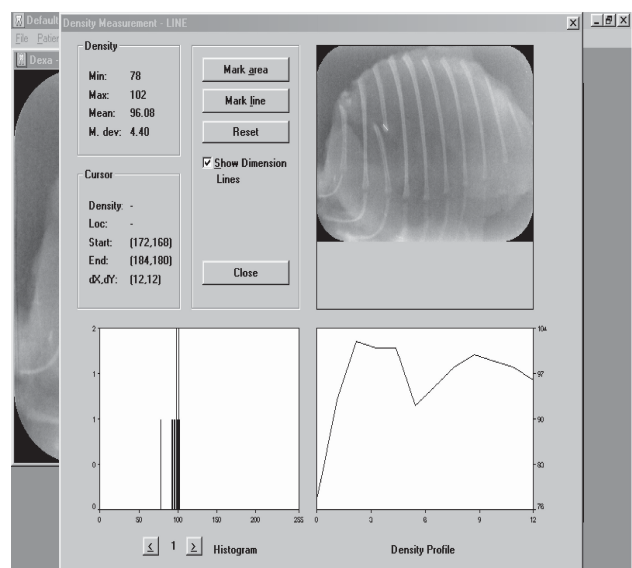


FIGURE 1- Image showing Bone Linear Density analysis by Digora System determining the line over the fracture stubs (arrow), showing the minimum (78.00), maximum (102.00), and the mean (96.80) density profiles for this image set

black. It should be considered that the different levels of gray have degrees of density that range from 01 to 255.

Statistical analysis of linear density was done considering the time of treatments:

Analysis of Variance (ANOVA) was used ($p=0.05$). The Tukey test for multiple comparisons of measurements was elected when the analysis of variance detected the significant effect of a factor. It was also defined that the factor time should be analyzed by a polynomial regression in order to check its effect on the response variable (linear density). In all calculations the SAS^β System (Statistical Analysis Systems, Institute Inc., Cary, NC, USA) was used though the GLM procedures and the SAS/LAB software 17.

RESULTS

The method made feasible to supply data that were statistically significant in assessing the gain in bone density during the period of time analyzed. Also the doses of employed Dexamethasone did not significantly alter the gain in bone density.

In the Control Group, the linear density increased as time passed, showing evidence of differences, the linear density measurements at the end of the treatment (14 days) being significantly greater than the measurements at the times of 2 and 3 days.

In Group 1, the increase in linear density is evident when one compares the specimens at 14 days to the specimens at 2, 3, and 7 days (Figure 2).

After the polynomial regression, it was possible to cross the information of the previous analyses and observe that in the linear equations for the Control Group and Group 1 gains in linear density are observed (sloping trend lines – Figure 3), showing positive association between time and gain in linear density.

DISCUSSION

There was concern about creating an experimental model that would provide conditions for checking the increase in linear density at the stubs of fractures in rats, with or without the influence of Dexamethasone, by means of Digora digital radiography program tool⁸.

The glucocorticoids act by inhibiting phospholipase A2 and also interfere in the work of cytokines at the level of the regulating genes, influencing not only the repair phase but also the bone metabolism. This influence is related to the dosage and with the time that drug is administered¹. In the present study, the posology was followed for modulating the inflammatory response made by injuries, in the case of the fracture of a rib. An analysis was made in order to verify if there was an alteration in the density of this location of the fracture, according to the dosage. The doses of Dexamethasone were extrapolated from the dose used for a

young, normal reactive adult from 70 to 80Kg, and also from doses used in protocols for reducing the inflammatory effects after surgeries including third molars⁴. Some experimental model used glucocorticoids in large quantities for long periods of time, with the intention of provoking osteoporosis, obtained a greater bone repair inhibitory effect in the group treated with Dexamethasone^{9,16}. A reduction in the serum level of calcium showed that the excess of glucocorticoids really provoked not only a decrease in bone trabeculae, but also spacing of these trabeculae^{9,16}. The inhibition of the matrix occurs after exposure of the bone to high levels of glucocorticoids^{9,16}.

Some investigators have examined the use of several

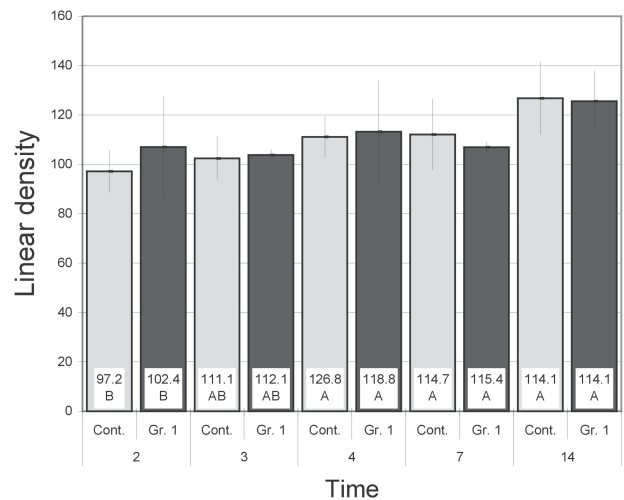


FIGURE 2- Means, Standard errors and confidence level of means of Linear Density in the different times and treatments studied. Bars with the same letter indicate means of times that do not differ

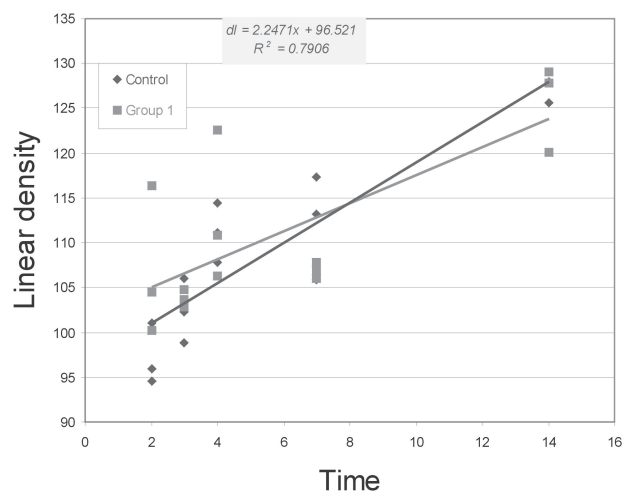


FIGURE 3- Study of the dispersion of Linear Density data as a result of time with interpolation of data by means of linear regression equations.

^β SAS Institute Inc., The SAS System Release 8.02, 1999.

sensor-based systems for direct digital radiography in attempt to improve detection of bone alterations^{2,10,11,14,15}. In our experiment, analyzing linear density in direct digital radiographs, the exposure values were predetermined in a pilot study, using a specimen that was submitted to exposure times of 0.10s, 0.16s, 0.20s, 0.25s and 0.30s with 50kVp and 60kVp. For selecting the ideal regimen, the radiographs were taken together with an aluminum stepwedge. The regimen selected was 50kVp, 10mA and 0.10s for normal radiographic films. In preliminary studies, Borg & Gröndahl⁷ (1996) determined that when digital sensors are used, the doses should be smaller than the value of 50kVp, 10mA and 0.05 seconds, thus being established as standard for the Digora system. In the present experiment, analysis of linear density by digital radiography for repairing fractures in rats was done by the sum of the linear density averages of the two stubs of the fracture. It was possible to identify the action of Dexamethasone in sufficient dosages for modulating the inflammatory response as well as the relation of time and their interaction.

With regard to figure 3, it was possible to note that the interaction of time with the treatment in Group 1 provided a gain in bone density that behaved as the Control Group, which did not receive Dexamethasone. Therefore, the factor time was the only responsible for the increase in density, and subsequently the dose of Dexamethasone was incapable of diminishing new bone formation. This process minimized concern regarding the need for medicating the patient who has to be submitted to an intervention, whose injury may have import inflammatory consequences and should be modulated for this type of drugs.

There are several methods for bone density analysis. Volumetric CT scan (Maxiscan) is used to analyze bone density around immediately loaded dental implants³. This radiological assessment showed that the mean of densitometric profile is a measurement of bone mineralization, and can be used as a new method to analyze bone density reducing the need of histological analysis by human biopsy³. This is in agreement with the present results, which demonstrated that Digora tools for density analysis were efficient in order to provide numeric values about bone density alterations. Dental computed tomography is used to analyze bone mineral density in correlation of insertion torques in oral implants⁵. Also, it is observed that non-invasive assessment of bone mineral density employed a low dose protocol and may be used to estimate expected primary stability, helping the surgeon in operation technique⁵. Using digital imaging analyses by Radiograph Workshop Software was able to analyze bone density in patients with generic osteoporosis symptoms, where the severity of changes in the mandibular cortex was significantly related to all measured mandibular bone mineral density values¹⁸. Following this discussion, we think that digital dental radiograph can in such a way be used for previous diagnosis to surgical procedures for the preservation of post-operative cases as in the present experiment.

Furthermore, the efficiency of the digital radiograph as a method for bone analysis was improved. In our opinion,

this imaging methodology can be used as an important diagnostic tool for preservation of post-operative cases not only of fractures, but also of any procedure that involves bone repair and regeneration.

CONCLUSIONS

Direct dental digital radiograph is useful for bone density analysis adding high and quick image attainment for fracture repairing.

Dexamethasone was shown to be incapable of diminishing new bone formation in the protocol used.

REFERENCES

- Alexander RE, Thronson RR. A review of perioperative corticosteroid use in dentoalveolar surgery. *Oral Surg Oral Med Oral Pathol Oral Radiol Endod* 2000;90:406-15.
- Barbat J, Messer H. Detectability of artificial periapical lesions using direct digital and conventional radiography. *J Endodont* 1998; 24:837-42
- Barone A, Covani U, Cornelini R, Gherlone E. Radiographic bone density around immediately loaded oral implants. *Clin Oral Implants Res* 2003; 14:610-5.
- Baxendale BR, Vater M, Lavery KM. Dexamethasone reduces pain and swelling following extraction of third molar teeth. *Anaesthesia* 1993; 48:961-4.
- Beer A, Gahleitner A, Holm A, Tschabitscher M, Homolka P. Correlation of insertion torques with bone mineral density from dental quantitative CT in the mandible. *Clin Oral Implants Res* 2003;14:616-20.
- Brettell DS, Ellwood R, Launders J, Horner K, Davies R. The imaging performance of a storage phosphor system for dental radiography. *Br J Radiol* 1996;69:256-61.
- Borg E, Gröndahl HG. On the dynamic range of different X-ray photon detectors in intra-oral radiography. A comparison of image quality in film, charge-coupled device and storage phosphor systems. *Dentomaxillofac Radiol* 1996; 5:82-8.
- Digora Instruction Manual, Soredex, Finland, 1994.
- Fujimoto T, Nimi A, Sawai T, Minoru U. Effects of steroid – induced osteoporosis on osteointegration of titanium implants. *Int J Oral Maxillofac Impl* 1998;13:183-9.
- Furkart AJ, Dove SB, MacDavid WD, Nummikoski P, Matteson SR. Direct digital radiography for detection of periodontal bone lesions. *Oral Surg Oral Med Oral Pathol Endod* 1992;74:654-60.
- Holtzmann DJ, Johnson WT, Southard TE, Khademi JA, Chang PJ, Rivera EM. Storage-phosphor computed radiography versus film radiography in the detection of pathologic periradicular bone loss in cadavers. *Oral Surg Oral Med Oral Pathol Oral Radiol Endod* 1998;87:90-7.
- Huda W, Rill LN, Benn DK, Pettigrew JC. Comparison of a photostimulable phosphor system with film for dental radiology. *Oral Surg Oral Med Oral Pathol Oral Radiol Endod* 1997;83:725-31.

13- Janhom A, van der Stelt PF, van Ginkel FC, Geraets WG. Effect of noise on the compressibility and diagnostic accuracy for caries detection of digital bitewing radiographs. *Dentomaxillofac Radiol* 1999; 28:6-12.

14- Kaepler G, Vogel A, Axmann-Kremer D. Intra-oral storage phosphor and conventional radiography in the assessment of alveolar bone structures. *Dentomaxillofac Radiol* 2000; 29:362-67.

15- Kullendorff B, Nilsson M, Rohlin M. Diagnostic accuracy of direct digital dental radiography for the detection periapical bone lesions *Oral Surg Oral Med Oral Pathol Oral Radiol Endod* 1996;82:344-50.

16- Sato S, Kim T, Arai T, Mauyama S, Tajima M, Utsumi N. Comparison between the effects of dexamethasone and indometacin on bone wound healing. *Jpn J Pharmacol* 1986; 42:71-8.

17- SAS Institute Inc., The SAS (Statistical Analysis Systems, Institute Inc.) System Release 8.02, 1999. Cary, NC, USA.

18- Tomaszewski T. Assessment of density and mandible bone structure in patients with generic osteoporosis symptoms. *Ann Univ Mariae Curie Skłodowska* 2002;57:329-41.

19- Vandre RH, Webber RL. Future trends in dental radiology. *Oral Surg Oral Med Oral Pathol Oral Radiol Endod* 1995; 80:471-8.

20- Velders XL, Sanderink GC, van der Stelt PF. Dose reduction of two digital sensor systems measuring file lengths. *Oral Surg Oral Med Oral Pathol Oral Radiol Endod* 1996; 81:607-12.