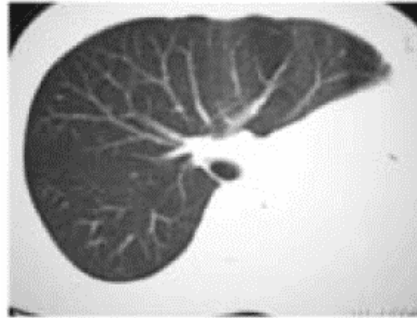
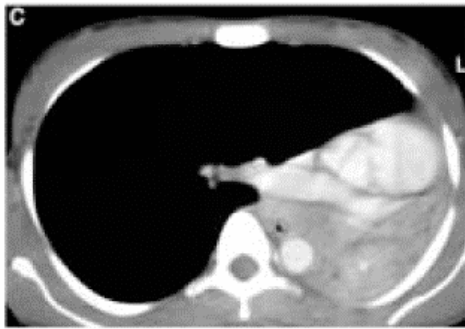
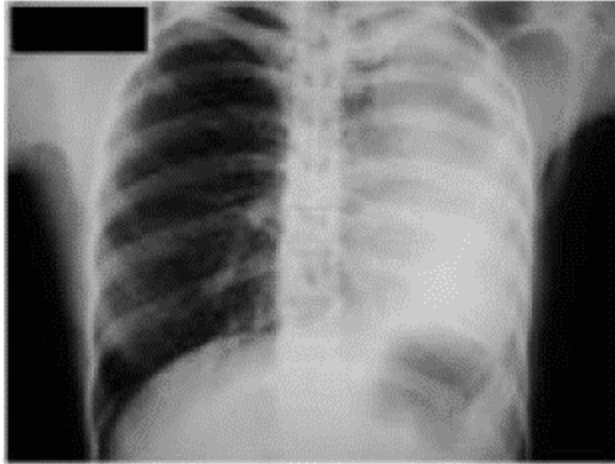


We ask: What is the diagnosis?

- **28-year-old female patient**
- **Recurrent pneumonias**



CIRO YOSHIDA JUNIOR
UNIFESP-EPM, São Paulo, SP

DANY JASINOWODOLINSKI
Centro de Medicina Diagnóstica Fleury,
São Paulo, SP

GUSTAVO DE SOUZA PORTES MEIRELLES
UNIFESP-EPM, São Paulo, SP and Centro de Medicina Diagnóstica Fleury, São
Paulo, SP

NESTOR MÜLLER
St. Paul's Hospital, Vancouver, BC, Canada