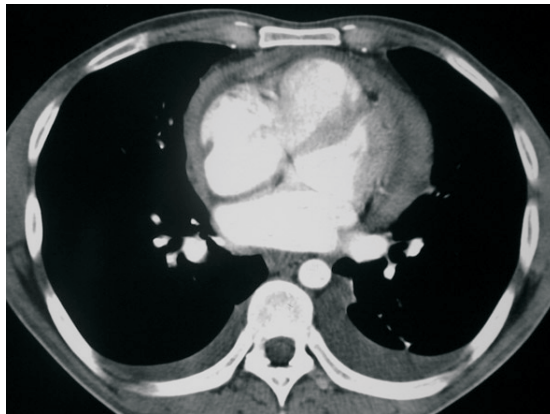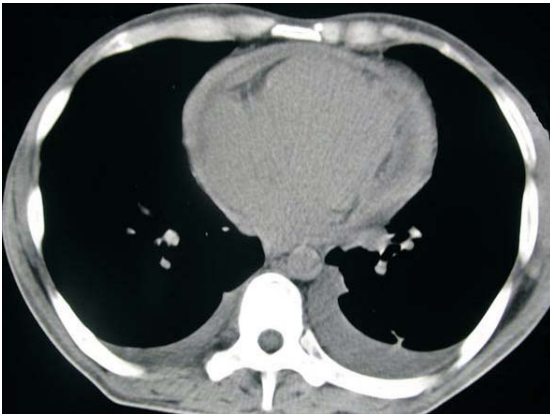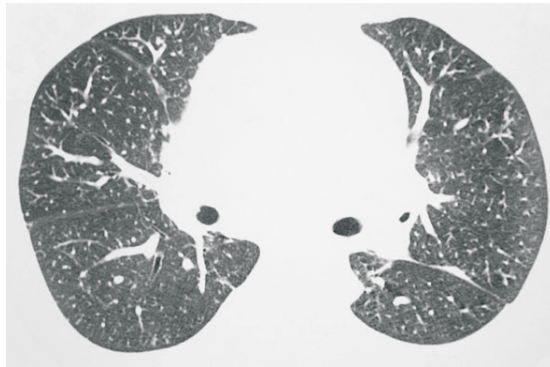
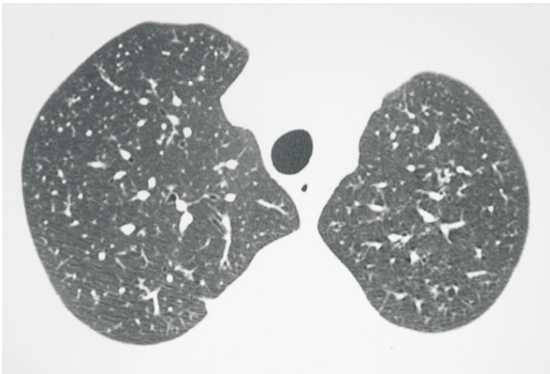


Radiological Diagnosis

We ask: What is the diagnosis?

56 year-old male
Dyspnea for two months with progressive worsening
Low-grade fever and dry cough



GUSTAVO SOBREIRA TABERNER, EDUARDO SCORTEGAGNA JÚNIOR,
C. ISABELA S. SILVA, NESTOR L. MÜLLER

Departament of Diagnostic Imaging, Universidade Federal de São Paulo, Escola Paulista de Medicina, São Paulo, SP, Brazil and the Radiology Department, Vancouver General Hospital, University of British Columbia, Vancouver, BC, Canada.

This section is intended to encourage a diagnostic approach based on clinical and radiographic findings. We invite all of our readers to participate.

Submit your diagnosis by completing the form you will find on our website (www.jornaldepneumologia.com.br) or by sending an e-mail to jpneumo@terra.com.br. Remember to include the full name of your institution. The images shown here are those that were most relevant in making the final diagnosis. In the next issue of the journal, we will publish the diagnosis for this case, along with the names of those who submitted correct responses.