

Case Reports

Mediastinal teratoma mimicking pleural effusion on chest X rays*

Miguel Angelo Martins de Castro Junior¹, Nelson Perelman Rosemberg²,
Miguel Angelo Martins de Castro³, Angela Potter de Castro⁴,
Cacio Wietzycoscki⁵, Cleiton Mespaque⁵

Abstract

Teratomas account for 8–13% of all mediastinal tumors. A 27-year-old patient presented with chest pain and dyspnea of prolonged evolution. A chest X ray revealed near total opacification of the right hemithorax, raising the suspicion of pleural effusion. On a tomography scan of the chest, a collection of heterogeneous fluid, with regular borders and 10.1 x 11.7 cm in size, was seen in the pleura of the lower two-thirds of the right hemithorax but was not encroaching upon any of the adjacent structures. Based on the hypothesis that these findings represented a benign cystic mediastinal teratoma, an exploratory thoracotomy was performed, during which such a teratoma was found and completely excised. The post-operative evolution was favorable. The atypical presentation and considerable growth of the tumor hindered the pre-operative diagnosis.

Keywords: Teratoma; Mediastinal neoplasms; Pleural effusion; Radiography, thoracic.

Introduction

Mediastinal teratomas are rare occurrences and account for 8–13% of all mediastinal tumors. Teratomas primarily occur in the anterior mediastinum and affect young adults.^(1,2) Mediastinal teratomas originate from pluripotent germ cells and comprise a wide variety of tissues originating from the three embryonic layers.^(2,3) They may contain several types of tissues, such as epithelial and muscle tissues, as well as cartilage, and even teeth. Benign teratomas usually grow slowly and are asymptomatic for long periods or present minimal symptoms, which are very often disregarded not only by the patient but also by the physician. They are frequently detected on routine chest X rays. In general, they appear as well circumscribed masses and are usually excised without much difficulty.⁽²⁻⁴⁾

Case report

A 27-year-old, previously healthy female patient, a native and resident of Taquara (located in the state of Rio Grande

do Sul, Brazil), sought treatment in her hometown due to chest pain and progressive dyspnea. A chest X ray performed in the emergency room revealed near total opacification of the right hemithorax. The patient was then submitted to an initial thoracentesis with the removal of 500 mL of purulent fluid, which raised the suspicion of pleural empyema. Based on these findings, the patient received antibiotic therapy and was referred to the Thoracic Surgery Unit of the Hospital Nossa Senhora da Conceição in the capital city of Porto Alegre. Upon admission, the patient was asymptomatic. The patient had no fever and reported having no fever in the preceding days. Since there was no radiological improvement, a computed tomography scan of the chest was performed, revealing a heterogeneous lung mass with regular borders. The mass was 10.1 x 11.7 cm in size and occupied the lower two-thirds of the right hemithorax but was not encroaching upon any of the adjacent structures (Figure 1).

*Study carried out in the Thoracic Surgery Unit, Department of Surgery, Fundação Universidade Federal de Rio Grande (FURG, Federal University of Rio Grande Foundation) Hospital Nossa Senhora da Conceição – Rio Grande (RS), Brazil.

1. Masters in Medicine from the Universidade Federal do Rio Grande do Sul (UFRGS, Federal University of Rio Grande do Sul) – Porto Alegre (RS), Brazil.

2. Full member of the Colégio Brasileiro de Cirurgiões (CBC, Brazilian College of Surgeons) – Rio de Janeiro (RJ), Brazil.

3. PhD in Medicine from the Universidade Federal de Minas Gerais (UFMG, Federal University of Minas Gerais) – Belo Horizonte (MG), Brazil.

4. Masters from the Universidade Federal do Rio Grande do Sul (UFRGS, Federal University of Rio Grande do Sul) – Porto Alegre (RS), Brazil.

5. Medical Student at the Fundação Universidade Federal de Rio Grande (FURG, Federal University of Rio Grande Foundation) – Rio Grande (RS), Brazil.

Correspondence to: Miguel Angelo Martins de Castro Junior. Rua Duque de Caxias, 585, Centro, CEP 96200-020. Rio Grande, RS, Brasil.

Phone 55 53 3231-6215. E-mail: miguelacjr@hotmail.com

Submitted 14/11/05. Accepted, after review 7/4/06.

In view of these findings, an exploratory thoracotomy was performed. An incision was made at the right lung base on the midaxillary line. The opening of the chest cavity revealed a large encapsulated lesion containing yellowish secretion. The pleural cavity was opened, and there were no signs of fluid within. Due to the characteristics of the lesion, a hypothetical diagnosis of a benign cystic mediastinal teratoma was made, and this led to the complete excision of the lesion. The origin of the cyst was the anterosuperior mediastinum, and it had grown inferolaterally to the right, compressing the lung (Figure 2). The anatomopathological examination of the sample confirmed the presence of a benign mediastinal teratoma. The post-operative evolution was favorable. The patient was asymptomatic and presented re-expansion of the right lung. Therefore, she was discharged.

Discussion

The first case of mediastinal teratoma was described in 1823, and, since then, a variety of atypical presentations of this condition have been reported.⁽⁴⁾ These tumors are often clinically manifested by their complications, the most common being the compression of the intrathoracic structures due to the tumor growth.⁽²⁾ Perforation of the pleural cavity, pericardial sac, and bronchi, as well as invasion of the lung tissue and massive hemoptysis, have also been reported, although malignancy is rare.^(2,5)

We discuss this case placing emphasis on the atypical presentation of the benign cystic mediastinal teratoma, which mimicked pleural empyema, while remaining attentive to the possibility of enhanced tumor growth, which hinders the definitive pre-operative diagnosis. In reviewing the literature, we observed that most physicians make an initial diagnosis of pleural empyema when faced with a benign cystic mediastinal teratoma of considerable volume. Although such misdiagnosis is understandable due to the similarity of the clinical and radiological characteristics, it delays the diagnosis and makes the treatment more expensive. Therefore, we realize the importance of suspecting this disease in a patient presenting a large, well-defined opacification of one hemithorax and having no history of pulmonary infection or any other condition that might predispose to

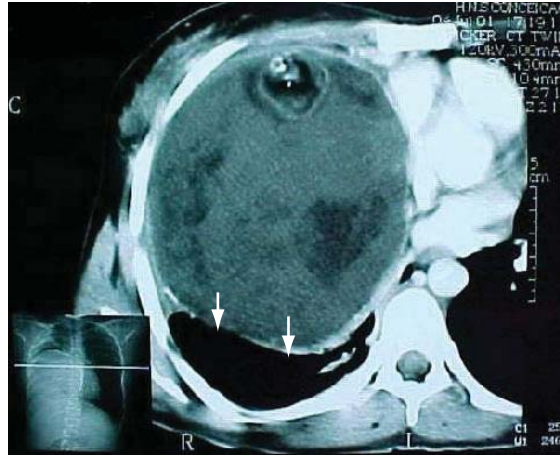


Figure 1 - Computed tomography scan of the chest revealing a heterogeneous mass with regular borders occupying a large portion of the right hemithorax, causing pulmonary collapse (arrows) and contralateral deviation of the mediastinum.

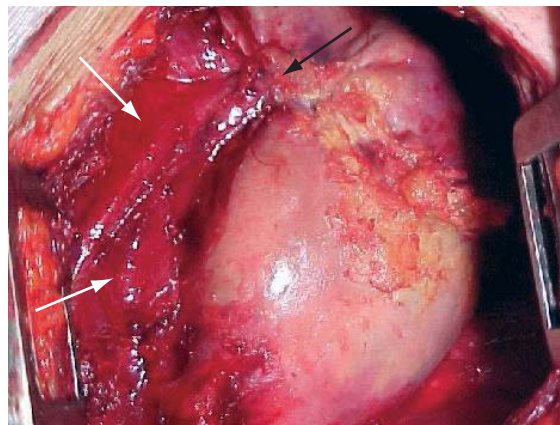


Figure 2 - Intraoperative image of the benign cystic mediastinal teratoma revealing a capsule containing a great quantity of yellowish secretion. Origin of the cyst in the anterosuperior mediastinum (black arrow) and subsequent collapse of the lung (white arrows).

pleural empyema. Surgery should be performed in order to clarify the diagnosis or whenever complications such as pulmonary atelectasis, adhesion to/compression of adjacent structures, and malignant transformation are probable. The results after surgical resection are excellent.^(1,2,6) Radiotherapy can be used to prevent local recidivism when it is not possible to fully excise the cyst.⁽⁶⁾

References

1. Verhaeghe W, Meysman M, Noppen M, Monsieur I, Lamote J, Op De Beeck B, et al. Benign cystic teratoma: an uncommon cause of anterior mediastinal mass. *Acta Clin Belg.* 1995;50(2):126-9.
2. Savas B, Kucukarslan N, Gurkok S, Özcan A, Harun H. Surgical treatment of a benign mature teratoma localised in anterosuperior mediastinum. *Internet J Thorac Cardiovasc Surg* [serial on the Internet]. 2005;7(1) [cited 2005 Nov 12]. Available from: <http://www.ispub.com/ostia/index.php?xmlFilePath=journals/ijtcvs/vol7n1/teratoma.xml>
3. Cocks CE, Kamdar HH. Mediastinal teratoma: two case reports. *East Afr Med J.* 1994;71(1):63-6.
4. Wagner RB. The history of mediastinal teratoma. *Chest Surg Clin N Am.* 2000;10(1):213-22, xi.
5. Sakamoto K, Kase M, Mo M, Kurata H. Mediastinal mature teratoma perforated into the pericardial sac: a case report. *Kyobu Geka.* 2000; 53(1):74-7. Japanese.
6. Figueiredo JCB, Alexandre Neto A, Camargo MB, Orsi FL. Teratoma de mediastino. *J Bras Med.* 1985.;49(2):31-2.