

# Case Report

## Accelerated form of interstitial pulmonary fibrosis in the native lung after single lung transplantation\*

Rogério Rufino<sup>1</sup>, Kalil Madi<sup>2</sup>, Omar Mourad<sup>3</sup>, Angelo Judice<sup>3</sup>,  
Giovanni Marsico<sup>4</sup>, Carlos Henrique Boasquevisque<sup>5</sup>

### Abstract

We report the case of a 56-year-old patient who underwent left single lung transplantation for idiopathic pulmonary fibrosis (IPF). Despite the high level of immunosuppression after the surgery, there was rapid progression to IPF in the native (right) lung as demonstrated by thoracoscopic lung biopsy. After 104 days on mechanical ventilation (MV), the patient underwent right lung transplant and was discharged from the hospital on postoperative day 26.

**Keywords:** Idiopathic pulmonary fibrosis; Lung transplantation; Case reports [publication type].

### Introduction

Idiopathic pulmonary fibrosis (IPF) is a chronic disease with progressive evolution to incapacitating respiratory failure, despite drug treatment. Other idiopathic interstitial pneumonias, such as desquamative interstitial pneumonia, acute interstitial pneumonia/diffuse alveolar damage, lymphocytic interstitial pneumonia, nonspecific interstitial pneumonia, cryptogenic organizing pneumonia, and respiratory bronchiolitis accompanied by interstitial lung disease, can present a more favorable clinical, therapeutic, and prognostic evolution than does IPF.<sup>(1)</sup> As a result, lung transplantation qualifies as one of the treatment options in IPF patients.

Lung transplantation center reports collected and published by the International Society for Heart and Lung Transplantation in 2003 cited that IPF is the second leading indication for transplantation, after pulmonary emphysema.<sup>(2)</sup>

The criteria for indication of lung transplantation are not the same for all diseases. In patients with IPF, the criteria considered are vital capacity or total lung capacity  $\leq 60\%$  of the predicted value, diffusing capacity of the lung for carbon monoxide corrected for alveolar volume  $\leq 50\%$  of the predicted value, arterial blood gas analysis with arterial oxygen tension ( $\text{PaO}_2$ )  $\leq 55$  mmHg, and alveolar-arterial oxygen gradient  $\geq 30$  mmHg at rest.<sup>(2)</sup> In the clinical criteria, the progressive increase of dyspnea indicates transplantation. However, it should be accompanied by worsening of pulmonary function or exacerbation of labor capacity scores.<sup>(1,3,4)</sup>

In clinical, tomographic and pathological terms, the case presented here demonstrates the accelerated fibrosing evolution in the native contralateral lung, characterizing a subtype of IPF, with exacerbation of the clinical profile,

\* Study carried out at the *Universidade Federal do Rio de Janeiro* – UFRJ, Federal University of Rio de Janeiro – at the *Universidade do Estado do Rio de Janeiro* – UERJ, State University of Rio de Janeiro – and at the Barra D'Or Hospital, Rio de Janeiro (RJ) Brazil.

1. Adjunct Professor of Pulmonology and Phthisiology. *Universidade do Estado do Rio de Janeiro* – UERJ, Rio de Janeiro State University – School of Medical Sciences, Rio de Janeiro, Brazil.

2. Full Professor of the Department of Pathology. *Universidade Federal do Rio de Janeiro* – UFRJ, Federal University of Rio de Janeiro – School of Medicine, Rio de Janeiro, Brazil.

3. Thoracic Surgeon at the Barra D'Or Hospital, Rio de Janeiro, Brazil.

4. PhD in Thoracic Surgery from the *Universidade Federal do Rio de Janeiro* – UFRJ, Federal University of Rio de Janeiro – Rio de Janeiro, Brazil.

5. Adjunct Professor of Thoracic Surgery in the Department of Surgery. *Universidade Federal do Rio de Janeiro* – UFRJ, Federal University of Rio de Janeiro – School of Medicine, Rio de Janeiro, Brazil.

Correspondence to: Carlos Henrique Boasquevisque. Rua Voluntários da Pátria, 389/228, Botafogo, CEP 22270-000, Rio de Janeiro, RJ, Brasil.

Tel 55 21 2527-6871. Email: cboasquevisque@uol.com.br

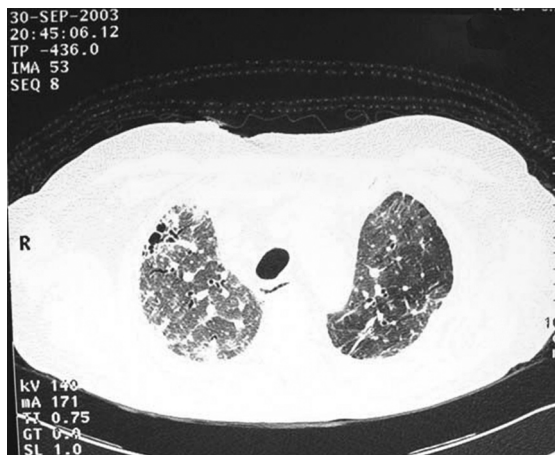Submitted: 25 September 2006. Accepted, after review: 21 November 2006.

deterioration of pulmonary function, intensification of pulmonary infiltrates, and maintenance of the histological pattern of usual interstitial pneumonia (UIP).<sup>(5)</sup>

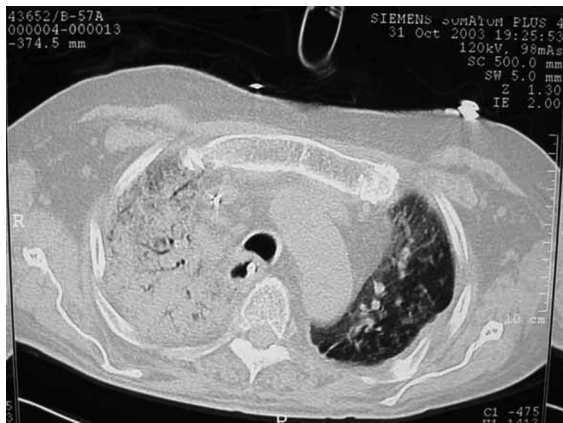## Case Report

A 56-year-old man diagnosed with IPF (using clinical, functional, tomographic and pathological criteria) five years prior, progressively evolved to dyspnea upon exertion and intense difficult-to-control cough with sparse mucoid expectoration. In the month preceding the lung transplantation, he presented hypoxemia and hypercapnia (arterial blood gas analysis with a  $\text{PaO}_2$  of 57 mmHg and arterial carbon dioxide tension of 45 mmHg at rest on room air at sea level), diffusing capacity of the lung for carbon monoxide at 29% of the predicted value, forced vital capacity of 40.8% (1.41 L), and forced expiratory volume in one second of 52.6% (1.31 L). Pulmonary perfusion scintigraphy revealed arterial flow of 76.7% for the right lung and 23.3% for the left lung. The laboratory tests for collagen-related diseases and the epidemiological investigation of known interstitial diseases were negative. During the five years of outpatient monitoring, the patient had been treated with corticosteroids (prednisone, 0.25 to 1 mg/kg/day), immunosuppressive agents (azathioprine or cyclophosphamide, 0.5 to 2 mg/kg/day), and an antifibrotic/immunomodulatory agent (interferon- $\gamma$ 1b) for four months. The transplantation was unilateral at left, corresponding to the minimal arterial perfusion and the greater intensity of the interstitial involvement according to the high-resolution computed tomography (HRCT) scan. Immediately after surgery, the patient evolved to thoracic instability due to the fracture of three ribs as a result of the osteopenic rib traction during the closure of the incision. He also presented ischemia of severe pulmonary reperfusion (arterial blood gas analysis with a  $\text{PaO}_2$ /fraction of inspired oxygen ratio = 124). The patient was tracheostomized and remained on invasive mechanical ventilation (MV) for ten days, progressively recovering from hypoxemia. The immunosuppressive regimen began with 5 mg/kg of cyclosporine (12/12 h), 0.5 mg/kg/day of prednisone, and 2 mg/kg/day of azathioprine. In addition, anti-basiliximab interleukin-2 antibody was administered on postoperative days 1 and 4. Anti-methylprednisolone antibody (1 g) was also

administered postoperatively. The patient was discharged from the intensive care unit to the semi-intensive care unit. However, on the eighth day in the semi-intensive care unit, he presented exacerbation of dyspnea, accompanied by the return of the dry cough and progressive crackling rales throughout the right hemithorax, and was therefore re-admitted to the intensive care unit. The patient was again submitted to an HRCT scan. In addition, fiberoptic bronchoscopy with bronchoalveolar lavage (BAL) was performed, together with transbronchial biopsy of the left lower lobe and the right upper lobe. All cultures tested negative, the BAL fluid presented a neutrophilic pattern, without eosinophils or hemosiderin-laden macrophages, and the histopathological analysis was inconclusive. A pulmonary arteriogram was performed, followed by thoracoscopic lung biopsy in three different regions of the right upper lobe to ensure that the disease was representative (Figures 1 and 2). The pulmonary arteriogram did not demonstrate thromboembolic disease. The biopsy culture was negative for bacteria, fungi, and mycobacteria. Herpes simplex virus and cytomegalovirus tests were also negative. Direct immunofluorescence for *Chlamydia pneumoniae*, *Legionella pneumophila*, and *Mycoplasma pneumoniae*, as well as for antigenuria for *L. pneumophila* serotype 1, were negative. The histological study of the biopsy of the



**Figure 1** - High resolution computed tomography prior to the evolution to pulmonary condensation. Patchy ground-glass pattern prevailing in the right upper lobe of the native lung, with few peripheral cysts. The left lung at one month after of the transplantation.

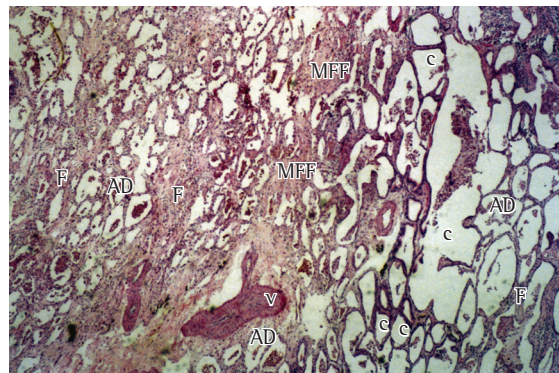


**Figure 2** - High resolution computed tomography with homogeneous condensation and presence of air bronchograms in the upper lobe. Dense condensation and bronchograms extending to the lung periphery in the right upper lobe. The aspect suggests chronic interstitial pneumonitis.

three right lung areas showed an exclusive pattern of UIP, similar to the left native lung (Figure 3). Pulse therapy with 1 g of methylprednisolone was performed for three consecutive days. The patient remained on invasive MV, then evolved to sepsis caused by infection with *Klebsiella pneumophila* and *Pseudomonas aeruginosa*. On day 141 of the hospital stay, after the patient had been on invasive MV and using noradrenaline (0.2 µg/kg/day) for 109 days, transplant of the right native lung was carried out – bilateral sequential transplantation with more than a month interval – regardless of the relative contraindications: high dose of corticosteroid (>20 mg/day), MV, and sepsis treatment.<sup>(6)</sup> On day 31 after the second transplantation, the patient was discharged from the hospital, without of the need for oxygen supplementation. Two years later, he was still in follow-up treatment with a new immunosuppressive regimen: sirolimus (2.5 mg/day), azathioprine (50 mg/day), and prednisone (5 mg/day).

## Discussion

In the 1960s, studies on idiopathic interstitial lung diseases were conducted using lung biopsy material, and various histological patterns for idiopathic interstitial pneumonias were established.<sup>(7,8)</sup> Currently, it is known that the histological pattern



**Figure 3** - Histopathology demonstrating an interstitial pulmonary fibrosis (IPF) pattern. Panoramic view of lung biopsy showing, on the right side of the photo, pulmonary fibrosis with minimum inflammatory reaction, little alveolar 'desquamation', and large cystic cavities (honeycombing). In the middle, the fibrosis is denser, with thick and deformed pulmonary septa, configuring the heterogeneous pattern of the IPF lesions. There are also vessels sclerosed by the fibrosis, and focus of fibroblastic proliferation (Hematoxylin and eosin, average increase). c: (pulmonary) cysts; F: fibrosis; MFF: myofibroblast focus; AD: alveolar desquamation; and V: Vessel.

can be similar in several diseases. For example, the UIP pattern is seen in IPF, collagen-related diseases, and asbestosis. Therefore, it is necessary to evaluate HRCT findings, pulmonary function, clinical status, and therapeutic response in conjunction in order to establish an accurate diagnosis.<sup>(1)</sup> The patient presented an UIP pattern in the lung biopsy performed five years prior to the transplantations.

The acute interstitial pneumonia/diffuse alveolar damage syndrome, or Hammam-Rich disease, presents rapid clinical progression (weeks), areas of diffuse ground-glass attenuation on the HRCT scan, and indistinguishable histological pattern of acute respiratory distress syndrome.<sup>(2,9,10)</sup> In this case, the hyaline membrane that characterizes the acute respiratory distress syndrome and the diffuse alveolar damage was not identified in the material studied.

Nosocomial pneumonia (bacterial, viral, protozoan or fungal), acute eosinophilic pneumonia, cryptogenic organizing pneumonia, and pulmonary thromboembolism were investigated using the gold standard methods (biopsy for the parenchymatous infectious and infiltrating processes and arterio-

gram for the vascular involvement), with negative results.<sup>(1,11)</sup>

Acute or chronic rejection does not occur in the native lung, and drug-induced pulmonary infiltrate induced by drugs was ruled out by the unilateral impairment.<sup>(12)</sup>

In 1993, one group of authors reported three cases of acute IPF with rapid evolution to acute respiratory insufficiency.<sup>(5)</sup> The BAL fluid cellularity findings demonstrated neutrophilia, and the histology findings revealed a UIP pattern without hyaline membranes. All three patients received pulse therapy with methylprednisolone (1 g) for three consecutive days, evolving to progressive clinical improvement. In 1993,<sup>(13)</sup> another group of authors described an IPF variant in two patients who rapidly evolved to acute respiratory failure, which was designated noninfectious exacerbation or IPF acceleration. In 2002,<sup>(14)</sup> another case of IPF with rapid evolution to death, with the same characteristics, was described. In both cases, treatment with high doses of corticosteroids did not lead to therapeutic success.

Another group of authors reported that the rapid deterioration of IPF (or IPF accelerated phase) might be caused by unknown factors, and that this diagnosis should be made by ruling out the identifiable causes.<sup>(15)</sup>

In a randomized, double-blind study to evaluate the use of interferon- $\gamma$  1b in IPF, another group of authors described a subtype of IPF, designated the accelerated form, which is characterized by the rapid progression of dyspnea (less than a month), recent opacities with diffuse distribution on HRCT scans, accentuation of hypoxemia, and rapid evolution to acute respiratory insufficiency, in the absence of infection and other alternative diagnoses. In addition, the authors stated that this syndrome might be responsible for approximately 40% of the deaths occurring in IPF patients.<sup>(16)</sup>

According to data obtained from the International Society for Heart and Lung Transplantation,<sup>(2)</sup> more than 50% of the transplantations for IPF in 2006 were unilateral. Since unilateral transplantation involves directing ventilation and perfusion preferentially to the graft, IPF is an ideal disease model for this type of transplantation.<sup>(17)</sup> However, the native lung is a potential source of complications, including native lung 'cirrhosis' (chronic interstitial pneumonitis), which has yet to be reported in the literature.

The radiological imaging demonstrated condensation in the middle, upper, and lower right lobes, and the established diagnosis was IPF exacerbation in the native lung, mainly characterized by the UIP histological aspect (nonuniform and multifocal infiltrate, with inflammatory and fibrous thickening of the alveolar interstitium, pulmonary cysts, peribronchiolar fibrosis, alveolar hyperplasia, and absence of hyaline membranes), and the absence of microbial increase in lung tissues and cardiovascular decompensation. It is known that, in IPF, the lung becomes progressively collapsed, which can simulate images of pulmonary condensation. The accelerated variant of IPF has recently been described and should have its diagnosis characterized by ruling out other causes of exacerbation. The literature mentions, in unilateral lung transplantation, chronic progression of IPF in the native lung. However, there have been no reports of acute progression. This is the first case described in the national literature as IPF in its accelerated phase.

## Acknowledgement

The authors would like to thank Dr. Roberto José de Lima and Dr. Margareth Pretti Dalcolmo, as well as the entire postoperative ICU team of the Barra D'Or Hospital.

## References

1. American Thoracic Society; European Respiratory Society. American Thoracic Society/European Respiratory Society International Multidisciplinary Consensus Classification of the Idiopathic Interstitial Pneumonias. This joint statement of the American Thoracic Society (ATS), and the European Respiratory Society (ERS) was adopted by the ATS board of directors, June 2001 and by the ERS Executive Committee, June 2001. *Am J Respir Crit Care Med.* 2002;165(2):277-304.
2. Trulock EP, Edwards LB, Taylor DO, Boucek MM, Keck BM, Hertz MI, et al. Registry of the International Society for Heart and Lung Transplantation: twenty-third official adult lung and heart-lung transplantation report--2006. *J Heart Lung Transplant.* 2006;25(8):880-92.
3. American Thoracic Society. Idiopathic pulmonary fibrosis: diagnosis and treatment. International consensus statement. American Thoracic Society (ATS), and the European Respiratory Society (ERS). *Am J Respir Crit Care Med.* 2000;161(2 Pt 1):646-64.
4. Rufino R, Siqueira HR, Chauvet PR. Teste de função na fibrose pulmonar idiopática. In: Rufino R, Madi K, editors. *Fibrose Pulmonar Idiopática.* Rio de Janeiro: Revinter; 2005. p. 51-64.
5. Kondoh Y, Taniguchi H, Kawabata Y, Yokoi T, Suzuki K, Takagi K. Acute exacerbation in idiopathic pulmonary

- fibrosis. Analysis of clinical and pathologic findings in three cases. *Chest*. 1993;103(6):1808-12.
6. Glanville AR, Estenne M. Indications, patient selection and timing of referral for lung transplantations. In: Boe J, Estenne M, Weder W editors. *Lung Transplantation*. European Respiratory Monograph. London: European Respiratory Society, 2003; p. 1.
  7. Liebow AA. New concepts and entities in pulmonary disease. In: Liebow AA editor. *The Lung*. Baltimore: Williams and Wilkins; 1968. p. 344.
  8. Scadding JG, Hinson KF. Diffuse fibrosing alveolitis (diffuse interstitial fibrosis of the lungs). Correlation of histology at biopsy with prognosis. *Thorax*. 1967;22(4):291-304.
  9. Katzenstein AL, Myers JL, Mazur MT. Acute interstitial pneumonia. A clinicopathologic, ultrastructural, and cell kinetic study. *Am J Surg Pathol*. 1986;10(4):256-67.
  10. Bouros D, Nicholson AC, Polychronopoulos V, du Bois RM. Acute interstitial pneumonia. *Eur Respir J*. 2000;15(2):412-8.
  11. Nagai S, Kitaichi M, Itoh H, Nishimura K, Izumi T, Colby TV. Idiopathic nonspecific interstitial pneumonia/fibrosis: comparison with idiopathic pulmonary fibrosis and BOOP. *Eur Respir J*. 1998;12(5):1010-9.
  12. Camus P, Bonniaud P, Fanton A, Camus C, Baudaun N, Foucher P. Drug-induced and iatrogenic infiltrative lung disease. *Clin Chest Med*. 2004;25(3):479-519, vi.
  13. Akira M. Computed tomography and pathologic findings in fulminant forms of idiopathic interstitial pneumonia. *J Thorac Imaging*. 1999;14(2):76-84.
  14. Gong MN, Mark EJ. Case records of the Massachusetts General Hospital. Weekly clinicopathological exercises. Case 40-2002. A 56-year-old man with rapidly worsening dyspnea. *N Engl J Med*. 2002;347(26):2149-57.
  15. Kim DS, Collard HR, King TE Jr. Classification and natural history of the idiopathic interstitial pneumonias. *Proc Am Thorac Soc*. 2006;3(4):285-92.
  16. Martinez FJ, Safrin S, Weycker D, Starke KM, Bradford WZ, King TE Jr, et al. The clinical course of patients with idiopathic pulmonary fibrosis. *Ann Intern Med*. 2005;142(12 Pt 1):963-7.
  17. Meyers BF, Lynch JP, Trulock EP, Guthrie T, Cooper JD, Patterson GA. Single versus bilateral lung transplantation for idiopathic pulmonary fibrosis: a ten-year institutional experience. *J Thorac Cardiovasc Surg*. 2000;120(1):99-107.