

# Case Report

## Idiopathic pulmonary hemosiderosis treated with azathioprine in a child\*

Clemax Couto Sant'Anna<sup>1</sup>, Angélica Almada Horta<sup>2</sup>, Monica T Tura<sup>3</sup>,  
Maria de Fatima Bazhuni Pombo March<sup>4</sup>, Sidnei Ferreira<sup>5</sup>,  
Rafaela Baroni Aurilio<sup>6</sup>, Débora Brandão Vieira<sup>6</sup>

### Abstract

Idiopathic pulmonary hemosiderosis (IPH), the main cause of pulmonary hemosiderosis in children, is characterized by intermittent alveolar bleeding and hemosiderin-laden macrophages in sputum and in gastric lavage. The treatment is based on corticosteroids and cytotoxic drugs, under special conditions. We describe the case of a 7-year-old girl with IPH who achieved partial clinical remission with high doses of corticosteroids. However, the treatment had to be discontinued because the patient developed Cushing's syndrome. Treatment was started with an azathioprine-corticosteroid combination and then changed to azathioprine alone, which was maintained for four years, with excellent results.

**Keywords:** Hemosiderosis; Azathioprine; Hemorrhage; Case reports [publication type].

### Introduction

In most cases, idiopathic pulmonary hemosiderosis (IPH) manifests as iron-deficiency anemia, although it can also be characterized by hemolytic anemia, hemoptysis and diffuse pulmonary infiltrates, provided that other causes of intrapulmonary bleeding are ruled out. The etiology of this disease is unclear, and various authors argue that it is immunological in origin.<sup>(1-3)</sup>

The definitive diagnosis of IPH is made based upon the typical clinical and radiological profile, accompanied by the

identification of hemosiderin-laden macrophages in sputum or in gastric lavage.<sup>(2,4)</sup>

From the time of diagnosis, the use of corticosteroids in high doses (1-2 mg/kg/day) is indicated. Many patients present relapse and require prolonged corticosteroid treatment. Immunosuppressants such as azathioprine, cyclophosphamide and chloroquine, generally prescribed in conjunction with the lowest doses of corticosteroids, are indicated in patients presenting unfavorable evolution

\* Study carried out at the Martagão Gesteira Pediatrics Institute of the *Universidade Federal do Rio de Janeiro* – UFRJ, Federal University of Rio de Janeiro – Rio de Janeiro (RJ) Brazil.

1. Associate Professor. *Universidade Federal do Rio de Janeiro* – UFRJ, Federal University of Rio de Janeiro – School of Medicine, Rio de Janeiro (RJ) Brazil.

2. Pediatric Pulmonologist. *Universidade Federal do Rio de Janeiro* – UFRJ, Federal University of Rio de Janeiro – Rio de Janeiro (RJ) Brazil.

3. Resident Doctor. Martagão Gesteira Pediatrics Institute of the *Universidade Federal do Rio de Janeiro* – UFRJ, Federal University of Rio de Janeiro – Rio de Janeiro (RJ) Brazil.

4. Adjunct Professor. *Universidade Federal do Rio de Janeiro* – UFRJ, Federal University of Rio de Janeiro – Rio de Janeiro (RJ) Brazil.

5. Assistant Professor. *Universidade Federal do Rio de Janeiro* – UFRJ, Federal University of Rio de Janeiro – Rio de Janeiro (RJ) Brazil.

6. Graduate student in Pediatric Pulmonology. *Universidade Federal do Rio de Janeiro* – UFRJ, Federal University of Rio de Janeiro – Rio de Janeiro (RJ) Brazil.

Correspondence to: Clemax Couto Sant'Anna, Rua Sá Ferreira, 159, apto. 402, Copacabana, CEP 22071-100, Rio de Janeiro, RJ, Brasil.

Tel 55 21 2268-8561. Fax 55 21 2590-4891. E-mail: clemax@vetor.com.br

Submitted: 27 September 2005. Accepted, after review: 24 October 2006.

under treatment with corticosteroids in isolation, or when such treatment is contra-indicated.<sup>(1,2,5)</sup>

In patients with IPH, azathioprine is typically combined with corticosteroids in order to reduce the dose of the latter and thus avoid the occurrence of undesirable side effects.<sup>(2,6-10)</sup>

The present case describes the long-term treatment of IPH with azathioprine alone, a drug whose use in children has been little reported in literature.

## Case report

A seven-year-old mulatto female patient sought treatment in the emergency room reporting hematemesis for a week. Examinations at profile onset showed a hematocrit of 30% and a hemoglobin level of 8 mg/dL. The patient reported productive cough for a month and sporadic high fever for 15 days.

In the past two years the patient had had five bouts of pneumonia, for which she had been treated at an outpatient clinic, and had been hospitalized with pneumonia and anemia three months prior. The patient reported no history of asthma or of having had contact with tuberculosis.

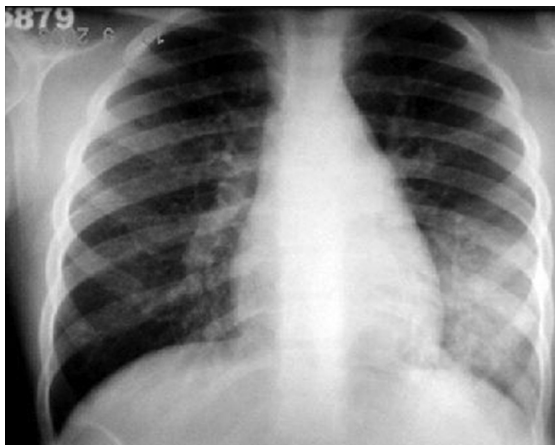
The physical examination revealed satisfactory general health status, although the patient was pale and had lost weight. In addition, she presented tachycardia, mild jaundice, and mild tachypnea.

Pulmonary auscultation revealed bilaterally reduced breath sounds, together with diffuse fine rales, predominantly in the right hemithorax base. The patient also presented moderate hepatosplenomegaly.

Laboratory tests performed at admission revealed the following: hemoglobin: 5.9 g/dL; hematocrit: 19.2%; platelets: 228,000 mm<sup>3</sup>; leukocytes: 10,200 mm<sup>3</sup>; differentials: (0/1/0/1/5/71/20/2); reticulocytes: 9.1%; total bilirubin: 4.5 mg/dL (direct: 1.3 mg/dL; indirect: 3.2 mg/dL) and lactate dehydrogenase: 221 IU/L.

Chest X-ray revealed diffuse reticular nodular infiltrates with areas of confluence on the left base, mimicking acute pneumonia (Figure 1).

Treatment was started with an oxacillin-azathioprine combination. On the following day, the disease was still severe, and the hematological parameters had worsened (hematocrit: 14%, hemoglobin: 4.2 mg/dL), despite the blood transfusion of the previous day. Testing with cold agglutinins revealed a titer of 1:32, suggesting a diagnosis of



**Figure 1** - Chest X-ray revealing diffuse reticular nodular infiltrates with areas of confluence in the left base.

autoimmune hemolytic anemia. Therefore, pulse therapy with methylprednisolone was started. The patient was discharged after a week, with significant improvement in her clinical and radiological profile, as well as recovery from anemia. The diagnosis of IPH was established one month later, when she was again hospitalized with similar clinical and radiological findings. At that time, she required an emergency blood transfusion. Gastric lavage revealed abundant hemosiderin-laden macrophages, which confirmed the diagnosis. Testing for auto-antibodies revealed anti-extractable nuclear antigen, anti-Ro, anti-La, anti-RNP, anti-Sm and negative antineutrophil cytoplasmic antibodies, as well as positive antinuclear factor with a low titer (1:40), which became negative four months later.

Treatment was started with 2 mg/kg/day of oral prednisone, and the clinical response was excellent. Attempts to reduce the dose failed, doses <1 mg/kg/day leading to clinical and radiological decompensation. The patient evolved to severe Cushing's syndrome and, after ten months of therapy, treatment was started with azathioprine (2 mg/kg/day) as a corticosteroid-sparing agent. Two months after the treatment with azathioprine was initiated, the corticosteroid was slowly reduced and was completely discontinued by month six. Azathioprine in isolation was maintained.

During the follow-up period, the patient presented lower airway obstruction and wheezing, with or without exacerbation of the disease (although often aggravated by it) and an excellent

response to corticosteroid treatment (800 µg/day of inhaled budesonide), which was initiated three months before the treatment with azathioprine was started.

During the second year of treatment with azathioprine, the patient presented radiological worsening, with cough and mild hemoptysis, on three occasions. However, she did not require corticosteroids or hospitalization, although it was necessary to increase the dose of azathioprine to 5 mg/kg/day. The clinical response was excellent, and the diffusing capacity of the lung for carbon monoxide, tested at the end of the second year of treatment with azathioprine, was within the range of normality. At the time of this writing, after an uneventful four-year follow-up period, the patient was still using the drug.

## Discussion

Pulmonary infiltrate accompanied by acute anemia suggests IPH. Hemolytic anemia, with a positive result on the direct Coombs test, can also occur in IPH, suggesting an immunological origin and often delaying diagnosis. In this patient, due to the confusion with pulmonary infection complicated by hemolysis, the initial diagnosis was infection with *Mycoplasma pneumoniae*.<sup>(2)</sup> The testing of cow milk protein antibodies, to rule out allergy to such milk, which is one of the etiologies of hemosiderosis,<sup>(11)</sup> and laboratory confirmation of Cushing's syndrome were not possible in the present case, due to difficulties encountered in the hospital laboratory at the time. However, over the course of the four-year follow-up evaluation of the patient, these diagnoses were ruled out, as were collagenosis and vasculitis.

Corticosteroids have a favorable effect in acute episodes of alveolar hemorrhage, although there have been few studies showing that, in patients with IPH, they are protective against recurrence or evolution to pulmonary fibrosis.<sup>(1,2,6,7,11)</sup> In the present case, the corticosteroid treatment during exacerbations was beneficial, which initially led us to maintain the treatment with high doses of corticosteroid (1-1.5 mg/kg/day). However, the alternative treatment with azathioprine, initiated after the severe Cushing's syndrome that the patient presented under corticosteroid treatment, was the determining factor in maintaining symptom control and later allowed us to discontinue the systemic

corticosteroid. In addition, the drug did not cause any adverse effects in the patient, which ratifies the idea that it is well tolerated in children.<sup>(10)</sup> Since the course of the disease, to a certain extent, does not depend on maintenance therapy, it is difficult to understand the true role of the immunosuppressant treatment.<sup>(2,4,7)</sup> Rarely do immunosuppressants, as second-line drugs, allow the control of the disease and the complete discontinuation of the corticosteroid treatment, as in our case.<sup>(1)</sup>

Inhaled corticosteroids, such as budesonide or flunisolide, have been used in IPH as systemic corticosteroid-sparing agents, due to the need for prolonged corticosteroid treatment for the remission of the disease, with varying results.<sup>(7,12-14)</sup> In the case presented here, the inhaled corticosteroid therapy, initiated in the sixth month of treatment, was not carried out with this intention. Rather, it was aimed at controlling the symptoms suggestive of bronchial hyperreactivity.

The great variety of clinical presentations of IPH, the intermittent nature of the disease and the lack of knowledge regarding the mechanisms involved in its pathogenesis are the greatest challenges we face when trying to confirm the efficacy of the various treatments available: treatment with immunosuppressant agents; corticosteroid therapy; intravenous administration of immunoglobulin; and plasmapheresis. Data regarding these treatments are limited to those provided in case reports. However, in recent decades, IPH patient survival has increased, which has been attributed to the wider use of immunosuppressants and to longer treatment duration.<sup>(1,6,7,9,11)</sup>

## References

1. Le Clainche L, Le Bourgeois M, Fauroux B, Foreza N, Dommergues JP, Desbois JC, et al. Long-term outcome of idiopathic pulmonary hemosiderosis in children. *Medicine (Baltimore)*. 2000;79(5):318-26.
2. Yao TC, Hung IJ, Wong KS, Huang JL, Niu CK. Idiopathic pulmonary haemosiderosis: an Oriental experience. *J Paediatr Child Health*. 2003;39(1):27-30.
3. Blanco A, Solis P, Gomez S, Valbuena C, Telleria JJ. Antineutrophil cytoplasmic antibodies (ANCA) in idiopathic pulmonary hemosiderosis. *Pediatr Allergy Immunol*. 1994;5(4):235-9.
4. Ferrari GF, Fioretto JR, Alves AFR, Brandão GS. Idiopathic pulmonary hemosiderosis: a case report. *J Pediatr (Rio J)*. 2000;76(2):149-52.
5. Meral A, Günay U, Küçükerođan A, Canitez Y, Ozuysal S. Chloroquine in idiopathic pulmonary hemosiderosis. A case report. *Turk J Pediatr*. 1997;39(1):111-5.

6. Rossi GA, Balzano E, Battistini E, Oddera S, Marchese P, Acquila M, et al. Long-term prednisone and azathioprine treatment of a patient with idiopathic pulmonary hemosiderosis. *Pediatr Pulmonol.* 1992;13(3):176-80.
7. Rubilar LO, Maggiolo JM, Girardi GB, González RV. Hemosiderosis pulmonar idiopática: Evolución de 5 niños. *Rev Chil Pediatr.* 2003;74(2):186-92.
8. Vieira SE, Osmo AA, Lotufo JPB, Gilio AE. Hemossiderose pulmonar idiopática tratada com ciclofosfamida e prednisona. *J. Pediatr (Rio de J.).* 1996;72(6):422-6.
9. Castañeda-Ramos AS, Munguía RM, Flores MAE, Àvalos LL, Calvo VV, López JJT, et al. Hemossiderosis pulmonar idiopática. *Bol Méd Hosp Infant Mex,* 2001;58(6):615-26.
10. Airaghi L, Ciceri L, Giannini S, Ferrero S, Meroni PL, Tedeschi A. Idiopathic pulmonary hemosiderosis in an adult. Favourable response to azathioprine. *Monaldi Arch Chest Dis.* 2001;56(3):211-3.
11. Nuesslein TG, Teig N, Rieger CH. Pulmonary haemosiderosis in infants and children. *Paediatr Respir Rev.* 2006;7(1):45-8.
12. Paul G, Bhatnagar SK, al Maskary S, Kuruvilla S, Kurien S. Idiopathic pulmonary haemosiderosis. *J Trop Pediatr.* 2000;46(4):243-5.
13. Elinder G. Budesonide inhalation to treat idiopathic pulmonary haemosiderosis. *Lancet.* 1985;1(8435):981-2.
14. Tutor JD, Eid NS. Treatment of idiopathic pulmonary hemosiderosis with inhaled flunisolide. *South Med J.* 1995;88(9):984-6.