

Original Article

Foreign body aspiration in children: clinical aspects, radiological aspects and bronchoscopic treatment*

Andrea de Melo Alexandre Fraga¹, Marcelo Conrado dos Reis², Mariana Porto Zambon³, Ivan Contrera Toro⁴, José Dirceu Ribeiro⁵, Emilio Carlos Elias Baracat⁵

Abstract

Objective: To describe the clinical manifestations and bronchoscopic treatment of foreign body aspiration in children under 14 years of age, correlating the clinical aspects with the bronchoscopic findings. **Methods:** A retrospective, descriptive study analyzing data related to children under 14 years of age undergoing bronchoscopy due to clinical suspicion of foreign body aspiration at the State University at Campinas *Hospital das Clínicas* from January of 2000 to December of 2005. **Results:** The sample consisted of 69 patients, ranging in age from 8 months to 12 years/7 months (75.4% under 3 years of age), 62.3% of whom were male. The principal complaint was sudden-onset cough (75.4%), auscultation was abnormal in 74%, and dyspnea was observed in 29%. Radiological abnormalities were seen in 88% of the cases. Aspirations were primarily into the right lung (54.8%), and 30.7% of the foreign bodies were of vegetal origin (principally beans and peanuts). In the follow-up period, 29% presented complications (most commonly pneumonia), which were found to be associated with longer aspiration time ($p = 0.03$). Mechanical ventilation was required in 7 children (10.1%), and multiple bronchoscopies were performed in 5 (7.2%). **Conclusions:** A history of sudden-onset choking and cough, plus abnormal auscultation and radiological findings, characterizes the profile of foreign body aspiration. In such cases, bronchoscopy is indicated. Longer aspiration time translates to a higher risk of complications. The high prevalence of foreign bodies of vegetal origin underscores the relevance of prevention at children younger than 3 years of age.

Keywords: Foreign bodies; Bronchoscopy; Pediatrics.

* Study carried out in the Department of Pediatrics at the *Universidade Estadual de Campinas* – Unicamp, State University at Campinas – School of Medical Sciences, Campinas, Brazil.

1. Attending Physician in the Pediatric Emergency Room of the *Hospital das Clínicas da Universidade Estadual de Campinas* – HC-Unicamp, State University at Campinas *Hospital das Clínicas* – Campinas, Brazil.

2. Physician in the Pediatric Emergency Room of the *Hospital das Clínicas da Universidade Estadual de Campinas* – HC-Unicamp, State University at Campinas *Hospital das Clínicas* – Campinas, Brazil.

3. PhD Assistant Professor in the Pediatric Emergency Room in the *Hospital das Clínicas da Universidade Estadual de Campinas* – HC-Unicamp, State University at Campinas *Hospital das Clínicas* – Campinas, Brazil.

4. PhD Assistant Professor in the Department of Thoracic Surgery of the *Universidade Estadual de Campinas* – Unicamp, State University at Campinas – Campinas, Brazil.

5. PhD Assistant Professor in the Department of Pediatric Pulmonology of the *Universidade Estadual de Campinas* – Unicamp, State University at Campinas – Campinas, Brazil.

Correspondence to: Andrea de Melo Alexandre Fraga. Avenida Coronel Silva Teles, 211, apto. 3, Cambuí, CEP 13024-000, Campinas, SP, Brasil.

Tel 55 19 3521-8768. E-mail: andreafrag@gmail.com

Submitted: 22 February 2007. Accepted after review: 13 June 2007.

Introduction

Childhood accidents are a major cause of morbidity and mortality worldwide, corresponding to approximately 53% of all insults to the health of children and young people in Brazil. They constitute the leading cause of mortality in individuals between 1 and 19 years of age, despite accident prevention campaigns, discussions about traffic in schools and greater pediatrician dissemination of information regarding preventive measures.⁽¹⁾

Among the accidents, we highlight airway foreign body aspiration (FBA).^(2,3) Statistics show that, in the United States, 5% of all accident-related deaths in children under the age of 4 are caused by FBA, which is also the leading cause of accidental death in the home among children under the age of 6.⁽⁴⁾ In Brazil, FBA is the third leading cause of accidents that result in death.⁽⁵⁾

In children, FBA is associated with the failure in the laryngeal closure reflex, inadequate swallowing reflex and the habit of putting objects in the mouth. Parental negligence and lack of information regarding certain objects that might be aspirated, such as small toys and certain types of food, are predisposing factors.⁽⁶⁾

Early diagnosis of FBA is essential, since the delay in its recognition and treatment can result in permanent side effects or fatal damage. Many patients presenting recurrent respiratory diseases are treated for weeks or months prior to the suspicion of FBA.⁽³⁾

Clinically, FBA manifests as cough, followed by choking, that might or might not be given any consideration by the parents. The first episode of sudden wheezing can also raise the suspicion of FBA.⁽³⁾ Clinical findings depend on the type, size and location of foreign body and include persistent cough, localized airway resistance, localized or diffuse wheezing and difficulty in breathing. Approximately 40% of the patients are asymptomatic and present no alterations upon physical examination.⁽⁶⁾

Bronchoscopy is the procedure of choice for removal of the foreign body. We prefer the use of a rigid bronchoscope, since it presents a lower risk of complications. It is known that the foreign body is not found in 10 to 15% of the patients.⁽⁷⁾ Therefore, bronchoscopy should be carried out in every suspected case.

The *Hospital das Clínicas da Universidade Estadual de Campinas* (HC-Unicamp, State University at Campinas *Hospital das Clínicas*), located in the state of São Paulo, is a referral center for the bronchoscopic treatment of FBA. The evaluation of clinical and radiological findings, as well as the bronchoscopy results of patients submitted to this procedure in recent years, might help to establish the profile of these accidents. Such knowledge can serve to inform pediatricians not only regarding the most common clinical manifestations of FBA but also of preventive measures aimed at the target population.

Methods

This study was conducted in the HC-Unicamp *Unidade de Emergência Pediátrica* (UE-Ped, Pediatric Emergency Room), which is a tertiary care facility, treating patients covered under the Unified Health Care System. The HC-Unicamp UE-Ped serves the pediatric (under 14 years of age) population in the greater metropolitan area of Campinas as well as in other cities in the region and treats an average of 1600 patients/month.

The Bronchoscopy Sector of the HC-Unicamp carries out an average of 70 diagnostic or therapeutic bronchoscopies per month.

We evaluated the records of 116 patients under the age of 14 who were submitted to bronchoscopy between January of 2000 and December of 2005. Of those 116 patients, 69 were evaluated for suspicion of FBA and were selected for study.

The procedures were carried out under general anesthesia and using a rigid bronchoscope (model 10338; Karl Storz Instruments, Tuttlingen, Germany), with calibers of 2.5, 3.5 or 5.0, according to the size of the patient.

The data were compiled using the Epi Info program, version 6.04d, and were analyzed using the chi-square test or Fisher's exact test, when necessary, with a significance level of 5%.

Since this is a retrospective study, based on the analysis of patient charts, it was not necessary to obtain written informed consent. The anonymity of the patients was maintained in accordance with resolution CNS-196/96 (CAAE: 0381.0.146.000-06), and the study design was approved by the HC-Unicamp Ethics in Research Committee (process no. 492/2006).

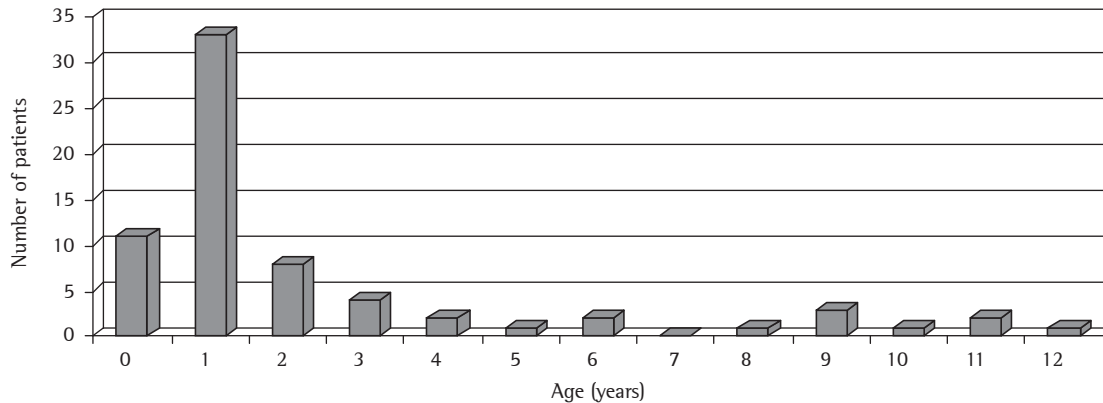


Figure 1 – Number of patients submitted to bronchoscopy due to clinical suspicion of foreign body aspiration in the 2000-2005 period, according to age.

Variables studied

- Epidemiological data: gender, age and precedence;
- Interval between event and symptom onset;
- Symptoms at admission: absent, choking, cough or wheezing;
- Assessment: signs of respiratory insufficiency (respiratory frequency, respiratory effort, cyanosis and peripheral oxygen saturation lower than 95%) and pulmonary auscultation findings;
- Chest X-ray: normal or abnormal (parenchyma opacity, atelectasis, hyperinflation, mediastinal deviation or visible foreign body);
- Interval between admission and bronchoscopy
- Location of foreign body: right bronchus, left bronchus, both bronchi or trachea;
- Foreign body: metal, plastic, vegetable or mineral;
- Destination following the procedure: UE-Ped, pediatric infirmary or pediatric intensive care unit;
- Hospitalization (days);
- Invasive mechanical ventilation;
- Complications following the procedure: primary complications, related to FBA; secondary complications, related to the bronchoscopy procedure; and late complications; and
- Outpatient follow-up: time and specialty

In order to determine the associations between bronchoscopy findings and clinical variables, the following comparisons were carried out:

- between symptoms at admission and location; and
- between a number of variables (clinical status, progress, radiological findings, need for mechanical ventilation, location and second bronchoscopy) and the presence of complications

Results

Among the 69 patients, there was a predominance of males (62.3%) ranging in age from 8 months to 12 years/7 months, with a mean age of 35.8 months (Figure 1), and 75.4% of the patients were under 3 years of age.

The interval between the event and the admission to the UE-Ped ranged from 1 h to 60 days. A total of 26 children (37.7%) were admitted within the first 24 h.

A total of 32 patients (46.4%) were residents of Campinas. Another 32 came from different cities in the state of São Paulo, and 5 (7.2%) came from cities in the southern region of Minas Gerais.

Among the clinical findings (Table 1), a history of choking and sudden-onset cough was present in 52 (75.4%) patients.

In the lung assessment at admission (Table 1), 20 children (29%) presented dyspnea. Of those 20, 3 (4.3%) had been orotracheally intubated

Table 1 - Clinical symptoms and pulmonary auscultation at admission of patients submitted to bronchoscopy for clinical suspicion of foreign body aspiration in the 2000-2005 period.

Clinical symptoms	n	%
Cough	52	75.4
Respiratory discomfort	29	42.0
Cyanosis	19	27.5
Wheezing	18	26.0
Fever	10	14.5
Vomiting	7	10.1
Chest pain	3	4.3
Stridor	2	2.9
Hoarseness	1	1.4
Halitosis	1	1.4
Asymptomatic	1	1.4
Pulmonary auscultation	n	%
Asymmetry in breath sounds	27	39.1
Normal	18	26.1
Wheezing	17	24.7
Asymmetric breath sounds with wheezing	7	10.1

prior to their transfer, and another 2 (2.9%) underwent the procedure immediately after admission. Continuous monitoring with pulse oximetry was indicated in 15 cases, 7 of which (46.7%) presented peripheral oxygen saturation lower than 95%.

A simple chest X-ray was conducted in 67 cases, and 8 (11.9%) presented no alterations. The most common finding was atelectasis (26 cases; 38.8%). Other alterations were hyperinflation (16 cases; 23.9%), lung parenchyma opacity (10 cases; 14.9%) and deviation of the trachea (9 cases; 13.4%). In 15 cases (22.4%), the foreign body was visible.

All of the children underwent bronchoscopy, 52.2% in the first 6 h following admission and 64 (92.8%) within the first 24 h. In the 5 remaining cases (7.2%), which had a prolonged and undefined history (5 to 30 days after the onset of symptoms), bronchoscopy was elective.

During bronchoscopy, the foreign body was identified and removed in 60 cases (87%). In another 9 (13%), there were indirect signs, such as edema, hyperemia of bronchial mucosa and presence of secretion. However, the foreign body was not found. In most cases (33; 55%), the foreign body was found in the right bronchus (or in one of its segments). In 22 cases (36.7%), it was located in the left bronchus or segment, whereas in 4 children (6.7%), it was located in the trachea. In one

child who aspirated a peanut, fragments of the foreign body were found in both bronchi. In 5 cases (7.2%), the removal of the foreign body was not possible in the initial bronchoscopy, and a second bronchoscopy was required in 3 patients. In addition, it was necessary to perform thoracotomy in 1 patient. In the remaining case, the foreign body was not removed after two attempts, and the object migrated to the segmental bronchus. During the outpatient follow-up period, the patient remained asymptomatic, and a third bronchoscopy was proposed. However, the patient did not return for the follow-up visits, even after being contacted.

Comparing the topography of the foreign body to the bronchoscopy findings, age and clinical aspects, we observed that the presence of cough presented a correlation, albeit below the level of statistical significance ($p = 0.068$), with the variables foreign body in the bronchus and foreign body in the trachea, being more closely associated to the former.

As can be seen in Table 2, the origin of the foreign body aspirated was predominantly vegetal (in 40.6% of the cases), followed by metallic (in 17.4%), plastic (in 15.9%) and mineral (in 2.9%).

A total of 46 children (66.7%) returned to the UE-Ped in the postoperative period immediately after bronchoscopy, and 43 (93.5%) of those 46 were hospitalized for up to 24 h. Fourteen children (20.3%) were sent to the pediatric infirmary, and another 9 (13%) were admitted to the pediatric intensive care unit, 7 (10.1%) requiring invasive mechanical ventilation for 1 to 7 days (median, 2 days; mean, 3.6 days).

The period of hospitalization following bronchoscopy ranged from 1 to 12 days (mean, 2.1 days). In the patients presenting complications, we observed a longer hospitalization period, with a mean of 4.7 days (1.1 days in the group presenting no complications) ($p < 0.05$).

No deaths occurred.

Complications occurred in 18 children (26.1%); the most frequent pulmonary complications were primary complications, followed by secondary complications and late complications (Table 3). In comparing the different variables with the presence of primary complications (Table 4), we found that the presence of primary complications was associated with a longer than 48 h interval between the event and admission ($p = 0.03$) as well as with the

Table 2 – Number of patients submitted to bronchoscopy for clinical suspicion of foreign body aspiration, in the 2000–2005 period, according to the composition of the foreign body aspirated.

Foreign body	n	%
Bean	13	21.7
Peanut	11	18.3
Plastic pen cap	4	6.7
Earring	3	5.0
Fruit seed	3	5.0
Chicken bone	3	5.0
Stone	2	3.3
Chicken cartilage	2	3.3
Coffee bean	2	3.3
Pin	2	3.3
Plastic toy	2	3.3
Hair pin	1	1.7
Metal piece	1	1.7
Metallic pen tip	1	1.7
Nail	1	1.7
Hair clip	1	1.7
Bracelet	1	1.7
Earring back	1	1.7
Sequin	1	1.7
Plastic curtain holder	1	1.7
Plastic piece	1	1.7
Ball inflation needle	1	1.7
Cracker	1	1.7
Peanut + toy	1	1.7

need for a second procedure in order to remove the foreign body ($p < 0.05$).

In relation to the subsequent follow-up evaluation, 51 children were discharged from the hospital, and 18 (26%) returned as outpatients, the follow-up period ranging from 1 to 98 months (median, 3 months).

Discussion

In children, FBA is a life threatening event and is associated with high morbidity rates, principally in children under the age of 3. It is a preventable condition, requiring educational programs directed at parents, involving counseling regarding habits that predispose children in this age bracket to FBA, as well as education regarding the basic concepts of resolving upper airway obstruction. After the introduction of these techniques by the Pediatric Basic Life Support Program in 1989, deaths from airway

obstruction caused by foreign body decreased 60% in the USA.⁽⁸⁾

Most cases of FBA occur in males under 3 years of age, as described in this study and in many other international^[6,9,10-13] and national^[2,5,14] studies. This is probably due to the developmental characteristics in this age bracket, as well as to the more adventurous and impulsive nature of young boys.⁽¹⁵⁾

Studies conducted at referral centers show that most patients with suspicion of FBA present for treatment within 24 h after the accident.^(11,14,16-18) In our sample, the interval between the occurrence of the event and admission to the UE-Ped ranged from 1 h to 60 days. Nevertheless, 37.7% of the patients were admitted within the first 24 h after the event, showing that, in the health system of the region, there is an appropriate hierarchy for the admission of patients suffering this type of accident. In a study conducted in Canada, the interval between FBA and the diagnosis was longer than 30 days in 17% of the patients.⁽¹⁹⁾ In a study conducted in Israel, 47% of the diagnoses were delayed from 1 day to 1 month.⁽³⁾ In a study conducted in China, 28.7% of the cases were diagnosed after 7 days, and 6.8% were diagnosed after 1 month.⁽⁶⁾

The diagnosis of FBA is not always easy, since, in most cases, parents do not witness the accident and suspicion must be raised based on clinical history, symptoms (sudden-onset cough and choking) and clinical signs (wheezing during auscultation and respiratory discomfort). In our study, 75.4% of the patients had a history of choking and coughing, showing the value of these complaints as indicators of FBA.^(15,17) Cyanosis was a sign present in a significant portion of the patients and is a cause for concern, since it is an extremely severe symptom and calls for rapid management of the airway by a skilled team of professionals. Recent studies have shown that cyanosis is present in 10% to 15% of all cases of FBA.^(15,20) However, in a joint French-Brazilian study conducted in 2006, a value approximating that found in the present study was observed (21.5% and 27.5%, respectively),⁽¹⁴⁾ which might be explained by the short interval between the accident and the arrival at the emergency room.

In the present study, we found asymmetry in pulmonary auscultation in 39.2% of the cases, which is in accordance with the findings of a study conducted in 2005.⁽¹⁵⁾ This finding appears to have high specificity in FBA,^(21,22) being present in more

Table 3 – Number of patients submitted to bronchoscopy for clinical suspicion of foreign body aspiration, in the 2000-2005 period, according to the presence/type of complications.

Complications	n	%
Primary		
Pneumonia	9	13.0
Pneumonia + atelectasis	5	7.2
Atelectasis	1	1.4
Secondary		
Barotrauma	1	1.4
Barotrauma + laceration of the trachea	1	1.4
Late		
Granulomatous stenosis	1	1.4

than half of all cases.^(10,16,23) As it is dependent on the examiner, asymmetry in pulmonary auscultation might present a high degree of subjectivity, and its absence should not be considered a reason for ruling out FBA. When other signs and symptoms have raised the suspicion of FBA, clinicians should attempt to perform a more accurate and careful pulmonary auscultation in the search for asymmetry.

When relating the clinical history and the symptoms of the patients with the location of the foreign body in bronchoscopy, it was observed that the presence of cough was suggestive of the foreign body being lodged in the bronchus. Although it was not statistically significant, the fact that the p value was near 0.05 for this variable might indicate a trend toward a correlation, which might be seen in larger samples.

A simple chest X-ray is the first procedure to be carried out in the suspicion of FBA, since it is readily available at health facilities and presents considerable sensitivity. In a previous study,⁽²⁴⁾ it was observed that the signs considered typical of FBA, atelectasis and localized hyperinflation, were present in patients for whom the bronchoscopy for foreign body was with positive, as well as in those for whom it was negative (68% of sensitivity and 67% of specificity for the method). Other authors observed normal X-rays in 47% of patients with FBA,⁽¹⁷⁾ and still others,⁽⁶⁾ in a sample of 400 patients, observed normal X-rays in 35% of patients presenting a foreign body located in the bronchi and in 84% of those presenting a foreign body located in the trachea. In our sample, 67 simple chest X-rays

were conducted. Of those, 8 (11.9%) presented no alterations. These observations, once again, underscore the need to consider radiological findings in conjunction with other clinical signs in order to make a diagnosis of FBA.^(2,6,7,9,11,14,16) The discussion regarding the need for X-rays continues, since other clinical findings present a higher relevance for the indication of bronchoscopy.

The most frequent X-ray finding in our sample was atelectasis (in 38.8%). Other authors have observed similar values.^(7,25,26) Some studies in the literature have reported lower rates of atelectasis on simple chest X-rays (between 15 and 20%).^(6,14,17) These differences might be associated with the types, shapes and sizes of the foreign bodies aspirated, as well as with patient age, all of which vary widely among studies. In addition, the length of time that the object remains in the bronchial lumen affects the finding of atelectasis, since the risk of occlusion by edema or accumulation of secretion increases over time.⁽²⁵⁾

The visualization of the foreign body on a simple chest X-ray also presents variation in the literature, depending on the geographic region, which affects the type of foreign body most often aspirated. In the present study the foreign body was apparent on simple chest X-rays in 15 cases (22.4%), a value approximate to that observed in a recent study,⁽¹⁴⁾ in which the foreign body was visible in 25% of the cases. Since most aspirated foreign bodies are radiotransparent, secondary radiological alterations should receive special attention, such as the duration of symptoms, the nature of the object aspirated and the degree of obstruction caused.^(9,25)

The nature of the foreign body aspirated is connected with cultural habits, intellectual level and socioeconomic situation of each country. However, there is a clear predominance of objects of organic origin.^(2,4,5,16,26,27) In Lebanon, the foreign body most often aspirated is the watermelon seed,⁽¹¹⁾ whereas peanuts and dried fruits predominate in Egypt.⁽¹²⁾ In the United States, the foreign bodies most often aspirated are those of vegetal origin, peanuts predominating.^(7,16) In Brazil, peanuts, beans and corn are the foreign bodies most commonly aspirated.^(2,14,25) In our sample, there was also a predominance of foreign bodies of vegetal origin, especially beans (13 cases; 46.4%) and peanuts (11 cases; 39.3%)

Table 4 – Factors associated with primary pulmonary complications among patients submitted to bronchoscopy for foreign body removal, in the 2000–2005 period.

Variables	Complications (yes/no)	p
Gender		
Male	27.9% (12/31)	0.194
Female	11.5% (3/23)	
Age		
<2 Years	20.0% (8/32)	0.907
≥2 Years	24.1% (7/22)	
Interval event/admission		
<48 H	7.1% (2/26)	0.033
≥48 H	31.7% (13/28)	
Arf on physical examination		
Present	17.2% (5/24)	0.634
Absent	25.0% (10/30)	
Intubation at admission		
Yes	40.0% (2/3)	0.641
No	20.3% (13/51)	
Pulmonary assessment		
Normal	11.8% (2/15)	0.418
Altered	25.0% (13/39)	
X-ray at admission		
Normal	12.5% (1/7)	0.827
Altered	23.7% (14/45)	
Location of fb		
Trachea	0% (0/4)	0.550
Bronchi	26.8% (15/41)	
Location of fb		
Right bronchus	27.3% (9/33)	0.949
Left bronchus	22.7% (5/22)	
Origin of fb		
Vegetal	32.1% (9/19)	0.370
Other	18.8% (6/26)	
Second bronchoscopy for fb removal		
Yes	100.0% (5/0)	<0.005
No	18.5% (10/44)	
Mechanical ventilation following bronchoscopy		
Yes	28.6% (2/5)	0.983
No	21.0% (13/49)	

ARF: Acute respiratory failure; and FB: foreign body.

Anatomically, the right bronchus, due to its greater verticality and larger diameter, favors the entry of a foreign body.⁽²¹⁾ In the present study, we observed a predominance of the location of the foreign bodies were more often lodged in the right bronchus than in the left bronchus (54.8% vs. 37.1%), a finding that is in agreement with those

of various other studies.^(20,28,29,30) Other authors,⁽²⁵⁾ studying 74 patients suffering FBA, reported that the foreign body was lodged in the right bronchus in 50% of the patients, in the left bronchus in 35% and in the trachea in 15%.

In our sample, the principal primary complication was pneumonia, as previously described in other

studies.^(5,11,16) Procedure-related complications, such as barotrauma, occurred in only 2 patients. Other authors have reported the occurrence of pneumo-mediastinum.⁽¹⁰⁾ In another study,⁽¹¹⁾ pneumothorax was observed. However, neither of those conditions is common. In a sample of 304 patients, another group of authors observed that older children with a foreign body in the right bronchus and submitted to more than one bronchoscopy presented a higher risk of complications.⁽²⁰⁾ In our study, all 5 patients who required a second bronchoscopic procedure presented complications.

In our sample, there were no deaths, as have been described by other authors,^(10,11,13) and the period of hospitalization was short (less than 24 h) in 72.1% of the cases, demonstrating the safety of bronchoscopic treatment.^(2,15,16,20,30)

The delay in the diagnosis of FBA is associated with the lack of attention to the signs and symptoms present in the clinical history of choking and cough, especially in children under 3 years of age. The weight given to simple chest X-ray as an examination indicated for the exclusion of FBA is another common error. These diagnostic difficulties result in inappropriate treatment for symptoms of pneumonia, asthma or laryngitis. Knowing that the longer a foreign body remains in the tracheobronchial tree, the higher is the possibility of complications, FBA must be included in the differential diagnosis of acute respiratory symptoms. These conditions do not negate the need for the implementation of programs directed to the lay populations, of prevention and counseling regarding the management and resolution of airway obstruction.

In conclusion, FBA occurs predominantly in male children under 3 years of age with a clinical history of sudden-onset cough. These data, together with pulmonary auscultation findings, even when chest X-rays are normal, characterize the clinical symptoms of FBA and suggest that bronchoscopy is indicated. In the present study, foreign bodies of vegetal origin, located in the right bronchus, were the most prevalent. The complications that occurred were aspiration time-dependent.

References

- Paes CE, Gaspar VL. As injúrias não intencionais no ambiente domiciliar: a casa segura. *J Pediatr (Rio J)*. 2005;81(Supl 5):S146-S54.
- Cassol V, Pereira AM, Zorzela LM, Becker MM, Barreto SS. Corpo estranho na via aérea de crianças. *J Pneumol*. 2003;29(3):139-44.
- Weissberg D, Schwartz I. Foreign bodies in the tracheobronchial tree. *Chest*. 1987;91(5):730-3.
- Rovin JD, Rodgers BM. Pediatric foreign body aspiration. *Pediatr Rev*. 2000;21(3):86-90.
- Lima JA, Fischer GB, Felicetti JC, Flores JA, Penna CN, Ludwig E. Aspiração de corpo estranho na árvore traqueobrônquica em crianças: avaliação de seqüelas através de exame cintilográfico. *J Pneumol*. 2000;26(1):20-4.
- Mu LC, Sun DQ, He P. Radiological diagnosis of aspirated foreign bodies in children: review of 343 cases. *J Laryngol Otol*. 1990;104(10):778-82.
- Mantor PC, Tuggle DW, Tunell WP. An appropriate negative bronchoscopy rate in suspected foreign body aspiration. *Am J Surg*. 1989;158(6):622-4.
- American Heart Association. Suporte Avançado de Vida em Pediatria [Pediatric Advanced Life Support - PALS]. Manual para Provedores. Rio de Janeiro: ACINDES; 2003.
- Baharloo F, Veyckemans F, Francis C, Bietlot MP, Rodenstein DO. Tracheobronchial foreign bodies: presentation and management in children and adults. *Chest*. 1999;115(5):1357-62.
- Black RE, Johnson DG, Matlak ME. Bronchoscopic removal of aspirated foreign bodies in children. *J Pediatr Surg*. 1994;29(5):682-4.
- Zaytoun GM, Rouadi PW, Baki DH. Endoscopic management of foreign bodies in the tracheobronchial tree: predictive factors for complications. *Otolaryngol Head Neck Surg*. 2000;123(3):311-6.
- Sersar SI, Rizk WH, Bilal M, El Diasty MM, Eltantawy TA, Abdelhakam BB, et al. Inhaled foreign bodies: presentation, management and value of history and plain chest radiography in delayed presentation. *Otolaryngol Head Neck Surg*. 2006;134(1):92-9.
- Aydoğan LB, Tuncer U, Soylu L, Kiroğlu M, Ozsahinoglu C. Rigid bronchoscopy for the suspicion of foreign body in the airway. *Int J Pediatr Otorhinolaryngol*. 2006;70(5):823-8.
- Bittencourt PF, Camargos PA, Scheinmann P, de Blic J. Foreign body aspiration: clinical, radiological findings and factors associated with its late removal. *Int J Pediatr Otorhinolaryngol*. 2006;70(5):879-84.
- Chiu CY, Wong KS, Lai SH, Hsia SH, Wu CT. Factors predicting early diagnosis of foreign body aspiration in children. *Pediatr Emerg Care*. 2005;21(3):161-4.
- Vane DW, Pritchard J, Colville CW, West KW, Eigen H, Grosfeld JL. Bronchoscopy for aspirated foreign bodies in children. Experience in 131 cases. *Arch Surg*. 1988;123(7):885-8.
- Zerella JT, Dimler M, McGill LC, Pippus KJ. Foreign body aspiration in children: value of radiography and complications of bronchoscopy. *J Pediatr Surg*. 1998;33(11):1651-4.
- Griffiths DM, Freeman NV. Expiratory chest x ray examination in the diagnosis of inhaled foreign bodies. *Br Med J (Clin Res Ed)*. 1984;288(6423):1074-5.
- Corrêa EP, Figueiredo VR, Jacomelli M. A utilização da broncoscopia flexível na retirada de corpos estranhos de vias aéreas. In: Saad Jr R, Carvalho WR, Ximenez-Netto M, Forte V, editors. *Cirurgia torácica geral*. Rio de Janeiro: Atheneu; 2005.
- Tang FL, Chen MZ, Du ZL, Zou CC, Zhao YZ. Fibrobronchoscopic treatment of foreign body aspiration in

- children: an experience of 5 years in Hangzhou City, China. *Pediatr Surg*. 2006;41(1):e1-5.
21. Hoeve LJ, Rombout J, Pot DJ. Foreign body aspiration in children. The diagnostic value of signs, symptoms and pre-operative examination. *Clin Otolaryngol Allied Sci*. 1993;18(1):55-7.
 22. Karakoç F, Karadağ B, Akbenlioğlu C, Ersu R, Yildizeli B, Yüksel M, et al. Foreign body aspiration: what is the outcome? *Pediatr Pulmonol*. 2002;34(1):30-6.
 23. Lea E, Nawaf H, Yoav T, Elvin S, Ze'ev Z, Amir K. Diagnostic evaluation of foreign body aspiration in children: a prospective study. *J Pediatr Surg*. 2005;40(7):1122-7. Erratum in: *J Pediatr Surg*. 2005;40(11):1815.
 24. Svedström E, Puhakka H, Kero P. How accurate is chest radiography in the diagnosis of tracheobronchial foreign bodies in children? *Pediatr Radiol*. 1989;19(8):520-2.
 25. Cataneo AJ, Reiberscheid SM, Ruiz Júnior RL, Ferrari GF. Foreign body in the tracheobronchial tree. *Clin Pediatr (Phila)*. 1997;36(12):701-6.
 26. Midulla F, Guidi R, Barbato A, Capocaccia P, Forenza N, Marseglia G, et al. Foreign body aspiration in children. *Pediatr Int*. 2005;47(6):663-8.
 27. Kim IG, Brummitt WM, Humphry A, Siomra SW, Wallace WB. Foreign body in the airway: a review of 202 cases. *Laryngoscope*. 1973;83(3):347-54.
 28. Black RE, Choi KJ, Syme WC, Johnson DG, Matlak ME. Bronchoscopic removal of aspirated foreign bodies in children. *Am J Surg*. 1984;148(6):778-81.
 29. Pinto A, Scaglione M, Pinto F, Guidi G, Pepe M, Del Prato B, et al. Tracheobronchial aspiration of foreign bodies: current indications for emergency plain chest radiography. *Radiol Med (Torino)*. 2006;111(4):497-506.
 30. Blazer S, Naveh Y, Friedman A. Foreign body in the airway. A review of 200 cases. *Am J Dis Child*. 1980;134(1):68-71.