

# Case Report

## A very rare cause of dyspnea with a unique presentation on a computed tomography scan of the chest: macrophage activation syndrome\*

Uma rara causa de dispnéia com apresentação singular na tomografia computadorizada de tórax: síndrome de ativação macrófágica

Rodrigo Antônio Brandão-Neto<sup>1</sup>, Alfredo Nicodemos Cruz Santana<sup>2</sup>, Debora Lucia Seguro Danilovic<sup>3</sup>, Fabíola Del Carlo Bernardi<sup>4</sup>, Carmen Silvia Valente Barbas<sup>5</sup>, Berenice Bilharinho de Mendonça<sup>6</sup>

### Abstract

Macrophage activation syndrome is a rare and potentially life-threatening disease. It occurs due to immune dysregulation manifested as excessive macrophage proliferation, typically causing hepatosplenomegaly, pancytopenia and hepatic dysfunction. Here, we report an unusual case of macrophage activation syndrome presenting as dyspnea, as well as (reported here for the first time) high resolution computed tomography findings of an excavated nodule, diffuse ground glass opacities and consolidations (mimicking severe pneumonia or alveolar hemorrhage). The patient was successfully treated with human immunoglobulin. We recommend that macrophage activation syndrome be considered in the differential diagnosis of respiratory failure. Rapid diagnosis and treatment are essential to achieving favorable outcomes in patients with this syndrome.

**Keywords:** Macrophage activation; Lymphohistiocytosis, hemophagocytic; Tomography, X-ray computed; Lung diseases, interstitial.

### Resumo

A síndrome de ativação macrófágica é uma doença rara e potencialmente fatal. Ela ocorre devido a uma alteração no sistema imunológico, com excessiva proliferação de macrófagos, geralmente causando hepatoesplenomegalia, pancitopenia e disfunção hepática. Neste artigo, relatamos uma raríssima apresentação da síndrome de ativação macrófágica como insuficiência respiratória, bem como a primeira descrição de nódulo escavado, vidro fosco e consolidação na tomografia computadorizada de alta resolução de pulmão (simulando uma pneumonia ou hemorragia alveolar) e o sucesso terapêutico com o uso de imunoglobulina humana. Assim, sugerimos que a síndrome de ativação macrófágica seja colocada no diagnóstico diferencial de causas de insuficiência respiratória e que o rápido diagnóstico e tratamento seja imperativo para a boa evolução do paciente.

**Descritores:** Ativação de macrófagos; Linfohistiocitose hemofagocítica; Tomografia computadorizada por raios X; Doenças pulmonares intersticiais.

### Introduction

Macrophage activation syndrome (MAS), also known as hemophagocytic syndrome or hemophagocytic lymphohistiocytosis, is a rare and potentially life-threatening disease. It occurs due to immune dysregulation manifested as excessive macrophage proliferation in response to a triggering

agent, such as infections, rheumatologic diseases or tumors. The typical clinical presentation of MAS is the sudden onset of fever, hepatosplenomegaly, lymphadenopathy, pancytopenia and hepatic dysfunction. The histopathological finding is macrophage phagocytosis by erythrocytes (which

\* Study conducted at the *Hospital das Clínicas da Faculdade de Medicina da Universidade de São Paulo* – HCFMUSP, University of São Paulo School of Medicine *Hospital das Clínicas* – and at the *Hospital Universitário da Universidade de São Paulo* – HUUSP, University of São Paulo University Hospital – São Paulo, Brazil.

1. Attending Physician in the Clinical Emergency Department. *Hospital das Clínicas da Faculdade de Medicina da Universidade de São Paulo* – HCFMUSP, University of São Paulo School of Medicine *Hospital das Clínicas* – São Paulo, Brazil.

2. Doctoral Student in Pulmonology. *Faculdade de Medicina da Universidade de São Paulo* – FMUSP, University of São Paulo School of Medicine – São Paulo, Brazil.

3. Doctoral Student in Endocrinology. *Faculdade de Medicina da Universidade de São Paulo* – FMUSP, University of São Paulo School of Medicine – São Paulo, Brazil.

4. Attending Physician in the Department of Pathology. *Hospital das Clínicas da Faculdade de Medicina da Universidade de São Paulo* – HCFMUSP, University of São Paulo School of Medicine *Hospital das Clínicas* – São Paulo, Brazil.

5. Tenured Professor in the Department of Pulmonology. *Hospital das Clínicas da Faculdade de Medicina da Universidade de São Paulo* – HCFMUSP, University of São Paulo School of Medicine *Hospital das Clínicas* – São Paulo, Brazil.

6. Full Professor in the Department of Endocrinology. *Hospital das Clínicas da Faculdade de Medicina da Universidade de São Paulo* – HCFMUSP, University of São Paulo School of Medicine *Hospital das Clínicas* – São Paulo, Brazil.

Correspondence to: Alfredo Nicodemos Cruz Santana. Rua Oscar Freire, 2121, ap 602, Pinheiros, CEP 05409-011, São Paulo, SP, Brasil.

Tel 55 11 3088-6603. E-mail: alfredonicodemos@hotmail.com

Submitted: 4 January 2007. Accepted, after review: 25 March 2007.

degrades the erythrocytes, producing hemosiderin) in the bone marrow, spleen, lymph nodes or lungs, without significant pleomorphism or mitotic activity.<sup>(1-4)</sup> Here, we report the first case in which diffuse ground glass opacities accompanied by pulmonary consolidations, mimicking severe pneumonia, were seen on a high-resolution computed tomography (HRCT) scan of an adult individual with MAS.

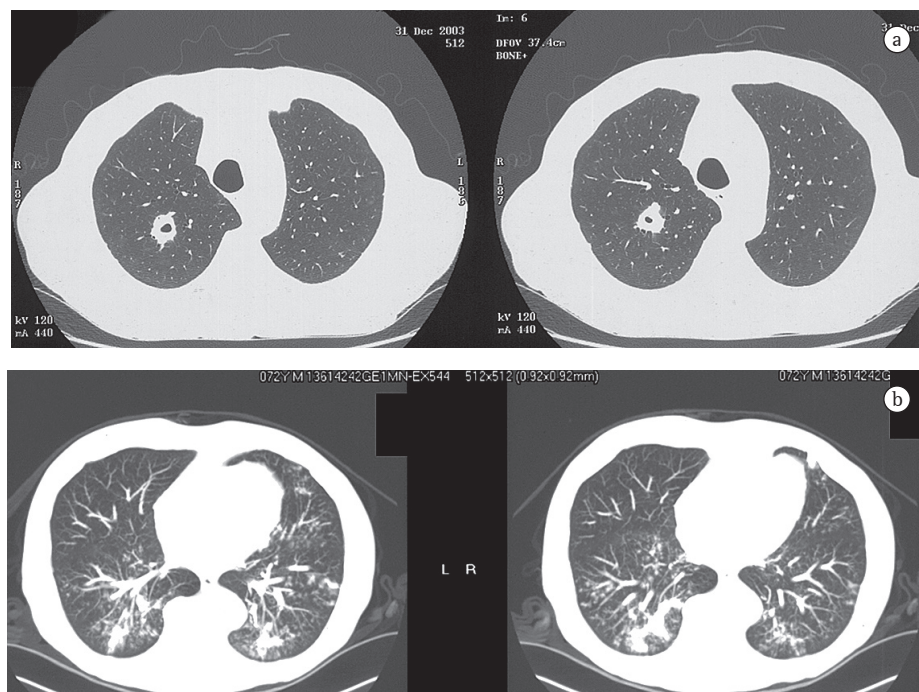
### Case report

A 71-year-old man, recently diagnosed with Cushing's syndrome due to an adrenal tumor, complained of cough, dyspnea and fever. Physical examination showed that oxygen saturation on room air was 88%. Laboratory tests revealed anemia, thrombocytopenia and elevated levels of hepatic aminotransferase, as well as cholestasis, hypertriglyceridemia and an extremely high serum ferritin level (10,580 µg/L; normal range, 20-250 µg/L). Normal magnetic resonance cholangiopancreatography and ultrasonography ruled out obstruction of the biliary system. To investigate the anemia, bone marrow aspiration was performed, and the results were consistent with a diagnosis of MAS. The aspi-

ration culture results were negative. A chest CT scan revealed an excavated nodule, together with ground glass opacities and consolidations (Figure 1). Bronchoscopy was then performed. Cultures of the bronchoalveolar lavage fluid were negative, and a transbronchial biopsy of the right lower lobe showed that hemosiderin-laden macrophages were abundant in the alveolar spaces, and that there was no significant pleomorphism or mitotic activity. There was lymphocytic infiltrate in the alveolar septa, which presented thickening. These histopathological findings are also consistent with MAS. Considering this diagnosis, intravenous pulse human immunoglobulin was initiated (1 g/kg daily for 2 days).<sup>(1)</sup> After 20 days, the anemia, hepatic alterations, pulmonary infiltrates and hypoxemia disappeared, and the serum ferritin level normalized. Three years after the immunoglobulin therapy, the patient presented normal chest CT findings and laboratory test results, reporting no complaints.

### Discussion

This was the first reported case of MAS in which the combination of excavated nodule, ground glass opacities and pulmonary consolidations was



**Figure 1** - a) High-resolution computed tomography of the chest revealing an excavated nodule; and b) computed tomography of the chest showing multiple ground glass opacities and consolidations.

observed on an HRCT scan (Figure 1). This finding is important because it includes MAS in the differential tomographic diagnosis of pneumonia, lymphoma, pulmonary vasculitis, alveolar hemorrhage, tuberculosis, nocardiosis and fungal disease.<sup>(5-9)</sup>

There have been only two previous reports of HRCT-proven pulmonary involvement in MAS.<sup>(3,4)</sup> The first described diffuse reticulonodular pulmonary opacities and septal thickening.<sup>(3)</sup> In that case, the transbronchial biopsy showed that the alveolar septa were thickened and infiltrated by lymphocytes, and that hemophagocytic macrophages occupied the alveolar spaces. These pathological findings are similar to those of our case. The patient showed improvement after treatment for MAS.<sup>(3)</sup> The second report was of a case in which there was a polypoid soft mass in the nasal cavity, cervical lymphadenomegaly, hepatosplenomegaly and a 25-mm pulmonary nodule in the right lower lung lobe on chest CT.<sup>(4)</sup> In that case, two separate biopsies (nasal and lymph node) revealed extensive benign proliferation of hemophagocytic and hemosiderin-laden macrophages with lymphocytic infiltrate, findings similar to ours as well as to those accepted in the literature as being diagnostic of MAS.<sup>(1-4)</sup> In that same case, complete regression of the nasal polyps, lymphadenomegaly and hepatosplenomegaly, as well as of a pulmonary nodule, was seen after treatment for MAS. These different tomographic presentations of MAS (nodules, reticulonodular opacities, ground glass opacities and consolidation) might correspond to the presence of macrophages and lymphocytes infiltrating, to varying degrees, the alveolar spaces and septa, similar to what occurs in desquamative interstitial pneumonia and lymphocytic interstitial pneumonia.<sup>(10,11)</sup>

The diagnosis of MAS is established when at least five of the following criteria are met: fever; bicytopenia; hypertriglyceridemia; hemophagocytosis; serum ferritin level > 500 µg/L; splenomegaly; low natural killer cell activity; and increased serum levels of sCD25.<sup>(1)</sup> Our case met the first five criteria, with MAS being secondary to the adrenal tumor. Furthermore, the extremely high serum ferritin level, as well as the bone marrow aspirate and transbronchial biopsy results consistent with MAS, together with the excellent response to immunoglobulin therapy (resolution of the pulmonary, hepatic and

hematologic alterations), support the diagnosis of MAS with pulmonary involvement.

In conclusion, patients with MAS can present respiratory failure, as well as HRCT findings of diffuse ground glass opacities and consolidations, mimicking severe pneumonia or alveolar hemorrhage. In addition, the diagnosis of MAS should be considered especially in patients with concomitant hepatic alterations, cytopenias or high serum levels of ferritin. Consequently, this clinical profile should lead pulmonologists to suspect this potentially lethal condition, allowing rapid diagnosis and treatment, which are essential to achieving favorable outcomes.

## References

1. Emmenegger U, Schaer DJ, Larroche C, Neftel KA. Haemophagocytic syndromes in adults: current concepts and challenges ahead. *Swiss Med Wkly.* 2005;135(21-22):299-314.
2. Popper HH, Zenz W, Mache C, Ohlinger W. Familial haemophagocytic lymphohistiocytosis. A report of three cases with unusual lung involvement. *Histopathology.* 1994;25(5):439-45.
3. Tateishi U, Nishihara H, Okano M, Kobayashi R, Kobayashi I, Fujita N. High-resolution CT findings of macrophage activation syndrome: a case report. *Pediatr Radiol.* 2000;30(10):699-701.
4. Buza N, Bálint I, Schneider T, Koltai L, Orosz Z. Unusual clinical manifestation of virus-associated hemophagocytic syndrome. *Pathol Res Pract.* 2003;199(11):755-9.
5. Baldi BG, Santana AN, Takagaki TY. Nocardiose pulmonar e cutânea em paciente usuário de corticosteróide. *J Bras Pneumol.* 2006;32(6):592-5.
6. Silva RM, Rosa L, Lemos RN. Alterações radiográficas em pacientes com a co-infecção vírus da imunodeficiência humana/tuberculose: relação com a contagem de células TCD4+. *J Bras Pneumol.* 2006;32(3):228-33.
7. Bombarda S, Figueiredo CM, Seiscento M, Terra-filho M. Pulmonary tuberculosis: tomographic evaluation in the active and post-treatment phases. *Sao Paulo Med J.* 2003;121(5):198-202.
8. Leão RC, Marchiori E, Rodrigues R, Souza Jr AS, Gasparetto EL, Escuissato DL. Tomografia computadorizada na avaliação da aspergilose pulmonar angioinvasiva em pacientes com leucemia aguda. *Radiol Bras.* 2006;39(5):327-31.
9. Santos ML, Marchiori E, Vianna AD, Souza Jr AS, Moraes HP. Opacidades em vidro fosco nas doenças pulmonares difusas: correlação da tomografia computadorizada de alta resolução com a anatomopatologia. *Radiol Bras.* 2003; 36(6):329-38.
10. Pipavath S, Godwin JD. Imaging of the chest: idiopathic interstitial pneumonia. *Clin Chest Med.* 2004;25(4):651-6, v-vi. Review.
11. Leslie KO. Pathology of interstitial lung disease. *Clin Chest Med.* 2004;25(4):657-703, vi. Review.