

Original Article

Pulmonary involvement in Behçet's disease: a positive single-center experience with the use of immunosuppressive therapy^{*,**}

Acometimento pulmonar na doença de Behçet: uma boa experiência com o uso de imunossupressores

Alfredo Nicodemos Cruz Santana¹, Telma Antunes², Juliana Monteiro de Barros², Ronaldo Adib Kairalla³, Carlos Roberto Ribeiro de Carvalho⁴, Carmen Silvia Valente Barbas⁵

Abstract

Objective: Behçet's syndrome, or Behçet's disease (BD), is a multisystem pathology, and survival is related to pulmonary involvement. However, it appears that different treatments correlate with different prognoses. The aim of this study was to evaluate clinical and tomographic evolution, as well as the survival, of patients with BD-related pulmonary involvement. **Methods:** A retrospective review of our experience with pulmonary manifestations in patients with BD treated at our institution between January 1, 1988 and April 30, 2006. The clinical, radiological, treatment and survival data were obtained from medical charts. **Results:** We identified 9 patients with BD-related pulmonary involvement. The mean age was 34 ± 11.5 years, and 7 of the patients were male. The radiological findings were as follows: pulmonary artery aneurysm (PAA) in 8 patients; pulmonary embolism in 3 (translating to an incidence of 5.11 cases/100 patient-years); alveolar hemorrhage in one; and pulmonary hypertension in one. The treatment consisted of immunosuppression with prednisone plus chlorambucil (or cyclophosphamide or mycophenolate mofetil) in all patients, with partial or complete resolution of the PAAs. One patient with a PAA and pulmonary hypertension also received sildenafil and warfarin, with good clinical and tomographic response (the first report in the English literature). In our sample, the mean duration of the follow-up period was 6.52 years. The three-year survival rate was 88.8%, as was the five-year survival rate. **Conclusions:** Patients with BD-related pulmonary involvement can present good survival with immunosuppressive therapy, and BD should be borne in mind as a possible cause of pulmonary hypertension and alveolar hemorrhage.

Keywords: Behçet Syndrome; Lung diseases, interstitial; Pulmonary circulation; Hypertension, pulmonary; Pulmonary embolism; Alveolar hemorrhage.

Resumo

Objetivo: A doença de Behçet (DB) representa uma patologia sistêmica, cuja sobrevida se relaciona com a presença de acometimento pulmonar. Entretanto, sugere-se que pacientes com diferentes tratamentos podem apresentar diferentes prognósticos. O objetivo deste estudo foi avaliar a evolução clínica e tomográfica, bem como a sobrevida destes pacientes com acometimento pulmonar relacionado à DB acompanhados em nosso serviço. **Métodos:** Uma análise retrospectiva de nossa experiência com pacientes com acometimento pulmonar relacionado a DB acompanhados de 1 de Janeiro de 1988 a 30 de Abril de 2006. Os dados clínicos, radiológicos, terapêuticos e de sobrevida foram obtidos dos prontuários médicos. **Resultados:** Foram identificados 9 pacientes, com idade média de $34 \pm 11,5$ anos, sendo 7 deles do sexo masculino. Os achados radiológicos foram aneurisma de artéria pulmonar (AAP) em 8 pacientes, embolia pulmonar em 3 (resultando em uma incidência de 5,11 casos/100 paciente-anos), hemorragia alveolar em 1 e hipertensão pulmonar em 1 de 9 doentes. O tratamento consistiu-se de prednisona mais clorambucil (ou ciclofosfamida ou micofenolato de mofetil) em todos os 9 pacientes, com resolução total ou parcial dos AAP. O paciente com AAP e hipertensão pulmonar também recebeu sildenafil e warfarina, com boa resposta clínica e tomográfica. A sobrevida de nossos pacientes foi de 88,8% em 3 e 5 anos, com acompanhamento médio de 6,52 anos. **Conclusões:** Pacientes com acometimento pulmonar relacionado à DB podem apresentar boa sobrevida com tratamento imunossupressor, e a DB deve ser lembrada como uma possível causa de hipertensão pulmonar e hemorragia alveolar.

Descritores: Síndrome de Behçet; Doenças pulmonares intersticiais; Circulação pulmonar; Hipertensão pulmonar; Embolia pulmonar; Hemorragia alveolar.

* Study carried out in the Pulmonology Department of the *Hospital das Clínicas da Faculdade de Medicina da Universidade de São Paulo* – HC-FMUSP, University of São Paulo School of Medicine *Hospital das Clínicas* – São Paulo (SP) Brazil.

1. Doctoral Student in the Pulmonology Department of the *Hospital das Clínicas da Faculdade de Medicina da Universidade de São Paulo* – HC-FMUSP, University of São Paulo School of Medicine *Hospital das Clínicas* – São Paulo (SP) Brazil.

2. Pulmonologist (PhD) at the *Hospital das Clínicas da Faculdade de Medicina da Universidade de São Paulo* – HC-FMUSP, University of São Paulo School of Medicine *Hospital das Clínicas* – São Paulo (SP) Brazil.

3. Attending Physician in the Pulmonology Department of the *Hospital das Clínicas da Faculdade de Medicina da Universidade de São Paulo* – HC-FMUSP, University of São Paulo School of Medicine *Hospital das Clínicas* – São Paulo (SP) Brazil.

4. Head of the Interstitial Disease Group in the Pulmonology Department of the *Hospital das Clínicas da Faculdade de Medicina da Universidade de São Paulo* – HC-FMUSP, University of São Paulo School of Medicine *Hospital das Clínicas* – São Paulo (SP) Brazil.

5. Tenured Professor in the Pulmonology Department of the *Hospital das Clínicas da Faculdade de Medicina da Universidade de São Paulo* – HC-FMUSP, University of São Paulo School of Medicine *Hospital das Clínicas* – São Paulo (SP) Brazil.

Correspondence to: Alfredo N. C. Santana. Rua Oscar Freire, 2121, apto 602, CEP 05409-011, São Paulo, SP, Brazil.

Tel 55 11 3088-6603. E-mail: alfredonicodemos@hotmail.com

Submitted: 18 June 2007. Accepted, after review: 11 September 2007.

**A versão completa em português deste artigo está disponível em www.jornaldepneumologia.com.br

Introduction

Behcet's disease, also known as Behcet's syndrome, is a multisystem pathology with a major vasculitic component. Classically, the disease consists of a triad of recurrent symptoms: sores in the oral mucosa; sores on the genitals; and uveitis.⁽¹⁾ Although Behcet's disease, in general, affects both genders with equal frequency, the most severe form is typically seen in men, primarily manifesting as pulmonary artery aneurysm (PAA).⁽²⁾ In the management of Behcet's disease-related pulmonary involvement in this subgroup of patients, a number of treatments have been used, such as immunosuppression, anticoagulation, surgery or embolization. However, there have been no randomized controlled studies evaluating these options in treatment, and only a few case series have been published on the topic.⁽³⁻⁵⁾ A recent cumulative analysis suggested good survival in patients receiving immunosuppressive therapy.⁽⁶⁾

The aim of this study was to analyze clinical and tomographic evolution, as well as the survival, of patients with Behcet's disease-related pulmonary involvement treated at our facility, all of whom received immunosuppressive therapy.

Methods

All patients diagnosed with Behcet's disease and concomitant Behcet's disease-related pulmonary involvement who sought treatment at our facility between January 1, 1988 and April 30, 2006 were considered eligible for the study.⁽¹⁾ Nine patients were diagnosed, and the following data were obtained

from the clinical charts: age; gender; physical examination findings; computed tomography of the chest findings; prescribed treatment; and follow-up information. All patients gave informed consent.

Statistical analysis was performed. Data are presented as mean \pm standard deviation for continuous variables, and as frequency and percentage for categorical variables. The Kaplan-Meier method was used to assess survival in patients with Behcet's disease-related pulmonary involvement.

Results

Table 1 outlines the demographic and clinical features of the 9 patients with Behcet's disease-related pulmonary involvement, with mean age of 34 ± 11.5 years. The major computed tomography findings were PAA and pulmonary embolism (Table 2; Figures 1 and 2). Other observed alterations were alveolar hemorrhage and pulmonary hypertension. Alveolar hemorrhage, confirmed through bronchoalveolar lavage, occurred simultaneously with pulmonary embolism in one patient (patient 6); pulmonary hypertension, confirmed through echocardiography, occurred simultaneously with PAA in another (patient 9). The computed tomography follow-up evaluation showed partial or complete resolution of the PAA, and no new PAA appeared.

All patients received prednisone plus chlorambucil, prednisone plus cyclophosphamide or prednisone plus mycophenolate mofetil for approximately 18 months (Table 1). One case is noteworthy: patient 6 presented, concomitantly, alveolar hemor-

Table 1 - Demographic data, clinical data and treatment of nine patients with Behcet's disease-related pulmonary involvement.

Patient	Age (Years)	Sex	Lesion				Treatment
			Pulmonary	Cutaneous	Ocular	Neurologic	
1	22	M	+	+			Ch
2	51	M	+		+		Ch
3	25	M	+	+	+	+	Ch
4	54	M	+		+		Ch
5	25	M	+	+			Cy
6	32	F	+	+	+		Ch
7	37	M	+	+		+	Ch
8	33	M	+	+			Ch
9	27	F	+	+			MMF

Ch: chlorambucil; Cy: cyclophosphamide; and MMF: mycophenolate mofetil.

Table 2 - Tomographic findings in nine patients with Behcet's disease-related pulmonary involvement.

Patient	Age (years)	Sex	PAA	PE	AH	PH
1	22	M	+			
2	51	M	+			
3	25	M	+	+		
4	54	M	+			
5	25	M	+			
6	32	F		+	+	
7	37	M	+	+		
8	33	M	+			
9	27	F	+			+

PAA: pulmonary artery aneurysm; PE: pulmonary embolism; AH: alveolar hemorrhage; and PH: pulmonary hypertension.

rhage (with hemoptysis, anemia, diffuse pulmonary infiltrate and hypoxemia), confirmed through bronchoalveolar lavage, in the right lower lung lobe, together with pulmonary embolism, which was confirmed using multidetector computed tomographic angiography. After immunosuppressive therapy (minus anticoagulants, due to the alveolar hemorrhage), the evolution of this patient was favorable (Figure 2). Another intriguing case, patient 9, had pulmonary hypertension and PAA. That patient was treated with mycophenolate mofetil, sildenafil and anticoagulants, after which there was improvement in functional class, resolution of *cor pulmonale*, and a significant reduction in PAA, as well as a significant reduction in systolic pulmonary artery pressure (from 95 to 57 mmHg), as estimated using echocardiography (Table 2 and Figure 2).

The survival rate among our patients (one-year, three-year and five-year survival) was 88.8%, with a mean follow-up period of 6.52 years (Figure 3). The only death occurred in the third month of treatment and was secondary to massive PAA-related hemoptysis (patient 1). It is also interesting to observe the high incidence of pulmonary embolism: 3 cases in 9 patients monitored for 6.52 years, translating to an estimated incidence of 5.11 cases/100 patient-years, which is as high as that seen in antineutrophil cytoplasmic antibody-associated vasculitis.⁽⁷⁾

Discussion

The main finding of our study was the good survival of our patients with Behcet's disease-related pulmonary involvement. The three-year survival rate

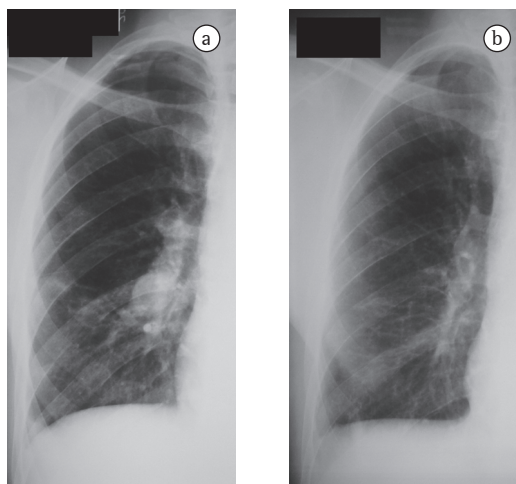


Figure 1 - Patient 4: a) chest X-ray revealing pulmonary artery aneurysm; b) chest X-ray showing resolution of pulmonary artery aneurysm after immunosuppressive therapy.

in the present study was 88.8%, compared to only 45% reported in another study.⁽⁶⁾ The good survival of our patients was probably due to the immunosuppressive therapy administered to all patients indiscriminately, as was done in the subgroup of patients receiving immunosuppressive therapy in another study, in which the two-year survival rate was approximately 80%.⁽⁶⁾

The tomographic imaging studies revealed that the rate of PAA in the present study was higher than that reported in the literature (88% vs. 33.6%).⁽⁶⁾ Despite the fact that aneurysms are considered to be the pulmonary manifestation that has the greatest negative impact on survival among patients with Behcet's disease, three-year survival in our sample was also better than that described in the literature (88.8% vs. 45%).⁽⁶⁾ The case of patient 6 is of note; although the patient presented concomitant alveolar hemorrhage and pulmonary embolism (Figure 2), favorable evolution was achieved using immunosuppression alone (without anticoagulation therapy). After three months, multidetector computed tomographic angiography showed complete reperfusion of the affected artery, and the echocardiogram disclosed no pulmonary hypertension. This supports the findings of other studies suggesting that immunosuppressive therapy might control or even revert the prothrombotic state seen in Behcet's disease.⁽⁷⁻⁹⁾ Another interesting case,

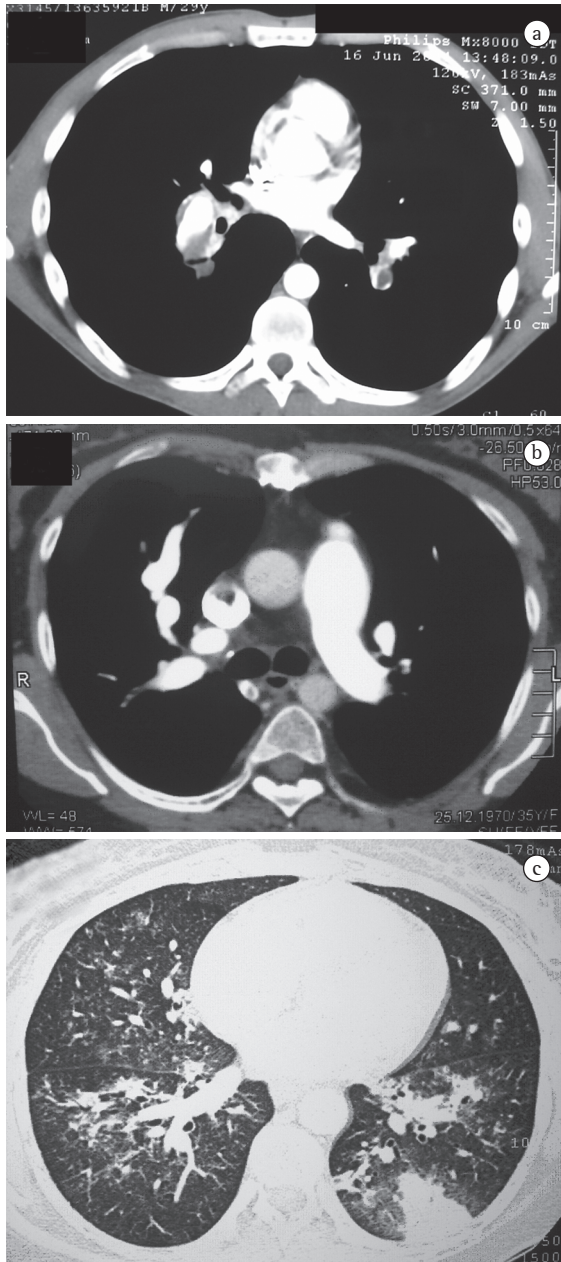


Figure 2 - a) Patient 5: contrast material-enhanced computed tomography scan revealing bilateral pulmonary artery aneurysms with thrombi; b) patient 9: contrast material-enhanced computed tomography scan showing pulmonary artery aneurysm (right lung) and enlargement of the pulmonary trunk with a maximum diameter of 34 mm, indicating pulmonary hypertension; c) patient 6: high-resolution computed tomography demonstrating bilateral ground-glass opacities (consistent with alveolar hemorrhage), and pleural-based wedge-shaped pulmonary consolidation (consistent with pulmonary infarction due to pulmonary embolism).

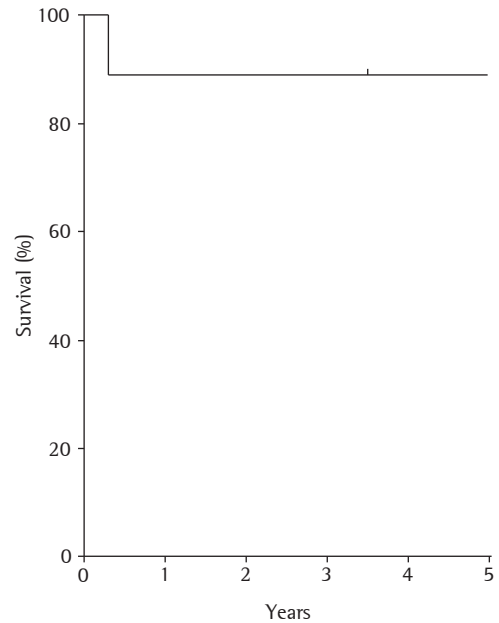


Figure 3 - Survival of nine patients with Behcet's disease-related pulmonary involvement (one patient was censored).

patient 9, had Behcet's disease-related pulmonary hypertension, which has rarely been described in the literature.⁽¹⁰⁾ To our knowledge, this patient represents the first case described in the English literature (PubMed) in which Behcet's disease-related pulmonary hypertension presented a good response to the treatment with mycophenolate mofetil, sildenafil and warfarin, as previously described for other rheumatologic diseases.⁽¹¹⁻¹⁶⁾

Our study had certain limitations. For instance, the retrospective nature of the study might limit the strength of our conclusions. However, the main limitation was the relatively small sample size, which increases the possibility of biases and might have influenced our results. However, the subgroup analysis in the study previously cited corroborates our data.⁽⁶⁾ In addition, small sample size is a problem inherent to studies of rare manifestations of low-prevalence diseases.^(4,5,17,18)

In summary, patients with Behcet's disease-related pulmonary involvement can present good survival with appropriate immunosuppressive therapy. In addition, Behcet's disease must be recalled as a cause of alveolar hemorrhage and pulmonary hypertension.

References

1. Criteria for diagnosis of Behçet's disease. International Study Group for Behçet's Disease. *Lancet*. 1990;335(8697):1078-80.
2. Barbas CS, Barros JM, Santana AN. Other forms of pulmonary vasculitis. *J Bras Pneumol*. 2005;31(Suppl. 1):S32-S35.
3. Hamuryudan V, Yurdakul S, Moral F, Numan F, Tüzün H, Tüzüner N, et al. Pulmonary arterial aneurysms in Behçet's syndrome: a report of 24 cases. *Br J Rheumatol*. 1994;33(1):48-51.
4. Tunaci M, Ozkorkmaz B, Tunaci A, Gül A, Engin G, Acunaş B. CT findings of pulmonary artery aneurysms during treatment for Behçet's disease. *AJR Am J Roentgenol*. 1999;172(3):729-33.
5. Ahn JM, Im JG, Ryoo JW, Kim SJ, Do YS, Choi YW, et al. Thoracic manifestations of Behçet syndrome: radiographic and CT findings in nine patients. *Radiology*. 1995;194(1):199-203.
6. Uzun O, Akpolat T, Erkan L. Pulmonary vasculitis in behcet disease: a cumulative analysis. *Chest*. 2005;127(6):2243-53.
7. Santana AN, Antunes T, Barbas CS. Treatment of ANCA-associated vasculitis. *JAMA*. 2007;298(23):2739; author reply 2740.
8. Kiraz S, Ertenli I, Oztürk MA, Haznedaroğlu IC, Celik I, Calgüneri M. Pathological haemostasis and "prothrombotic state" in Behçet's disease. *Thromb Res*. 2002;105(2):125-33.
9. Akarsu M, Demirkan F, Ozsan GH, Onen F, Yüksel F, Ozkan S, et al. Increased levels of tissue factor pathway inhibitor may reflect disease activity and play a role in thrombotic tendency in Behçet's disease. *Am J Hematol*. 2001;68(4):225-30.
10. Tănăseanu S, Tănăseanu C, Pompilian V, Badea C. Clinical particularities in a Romanian series of Behçet's disease patients. *Rom J Intern Med*. 2003;41(1):41-51.
11. Sanchez O, Sitbon O, Jaïs X, Simonneau G, Humbert M. Immunosuppressive therapy in connective tissue diseases-associated pulmonary arterial hypertension. *Chest*. 2006;130(1):182-9.
12. Pulmonary hypertension and systemic sclerosis. *J Bras Pneumol*. 2005;31(Suppl. 2):S24-S27.
13. Coghlan JG, Handler C. Connective tissue associated pulmonary arterial hypertension. *Lupus*. 2006;15(3):138-42.
14. Liu C, Liu K, Ji Z, Liu G. Treatments for pulmonary arterial hypertension. *Respir Med*. 2006;100(5):765-74.
15. van Wolferen SA, Grünberg K, Vonk Noordegraaf A. Diagnosis and management of pulmonary hypertension over the past 100 years. *Respir Med*. 2007;101(3):389-98.
16. Reichenberger F, Mainwood A, Doughty N, Fineberg A, Morrell NW, Pepke-Zaba J. Effects of nebulised iloprost on pulmonary function and gas exchange in severe pulmonary hypertension. *Respir Med*. 2007;101(2):217-22.
17. Yassine N, el Meziane A, Alaoui-Yazidi A, Bartal M. [Aneurysms of the pulmonary artery in Behçet disease. Apropos of 5 new cases][Article in French]. *Rev Pneumol Clin*. 1997;53(1):42-8.
18. Samano MN, Ladeira RT, Meireles LP, Pego-Fernades PM. Aneurisma de artéria pulmonar como manifestação da doença de Behçet. *J Pneumol*. 2002; 28(3):150-4.