

Case Report

Primary complex of paracoccidioidomycosis and hypereosinophilia*

Complexo primário da paracoccidioidomicose e hipereosinofilia

Roberto Martinez, Maria Janete Moya

Abstract

Primary infection with *Paracoccidioides brasiliensis* has rarely been observed. A 28-year-old male patient presented with a three-month history of fever, respiratory symptoms and malaise. Chest X-rays revealed bilateral apical infiltrates, right pleuritis and hilar lymphadenomegaly. The patient presented with leukocytosis, severe eosinophilia and increasing titers of anti-*P. brasiliensis* antibodies in serum. To our knowledge, this is the first report of the primary pulmonary lymph node complex of paracoccidioidomycosis accompanied by hypereosinophilia and affecting a previously healthy adult.

Keywords: Paracoccidioidomycosis; Eosinophilia; Lung diseases, fungal.

Resumo

A infecção primária por *Paracoccidioides brasiliensis* é observada raramente. Um paciente masculino de 28 anos de idade apresentou febre, sintomas respiratórios e indisposição durante três meses. Exames radiológicos evidenciaram infiltrado pulmonar apical bilateral, pleurite à direita e linfadenomegalia hilar. O paciente apresentava leucocitose, intensa eosinofilia e títulos crescentes de anticorpos séricos anti-*P. brasiliensis*. Até onde sabemos, este é o primeiro relato do complexo primário da paracoccidioidomicose, associado com hipereosinofilia, apresentado por um adulto previamente hígido.

Descritores: Paracoccidioidomicose; Eosinofilia; Pneumopatias fúngicas.

Introduction

Infection with *Paracoccidioides brasiliensis* is acquired via the airways and occurs in endemic areas in South America. In most individuals, the infection resolves spontaneously, leaving a scarring lung or lymphatic injury where the fungus can remain latent.⁽¹⁾ Some of those infected develop a self-limiting disease (regressive form of paracoccidioidomycosis), which is poorly understood, or a generalized disease, which predominantly affects the lymphatic system, the macrophagic-monocytic system and the skin (acute or subacute form). In adults over 30 years of age, it is known that reactivation of latent foci of *P. brasiliensis* result in injury to the lungs, the oropharyngeal mucosa and other tissues (chronic form).⁽²⁾

The chronic form of the lung disease is progressive and, on X-rays, typically appears as bilateral diffuse reticulomicronodular interstitial infiltrate.⁽³⁾ Acute lung injury in other forms of

paracoccidioidomycosis is more poorly characterized, either due to the fact that it is uncommon in its acute or subacute form or due to the scarcity of cases of regressive forms or symptomatic infection.^(3,4)

The primary complex resulting from infection with *P. brasiliensis* has rarely been observed in children^(5,6) or in immunocompromised adults.⁽⁷⁾ Here, we report the case of a young adult who presented with lung injury, hilar lymph node enlargement and hypereosinophilia as manifestations of the initial phase of this fungal infection.

Case report

A 28-year-old white male, who was a physician and a resident of the city of Ribeirão Preto, Brazil, presented with a three-month history of daily fever (37.5–38.5°C). He also presented with intense nonproductive cough, chest pain

* Study carried out at the University of São Paulo at Ribeirão Preto School of Medicine *Hospital das Clínicas*, Ribeirão Preto, Brazil. Correspondence to: Roberto Martinez. Faculdade de Medicina de Ribeirão Preto, Departamento de Clínica Médica, Avenida Bandeirantes, 3900, CEP 14049-900, Ribeirão Preto, SP, Brasil.

Tel 55 16 3602-2468. E-mail: rmartine@fmrp.usp.br

Financial support: None.

Submitted: 19 August 2009. Accepted, after review: 16 November 2009.

in the right subscapular region, loss of appetite and malaise. The patient received a nonsteroidal anti-inflammatory drug for 10 days, and the symptoms were attenuated. With the discontinuation of the drug, the fever returned, together with headache, malaise and productive cough with yellow expectoration. The patient received amoxicillin/clavulanate, and the expectoration decreased. However, he had dry cough, loss of appetite, prostration, weakness, night sweats and irregular fever, all of which had intensified within the last few days. In addition, he had lost approximately 4 kg of body weight.

The patient worked at a hospital in the city of Ribeirão Preto, as well as working shifts in the city of São José do Rio Pardo (both cities are located in the state of São Paulo), to which he commuted once a week. He stated that he had not traveled to other regions, and that he had not been exposed to pigeons, bats, woodlands or individuals with tuberculosis. He also stated that was not a smoker, alcoholic or illicit drug user; nor did he report a history of allergies or any other disease.

Physical examination revealed that the patient presented normal respiration and mildly reduced breath sounds in the upper third of the right hemithorax, without adventitious sounds. There was enlargement (to 2 cm in diameter) of the submandibular lymph node, which was mobile and slightly painful. The liver was not palpable. The spleen was percussible but not palpable. Arterial pressure was 120/80 mmHg, and HR was 68 bpm.

A chest X-ray, performed two months after the onset of symptoms, showed bilateral apical pulmonary opacification and mild left hilar lymph node enlargement (Figure 1). Chest CT scans showed condensation in the upper third of both lungs (Figure 2), as well as left hilar lymph node enlargement and right pleuritis (Figure 3). A sinus X-ray was normal. Abdominal ultrasound revealed mild splenomegaly. Bronchoscopy revealed a normal bronchial tree.

The laboratory test results were as follows: hemoglobin, 13.9 g/dL; hematocrit, 41.8%; leukocytes, 18,900/ μ L; neutrophils, 5,103/ μ L; eosinophils, 11,321/ μ L; basophils, 170/ μ L; lymphocytes, 1,777/ μ L; monocytes, 529/ μ L; C-reactive protein, 6.9 mg/dL; tests of liver and kidney function: normal; parasitological stool examination: negative; HIV antibody testing: negative; microscopy and culture for *M. tuberculosis* in sputum (five samples) and BAL: negative; and direct examination and

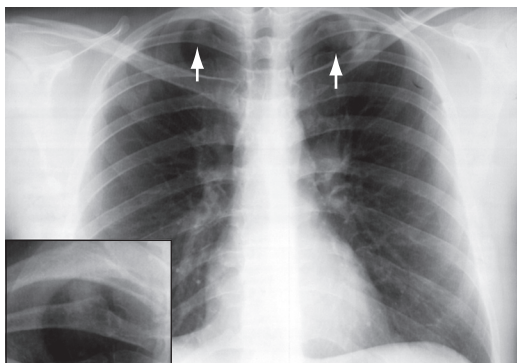


Figure 1 - Chest X-ray at two months after the onset of symptoms revealing condensation in both lung apices and mild left hilar lymph node enlargement. The insert shows the injury in the right apex.

culture for fungi in sputum (two samples) and BAL: negative. Counterimmunoelectrophoresis for antifungal serum antibodies showed the following titers: paracoccidioidomycosis, 1:64; histoplasmosis, 1:16; and aspergillosis, 1:8.

Having been diagnosed with paracoccidioidomycosis, the patient was treated with itraconazole (200 mg/day). After 7 days of therapy, his fever and cough had already subsided. On day 50 of therapy with itraconazole, the patient was asymptomatic and had gained 3 kg of body weight. In addition, the physical examination was normal. A chest X-ray performed on that day showed lungs without opacifications and normal pulmonary hila. The number of circulating eosinophils remained high until the initiation of treatment and then became normal (376/ μ L). Inversely, the titer of anti-*P. brasiliensis* antibodies in serum increased to 1:512. Cure was achieved after four months of therapy with itraconazole (100 mg/day).

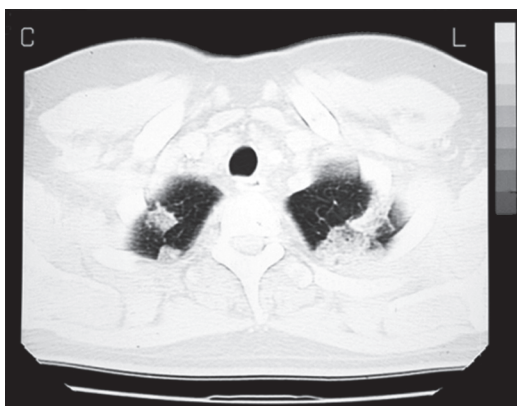

Figure 2 - Chest CT scan revealing condensation in the upper third of both lungs.

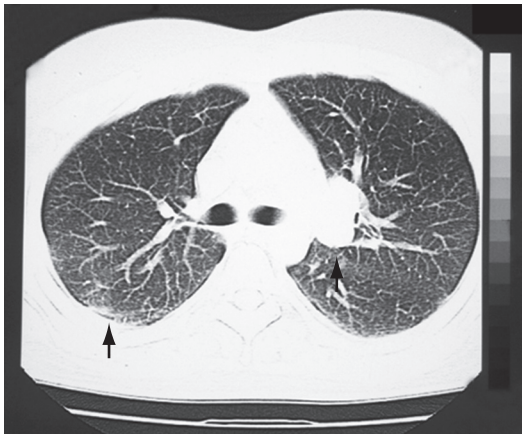

Figure 3 - Chest CT scan revealing peripheral condensation with right pleural involvement and left hilar lymph node enlargement.

Discussion

The pleuropulmonary focus and the satellite lymph node enlargement presented by the patient characterize the primary pulmonary lymph node complex of *P. brasiliensis* infection. The involvement of this fungus was revealed by the detection of serum antibodies in significant titers for paracoccidioidomycosis, there being cross-reaction with *Histoplasma capsulatum* antigens and *Aspergillus fumigatus* antigens. The marked increase in the anti-*P. brasiliensis* antibody titer in the second blood sample confirmed the diagnosis of paracoccidioidomycosis. The response to the therapy with itraconazole was immediate, and clinical and radiological cure was achieved within a few weeks of therapy. To our knowledge, this is the first report of the primary pulmonary lymph node complex of *P. brasiliensis* infection in an immunocompetent adult who also presented hyper eosinophilia.

Studies involving intradermal administration of paracoccidioidin to population samples from Brazil suggest that *P. brasiliensis* commonly causes an unapparent and nonprogressive infection.⁽⁶⁾ This subclinical infection was demonstrated by the incidental finding of residual fungal injuries in autopsies of patients whose death was caused by other diseases.⁽¹¹⁾ The finding of injury caused by *P. brasiliensis* in a few adult patients, usually asymptomatic, also shows the fungal infection that does not progress to open disease.⁽⁹⁾ Reactivation of the primary infection with *P. brasiliensis*, in the lung and in the mediastinal lymph node, was confirmed in the lung of an adult with lung carcinoma.⁽⁷⁾ The symptomatic primary pulmonary lymph node complex of *P. brasiliensis*

infection was observed in a 9-year-old child, who had alveolar consolidations in the lungs and hilar enlargement after having had respiratory symptoms for various months.⁽⁵⁾ Another child, who was 6 years old and had frequent contact with the rural environment, had high fever, mild bilateral interstitial pulmonary infiltrate and marked hilar lymphadenomegaly.⁽⁶⁾ In the following weeks, this child developed disseminated fungal disease, which led to the assumption that the initial findings represented the primary lymph node complex of *P. brasiliensis* infection.

In the case reported here, the primary focus was located in the upper thirds and in the apices of the lungs, reaching the pleura, which caused the patient to receive anti-inflammatory medication to control the chest pain. In addition to primary infection, acute lung injury caused by paracoccidioidomycosis has rarely been observed in the regressive,⁽¹⁰⁾ acute or subacute^(3,4) forms. Unlike the chronic form of the lung disease, the forms more temporally related to the fungal infection present pulmonary involvement that is heterogeneous in terms of type and location. One review of pediatric juvenile paracoccidioidomycosis included patients with alveolar consolidation, interstitial infiltrate, micronodules, nodules and pleural effusion.⁽¹¹⁾ There have also been reports of an adult who presented with cortico-pleuritis⁽¹⁾ and a young individual who had empyema and bilateral pulmonary consolidation, *P. brasiliensis* being detected in the bronchoalveolar lavage fluid.⁽³⁾ The acute injury caused by paracoccidioidomycosis can be located in the apex, the perihilar region, the juxtapleural region and the base of the lungs, or have a disseminated aspect.^(3,11) Conversely, *P. brasiliensis* was isolated from the respiratory secretion of patients with the acute or subacute form of paracoccidioidomycosis, without there being any apparent injury on chest X-rays.⁽¹²⁾ This suggests the existence of small pulmonary primary foci, not detectable on routine X-rays.

Eosinophilic pneumonia is observed in parasitic, fungal and bacterial infections, being also accompanied by hypersensitivity diseases, sarcoidosis and other less common diseases.⁽¹³⁾ Among systemic fungal infections, eosinophilia resulting from certain forms of aspergillosis and coccidioidomycosis is the most widely known. In the case reported here, it was not possible to evaluate the participation of eosinophils in the lung injury or to characterize the case as eosinophilic pneumonia. However, the patient presented persistent and marked peripheral

eosinophilia for some weeks. Mild to moderate eosinophilia is found in many patients with the chronic form of paracoccidioidomycosis. In children with acute or subacute disease, 61% and 76%, respectively, had eosinophil counts greater than 500/ μ L of blood.^(14,15) Hypereosinophilia sometimes occurs in acute or subacute paracoccidioidomycosis in children^(6,14) and in young adults.⁽¹⁶⁾ On chest X-rays, 3 of 7 children with more than 5,000 eosinophils/ μ L of blood presented pulmonary condensation or perihilar infiltrate,⁽¹⁴⁾ possibly corresponding to initial lung injury in patients with disseminated paracoccidioidomycosis. Hypereosinophilia in this disease has been attributed to high levels of cytokines, particularly IL-5, which are accompanied by Th2 cell immune response and disseminated injury.^(13,16) In the case reported here, incipient cervical lymph node enlargement and splenomegaly suggest extrapulmonary dissemination of *P. brasiliensis* and possible progression to the acute form of paracoccidioidomycosis. It is interesting that hypereosinophilia resolved rapidly with antifungal therapy, as has been observed in similar cases.⁽¹⁶⁾

Cases with initial injury caused by *P. brasiliensis* are indicators of the ecoepidemiology of paracoccidioidomycosis. The acquisition of this infection by the patient probably occurred in the journey between the cities of Ribeirão Preto e São José do Rio Pardo, both located in regions where paracoccidioidomycosis is hyperendemic. The air and the dust along the highways can contain conidia of the fungus, causing the infection through repeated exposure, as occurs with professional drivers and farm machine operators.⁽²⁾

In conclusion, paracoccidioidomycosis should be included in the differential diagnosis of acute pulmonary infections accompanied by hyper-eosinophilia in children and young adults living in endemic regions. Lung injury in such patients, even if atypical, can correspond to primary infection with *P. brasiliensis*. Considering the difficulty in isolating the agent in this initial phase, serological screening with fungal antigens can be useful in establishing the diagnosis.

About the authors

Roberto Martinez

Associate Professor. Department of Clinical Medicine, University of São Paulo at Ribeirão Preto School of Medicine, Ribeirão Preto, Brazil.

Maria Janete Moya

Supervising Physician. Department of Infectious Diseases, University of São Paulo at Ribeirão Preto School of Medicine Hospital das Clínicas, Ribeirão Preto, Brazil.

References

1. Negroni R. Pathogenesis. In: Franco M, Lacaz CS, Restrepo-Moreno A, Del Negro G, editors. Paracoccidioidomycosis. Boca Raton: CRC Press; 1994. p. 203-12.
2. Martinez R. Paracoccidioidomycose. In: Sidrim JJC, Rocha MFG, editors. Micologia Médica à Luz de Autores Contemporâneos. Rio de Janeiro: Guanabara Koogan; 2004. p. 204-21.
3. Londero AT. Paracoccidioidomycose. Patogenia, formas clínicas, manifestações pulmonares e diagnóstico. J Pneumol. 1986;12(1):41-57.
4. Restrepo A, Benard G, de Castro CC, Agudelo CA, Tobón AM. Pulmonary paracoccidioidomycosis. Semin Respir Crit Care Med. 2008;29(2):182-97.
5. Ramos CD, Londero AT, Gal MC. Pulmonary paracoccidioidomycosis in a nine year old girl. Mycopathologia. 1981;74(1):15-8.
6. Campos EP, Bertioli CJ, Barbosa KS. Linfonodo pulmonar na paracoccidioidomycose aguda infantil (relato de um caso). Rev Soc Bras Med Trop. 1992;25(3):195-200.
7. Severo LC, Geyer GR, Londero AT, Porto NS, Rizzon CFC. The primary pulmonary lymph node complex in paracoccidioidomycosis. Mycopathologia. 1979;67(2):115-8.
8. Fava S di C, Netto CF. Epidemiologic surveys of histoplasmin and paracoccidioidin sensitivity in Brazil. Rev Inst Med Trop Sao Paulo. 1998;40(3):155-64.
9. dos Santos JW, Michel GT, Londero AT. Paracoccidioidoma: case record and review. Mycopathologia. 1997;137(2):83-5.
10. López R, Restrepo A. Spontaneous regression of pulmonary paracoccidioidomycosis. Report of a case. Mycopathologia. 1983;83(3):187-9.
11. Londero AT, Melo IS. Paracoccidioidomycosis in childhood. A critical review. Mycopathologia. 1983;82(1):49-55.
12. Restrepo A, Trujillo M, Gomez I. Inapparent lung involvement in patients with the subacute juvenile type of paracoccidioidomycosis. Rev Inst Med Trop Sao Paulo. 1989;31(1):18-22.
13. Campos LE, Pereira LF. Pulmonary eosinophilia. J Bras Pneumol. 2009;35(6):561-73.
14. Gonçalves AJR, Terra GMF, Rozenbaum R, Nogueira SA, Abreu TF, Caiubi MJ, et al. A eosinofilia na paracoccidioidomycose infantil. Arq Bras Med. 1999;73(1/2):13-21.
15. Pereira RM, Bucarety F, Barison Ede M, Hessel G, Tresoldi AT. Paracoccidioidomycosis in children: clinical presentation, follow-up and outcome. Rev Inst Med Trop Sao Paulo. 2004;46(3):127-31.
16. Shikanai-Yasuda MA, Higaki Y, Uip DE, Mori NS, Del Negro G, Melo NT, et al. Comprometimento da medula óssea e eosinofilia na paracoccidioidomycose. Rev Inst Med Trop Sao Paulo. 1992;34(2):85-90.