

Letter to the Editor

Pulmonary cryptosporidiosis in AIDS patients, an underdiagnosed disease

Criptosporidiose pulmonar em pacientes com AIDS,
uma doença subdiagnosticada

Yvana Maria Maia de Albuquerque, Márcia Cristina Fraga Silva,
Ana Luiza Magalhães de Andrade Lima, Vera Magalhães

To the Editor:

Cryptosporidiosis is an infection caused by a protozoan (*Cryptosporidium spp.*) that infects the epithelial cells of the gastrointestinal tract of humans and animals.⁽¹⁾

Clinical manifestations depend on the immune status of the patient. In immunocompetent patients, cryptosporidiosis causes episodes of self-limiting diarrhea, especially in children in Latin America. In AIDS patients with advanced immunodeficiency, cryptosporidiosis is the most common parasitic cause of prolonged diarrhea, associated with pronounced weight loss, and can progress to severe dehydration and electrolyte disturbance.^(1,2)

In the pre-antiretroviral therapy (ART) era, intestinal cryptosporidiosis was responsible for diarrheal symptoms in 10–30% of AIDS patients in developed countries and in 30–50% of those in developing countries.⁽³⁾ Currently, in developed countries in which the rates of environmental contamination are low and in which potent ART is widely available, intestinal cryptosporidiosis occurs at an incidence rate of < 1 per 100 person-years among AIDS patients.⁽⁴⁾

Pulmonary impairment is a rare complication of intestinal cryptosporidiosis, having been reported in immunocompromised patients, most of whom have AIDS and severe immunodeficiency.⁽²⁾ The prevalence of pulmonary cryptosporidiosis, however, might be underestimated, given that it is not systematically investigated.⁽⁵⁾ In a retrospective study conducted in Spain and investigating 275 AIDS patients, 43 had enteritis caused by *Cryptosporidium spp.*; in 7 of those 43 patients, sputum examination identified *Cryptosporidium spp.* oocysts.⁽³⁾

The pathogenesis of pulmonary cryptosporidiosis has yet to be fully clarified.^(2,6) The possibility that pulmonary involvement is due to inhalation of oocysts during an episode

of vomiting or results from hematogenous dissemination has been a point of discussion.⁽²⁾ Although *Cryptosporidium* oocysts do not usually invade the intestinal mucosa, they have been found within macrophages, leading to reduced phagocytic ability. In addition, this parasite can multiply in macrophages in vitro, which suggests that extraintestinal parasites spread via circulating phagocytes.⁽⁷⁾ This hypothesis is supported by the presence of *Cryptosporidium spp.* within the blood vessels in the intestinal and pulmonary submucosa, as revealed by autopsy studies.^(2,7)

The clinical manifestations of pulmonary cryptosporidiosis are nonspecific and typically include chronic cough, fever, and dyspnea as the most common symptoms, and radiological changes may or may not occur.⁽²⁾ Although there have been no reports of pathognomonic radiological findings in pulmonary cryptosporidiosis, interstitial opacity has been described in some case reports.^(2,3,7,8)

In a survey conducted in referral hospitals for the treatment of HIV/AIDS patients with clinically suspected pulmonary tuberculosis in the city of Recife, Brazil, *Cryptosporidium spp.* was the only agent identified in 2 (1.5%) of the 130 sputum examinations performed during the survey period; diagnosis was based on the finding of *Cryptosporidium spp.* oocysts on Ziehl-Neelsen-stained sputum smear (Figure 1). In both cases, the patients had evening fever, cough, weight loss, and general malaise, all of which were suggestive of pulmonary tuberculosis. In the 2 cases studied, the patients were severely immunocompromised, with very low CD4+ T-cell counts (25 and 37 cells/ μ L). Although the presence of *Pneumocystis jirovecii* was not investigated, sulfamethoxazole-trimethoprim was prescribed for prophylaxis against that agent. Both patients had recently been diagnosed with AIDS. Only one of the patients was initially suspected

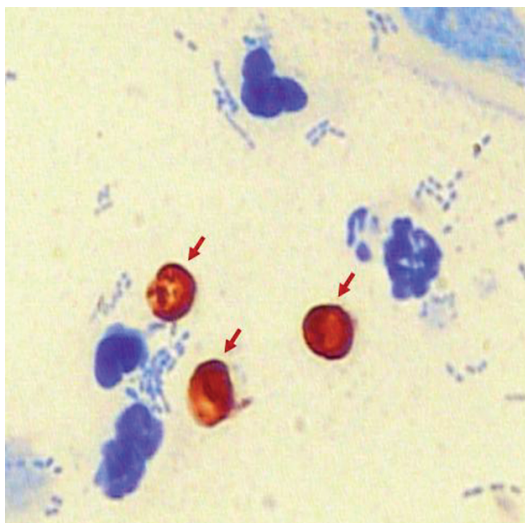


Figure 1 – Ziehl-Neelsen-stained sputum smear showing *Cryptosporidium* spp. oocysts (red arrows). Source: Image database of the researcher.

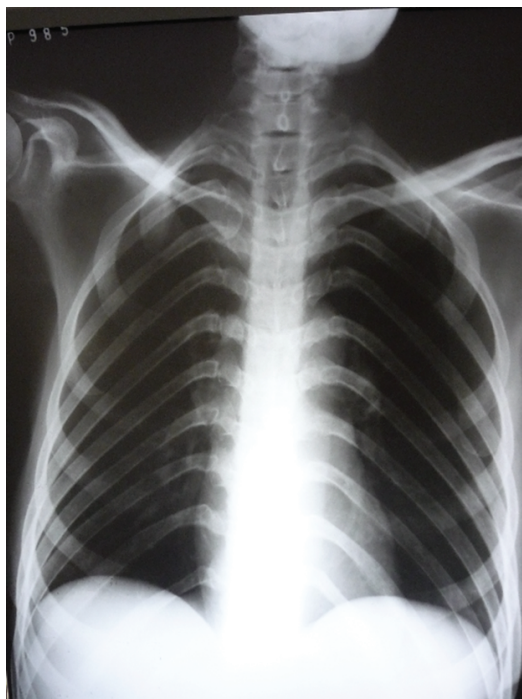


Figure 2 – Chest X-ray of a patient with AIDS/pulmonary cryptosporidiosis, showing normal radiological findings. Source: Image database of the researcher.

of having intestinal cryptosporidiosis (which was confirmed by stool examination for ova and parasites), whereas the other had clinical signs suggestive of pulmonary tuberculosis but no digestive complaints. Chest X-ray findings (Figure 2) were normal in the 2 patients. Sputum culture (on Löwenstein-Jensen medium and in Middlebrook 7H9 medium) yielded no bacterial growth.

The patients showed progressive clinical, immunological, and virological improvement after ART initiation. There is no specific drug with proven efficacy in the treatment of cryptosporidiosis, and clinical improvement is related to the immune status of the patient.⁽²⁾

We emphasize the need for investigating this parasitosis in AIDS patients with clinically suspected pulmonary tuberculosis, especially in those with prolonged diarrhea.

Acknowledgments

The authors would like to thank the Marcelo Magalhães Laboratory for the support in performing sputum examinations.

Yvana Maria Maia de Albuquerque
 Infectious Disease Physician,
 Correia Picanço Hospital, Pernambuco
 State Department of Health,
 Recife, Brazil

Márcia Cristina Fraga Silva
 Infectious Disease Physician,
 Correia Picanço Hospital, Pernambuco
 State Department of Health,
 Recife, Brazil

Ana Luiza Magalhães de Andrade Lima
 Medical Student, Pernambuco
 State School of Health,
 Recife, Brazil

Vera Magalhães
 Full Professor of Infectious Diseases,
 Federal University of Pernambuco,
 Recife, Brazil

References

1. Vergara Castiblanco C, Santos Núñez S, Freire Santos F, Ares Mazás E. Cryptosporidiosis in the Andean region of Colombia: seroprevalence and recognition of antigens [Article in Spanish]. *Rev Panam Salud Publica*. 2000;8(6):373-9. <http://dx.doi.org/10.1590/S1020-4989200001100001>
2. Corti M, Villafañe MF, Muzzio E, Bava J, Abuin JC, Palmieri OJ. Pulmonary cryptosporidiosis in AIDS patients [Article

- in Spanish]. *Rev Argent Microbiol.* 2008;40(2):106-8. PMID:18705491.
3. López-Vélez R, Tarazona R, Garcia Camacho A, Gomez-Mampaso E, Guerrero A, Moreira V, et al. Intestinal and extraintestinal cryptosporidiosis in AIDS patients. *Eur J Clin Microbiol Infect Dis.* 1995;14(8):677-81. PMID:6756909. <http://dx.doi.org/10.1007/BF01690873>
 4. Bonasser Filho F. Manifestações Gastrointestinais. In: Veronesi R, editor. *Tratado de infectologia.* São Paulo: Atheneu; 2002. p. 208-12.
 5. Meamar AR, Rezaian M, Rezaie S, Mohraz M, Kia EB, Hought ER, et al. *Cryptosporidium parvum* bovine genotype oocysts in the respiratory samples of an AIDS patient: efficacy of treatment with a combination of azithromycin and paromomycin. *Parasitol Res.* 2006;98(6):593-5. PMID:16416289. <http://dx.doi.org/10.1007/s00436-005-0097-4>
 6. Poirot JL, Deluol AM, Antoine M, Heyer F, Cadranet J, Meynard JL, et al. Broncho-pulmonary cryptosporidiosis in four HIV-infected patients. *J Eukaryot Microbiol.* 1996;43(5):78S-79S. PMID:8822872. <http://dx.doi.org/10.1111/j.1550-7408.1996.tb05007.x>
 7. Dupont C, Bougnoux ME, Turner L, Rouveix E, Dorra M. Microbiological findings about pulmonary cryptosporidiosis in two AIDS patients. *J Clin Microbiol.* 1996;34(1):227-9. PMID:8748314 PMCID:228771.
 8. Palmieri F, Cicalini S, Froio N, Rizzi EB, Goletti D, Festa A, et al. Pulmonary cryptosporidiosis in an AIDS patient: successful treatment with paromomycin plus azithromycin. *Int J STD AIDS.* 2005;16(7):515-7. <http://dx.doi.org/10.1258/0956462054308332>