

## Maternal malnutrition during lactation in Wistar rats: effects on elastic fibers of the extracellular matrix in the trachea of offspring<sup>\*,\*\*</sup>

Desnutrição materna durante a lactação em ratos Wistar: efeitos sobre as fibras elásticas da matriz extracelular na traqueia dos filhotes

Filipe Moreira de Andrade, Luiz Felipe Judice, Gilberto Perez Cardoso, Rafael Cisne, Cristiane da Fonte Ramos, Marcio Antonio Babinski

### Abstract

**Objective:** To investigate the effects of maternal protein malnutrition during lactation on the elastic fibers in the tracheas of Wistar rat pups. **Methods:** At delivery, 12 male pups of two Wistar rat dams were equally divided into two groups: control, in which the dam received water and standard rat chow ad libitum during lactation; and protein-restricted (PR), in which the dam received water ad libitum and an isoenergetic PR diet (8% protein). At 21 days of age, the pups were killed and their tracheas were excised. The elastic fibers were stained with Weigert's resorcin-fuchsin (after oxidation) and evaluated under light microscopy. Morphometric determinations were performed by stereology, with the point-counting method, and expressed as volumetric densities. **Results:** Elastic fibers, most having a longitudinal distribution, were identified beneath the tracheal mucosa. In addition, well-defined circular layers of elastic fibers were found around the inner and outer surfaces of the cartilaginous ring. There were no differences between the groups regarding the organization and distribution of the elastic fibers. The volumetric density of the elastic fibers of the pups in the control and PR groups was  $2.46 \pm 0.99\%$  and  $3.25 \pm 1.13\%$ , respectively ( $p < 0.01$ ). **Conclusions:** The volumetric density of elastic fibers appears to be greater in rat pups breastfed by dams receiving a PR diet than in those breastfed by dams receiving a normal diet.

**Keywords:** Trachea/growth and development; Trachea/anatomy and histology; Extracellular matrix; Airway remodeling; Malnutrition.

### Resumo

**Objetivo:** Investigar os efeitos da desnutrição proteica materna durante a lactação sobre as fibras elásticas da traqueia de filhotes de ratos Wistar. **Métodos:** Ao nascimento, 12 filhotes machos de duas ratas Wistar foram igualmente divididos em dois grupos: grupo controle, cuja mãe recebeu água e dieta padrão de laboratório ad libitum durante a lactação, e grupo restrição proteica (RP), cuja mãe recebeu água ad libitum e dieta isoenergética com RP (8% de proteína). Aos 21 dias de vida, os filhotes foram sacrificados, e suas traqueias foram ressecadas. As fibras elásticas foram coradas pelo método de resorcina-fucsina de Weigert (precedido de oxidação) e avaliadas sob microscopia óptica. As determinações morfométricas foram feitas por estereologia, utilizando o método de contagem de pontos, e expressas em densidade volumétrica. **Resultados:** As fibras elásticas foram identificadas abaixo da mucosa traqueal, sendo a maioria em distribuição longitudinal. Além disso, camadas circulares bem definidas de fibras elásticas envolviam as superfícies interna e externa do anel cartilaginoso. Não houve diferenças entre os grupos quanto à organização e distribuição das fibras elásticas. A densidade volumétrica das fibras elásticas dos filhotes nos grupos controle e RP foi de, respectivamente,  $2,46 \pm 0,99\%$  e  $3,25 \pm 1,13\%$  ( $p < 0,01$ ). **Conclusões:** Nossos resultados sugerem que a densidade volumétrica de fibras elásticas é maior em filhotes de ratos alimentados por fêmeas submetidas a dieta com RP do que naqueles de mães recebendo dieta normal.

**Descritores:** Traqueia/crescimento e desenvolvimento; Traqueia/anatomia e histologia; Matriz extracelular; Remodelação das vias aéreas; Desnutrição.

\* Study carried out in the Department of Surgery, Division of Thoracic Surgery. Antonio Pedro University Hospital, Fluminense Federal University, Niterói, Brazil.

Correspondence to: Filipe Moreira de Andrade. Rua Visconde do Rio Branco, 755/812, Centro, CEP 24020-006, Niterói, RJ, Brasil. Tel. 55 21 9500-1503. Fax: 55 21 3628-5795. E-mail: filipeandrade\_torax@hotmail.com

Financial support: None.

Submitted: 7 March 2012. Accepted, after review: 3 July 2012.

\*\*A versão completa em português deste artigo está disponível em [www.jornaldepneumologia.com.br](http://www.jornaldepneumologia.com.br)

## Introduction

Malnutrition is the most prevalent form of nutritional disorder among children in developing countries. In hospitalized patients, the reported prevalence of malnutrition is as high as 75%.<sup>(1,2)</sup> In addition, hospitalization further worsens the nutritional status. Malnutrition has been associated with increases in the risk of in-hospital morbidity/mortality, the length of hospital stay, the costs, and the use of health care resources.<sup>(3)</sup> Therefore, studying malnutrition is relevant and timely.

Some investigators have shown that the nutritional status of the mother during gestation and lactation is essential to normal growth and development in humans and in experimental animals.<sup>(4,5)</sup> Previous studies have shown that maternal malnutrition during lactation might change milk composition, serum hormone levels in pups at weaning, and the reproductive system in females. Interestingly, some of these changes can persist into adulthood.<sup>(6)</sup>

The rat has long been used as a model when studying the human respiratory tract and major airway diseases. The composition of the elastic fibers in the tracheas of rats is similar to that of those in the tracheas of humans.<sup>(7)</sup> In addition, the rat is considered a good model for nutritional research.<sup>(5)</sup>

Few studies have focused on the morphology of the trachea, especially regarding its extracellular matrix and elastic fibers.<sup>(7,8)</sup> Although considerable attention has been given to the elastic properties of the lung and chest wall, there have been no studies investigating the elastic network of the major airways.<sup>(9)</sup> We consider that the lack of studies on this topic is relevant, since procedures involving the trachea and the airways are emerging and becoming more complex. Tracheal resection with anastomosis, the utilization of a wide range of airway stents, and, recently, the attempts at tracheal transplantation and replacement with allografts<sup>(10-12)</sup> make it essential to improve the understanding of the extracellular matrix. In addition, the effects of protein malnutrition on tracheal histology are worth studying, given the prevalence of this condition in hospitalized patients, especially in those in developing countries.<sup>(1,3,6)</sup>

An understanding of the effects of protein malnutrition on the elastic fibers in the tracheas of rats might improve the scientific knowledge base on the composition and organization of

the extracellular matrix in this organ. Studies of tracheal transplantation and tracheal replacement with aortic allografts have demonstrated that the development of mature respiratory epithelium and newly formed cartilage occurs in the extracellular matrix, particularly amid the elastic fibers.<sup>(10,11)</sup> This finding supports the key roles of the extracellular matrix and elastic fibers in the healing process. The objective of present study was to investigate the effects of maternal protein malnutrition during lactation on the elastic fibers in the tracheas of Wistar rat pups. In our analysis, we characterized and quantified the elastic fibers in the trachea. Our quantitative analyses focused on volumetric density determination by stereological methods.<sup>(13)</sup>

## Methods

The study design and experimental protocols were approved by the Animal Care and Use Committee of the Fluminense Federal University, located in the city of Niterói, Brazil, and were in accordance with the American Physiological Society guidelines.<sup>(14)</sup> The experiments described herein were performed in accordance with the guidelines of the Brazilian College for Animal Experimentation.<sup>(15)</sup>

Wistar rats obtained from the Experimental Morphology Laboratory of the Fluminense Federal University were housed at  $25 \pm 1^\circ\text{C}$  on a 12/12-h light/dark cycle (lights on from 7:00 a.m. to 7:00 p.m.) throughout the experiment. Two three-month-old virgin female rats were housed in individual cages with two male rats, at a proportion of 1:1. After mating, each female was placed in an individual cage. The two females had a normal pregnancy, having received food and water *ad libitum* until delivery. All of the pups were born in good health.

At delivery, one of the Wistar rat dams—the control dam—was started on water and standard rat chow *ad libitum* and the other—the protein-restricted (PR) dam—was started on water *ad libitum* and an isoenergetic PR diet during that period. The quantity of diet that the PR dam received each day was calculated on the basis of the mean intake by the control dam in order to prevent the PR dam from “compensating” for the reduced protein intake by ingesting a greater quantity of the diet.<sup>(5)</sup>

The low-protein diet was prepared in our laboratory, and its composition is shown in Table 1. This diet has been used in previous studies.<sup>(5)</sup> The

vitamin and mineral mixtures were formulated in order to meet the American Institute of Nutrition AIN-93G recommendations for rodent diets.<sup>(16)</sup> In order to evaluate the nutritional status, the body weight of the pups and dams were monitored throughout the experiment. Twenty-four hours after birth, excess pups were removed in order to reduce the size of each litter (group) to six, since this procedure maximizes lactation.<sup>(5,7)</sup> At delivery, the PR diet started to be offered to the PR dam, this having been defined as lactation day 0 (D0). At 21 days of age (weaning), all pups were killed with an overdose of sodium pentobarbital (0.15 mL/100 g of body weight) in the morning and perfused through the left ventricle with PBS, followed by a formalin solution.

After perfusion, the tracheas were dissected from the adjacent structures, excised, fixed in a solution of 4% formalin in 0.1 mol/L PBS (pH 7.4) for 24 h at room temperature, processed in accordance with routine histological methods, and embedded in paraffin. From the paraffin-embedded samples, 5-µm-thick sections were initially stained with H&E in order to confirm sample adequacy. Weigert’s resorcin-fuchsin, preceded by oxidation with potassium peroxymonosulfuric acid (Oxone®), was used for the demonstration and evaluation of elastic fibers, which were stained violet, producing a sharp contrast.

**Table 1** – Diet composition for the control dam and protein-restricted dams.

Variable	Control <sup>a</sup>	Protein-restricted <sup>bc</sup>
Total protein, g/kg <sup>e</sup>	230.0	80.0
Corn starch, g/kg	676.0	826.0
Soybean oil, g/kg	50.0	50.0
Vitamin mixture, g/kg <sup>d</sup>	4.0	4.0
Mineral mixture, g/kg <sup>d</sup>	40.0	40.0
Macronutrient composition, %		
Protein	23.0	8.0
Carbohydrate	66.0	81.0
Fat	11.0	11.0
Total energy, kJ/kg	17,038.7	17,038.7

<sup>a</sup>Standard rat chow (Nuvilab-Nuvital Ltd., Curitiba, Brazil).

<sup>b</sup>The protein-restricted diet was prepared in our laboratory by replacing part of the protein content of the control diet with corn starch. The amount of starch was calculated to provide the same energy content as that provided by the control diet. <sup>c</sup>The main protein sources were soy, wheat, beef, fish, and amino acids. <sup>d</sup>Vitamin and mineral mixtures were formulated to meet the American Institute of Nutrition AIN-93G recommendations for rodent diets.<sup>(16)</sup>

From each specimen, five tissue sections were analyzed, and from each section, five random fields were evaluated; therefore, we analyzed 25 test areas for each individual. The analyzed fields were digitized using a video camera coupled to a light microscope, with a final magnification of ×400. The quantification was carried out by using a specific test grid system (M42) on the digitized fields on the screen of a color monitor. The volume density of the histological components was calculated by the following formula:

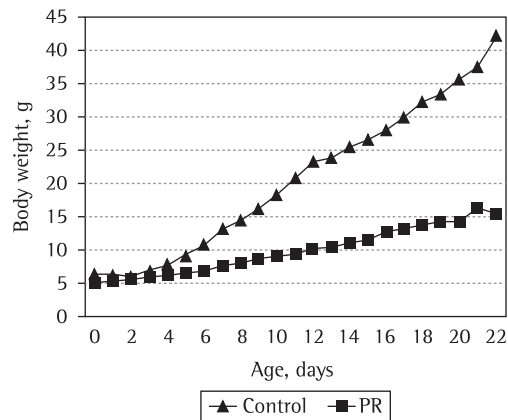
$$Vv = Pp/Pt$$

where *Vv* is the volume density, *p* is the tissue component to be taken into consideration, *Pp* is the number of test points associated with *p*, and *Pt* is the number of points of the test system. The stereological methods employed have been described in detail elsewhere.<sup>(7,13)</sup>

The data are expressed as mean ± SD, with the respective 95% CIs. The Mann-Whitney test was used in order to compare the results between the groups. We used the program GraphPad Prism, version 4 (GraphPad Inc., San Diego, CA, USA).

## Results

The body weight gain of the pups throughout the study is depicted in Figure 1. At the end of the study (D21), the body weight of the pups of the PR dam (PR group) was approximately 61% lower than was that of those of the control dam (control group; *p* < 0.01). The body weight of the PR dam at D21 was approximately 37% lower than was that of the control dam (*p* < 0.01).

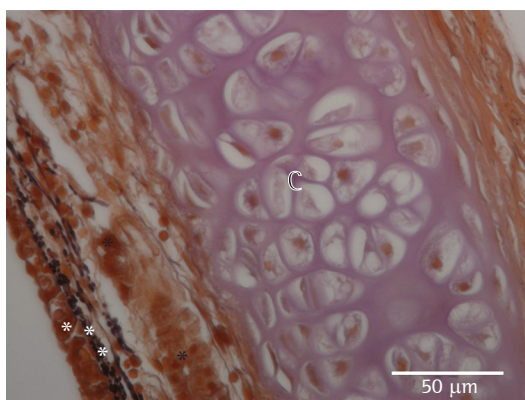


**Figure 1** – Body weight gain of the rat pups in the control and protein-restricted (PR) groups, sacrificed at 21 days of age (*p* < 0.01).

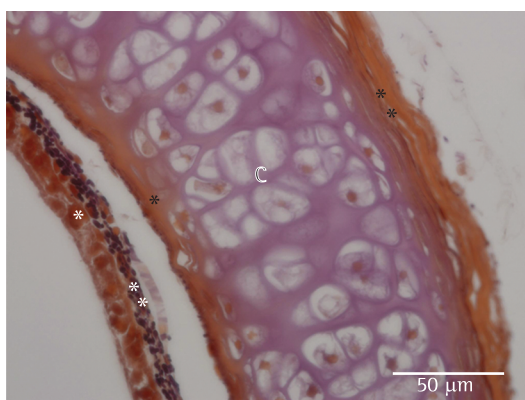
Elastic fibers, most having a longitudinal distribution, were identified beneath the tracheal mucosa, in both groups. Bundles of oblique fibers were found in this region, forming an irregular network of elastic tissue (Figure 2). In close contact with the inner surface of the cartilaginous ring, a well-defined and organized circular layer was present, surrounding the cartilage (Figure 3). Outside the cartilaginous rings, the elastic fibers were exclusively arranged in a circular

layer, following the circular cartilaginous rings (Figure 3). In that topography, there was no longitudinal or oblique arrangement of elastic fibers. There were no differences between the groups regarding the organization and distribution of the elastic fibers in the trachea.

Regarding quantitative stereological analysis, our study revealed that the volumetric density of the elastic fibers of the pups in the control and PR groups was  $2.46 \pm 0.99\%$  (95% CI: 2.05-2.87;  $p < 0.01$ ) and  $3.25 \pm 1.13$  (95% CI: 2.78-3.71;  $p < 0.01$ ), respectively. A comparison of the volumetric density between the groups is shown in Figure 4.



**Figure 2** - Photomicrograph of a tracheal section showing the epithelium (single white asterisk) and the basal layer (double white asterisks). Note the longitudinal distribution of elastic fibers beneath the basal layer (black asterisks), with a few oblique bundles (Weigert's resorcin-fuchsin; magnification,  $\times 600$ ). C: cartilage.

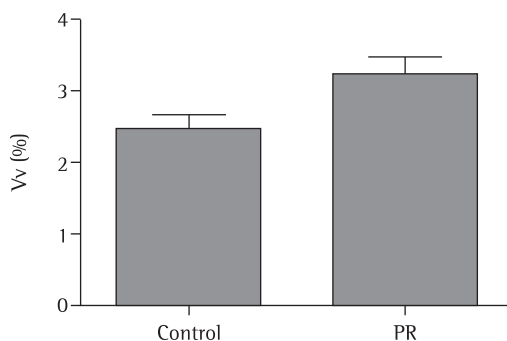


**Figure 3** - Photomicrograph of a tracheal segment showing the epithelium (single white asterisk) and the basal layer (double white asterisks). A circular layer of elastic fibers is in close contact with the inner surface of the cartilaginous ring (single black asterisk). Outside the cartilage (C), there is a single circular layer (double black asterisks) of elastic fibers (Weigert's resorcin-fuchsin; magnification,  $\times 600$ ).

## Discussion

Since the advent of computer-aided image analysis programs, most studies attempting to quantify linear structures have used area density.<sup>(7)</sup> These programs use the color properties of the elements (pixels) of an image in order to determine a threshold level for inclusion. However, in very thin linear structures, such as elastic fibers, the contrast between the structural elements (e.g., fibers) and the background is low; therefore, there is a high error rate when such programs are used.<sup>(7,13)</sup>

The point-counting method (stereology) used in our study has proven to be quite effective in avoiding the bias that frequently occurs when computer-based image analyses are performed. This method has been widely used in order to determine the amount of elastic fibers when analyzing the morphological composition of a tissue.<sup>(7,13)</sup> This quantification is expressed as



**Figure 4** - Volumetric density (Vv), expressed as percentage, of the elastic fibers in the tracheas of the rat pups in the control and protein-restricted (PR) groups, at 21 days of age ( $p < 0.01$ ).

the proportion of the volumetric density of the tissue that is occupied by elastic fibers.

Elastic fibers are characterized by major extensibility and elastic recoil. The location and arrangement of these fibers are related to their functionality, which reflects the mechanical properties of the local tissue.<sup>(17,18)</sup> Extensibility and elastic recoil in the human trachea are remarkably age-dependent, decreasing from a maximum of 50% in children to approximately 20% at 70 years of age.<sup>(18)</sup> Although the aging-related decrease in the elastic properties of the lungs and chest wall has been extensively studied, studies involving the elastic tissue of the major airways are still scarce.<sup>(9,18)</sup>

The importance of normal tracheal morphology is highlighted by congenital and acquired tracheal deformities, such as tracheobronchomegaly, tracheomalacia, and benign tracheal stenosis. The extracellular matrix plays a pivotal role in these remodeling processes, and the elastic fibers make a special contribution to that role.<sup>(10,11)</sup>

The objective of the present study was to evaluate the effects of a PR diet during lactation on the elastic fibers in the tracheas of Wistar rats. The Wistar rat has been by far the most used as a model for the human respiratory tract and major airway diseases. We performed a qualitative analysis of the distribution and organization of the elastic fibers (Figures 2 and 3). More importantly, we performed a quantitative evaluation (Figure 4), providing stereological data on the concentration of elastic fibers in the tracheas of the rats. The findings in the PR group were compared with those in the control group.

The nutritional status of a relevant proportion of patients undergoing surgical procedures is far from ideal, and malnutrition can affect the outcomes of such procedures.<sup>(2,3)</sup> According to previous studies, the first week of life is a critical period regarding the nutritional status, and the weight of an animal at an early age can influence the food intake and body weight of that animal for the rest of its life. Therefore, the degree of malnutrition during the fetal or neonatal period can determine the extent to which there will be recovery of the nutritional status during the periods of growth and development.<sup>(6,19)</sup>

Regarding the relationship between elastic fibers and surgical procedures involving the airways, new findings have emerged from recently attempted experiments involving tracheal

replacement in pigs.<sup>(11)</sup> In the study in question, the authors used aortic allografts to replace a tracheal segment and found that the normal aortic tissue in the allograft was replaced by a morphological structure that resembled a “new trachea”, with mature ciliated respiratory epithelium, respiratory glands, islets of cartilage, and even well-formed cartilage arches. Interestingly, this new trachea developed amid islets of elastic fibers in the extracellular matrix of the aortic allograft.<sup>(11)</sup> The extracellular matrix and the elastic fibers in particular seem to play an important role in the process of tissue regeneration and cellular ingrowth of recipient progenitor cells in the trachea.<sup>(10,11)</sup> Tracheal replacement might be an option in the future, when radical surgery for primary tracheal tumors, with resection of more than half of the tracheal length, is necessary. In one study on tissue-engineered replacement of a major airway, the authors discussed the active role of the extracellular matrix in regulating various aspects of cell biology that are essential to normal tissue function.<sup>(10)</sup> Therefore, research on the extracellular matrix of the airway is needed in order to improve the understanding of the morphological changes in this matrix during the process of inflammation and healing. In addition, experiments in the field of bioengineering have emphasized the role of elastic fibers in the development of new extracellular matrix-derived prosthetic materials, such as bioactive substrates.<sup>(10,20)</sup>

Regarding airway elastic fibers, previous studies have shown major changes related to the aging process. Age-related changes in the elastic fibers have been found beneath the epithelium of the human larynx.<sup>(18)</sup> Interestingly, there is an increase in the concentration of elastin in geriatric patients in comparison with that in young adults, although it is well known that the trachea loses its elastic properties with age.<sup>(18,21)</sup> Elastin increases continuously and progressively as individuals age. This phenomenon has also been reported to occur during the aging of the arteries and larynx, as well as regarding the extensibility of the lung.<sup>(9,21,22)</sup> Some studies have suggested that elasticity decreases in the elderly because the calcium-binding ability of elastin increases with age, although no histological changes can be detected in the elastic fibers.<sup>(21,22)</sup>

An increasing number of patients are being submitted to interventional procedures involving

the airways.<sup>(10,12,23)</sup> The nutritional status of several of these patients is abnormal; therefore, a deeper and more detailed understanding of the effects of malnutrition on the trachea is necessary. In addition, especially in developing countries, a poor socioeconomic status can lead to malnutrition during different periods of life, such as gestation, suckling, and weaning (or even later), and the effects of malnutrition on the organs might be irreversible.<sup>(2,5,6)</sup>

Figures 2 and 3 depict the qualitative evaluation of the elastic fibers in both groups of pups, which were identical. Regarding the quantitative evaluation by means of stereology, we found that the volumetric density of the elastic fibers was significantly higher in the PR group than in the control group (Figure 4). Previous studies have shown increased concentrations of elastic fibers and elastin during the aging process. Although further investigation is needed in order to establish a direct correlation between normal aging and malnutrition as an influence on the process of tissue remodeling over the lifetime of individuals, the effects of malnutrition on Wistar rats during the initial periods of life might resemble the effects of the aging process. In addition, recent advances in the field of tracheal replacement by allografts, tissue-engineered airway replacement, and the development of new extracellular matrix-derived prosthetic materials demand a better understanding of the morphology of elastic fibers in the trachea and the changes that might occur in patients submitted to invasive procedures involving the airways.<sup>(10,11,20)</sup>

In conclusion, our study showed that maternal malnutrition during lactation can affect the development of elastic fibers in the tracheas of Wistar rat pups. Our morphometric analysis by stereology (quantitative evaluation) demonstrated a significant increase in the volumetric density of elastic fibers in the rat pups breastfed by the dam receiving a PR diet, when compared with those in the control group. The organization and distribution (qualitative evaluation) of the elastic fibers in the tracheas of the rat pups were similar between the groups.

## References

1. de Onis M, Monteiro C, Akre J, Glugston G. The worldwide magnitude of protein-energy malnutrition: an overview from the WHO Global Database on Child Growth. *Bull*

- World Health Organ. 1993;71(6):703-12. PMID:8313488 PMCID:2393544.
2. Correia MI, Campos AC; ELAN Cooperative Study. Prevalence of hospital malnutrition in Latin America: the multicenter ELAN study. *Nutrition*. 2003;19(10):823-5. [http://dx.doi.org/10.1016/S0899-9007\(03\)00168-0](http://dx.doi.org/10.1016/S0899-9007(03)00168-0)
3. Naber TH, Schermer T, de Bree A, Nusteling K, Eggink L, Kruijmel JW, et al. Prevalence of malnutrition in nonsurgical hospitalized patients and its association with disease complications. *Am J Clin Nutr*. 1997;66(5):1232-9. PMID:9356543.
4. Barker DJ. In utero programming of cardiovascular disease. *Theriogenology*. 2000;53(2):555-74. [http://dx.doi.org/10.1016/S0093-691X\(99\)00258-7](http://dx.doi.org/10.1016/S0093-691X(99)00258-7)
5. Passos MC, Ramos CF, Moura EG. Short and long term effects of malnutrition in rats during lactation on the body weight of offspring. *Nutr Res* 2000;20(11):1603-12. [http://dx.doi.org/10.1016/S0271-5317\(00\)00246-3](http://dx.doi.org/10.1016/S0271-5317(00)00246-3)
6. Lucas A. Programming by early nutrition: an experimental approach. *J Nutr*. 1998;128(2 Suppl):401S-406S. PMID:9478036.
7. Andrade FM, Judice LF, Cisne R, Félix B, Mourad OM, Cardoso PG, et al. Structure and concentration of elastic system fibers in the trachea of the rat. *Int J Morphol* 2011;29(1):17-22. <http://dx.doi.org/10.4067/S0717-95022011000100002>
8. Kamel KS, Beckert LE, Stringer MD. Novel insights into the elastic and muscular components of the human trachea. *Clin Anat*. 2009;22(6):689-97. PMID:19637300. <http://dx.doi.org/10.1002/ca.20841>
9. Palecek F, Jezová E. Elastic properties of the rat respiratory system related to age. *Physiol Bohemoslov*. 1988;37(1):39-48. PMID:2967507.
10. Macchiarini P, Jungebluth P, Go T, Asnaghi MA, Rees LE, Cogan TA, et al. Clinical transplantation of a tissue-engineered airway. *Lancet*. 2008;372(9655):2023-30. [http://dx.doi.org/10.1016/S0140-6736\(08\)61598-6](http://dx.doi.org/10.1016/S0140-6736(08)61598-6)
11. Makris D, Holder-Espinasse M, Wurtz A, Seguin A, Hubert T, Jaillard S, et al. Tracheal replacement with cryopreserved allogenic aorta. *Chest*. 2010;137(1):60-7. PMID:19801581. <http://dx.doi.org/10.1378/chest.09-1275>
12. Andrade FM, Abou-Mourad OM, Judice LF, Carvalho-Filho AB, Schau B, Carvalho AC. Endotracheal inflammatory pseudotumor: the role of interventional bronchoscopy. *Ann Thorac Surg*. 2010;90(3):e36-7. PMID:20732473. <http://dx.doi.org/10.1016/j.athoracsur.2010.06.013>
13. Mandarim-de-Lacerda CA. Stereological tools in biomedical research. *An Acad Bras Cienc*. 2003;75(4):469-86. Erratum in: *An Acad Bras Cienc*. 2007;79(1):51. <http://dx.doi.org/10.1590/S0001-37652003000400006>
14. Bayne K. Revised Guide for the Care and Use of Laboratory Animals available. American Physiological Society. *Physiologist*. 1996;39(4):199, 208-11. PMID:8854724.
15. Schnaider TB. Ética e Pesquisa. *Acta Cir Bras*. 2008;23(1):107-11. PMID:18278401. <http://dx.doi.org/10.1590/S0102-86502008000100017>
16. Reeves PG, Nielsen FH, Fahey GC Jr. AIN-93 purified diets for laboratory rodents: final report of the American Institute of Nutrition ad hoc writing committee on the reformulation of the AIN-76A rodent diet. *J Nutr*. 1993;123(11):1939-51. PMID:8229312.
17. Kiely CM, Sherratt MJ, Shuttleworth CA. Elastic fibres. *J Cell Sci*. 2002;115(Pt 14):2817-28. PMID:12082143.
18. Hammond TH, Gray SD, Butler J, Zhou R, Hammond E. Age- and gender-related elastin distribution

- changes in human vocal folds. *Otolaryngol Head Neck Surg.* 1998;119(4):314-22. [http://dx.doi.org/10.1016/S0194-5998\(98\)70071-3](http://dx.doi.org/10.1016/S0194-5998(98)70071-3)
19. Alippi RM, Meta MD, Olivera MI, Bozzini C, Schneider P, Meta IF, et al. Effect of protein-energy malnutrition in early life on the dimensions and bone quality of the adult rat mandible. *Arch Oral Biol.* 2002;47(1):47-53. [http://dx.doi.org/10.1016/S0003-9969\(01\)00089-9](http://dx.doi.org/10.1016/S0003-9969(01)00089-9)
20. Conconi MT, De Coppi P, Di Liddo R, Vigolo S, Zanon GF, Parnigotto PP, et al. Tracheal matrices, obtained by a detergent-enzymatic method, support in vitro the adhesion of chondrocytes and tracheal epithelial cells. *Transpl Int.* 2005;18(6):727-34. PMID:15910302. <http://dx.doi.org/10.1111/j.1432-2277.2005.00082.x>
21. Arteaga-Solis E, Gayraud B, Ramirez F. Elastic and collagenous networks in vascular diseases. *Cell Struct Funct.* 2000;25(2):69-72. PMID:10885576 PMID:3053004. <http://dx.doi.org/10.1247/csf.25.69>
22. Kahane JC. Connective tissue changes in the larynx and their effects on voice. *J Voice.* 1987;1(1):27-30. [http://dx.doi.org/10.1016/S0892-1997\(87\)80020-6](http://dx.doi.org/10.1016/S0892-1997(87)80020-6)
23. Ferreira HP, Araújo CA, Cavalcante JF, Lima RP. Complex tracheal lesion: correction with an intercostal muscle pedicle flap. *J Bras Pneumol.* 2009;35(12):1250-3. PMID:20126929.

## ***About the authors***

---

### ***Filipe Moreira de Andrade***

Assistant Professor of Thoracic Surgery. Department of Surgery, Division of Thoracic Surgery, Fluminense Federal University, Niterói, Brazil. Visiting Professor of Thoracic Surgery. University of Alabama at Birmingham, Birmingham, AL, USA.

### ***Luiz Felipe Judice***

Full Professor of Thoracic Surgery. Department of Surgery, Division of Thoracic Surgery, Fluminense Federal University, Niterói, Brazil.

### ***Gilberto Perez Cardoso***

Full Professor of Clinical Medicine. Department of Clinical Medicine, Fluminense Federal University, Niterói, Brazil.

### ***Rafael Cisne***

Substitute Professor of Human Anatomy. Department of Morphology, Fluminense Federal University, Niterói, Brazil.

### ***Cristiane da Fonte Ramos***

Adjunct Professor of Human Anatomy. Rio de Janeiro State University, Rio de Janeiro, Brazil.

### ***Marcio Antonio Babinski***

Adjunct Professor of Human Anatomy. Department of Morphology, Fluminense Federal University, Niterói, Brazil.