



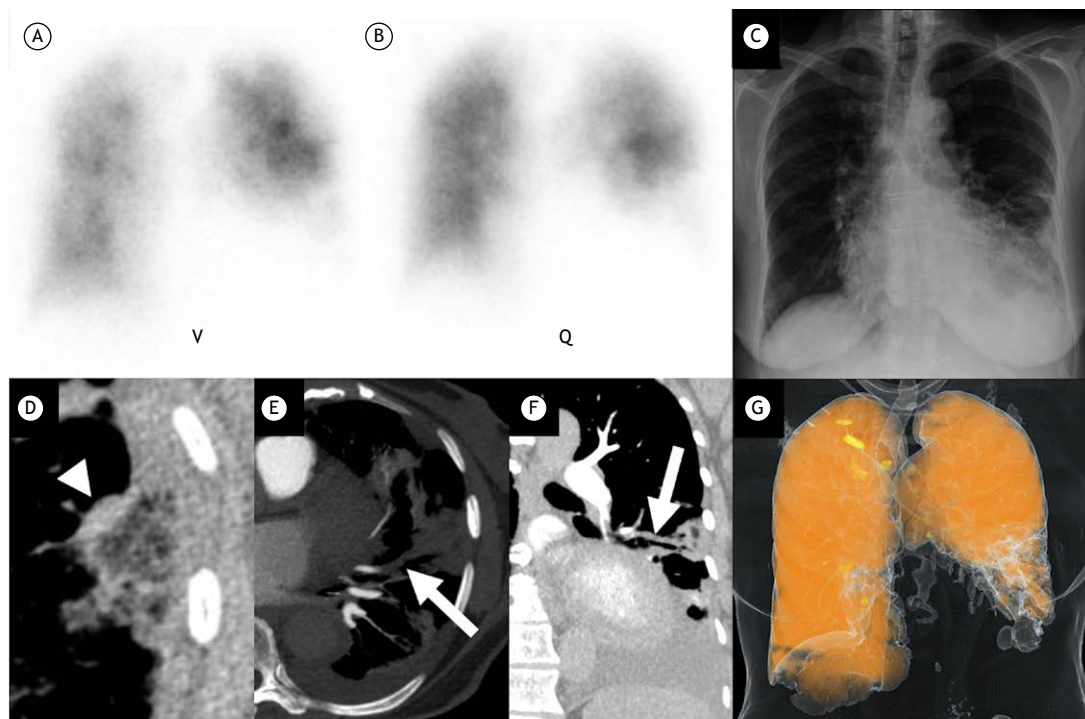
## Triple-matched defects on ventilation/perfusion scintigraphy and computed tomography: the importance of the reticular reversed halo sign

Bruno Lima Moreira<sup>1</sup> , Pablo Rydz Pinheiro Santana<sup>1,2</sup> ,  
Antônio Carlos Portugal Gomes<sup>1</sup> , Edson Marchiori<sup>3</sup>

### TO THE EDITOR:

An 87-year-old female patient with a history of heart failure and nondialysis chronic kidney disease was hospitalized for dyspnea and cough. She had a low pretest probability of pulmonary embolism (PE), as assessed by the original Wells score ( $< 2$ ). Her laboratory test results were as follows: hemoglobin, 12.0 g/dL; mild leukocytosis (11,570 cells/mm<sup>3</sup>); serum urea, 94 mg/dL; serum creatinine, 1.94 mg/dL (estimated glomerular filtration rate, as determined by the Modification of Diet in Renal Disease equation, 26 mL/min/1.73 m<sup>2</sup>); elevated C-reactive protein (11.34 mg/dL); and elevated D-dimer (2,536 ng/mL). A chest X-ray showed peripheral opacities in the middle and lower left lung fields, as well as signs of a small ipsilateral pleural effusion. Planar ventilation/perfusion (V/Q) scintigraphy revealed a segmental

matched V/Q defect in the left lower lobe, where the radiographic changes had been seen (constituting a triple-matched defect), leading to consideration of an intermediate (20-79%) probability of PE; that is, the procedure was considered nondiagnostic (Figures 1A-C). One caveat is that the diagnostic performance of planar V/Q scintigraphy is lower than that of V/Q single-photon emission CT, especially for segmental and subsegmental emboli.<sup>(1,2)</sup> Unenhanced chest CT showed peripheral opacities in the left lower lobe, as well as a reversed halo sign (RHS) with a reticular pattern within the halo (Figure 1D), together with a small ipsilateral pleural effusion. The presence of a reticular RHS in a juxtapleural location raised the possibility of pulmonary infarction. Prophylactic measures were implemented to prevent contrast-induced nephropathy, and dual-energy



**Figure 1.** Planar ventilation/perfusion (V/Q) scintigraphy (anterior view, in A and B) and chest X-ray (frontal view, in C) reveal a triple-matched defect in the left lower lobe. An axial CT image (in D) shows a reversed halo sign (RHS) with low-attenuation areas within the halo (reticular RHS; arrowhead) in a juxtapleural location, a finding suggestive of pulmonary infarction. On CT angiography, an axial maximum intensity projection image (in E) and an oblique coronal image (in F) show a complete filling defect in the subsegmental arterial branch (arrow) supplying the opacified area in the left lower lobe. A color-coded pulmonary blood volume map from dual-energy pulmonary CT angiography (in G) shows an iodine defect in the left lower lobe.

1. Med Imagem/BP Medicina Diagnóstica, Hospital Beneficência Portuguesa de São Paulo, São Paulo (SP) Brasil.  
2. Grupo Fleury, São Paulo (SP) Brasil.  
3. Departamento de Radiologia, Universidade Federal do Rio de Janeiro, Rio de Janeiro (RJ) Brasil.

pulmonary CT angiography was performed, confirming the presence of subsegmental PE (Figures 1E and 1F); color-coded iodine perfusion maps revealed an iodine defect in the left lower lobe (Figure 1G). Although dual-energy CT allows visualization of blood volume but not blood flow and does not provide true perfusion imaging, it allows selective visualization of contrast medium distribution with high spatial resolution (iodine color map) and eliminates registration problems with no additional radiation exposure.<sup>(3)</sup> In our patient, dual-energy CT showed a perfusion defect beyond an obstructive clot. Although this was not essential for diagnostic confirmation, it was very illustrative in terms of imaging.

According to the original and revised Prospective Investigation of Pulmonary Embolism Diagnosis II criteria, a solitary moderate-size or large triple-matched defect in the lower lung zone on V/Q scintigraphy and chest X-ray indicates an intermediate probability of PE and is nondiagnostic, respectively, a moderate defect covering 25-75% of a lung segment and a large defect covering > 75% of a lung segment.<sup>(4,5)</sup> In patients

with PE, pulmonary infarction has an incidence that ranges from 10% to 30% and typically presents on CT as pleural-based wedge-shaped opacities in cases of occlusion or subocclusion of segmental/subsegmental arterial branches, often in association with the RHS.<sup>(6,7)</sup> The RHS is defined as a focal area of ground-glass opacity surrounded by a more or less complete ring of consolidation.<sup>(8,9)</sup> Although it was originally described in the context of organizing pneumonia, it has been shown to be associated with several other lung diseases, including PE.<sup>(7,10,11)</sup> In immunocompetent patients, an RHS with reticulation within the halo (reticular RHS) in a juxtapleural location is highly suggestive of pulmonary infarction, usually secondary to thromboembolic disease.<sup>(12-14)</sup>

In an appropriate clinical context, the presence of a reticular RHS on unenhanced CT scans and nondiagnostic V/Q scans increase the likelihood of PE. In very specific situations, it might allow us to avoid the use of contrast media. Multicenter studies are needed in order to investigate this possibility.

## REFERENCES

1. Roach PJ, Schembri GP, Bailey DL. V/Q scanning using SPECT and SPECT/CT. *J Nucl Med.* 2013;54(9):1588-1596. <https://doi.org/10.2967/jnumed.113.124602>
2. Gutte H, Mortensen J, Jensen CV, Von Der Recke P, Petersen CL, Kristoffersen US, et al. Comparison of V/Q SPECT and planar V/Q lung scintigraphy in diagnosing acute pulmonary embolism. *Nucl Med Commun.* 2010;31(1):82-86. <https://doi.org/10.1097/MNM.0b013e3283336747>
3. Aran S, Daftari Besheli L, Karcaaltincaba M, Gupta R, Flores EJ, Abujudeh HH. Applications of dual-energy CT in emergency radiology [published correction appears in *AJR Am J Roentgenol.* 2014 Jun;202(6):1396. Besheli, Laleh Daftari [corrected to Daftari Besheli, Laleh]]. *AJR Am J Roentgenol.* 2014;202(4):W314-W324. <https://doi.org/10.2214/AJR.13.11682>
4. Gottschalk A, Stein PD, Goodman LR, Sostman HD. Overview of Prospective Investigation of Pulmonary Embolism Diagnosis II. *Semin Nucl Med.* 2002;32(3):173-182. <https://doi.org/10.1053/snuc.2002.124177>
5. Skarlovnik A, Hrastrnik D, Fettich J, Grmek M. Lung scintigraphy in the diagnosis of pulmonary embolism: current methods and interpretation criteria in clinical practice. *Radiol Oncol.* 2014;48(2):113-119. <https://doi.org/10.2478/raon-2013-0060>
6. Godoy MC, Viswanathan C, Marchiori E, Truong MT, Benveniste MF, Rossi S, et al. The reversed halo sign: update and differential diagnosis. *Br J Radiol.* 2012;85(1017):1226-1235. <https://doi.org/10.1259/bjr/54532316>
7. Casullo J, Semionov A. Reversed halo sign in acute pulmonary embolism and infarction. *Acta Radiol.* 2013;54(5):505-510. <https://doi.org/10.1177/0284185113475797>
8. Silva CI, Marchiori E, Souza Júnior AS, Müller NL; Comissão de Imagem da Sociedade Brasileira de Pneumologia e Tisiologia. Illustrated Brazilian consensus of terms and fundamental patterns in chest CT scans. *J Bras Pneumol.* 2010;36(1):99-123. <https://doi.org/10.1590/s1806-37132010000100016>
9. Hansell DM, Bankier AA, MacMahon H, McLoud TC, Müller NL, Remy J. Fleischner Society: glossary of terms for thoracic imaging. *Radiology.* 2008;246(3):697-722. <https://doi.org/10.1148/radiol.2462070712>
10. Marchiori E, Zanetti G, Escuissato DL, Souza AS Jr, Meirelles GS, Fagundes J, et al. Reversed halo sign: high-resolution CT scan findings in 79 patients. *Chest.* 2012;141(5):1260-1266. <https://doi.org/10.1378/chest.11-1050>
11. Maturu VN, Agarwal R. Reversed halo sign: a systematic review. *Respir Care.* 2014;59(9):1440-1449. <https://doi.org/10.4187/respcare.03020>
12. Marchiori E, Hochegger B, Zanetti G. Reversed halo sign in invasive fungal infections. *J Bras Pneumol.* 2016;42(3):232. <https://doi.org/10.1590/S1806-37562016000000119>
13. Marchiori E, Menna Barreto M, Pereira Freitas HM, Hochegger B, Soares Souza A Jr, Zanetti G, et al. Morphological characteristics of the reversed halo sign that may strongly suggest pulmonary infarction. *Clin Radiol.* 2018;73(5):503.e7-503.e13. <https://doi.org/10.1016/j.crad.2017.11.022>
14. Mançano AD, Rodrigues RS, Barreto MM, Zanetti G, Moraes TC, Marchiori E. Incidence and morphological characteristics of the reversed halo sign in patients with acute pulmonary embolism and pulmonary infarction undergoing computed tomography angiography of the pulmonary arteries. *J Bras Pneumol.* 2019;45(1):e20170438. <https://doi.org/10.1590/1806-3713/e20170438>