









Carinal resection via robotic surgery: a safe approach for selected cases

Erlon de Avila Carvalho¹, Daniel Oliveira Bonomi²,
Astunaldo Júnior Macedo Pinho², Márcio Oliveira Lucas³,
Marina Varela Braga de Oliveira⁴, Carolina Otoni Salemi²

TO THE EDITOR:

Tracheal tumors have an annual incidence of less than 0.2/100,000 population and a prevalence in autopsies of only 1 case in every 15,000.⁽¹⁾ They account for only 0.1% of all cancer deaths.⁽¹⁾ Among the histological types of tracheal tumors, the second most common is adenoid cystic carcinoma, which has an incidence of 18-59%. In addition, tracheal adenoid cystic carcinoma has equal gender distribution and is not related to smoking.^(2,3) Its symptoms are nonspecific, and the diagnosis is usually delayed.⁽⁴⁾ The treatment of choice is surgical resection.⁽⁴⁾

Because tracheal tumors are rare, few institutions have had the opportunity to gain experience regarding this type of neoplasm, and, consequently, treatment is provided exclusively at some specialized health care facilities. Therefore, surgical resection of tracheal tumors continues to be a challenge for the thoracic surgeon. Most procedures are performed via thoracotomy or median sternotomy. Some specialized centers are capable of video-assisted thoracoscopy.

As an alternative for performing this complex surgical procedure, robotic surgery has been shown to be a minimally invasive surgical modality that features several technological advances, such as a three-dimensional view for the surgeon, a greater range of motion of instrumentation, greater precision of movements, and less tissue damage. These advances make surgery safer, more precise, and more efficient. Robotic surgery has the following benefits⁽⁵⁾: shorter postoperative recovery; less postoperative pain; shorter hospital stays; a lower risk of bleeding and infections; smaller incisions; and surgeon-friendly ergonomics.

Here, we present the case of a 70-year-old male patient who presented with an episode of acute myocardial infarction, in his hometown, in February of 2018. During hospitalization, the patient developed hospital-acquired pneumonia. A lesion within the lumen of the carina was identified as an incidental finding on a CT scan of the chest. The patient underwent rigid bronchoscopy with excision of the lesion. The pathology result was adenoid cystic carcinoma.

The patient was then referred to a health care facility in the city of Belo Horizonte, Brazil, where he underwent flexible bronchoscopy, during which a residual exophytic lesion was seen in the carina. The decision was made to use robotic surgery in order to perform carinal

resection and mediastinal lymphadenectomy, with carinal reconstruction.

The patient was intubated with a single-lumen endotracheal tube, which was introduced into the left main bronchus under endoscopic guidance. Extracorporeal membrane oxygenation was available if necessary.

The da Vinci Xi robotic system (Intuitive, Sunnyvale, CA, USA) was used. An intercostal nerve block was performed, and four robotic ports were put in place. The optical port was placed in the eighth intercostal space on the right anterior axillary line, whereas the port for the anterior robotic arm was placed in the sixth intercostal space on the right anterior midclavicular line. The ports for the two other robotic arms were placed to form a triangle with the optical port, each being 7 cm from it. The surgery started with lymphadenectomy of the station 7 (subcarinal) mediastinal lymph nodes for visualization of the carina, as well as for dissection and stapling of the azygos vein (Figure 1A). The trachea was released to allow greater freedom of movement so that bronchoplasty could be performed. Bronchotomy was performed in the left main bronchus (Figure 1B), and the neoplastic lesion was identified by direct visualization. Carinal resection with histologically confirmed (frozen section) tumor-free margins was performed. That was followed by tracheal reconstruction and carinal reconstruction with continuous 3-0 polydioxanone barbed sutures (Figures 1C and 1D), together with a bovine pericardial patch and biological glue.

The patient had a favorable course and was discharged on postoperative day 3. Two weeks after discharge, he presented with moderate chest pain. A pneumothorax was identified, and the patient underwent chest tube drainage. Bronchoscopy revealed a bronchopleural microfistula. The decision was made to pursue conservative treatment, consisting of five days with a chest tube in place, and the condition resolved. Clinical and endoscopic follow-up showed adequate bronchial healing. The pathology result was adenoid cystic carcinoma without involvement of mediastinal lymph nodes and with disease-free surgical margins.

Robotic surgery has a series of advantages over other methods: it is minimally invasive, resulting in less pain, shorter hospital stays, and a rapid return to daily activities compared with open surgery; the robotic arms mimic the movements of the human hand, allowing more precise dissection compared with other minimally invasive

1. Instituto Mário Penna, Belo Horizonte (MG) Brasil.

2. Hospital Mater Dei, Belo Horizonte (MG) Brasil.

3. Hospital Américas, Rio de Janeiro (RJ) Brasil.

4. Hospital das Clínicas, Universidade Federal de Minas Gerais, Belo Horizonte (MG) Brasil.

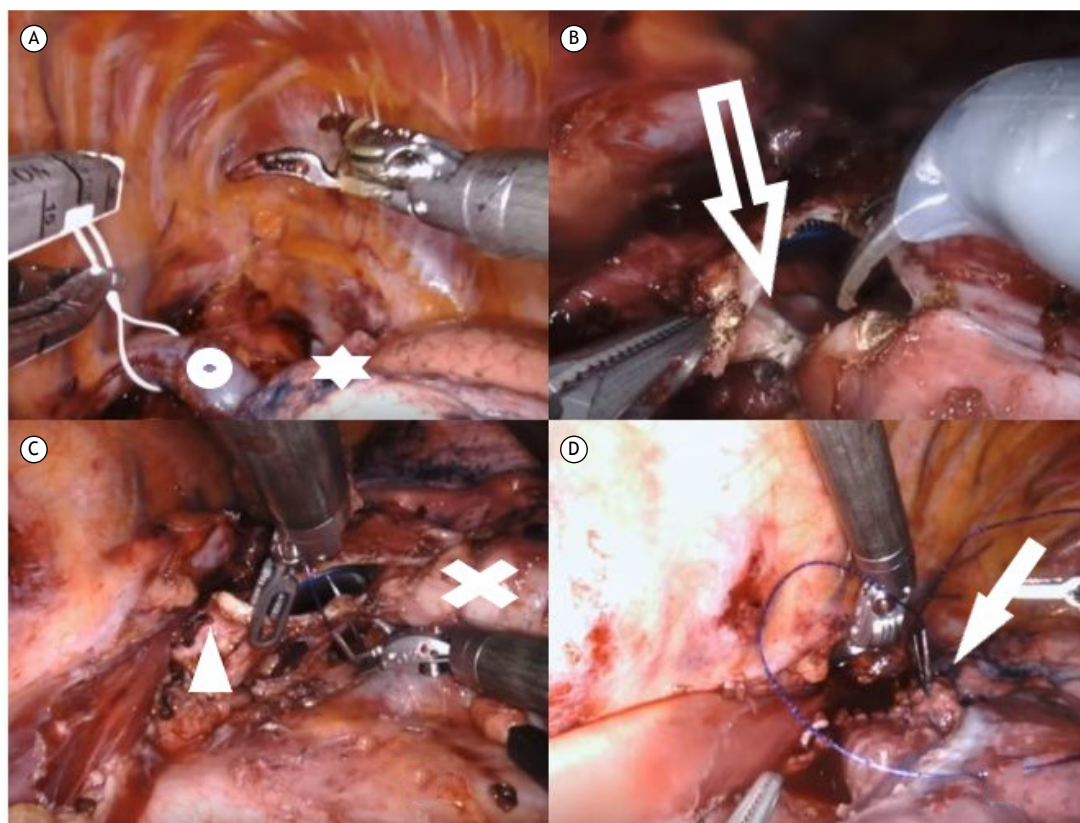


Figure 1. In A, dissection and repair of the azygos vein (circle) for sectioning and visualization of the right upper lobe (star). In B, opening of the main carina for resection of the tracheal tumor (arrow). In C, carinal reconstruction with continuous sutures, with visualization of the right main bronchus (X) and left main bronchus (arrowhead). In D, end of the suture line and the newly constructed carina (arrow).

approaches; the three-dimensional view magnifies the details of the anatomical structures, making surgery safer; and, as demonstrated here, robotic surgery

is entirely feasible for carefully selected cases, such as those requiring resection of small tumors without mediastinal invasion.

REFERENCES

1. Pearson FG, Cardoso P, Keshavjee S. Primary tumors of the upper airway. In: Pearson FG, Deslauries J, Ginsberg RJ, editors. Thoracic surgery. 1st ed. New York: Churchill & Livingstone; 1995. p.285-299.
2. Sato K, Takeyama Y, Kato T, Kato T, Hashimoto H, Fukui Y, Gonda H, et al. Tracheal adenoid cystic carcinoma treated by repeated bronchoscopic argon plasma coagulation as a palliative therapy. *Ann Thorac Cardiovasc Surg.* 2014;20 Suppl:602-605. <https://doi.org/10.5761/atcs.cr.12.02156>
3. Suemitsu R, Okamoto T, Maruyama R, Wataya H, Seto T, Ichinose Y. A long-term survivor after aggressive treatment for tracheal adenoid cystic carcinoma: a case report. *Ann Thorac Cardiovasc Surg.* 2007;13(5):335-337.
4. Caiado A, Moura e Sá J. Tracheal tumors review—a clinical case of adenoid cystic carcinoma [Article in Portuguese]. *Rev Port Pneumol.* 2008;14(4):527-534. [https://doi.org/10.1016/S0873-2159\(15\)30257-9](https://doi.org/10.1016/S0873-2159(15)30257-9)
5. Bodner J, Wykypiel H, Wetscher G, Schmid T. First experiences with the da Vinci operating robot in thoracic surgery. *Eur J Cardiothorac Surg.* 2004;25(5):844-851. <https://doi.org/10.1016/j.ejcts.2004.02.001>