

## Oral candidosis by *Candida albicans* in normal and xerostomic mice

### *Candidose oral por Candida albicans em camundongos normais e xerostômicos*

Marilda Aparecida Gonçalves Totti\*

Elisabete Brasil dos Santos\*\*

Oslei Paes de Almeida\*\*\*

Cristiane Yumi Koga-Ito\*\*\*\*

Antonio Olavo Cardoso Jorge\*\*\*\*\*

**ABSTRACT:** The aim of this study was to analyze the effect of sialoadenectomy on the development of oral candidosis after one or four inoculations of *Candida albicans*. Initially, a suspension containing  $10^8$  cells/ml of *C. albicans* ATCC 36801 was prepared. Seventy-eight sialoadenectomized mice and a similar amount of mice with normal salivary flow received a single inoculation of *C. albicans* suspension. Another group with a similar number of mice received 4 inoculations. The control group consisted of 6 sialoadenectomized mice and 6 mice with normal salivary flow that were not inoculated with *C. albicans*. Candidosis development was studied histologically in the tongue of the animals 1, 2, 3, 5, and 8 days after inoculation and at 15-day intervals up to 165 days. According to the results obtained, it could be concluded that sialoadenectomy and a higher frequency of yeast inoculation influenced the presence and extension of candidosis lesions.

**DESCRIPTORS:** Candidiasis, oral; *Candida albicans*; Xerostomia.

**RESUMO:** O objetivo deste estudo foi analisar o efeito da sialoadenectomia sobre o desenvolvimento da candidose oral após uma ou quatro inoculações de *Candida albicans*. Inicialmente, uma suspensão contendo  $10^8$  células/ml de *C. albicans* ATCC 36801 foi preparada. Setenta e oito camundongos sialoadenectomizados e mesma quantidade de camundongos com fluxo salivar normal receberam uma única inoculação de suspensão de *C. albicans*. Outro grupo, com o mesmo número de camundongos, recebeu 4 inoculações. O grupo controle consistiu de 6 camundongos sialoadenectomizados e 6 com fluxo salivar normal que não foram inoculados com *C. albicans*. O desenvolvimento de candidose foi estudado histologicamente na língua dos animais em períodos de 1, 2, 3, 5 e 8 dias após a inoculação e em intervalos de 15 dias até 165 dias. De acordo com os resultados obtidos, concluiu-se que a sialoadenectomia e uma maior frequência de inoculação influenciaram na presença e extensão das lesões de candidose.

**DESCRIPTORIOS:** Candidíase bucal; *Candida albicans*; Xerostomia.

## INTRODUCTION

Candidosis is the most common infection of the oral cavity caused by fungi and *C. albicans* is the main species related to its development. The genus *Candida* belongs to the indigenous oral flora of 20 to 40% of healthy subjects<sup>7,18</sup> and its pathogenicity is observed in the presence of predisposing conditions such as immunodepression, use of denture or orthodontic appliances and diabetes mellitus. The transformation from the saprophytic

to the parasitic form is related to various factors, including not only the virulence of these yeasts, but also host-related variables<sup>19</sup>. Among the host-related factors, the modification of the oral microbiota balance is considered a very important factor<sup>6</sup>.

Xerostomia is one of the main factors related to the development of oral candidosis, since the lack of or decrease in salivary flow causes changes

\* PhD in Oral Biopathology; \*\*\*Head Professor, Department of Oral Pathology – School of Dentistry of Piracicaba, State University of Campinas.

\*\* PhD, Assistant Professor, Department of Dentistry, University of Ponta Grossa.

\*\*\*\* PhD, Assistant Professor, Department of Biosciences and Oral Diagnosis, School of Dentistry of São José dos Campos, São Paulo State University.

\*\*\*\*\* Head Professor, Department of Dentistry, University of Taubaté.

in the resident oral microbiota. Also, food and microorganisms are poorly mechanically removed from the oral cavity and subjects lack the protector effect of saliva constituents, such as lactoferrin and lysozyme<sup>20</sup>.

In a previous study, Totti *et al.*<sup>22,23</sup> (1996, 2002) observed that xerostomia helps in the appearance, proliferation and persistency of five *Candida* species in the oral cavity of rats. Similar results were observed by Jorge *et al.*<sup>11,12</sup> (2000, 2002). Xerostomia is also related to the longer permanence of yeasts in the mouth of mice<sup>12</sup> and to a higher *Candida albicans* transmissibility<sup>11</sup>. Takakura *et al.*<sup>21</sup> (2003) correlated the number of candidosis lesions with the increased number of *Candida* in the oral cavity.

Rats have been used as an experimental model in studies on oral candidosis and also to evaluate the influence of local and systemic factors<sup>1,4,10</sup>. The use of mice as an experimental model in studies on oral candidosis is relevant, since *Candida* is not part of their indigenous oral microbiota<sup>14</sup>.

The influence of several inoculations of *C. albicans* on the development of candidosis in mice has not been discussed yet. The aim of this study was to analyze the effect of sialoadenectomy on the development of oral candidosis in mice after one or four inoculations of *Candida albicans* suspensions.

## MATERIAL AND METHODS

Three-hundred and twenty four male mice (*Mus musculus*, albinos, Swiss; School of Dentistry of São José dos Campos, University of São Paulo), weighting from 25 to 30 g were included in this study. The animals were divided into three groups as follows: 156 xerostomic mice, 156 mice with normal salivary flow and 12 controls.

Xerostomia was obtained by surgical removal of the major salivary glands, according to Cheyne<sup>4</sup> (1939), with modifications. Before the beginning of the experiment, the presence of *Candida* in the oral cavity of the normal and sialoadenectomized animals was analyzed by plating the collected material from the oral cavity of the mice with a sterile swab (CB Products, SP, Brazil) in Sabouraud dextrose agar with chloramphenicol (quemeticina succinato, Carlo Erba, 0.1 mg/ml, SP, Brazil). After incubation at 37°C for 48 h, the presence of *Candida* ssp. was analyzed. This procedure was repeated two weeks later. All mice were initially negative to *Candida*.

*C. albicans* ATCC 36801 was subcultured in Sabouraud agar slants (Difco, Detroit, USA) and incubated for 24 h at 35°C. The cells of *C. albicans* were resuspended in phosphate-buffered saline (PBS, pH 7.4, Sigma, St. Louis, USA) and washed three times. From these cells, a suspension containing 10<sup>8</sup> viable cells/ml of *C. albicans* was standardized using a Neubauer chamber (Assistant, München, Germany) and 0.05% methylene blue (Dr. Theodor Schuchardt GMBH & Co., München, Germany). The inoculations were performed using this cell suspension as follows:

- Single-inoculation group: 78 sialoadenectomized mice and 78 mice with normal salivary flow received a single inoculation of 0.1 ml of the *C. albicans* suspension containing 10<sup>8</sup> viable cells/ml using a 1 ml syringe and a 30 x 8 mm needle.
- Four-inoculation group: 78 sialoadenectomized mice and 78 mice with normal salivary flow received a total of 4 intraoral inoculations of the *C. albicans* suspension containing 10<sup>8</sup> viable cells/ml, performed during 4 consecutive days.
- Control group: 6 sialoadenectomized mice and 6 mice with normal salivary flow that were not inoculated with the *C. albicans* suspension.

All the animals did not receive water for at least 1 h after inoculation. Candidosis was studied in the tongue of normal and sialoadenectomized mice at 1, 2, 3, 5 and 8 days after inoculation and at 15-day intervals up to 165 days. Six animals of each group were sacrificed at each studied time and the tongue was surgically removed, fixed in a 10% formalin solution (Synth, SP, Brazil) and processed for histological examination. For the histological processing, the tongue was divided longitudinally and the two portions were included in paraffin. Semi serial slices of 5 µm were obtained, which allowed the analysis of the central, lateral and edge part of the tongue (designed sites A, B and C, respectively) on the left and right sides. The slides were dyed using PAS (periodic acid - Sigma, St. Louis, USA; Schiff's reagent - Merck, Darmstadt, Germany), H & E (Merck, Darmstadt, Germany) and Gomori-Grocott stains (Sigma, St. Louis, USA). The tongue was thoroughly examined for presence of candidosis, with a total of 18 sections examined for each animal. All the sections were analyzed by one examiner previously trained. The description of the candidosis areas was performed considering the localization, extension, alterations in the tissues, and candidal hyphae presence.

**TABLE 1** - Number (n) and percentage of normal and xerostomic mice that developed candidosis in the dorsum of the tongue after a single inoculation of the yeast in the oral cavity.

Days	Normal mice		Xerostomic mice	
	n	%	n	%
1	0	0	2	33.3
2	0	0	1	16.6
5	0	0	1	16.6
8	1	16.6	2	33.3
15	0	0	2	33.3
30	0	0	1	16.6
75	0	0	1	16.6

### Statistical analysis

Data on the mean and standard deviation of the number of animals with candidosis after one and four inoculations were compared statistically by means of the Student's *t*-test ( $\alpha = 5\%$ ).

## RESULTS

### Presence of candidosis

According to the histological analysis of the tongues, it could be observed that the development of candidosis occurred more frequently among sialoadenectomized mice submitted to both one and four inoculations of the yeast suspension.

Table 1 presents the number of sialoadenectomized and normal salivary flow mice that presented candidosis according to the period of time analyzed. Among the xerostomic animals that received 1 inoculation of *C. albicans*, candidosis was observed in 33.33% of the animals, after a period of 15 days. This value decreased to 16.6% 75 days after the inoculation. After this period, no animal presented candidosis.

Among the animals that received 4 inoculations of *Candida albicans* suspension, candidosis was observed in 83.3% to 100% of the xerostomic animals after the period of eight days. This number decreased to 33.33% after 15 days, and 115 days after the last inoculation only 1 (16.6%) animal presented candidosis.

Considering the mice with normal salivary flow, no difference could be observed in relation to the number of animals with candidosis after 1 or 4 inoculations of *C. albicans*. Eight days after a single inoculation, only one animal presented candidosis in the tongue dorsum. After 4 *C. albi-*

*cans* inoculations, candidosis was observed in one animal after 45 days.

Candidosis was not observed in animals from the control group, which were not inoculated with *C. albicans*.

Mean and standard deviations values of the number of candidosis areas observed among normal and xerostomic mice after 1 and 4 inoculations are presented in Table 2. Statistically significant differences were observed between the 4-inoculation normal salivary flow group and the 4-inoculation sialoadenectomized mice group at 2, 3 and 45 days. Considering the single-inoculation group, a statistically significant difference between sialoadenectomized and normal salivary flow mice was observed at day 8.

### Histological analysis

#### 8 days after *C. albicans* inoculation

After this period of time, considering the animals that received only a single inoculation, candidosis was observed in the dorsum of the tongue of 2 sialoadenectomized and of 1 normal mouse. The tongue of sialoadenectomized mice presented flattening of the papillae, acanthosis, parakeratosis, and lymphocytic infiltration.

Observations performed after 4 inoculations of *C. albicans*, showed necrotic areas on the dorsum of the tongue of normal mice. Sialoadenectomized animals presented extensive areas with intense candidosis, mainly in the papillae regions. Figure 1 shows the histologic examination of a sialoadenectomized animal 3 days after the last inoculation.

#### 15 to 60 days after the *C. albicans* inoculation

The epithelium of the dorsum of the tongue of normal salivary flow mice had normal histological aspect 15 days after a single inoculation. Candidosis lesions were observed in 2 sialoadenectomized animals 15 days after the inoculation and in 1 animal 30 days after the inoculation. Forty-five and 60 days after the inoculation, no candidosis lesions were registered. The lesions in the interior of the epithelium's keratine in the dorsum of the tongue presented few candidal hyphae. No alterations in the epithelium were observed.

After 4 inoculations of the *C. albicans* suspension, one normal and 2 sialoadenectomized mice presented candidosis in the dorsum of the tongue. Fifteen and 30 days after the inoculation, 2 sialoadenectomized animals presented candidosis in

**TABLE 2** - Mean and standard deviation values of the number of areas of candidosis after one and 4 inoculations of the *Candida albicans* suspension in the oral cavity of normal and xerostomic mice. Six regions of the tongue were considered: central portion of the left and right sides, lateral portion of the left and right sides and edge of the tongue at the left and right sides.

Days	Normal mice		Xerostomic mice	
	1 inoculation	4 inoculations	1 inoculation	4 inoculations
1	0	0	1.17 ± 2.04	4.17 ± 1.60
2	0	0.67 ± 1.21	0.16 ± 0.41	5.00 ± 2.45*
3	0	1.00 ± 2.45	0	4.33 ± 1.03*
5	0	0	0.50 ± 1.22	3.83 ± 2.71
8	0.17 ± 0.41	0	1.66 ± 1.47*	3.33 ± 2.34
15	0	0	0.83 ± 1.60	1.66 ± 2.66
30	0	0	1.00 ± 2.45	1.66 ± 2.42
45	0	0.17 ± 0.41	0	1.83 ± 2.40*
60	0	0	0	0.50 ± 1.22
75	0	0	1.00 ± 2.45	0.50 ± 1.22
90	0	0	0	0.50 ± 1.22
115	0	0	0	0.50 ± 1.22

\*Statistical significant difference at the level of significance of 5% (Student's *t*-test) in relation to normal salivary flow group.

the dorsum of the tongue and 60 days after the inoculations just one animal presented signs of candidosis. The observed candidosis areas were extensive, mainly in the lingual papillae region, and were found in all the extension of the dorsum of the tongue. Candidal hyphae could be observed penetrating the epithelium.

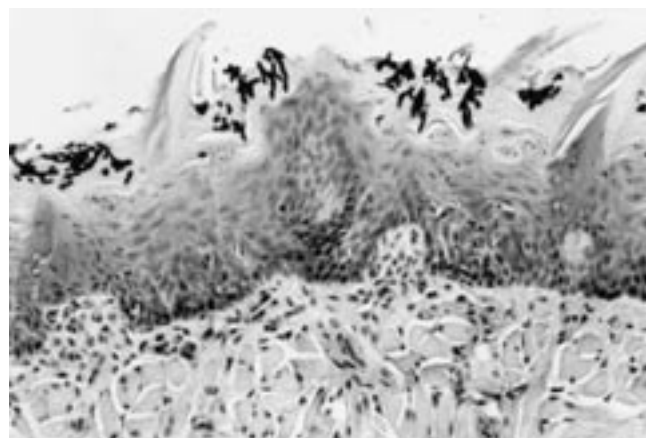
Among the mice without candidosis, flattening of lingual papillae, hiperkeratosis, acanthosis, lymphocitic infiltrate and areas of necrosis in the epithelium could be observed.

### 75 to 165 days after the inoculation

Only one sialoadenectomized mouse presented candidosis in this period. Extensive areas of candidosis with similar histologic aspects to those described previously were observed. In the other animals, the histologic aspect of the dorsum of the tongue was normal.

## DISCUSSION

It is well known that infections caused by *Candida* species have a multifactorial etiology. The transformation from the saprophytic to the parasitic form is related to several factors including not only the virulence of these yeasts but also host-related variables. Among the host-related fac-



**FIGURE 1** - Histologic examination of the tongue of sialoadenectomized animal, 3 days after four inoculations of *Candida albicans*. A high quantity of pseudohyphae, the presence of inflammatory infiltrate, flattening of lingual papillae, hiperkeratosis and acanthosis can be observed (PAS, 200 X).

tors, the salivary anti-*Candida* immunoglobulins and cellular defenses play an essential role for controlling the infection<sup>13,18</sup>. When these defenses are compromised, such as in cases of xerostomia, candidosis can occur. In fact, Brown *et al.*<sup>3</sup> (1975) observed an increase in the prevalence of *Candida* spp., mainly *C. albicans*, in patients with xerostomia induced by head and neck radiation.

In this study, it could be observed that the surgical removal of the major salivary glands produced deep xerostomia in mice. The volume of saliva was reduced by approximately 75%. In human beings, the symptoms of xerostomia can be observed when the salivary flow is reduced by 40 to 50%<sup>5,8</sup>. After surgery, the oral cavity of the mice was dry, presenting only residual viscous saliva and food on mucous tissue and teeth. The residual salivary flow present in the mouth of sialoadenectomized mice was probably produced by the minor salivary glands.

Our results showed that xerostomia induced by sialoadenectomy itself did not promote the appearance of *C. albicans* in the oral cavity. This fact is probably because these yeasts are not part of their indigenous oral microbiota. *Candida* was not isolated from the mice's oral cavity before the experiment. The cultures remained negative for *Candida* 1 and 2 weeks after surgery.

Sialoadenectomy was the technique selected to produce xerostomia in mice because it is a simple method and it causes a permanent reduction in the salivary flow. The use of chemical agents can also produce xerostomia<sup>16</sup>. However, their effects are transient and they can produce side effects that can interfere on the results.

In human beings, xerostomia is associated with atrophy of the oral mucosa, especially in the dorsum of the tongue<sup>24</sup>. In the present study, this alteration was not observed. On the other hand, alterations in the oral microbiota have also been reported in patients with xerostomia<sup>17</sup>.

Mice have been used in studies on the pathogenicity of *C. albicans* in the oral cavity. These animals do not harbor *Candida* in their oral cavity and can be considered more adequate for these studies, since other microbial species do not in-

terfere with the tested microorganism<sup>1,2,9,14,20</sup>. This way, the infection by *Candida* spp. is considered as a transient colonization in the oral cavity of these animals.

The development of candidosis, after 1 and 4 inoculations of the *C. albicans* suspension occurred more frequently in sialoadenectomized mice in comparison with the normal ones. Eight days after the last inoculation, 83.3% of the animals presented extensive candidosis lesions, particularly in the true papillae region.

In relation to the animals with normal salivary flow that received 1 inoculation, only one presented lesions in the dorsum of the tongue. This number was lower than that observed by Lacasse *et al.*<sup>15</sup> (1990). Among the animals that received 4 inoculations, 33.33% presented candidosis and this number decreased with time.

Candidosis on the dorsum of the tongue was characterized by the presence of pseudohyphae inside the epithelium, flattening of the lingual papillae, hyperkeratosis, akantosis and neutrophilic infiltrate, forming intraepithelial micro abscesses. There were no differences among lesions found in the central, lateral or edge regions of the tongue; however, a slightly higher prevalence of the lesions in the true and conical papillae was observed.

## CONCLUSION

According to the results obtained, it could be concluded that sialoadenectomy and a higher number of *C. albicans* inoculations influenced the frequency and extension of candidosis lesions in mice.

## REFERENCES

1. Adams D, Jones JH. Life history of experimentally induced acute oral candidiasis in the rat. J Dent Res 1971;50:643-4.
2. Allen CM. Animal models of oral candidiasis. A review. Oral Surg Oral Med Oral Pathol 1994;78:216-21.
3. Brown LR, Dreizen S, Handler S, Johnston DA. Effect of radiation-induced xerostomia on human oral microflora. J Dent Res 1975;54:740-50.
4. Cheyne VD. A description of the salivary glands of the rat and a procedure for their extirpation. J Dent Res 1939;18:457-68.
5. Dawes C. Physiological factors affecting salivary flow rate, oral sugar clearance, and the sensation of dry mouth in man. J Dent Res 1987;66:648-53.
6. do Rego MA, Koga-Ito CY, Jorge AOC. Effects of oral environment stabilization procedures on counts of *Candida* spp. in children. Pesqui Odontol Bras 2003;17(4):332-6.
7. Farah CS, Ashman RB, Challacombe SJ. Oral candidosis. Clin Dermatol 2000;18:553-62.
8. Fox CP, van der Ven PF, Sonies BC, Weiffenbach JM, Baum BJ. Xerostomia: evaluation of a symptom with increasing significance. J Am Dent Assoc 1985;110:519-25.
9. Hassan OE, Jones JH, Russell C. Experimental oral candidal infection and carriage of oral bacteria in rats subjected to a carbohydrate-rich diet and tetracycline treatment. J Med Microbiol 1985;20:291-8.
10. Jones JH, Russell C. The histology of chronic candidal infection of the rat's tongue. J Pathol 1974;113:97-100.

11. Jorge AOC, Batista JA, Rego MA. Influência da xerostomia na transmissibilidade de *Candida albicans* na cavidade bucal de ratos. *Rev Odontol UNICID* 2000;12:121-8.
12. Jorge AOC, Rego MA, Santos EB, Almeida OP. Efeitos da aplicação de *Candida albicans* na língua de ratos normais e sialoadenectomizados. *Rev Odontol UNICID* 2002;14:35-44.
13. Jorge AOC, Totti MAG, de Almeida OP, Scully C. Effect of sialoadenectomy on the carriage of *Candida albicans* in the mouths of rats. *J Oral Pathol Med* 1993;22:138-40.
14. Lacasse M, Fortier C, Chankir J, Cote L, Deslauriers N. Acquired resistance and persistence of *Candida albicans* following oral candidiasis in the mouse: a model of the carrier state in humans. *Oral Microbiol Immunol* 1993;8:313-8.
15. Lacasse M, Fortier C, Trudel L, Collet AJ, Deslauriers N. Experimental oral candidosis in the mouse: microbiologic and histologic aspects. *J Oral Pathol Med* 1990;19:136-41.
16. Lekholm U, Wallenius K. Experimental oral cancer in rats with xerostomia. *Odontol Revy* 1976;27:11-8.
17. Llory H, Dammron A, Frank RM. Les modifications de la flore buccale aerobie apres radiotherapie buccopharynge. *Arch Oral Biol* 1971;16:617-30.
18. Odds FC. *Candida* infections: an overview. *Crit Rev Microbiol* 1987;15:1-5.
19. Samaranayake LP, MacFarlane TW. *Oral candidosis*. Cambridge: Wright; 1990.
20. Samaranayake YH, Samaranayake LP. Experimental oral candidiasis in animal models. *Clin Microbiol Rev* 2001;14:398-429.
21. Takakura N, Sato Y, Ishibashi H, Oshima H, Uchida K, Yamaguchi H, *et al*. A novel murine model of oral candidiasis with local symptoms characteristic of oral thrush. *Microbiol Immunol* 2003;47:321-6.
22. Totti MAG, Jorge AOC, dos Santos EB, de Almeida OP, Scully C. Implantation of *Candida albicans* and other *Candida* species in the oral cavity of rats. *J Oral Pathol Med* 1996;25:308-10.
23. Totti MAG, Santos EB, Almeida OP, Jorge AOC. Implantation and permanency of *Candida albicans* in the oral cavity of normal and sialoadenectomized mice after a single inoculation of yeast. *Braz J Oral Sci* 2002,1:133-6.
24. Wallace MC, Petrusneck F. The dental implications of xerostomia. A review of the literature. *J Ala Dent Assoc* 1985;69:44-7.

Received for publication on Mar 01, 2004

Sent for alterations on Apr 22, 2004

Accepted for publication on May 26, 2004