

Effects of the unilateral removal and dissection of the masseter muscle on the facial growth of young rats

Lucimar Rodrigues^(a)
Andréia Aparecida Traina^(a)
Luiz Felipe Nakamai^(b)
João Gualberto de Cerqueira Luz^(c)

^(a)MS, Doctorate Student; ^(b)Graduate Student; ^(c)Associate Professor – Department of Maxillofacial Surgery, Prosthodontics and Traumatology, School of Dentistry, University of São Paulo.

Abstract: This study analyzed the effects of the unilateral removal and dissection of the masseter muscle on the facial growth of young rats. A total of 30 one-month-old Wistar rats were used. Unilateral complete removal of the masseter muscle was performed in the removal group, and detachment followed by repositioning of the masseter muscle was performed in the dissection group, while only surgical access was performed in the sham-operated group. The animals were sacrificed at three months of age. Axial radiographic projections of the skulls and lateral projections of the hemimandibles were taken. Cephalometric evaluations were made and the values obtained were submitted to statistical analyses. In the removal group, there were contour alterations of the angular process, and a significant homolateral difference in the length of the maxilla and a significant bilateral difference in the height of the mandibular body and the length of the mandible were observed. Comparison among groups revealed significance only in the removal group. It was concluded that the experimental removal of the masseter muscle during the growing period in rats induced atrophic changes in the angular process, as well as asymmetry of the maxilla and shortening of the whole mandible.

Descriptors: Masseter muscle; Maxillofacial development; Growth and development.

Corresponding author:

João Gualberto de Cerqueira Luz
Depto. de Cirurgia, Faculdade de
Odontologia, Universidade de São Paulo
Av. Prof. Lineu Prestes, 2227
Cidade Universitária
São Paulo - SP - Brazil
CEP: 05508-000
E-mail: jgcluz@usp.br

Received for publication on 18 Sep, 2007
Accepted for publication on 21 Jan, 2008

Introduction

The dynamics of normal postnatal growth of the craniofacial skeletal system is incompletely understood.¹ Studies have experimentally demonstrated the effect of bony or cartilaginous lesions on facial growth. Unilateral resection of the mandibular condyle induced severe facial asymmetry.^{2,3} Resection of the cartilaginous nasal septum promoted severe facial deformity.⁴ Also, osteotomies that simulated a mandibular fracture in the growing period had as consequences asymmetries of the maxilla and the mandible,⁵ or lessening of the mandible.⁶

It has been demonstrated that the masticatory muscle function is a determinant of the quality of bone of the growing mandible.⁷ The elevator muscles influence the transversal and the vertical dimensions of the face.⁸ Bilateral resections of the masseter and temporal muscles induced deformities in the mandible which were related to the amount of tissue removed.⁹ An open bite occurs in rats after bilateral removal of the masseter.¹⁰ Also, unilateral masticatory function caused asymmetric craniofacial growth.¹¹

Surgical procedures on the mandible are frequently carried out with muscle detachment. The reattachment process includes superficial new bone formation.¹² Experimental alterations of the masseter muscle length can change the gonial region.¹³ However, the role of the musculature in the process of bone formation is not well understood.¹⁴

The purpose of this study was to analyze the effects of the unilateral removal and dissection of the masseter muscle on the facial growth of young rats.

Materials and Methods

The study animals were 30 one-month-old female Wistar rats. All animals were fed an ordinary diet of rodent feed (Labina, Agribands Purina, Paulínia, SP, Brazil), and water. They were distributed into removal ($n = 10$), dissection ($n = 10$), and sham-operated ($n = 10$) groups.

Under general anesthesia, induced by xylazine hydrochloride (Rompum, Bayer, Porto Alegre, RS, Brazil), 10 mg/kg of body weight, and ketamine hydrochloride (Ketalar, Parke-Davis, Rio de Janeiro, RJ, Brazil), 25 mg/kg of body weight, the right side

was shaved and cleansed with a povidone-iodine solution (Riodeine, Rioquímica, São José do Rio Preto, SP, Brazil). A submandibular incision of 1 cm was made, followed by exposure of the masseter muscle. The removal group was submitted to complete resection of the masseter muscle. The dissection group was submitted to subperiosteal complete elevation of the masseter muscle, followed by repositioning of this structure. The sham-operated group was submitted to exposure of the masseter muscle. The procedures were concluded by suturing in layers. The animals were sacrificed at three months of age. The specimens were evaluated macroscopically. Their heads and mandibles were macerated. Following formalin fixation, radiographs in axial projections of the skull and lateral projection of the hemimandibles were obtained. These were taken with a dental X-ray machine (Spectro II, Dabi-Atlante, Ribeirão Preto, SP, Brazil) at 56 kV and 10 mA, with an exposure time of 0.4 s for the skull and 0.3 s for the hemimandibles. Periapical films were used (Ektaspeed Plus, Eastman Kodak Co, Rochester, NY, USA).

The radiographs were subjected to computerized cephalometric evaluation. They were digitized using an optical reader (Fotovix II, Tamron Co., Tokyo, Japan). Measurements were obtained with Imagelab software (Softium Informática Ltda., São Paulo, SP, Brazil). Using the skull radiographs, the following distances were measured bilaterally: TB-MR - tympanic bulla to the mesial root of the first molar; TB-IF - tympanic bulla to infraorbital foramen; and IF-IP - infraorbital foramen to incisal point (Figure 1). On the radiographs of the hemimandibles, the following distances were measured bilaterally: CP-AP - condylar process to angular process; TM-AN - distal face of the third molar to antegonial notch; II-CP - lower insertion of incisor to condylar process; and II-AP - lower insertion of incisor to angular process (Figure 2).

To evaluate the differences between the mean values from the right and left sides in each group, the paired Student's *t*-test was used, whilst the analysis of variance (ANOVA) and Tukey's tests were used for the mean values of the three groups. The level of significance was set at 5% ($p \leq 0.050$).

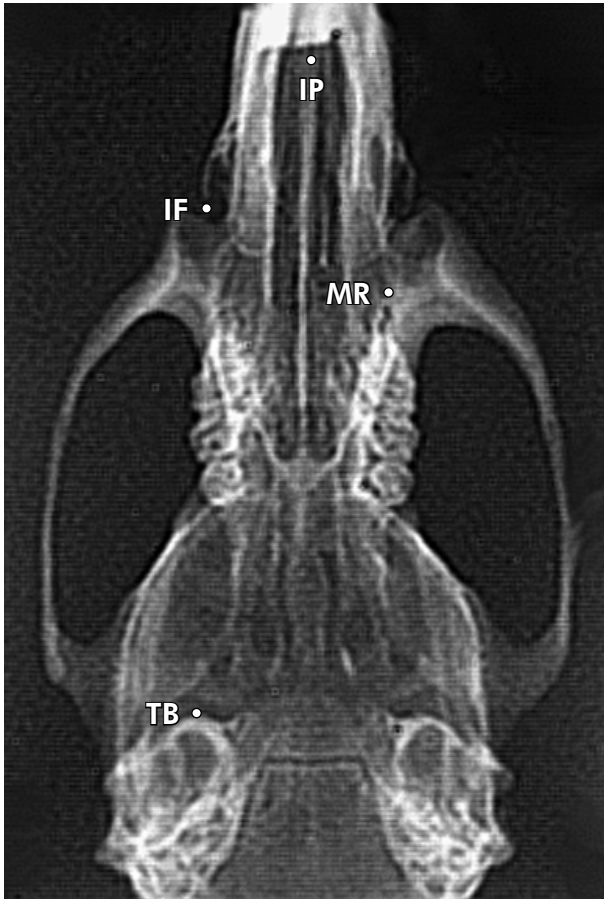


Figure 1 - Computerized cephalometric landmarks used in an axial radiograph of the skull of a specimen from the removal group. IP = Incisal point, IF = Infraorbital foramen, MR = Mesial root of the first molar, TB = Tympanic bulla.

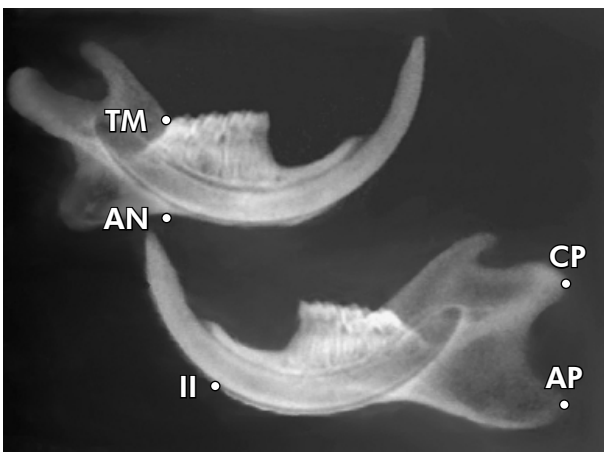


Figure 2 - Computerized cephalometric landmarks used in a lateral radiograph of the hemimandibles of a specimen from the removal group. CP = Condylar process, AP = Angular process, II = Lower insertion of incisor, AN = Antegonial notch, TM = Distal face of the third molar.

Results

Macroscopic examination of the specimens revealed facial asymmetry in the removal group, with deviation of the mandible to the right side, and discrete asymmetry in the dissection group. Contour alterations with irregularities and signs of atrophy of the angular process were noted only in the removal group (Figure 3).

The mean values of the distances found on the radiographs of the skulls of the removal, dissection and sham-operated groups are listed in Table 1. In the removal and dissection groups there was a significant difference between sides for all measurements: tympanic bulla to mesial root of the first molar (TB-MR), tympanic bulla to infraorbital foramen (TB-IF) and infraorbital foramen to incisal point (IF-IP). However, in the sham-operated group there was no significant difference between sides for all measurements.

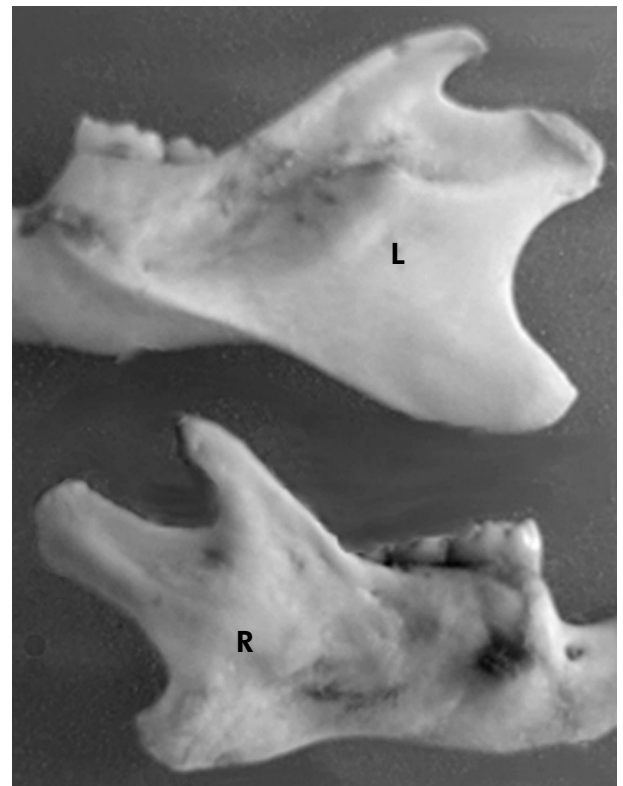

Figure 3 - Macroscopic view of the hemimandibles of a specimen from the removal group with atrophy, contour alterations and irregularities of the right (R) angular process. L = left side (control).

Table 1 - Mean values (mm) of the distances found on the axial radiographs of all the groups and significance of the paired Student's *t*-test.

Group		Measurements		
		TB-MR mean ± sd	TB-IF mean ± sd	IF-IP mean ± sd
Removal	Right side	17.14 ± 0.93	20.58 ± 0.68	8.48 ± 0.92
	Left side	17.43 ± 0.94	20.88 ± 0.79	9.54 ± 0.92
	p value	0.003	0.044	0.006
Dissection	Right side	17.49 ± 0.59	21.02 ± 0.71	8.94 ± 0.32
	Left side	17.73 ± 0.63	21.30 ± 0.74	9.41 ± 0.35
	p value	0.002	0.016	0.001
Sham-operated	Right side	17.87 ± 0.42	21.43 ± 0.40	9.44 ± 0.24
	Left side	18.01 ± 0.57	21.52 ± 0.62	9.38 ± 0.31
	p value	0.249	0.462	0.374

IP = Incisal point, IF = Infraorbital foramen, MR = Mesial root of the first molar, TB = Tympanic bulla.

In the comparison of the maxillary measurements among groups, the ANOVA demonstrated that there were differences in two measurements: TB-IF on the right side and IF-IP on the right side (Table 2). With the use of the Tukey test, the following significances between groups were found: TB-IF on the right side and IF-IP on the right side in the removal *versus* sham-operated groups.

The mean values of the distances found on the radiographs of the hemimandibles of the removal, dissection and sham-operated groups are listed in Table 3. In the removal group there was a significant difference between sides in lower insertion of incisor to angular process (II-AP), but not in the remaining measurements. In the dissection group there was a significant difference between sides in lower insertion of incisor to condylar process (II-CP), and lower insertion of incisor to angular process (II-AP), but not in the remaining measurements. However, in the sham-operated group there was no significant difference between sides for all measurements.

In the comparison of the mandibular measurements among groups, the ANOVA demonstrated that there were differences in most measurements: TM-AN on the right side, TM-AN on the left side, II-AP on the right side, II-AP on the left side, II-CP on the right side, and II-CP on the left side (Table 4). Using the Tukey test, the following significances between groups were found: TM-AN on the right side in the removal *versus* dissection groups, TM-AN

Table 2 - Significance of the Analysis of Variance of the measurements from the axial radiographs.

Measurement	Side	p value	Group and Tukey's test		
			Removal	Dissection	Sham-operated
TB-MR	Right	0.073	-	-	-
TB-MR	Left	0.229	-	-	-
TB-IF	Right	0.017	a	ab	b
TB-IF	Left	0.153	-	-	-
IF-IP	Right	0.004	a	ab	b
IF-IP	Left	0.820	-	-	-

Distinct letters indicate statistically significant difference ($p \leq 0.050$). IP = Incisal point, IF = Infraorbital foramen, MR = Mesial root of the first molar, TB = Tympanic bulla.

on the right side in the removal *versus* sham-operated groups, TM-AN on the left side in the removal *versus* dissection groups, TM-AN on the left side in the removal *versus* sham-operated groups, II-AP on the right side in the removal *versus* sham-operated groups, II-AP on the left side in the removal *versus* sham-operated groups, II-CP on the right side in the removal *versus* sham-operated groups, II-CP on the left side in the removal *versus* dissection groups, and II-CP on the left side in the removal *versus* sham-operated groups.

Discussion

The present study has shown that the removal of

Table 3 - Mean values (mm) of the distances found on the lateral radiographs of the hemimandibles of all the groups and significance of the paired Student's *t*-test.

Group		Measurements			
		TM-AN	II-AP	II-CP	CP-AP
		mean ± sd	mean ± sd	mean ± sd	mean ± sd
Removal	Right side	6.59± 0.39	21.21 ± 1.35	24.50 ± 0.73	8.06 ± 0.74
	Left side	6.66± 0.21	24.05 ± 0.85	24.80 ± 0.59	8.36 ± 0.68
	p value	0.505	< 0.001	0.215	0.321
Dissection	Right side	6.19± 0.38	21.68 ± 1.75	23.64 ± 1.00	7.82 ± 0.55
	Left side	6.24 ± 0.20	23.22 ± 0.79	23.95 ± 0.78	8.06 ± 0.49
	p value	0.660	0.006	0.017	0.107
Sham-operated	Right side	6.04 ± 0.17	22.87 ± 1.77	23.47 ± 0.57	7.70 ± 0.63
	Left side	6.07 ± 0.17	22.92 ± 0.82	23.59 ± 0.64	7.92 ± 0.42
	p value	0.456	0.747	0.578	0.272

TM = Distal face of the third molar, AN = Antegonial notch, CP = Condylar process, II = Lower insertion of incisor, AP = Angular process.

the masseter muscle in growing rats induced shortening of the mandible with consequences to the maxilla. Thus, the final result was a shortened mandible associated with an atrophic angular process on the right side. The cephalometric evaluations also identified asymmetric areas in the maxilla. On the other hand, some asymmetry in the length of the maxilla and mandible was found when comparing sides in the detachment of the masseter muscle, but not among groups.

Mandibular asymmetries have been related to the experimental unilateral removal of the masseter muscle.^{15,16} Undersized mandibles are associated with bilateral resections of the masseter muscle.^{9,10} However, this study detected a shortening of the whole mandible, probably due to a refined mensuration method and to the statistical analyses used. Another significant finding was a shortening of the maxilla. The possibility of maxillary growth influencing mandibular growth and contrariwise by occlusal intercuspatation has been described.¹⁷ Occlusal disturbances were considered the main cause of asymmetry of the midface after experimental mandibular fractures.^{5,18} Gross modifications in the form of the mandible occurred after resections of the masseter and temporal muscles in the young rat, supporting the functional matrix theory of the mandibular growth.^{9,19} Similar findings are reported after the denervation of the masseter muscle.^{20,21} How-

Table 4 - Significance of the Analysis of Variance of the measurements from the lateral radiographs of the hemimandibles.

Measurement	Side	p value	Group and Tukey's test		
			Removal	Dissection	Sham-operated
TM-AN	Right	0.003	a	b	b
TM-AN	Left	< 0.001	a	b	b
II-AP	Right	0.029	a	ab	b
II-AP	Left	0.013	a	ab	b
II-CP	Right	0.016	a	ab	b
II-CP	Left	0.001	a	b	b
CP-AP	Right	0.447	-	-	-
CP-AP	Left	0.203	-	-	-

Distinct letters indicate statistically significant difference ($p \leq 0.050$). TM = Distal face of the third molar, AN = Antegonial notch, CP = Condylar process, II = Lower insertion of incisor, AP = Angular process.

ever, the possibility that the removal of the muscles from the mandible eliminates the blood supply to the regions of insertion may be considered.²²

Cephalometric evaluations from radiographs of dissected specimens using a computer system lead to reliable measurements.²³ The distances used in this study were similar to those used in other experiments.^{23,24} The distances shared significant differences between sides in the dissection group, but not among groups. This may be attributable to the

detachment followed by repositioning of the masseter muscle. The possibility of a decrease in growth caused by the periosteal lesion should be considered.²⁵ The effects of muscle reattachment comprise new bone formation to envelop the reorganizing tendon.¹² Similar findings were observed after transposition of the masseter muscle.²⁶

Contour alterations of the angular process in the removal group were another important finding. After unilateral masseterectomy in the young rat, the angular process became blunt.^{15,16} Similar alterations on the angular process occurred after denervation of the masseter muscle.²⁰ A study of the changes in the

gonial region induced by alterations of the masseter muscle length concluded that blood supply and function influence the shape of the gonial region.¹³

Conclusion

The present experimental study demonstrated that the unilateral removal of the masseter muscle in the growing period induced atrophic changes in the angular process, asymmetry of the maxilla, and shortening of the mandible. Dissection of this muscle induced asymmetry of the maxilla and the mandible which were not significant when comparing among groups.

References

- Sarnat BG. The biology of trauma on facial growth. *In*: Thaller SR, McDonald WS. Facial trauma. New York: Marcel Dekker; 2004. p. 55-85.
- Rodrigues L, Luz JGC. Conseqüências da remoção do côndilo mandibular no crescimento da maxila e da mandíbula: estudo experimental em ratos. *Acta Cir Bras*. 2001;16(1):15-25.
- Sarnat BG, Muchnic H. Facial skeletal changes after mandibular condylectomy in the adult monkey. *J Anat*. 1971 Feb;108(2):323-38.
- Sarnat BG. The face and jaws after surgical experimentation with the septo-vomer region in growing and adult rabbits. *Acta Otolaryngol*. 1970;268(Suppl.):1-30.
- Rocha EMVF, Goulart AC, Goldenberg S, Luz JGC. Efeitos da fratura de corpo da mandíbula no crescimento da maxila e da mandíbula: estudo experimental em ratos jovens. *Acta Cir Bras*. 2002;17(2):102-9.
- Rodrigues L, Miyazaki LT, Luz JGC. Conseqüências no crescimento de maxila e mandíbula de defeito ósseo cirúrgico no ramo da mandíbula de ratos. *Acta Cir Bras*. 2004;19(5):523-8.
- Bresin A, Kiliaridis S, Strid KG. Effect of masticatory function on the internal bone structure in the mandible of the growing rat. *Eur J Oral Sci*. 1999 Feb;107(1):35-44.
- Kiliaridis S. Masticatory muscle influence on craniofacial growth. *Acta Odontol Scand*. 1995 Jun;53(3):196-202.
- Lifshitz J. Comparative anatomic study of mandibular growth in rats after bilateral resections of superficial masseter, posterior temporal, and anterior digastric muscles. *J Dent Res*. 1976 Sep-Oct;55(5):854-8.
- Monje F, Delgado E, Navarro MJ, Miralles C, del Hoyo JRA. Changes in the temporomandibular joint caused by the vertical facial pattern. Study on an experimental model. *J Cranio Maxillofac Surg*. 1994 Dec;22(6):361-70.
- Poikela A, Kantomaa T, Tuominen M, Pirttiniemi P. Effect of unilateral masticatory function on craniofacial growth in the rabbit. *Eur J Oral Sci*. 1995 Apr;103(2):106-11.
- Chierici G, Miller AJ. Experimental study of muscle reattachment following surgical detachment. *J Oral Maxillofac Surg*. 1984 Aug;42(8):485-90.
- Hendricksen RP, McNamara JA, Carlson D S, Yellich GM. Changes in the gonial region induced by alterations of muscle length. *J Oral Maxillofac Surg*. 1982 Sep;40(9):570-7.
- Woodside DG, Altuna G, Harvold E, Herbert M, Metakos A. Primate experiments in malocclusion and bone induction. *Am J Orthod*. 1983 Jun;83(6):460-8.
- Avis V. The significance of the angle of the mandible: an experimental and comparative study. *Am J Phys Anthropol*. 1961 Mar;19:55-61.
- Horowitz SL, Shapiro HH. Modification of skull and jaw architecture following removal of the masseter muscle in the rat. *Am J Phys Anthropol*. 1955 Jun;13(2):301-8.
- Enlow DH. Facial growth. 3rd ed. Philadelphia: WB Saunders; 1990.
- Altonen M, Ranta R, Ylipaavalniemi P. Midface deviation due to mandibular fractures. An experimental study with clinical comparison. *J Maxillofac Surg*. 1978 May;6(2):143-7.
- Moss ML, Rankow R. The role of the functional matrix in mandibular growth. *Angle Orthod*. 1968 Apr;38(2):95-103.
- Kikuchi M, Lu CH, Sebata M, Yamamoto Y. The mandibular development of the rat after the denervation of the masseteric nerve. *Bull Tokyo Dent Coll*. 1978 May;19(2):75-86.
- Sato Y. Influence of asymmetry in the function of masseter muscle on the growing mandibular condyles. *J Osaka Univ Dent Soc*. 1986;31(1):137-64.
- Boyd TG, Castelli WA, Huelke DF. Removal of the temporalis muscle from its origin: effects on the size and shape of the coronoid process. *J Dent Res*. 1967 Sep-Oct;46(5):997-1001.
- Fuente del Campo A, Martinez Elizondo M, Melloni Magnelli L, Salazar Valadez A, Saavedra Ontiveros D. Craniofacial development in rats with early resection of the zygomatic arch. *Plast Reconstr Surg*. 1995 Mar;95(3):486-95.

24. Queiroz LI, Corrêa L, Luz JGC. Efeitos da solução de continuidade do arco zigomático no crescimento facial em ratos jovens. *Pesqui Odontol Bras.* 2002 Oct-Dec;16(4):374-8.
25. Koski K, Rönning O. Condyle neck periostomy and the mitotic activity in the condylar tissues of young rats. *Swed Dent J Suppl.* 1982;15:109-13.
26. Teixeira LA, Madeira MC, Martins AA. Transposição da inserção do músculo masseter e sua influência em modificações anatômicas músculo-esqueléticas, no coelho adulto. *Rev Odontol UNESP.* 1990;19(1):13-20.