

Cephalometric assessment of vertical control in the treatment of class II malocclusion with a combined maxillary splint

Ivana Uglik Garbui^(a)
 Paulo Roberto Aranha Nouer^(b)
 Darcy Flávio Nouer^(c)
 Maria Beatriz Araújo Magnani^(d)
 João Sarmento Pereira Neto^(d)

^(a)Assistant Professor; ^(b)Professor and Coordinator of Orthodontics – São Leopoldo Mandic Dental Research Center, Campinas, SP, Brazil.

^(c)Head Professor of Orthodontics; ^(d)Assistant Professor of Orthodontics – Piracicaba Dental School, University of Campinas, Piracicaba, SP, Brazil.

Abstract: Vertical control is one of the primary objectives sought by orthodontists when treating malocclusions in hyperdivergent individuals. This investigation aimed at assessing vertical control, by cephalometric measurements, during the treatment of Angle Class II Division 1 malocclusion. Thirty cases, selected from the files of the São Leopoldo Mandic Dental Research Center, Brazil, of subjects with Angle Class II Division 1 malocclusion and facial hyperdivergence, were used in this study. The patients were treated using a combined extraoral appliance during a mean treatment time of 1.1 years. Pre- and posttreatment cephalometric measurements were compared to assess vertical control. The results were submitted to ANOVA ($p = 5\%$). The ANOVA test revealed no statistically significant difference between the pretreatment and posttreatment values of OP (Occlusal plane angle) and SN.MP. While there was a decrease in Y-axis, FMA, and PP.MP, there was an increase in SN.PP, Co-Go, AFH, PFH, and FHI. It was concluded that the divergence in the facial lower third of the patients did not increase, suggesting that the combined extraoral appliance with the line of force application directed to the resistance center of the maxilla was effective in treating Angle Class II malocclusion in hyperdivergent subjects.

Descriptors: Malocclusion, Angle Class II; Orthodontics; Extraoral Traction Appliances; Cephalometry.

Introduction

One of the primary objectives sought by orthodontists in treating hyperdivergent individuals is maintaining vertical control during the extent of the malocclusion treatment. The introduction of extraoral traction combined with removable appliances made it possible to apply a force across the entire maxillary arch, with control of both the horizontal and the vertical components.

In 1957, Gould¹ reported that changes in the inclination of the outer arm of an extraoral appliance could affect the Line of Force Application (LFA) as well as dental movement. Among the orthopedic appliances to correct Angle Class II malocclusions is the Thurow maxillary splint,² also known as combined extraoral appliance (CEA),³ which delivers force through fixed inner arms located in the palate.

Corresponding author:

Ivana Uglik Garbui
 Rua Labatut, 144, Ipiranga
 São Paulo - SP - Brazil
 CEP: 04214-000
 E-mail: cdivana@uol.com.br

Received for publication on Apr 16, 2009
 Accepted for publication on Oct 08, 2009

The CEA is recommended especially for correcting Angle Class II malocclusions with maxillary protrusion, labially inclined upper incisors and well-positioned or retrusive mandibles. This device is effective when applied during the mixed dentition, at which time it can be used to correct malocclusions in two stages.^{2,4}

A good understanding of biomechanical concepts may optimize correction of Angle Class II malocclusion by using a CEA in association with a correctly directed line of force application, considering the desired movement and the center of resistance (CRe) of the molar, the maxilla and the nasomaxillary complex.^{5,6}

Since the extrusion of anchor molars is a common effect in using extraoral appliances that use these teeth as anchorage, the purpose of the present study was to assess vertical control in still growing hyperdivergent subjects with Angle Class II, Division 1 malocclusion, treated with an extraoral appliance combined with a palatal expander.

Material and Methods

The sample for the present study was selected from the files of scientific documentation of the São Leopoldo Mandic Dental Research Center, in compliance with Ministry of Health regulations, pursuant to Resolution n. 196/96 of the National Health Council of the Ministry of Health, dated 10/10/96, and was approved by the Research Ethics Committee, Piracicaba Dental School, University of Campinas, under protocol n. 002/2003.

Thirty cases (15 male and 15 female), selected from the files of subjects with Angle Class II, Division 1 malocclusion and facial hyperdivergence were used in this study. The patients were treated with a CEA, and the LFA was directed to the center of resistance (CRe) of the maxilla during a mean treatment time of 1.1 years. The documents included the casts and cephalometric radiographs of the subjects treated. Pre- and posttreatment cephalometric measurements were compared to assess vertical control. The following criteria of inclusion were adopted: patients with mixed and permanent dentition; with molar and canine relationships consistent with Angle Class II malocclusion; vertical growth pat-

tern confirmed by the cephalometric values of FMA ($\geq 30^\circ$), Y-axis (FHP.SGn $\geq 60^\circ$), SN.MP ($\geq 35^\circ$) and ANB ($\geq 4.5^\circ$).

The appliance consisted of an encapsulated (fully covered) acrylic resin plate with a 600-302 expansion screw (Dentaurum-Ispringen®, Germany) placed between the premolars or the second deciduous molars. A telescopic tube measuring 1.2 mm in diameter (Morelli®, Sorocaba, SP, Brazil) was inserted in the palatal region of the plate, allowing insertion and removal of a 045°/AR03X extraoral appliance (Morelli®, Sorocaba, SP, Brazil), when necessary. The extraoral appliance was tensioned by Interlandi headgear (Morelli®, Sorocaba, SP, Brazil). The internal arch of the extraoral appliance was inserted through the distal surface of the canines and adapted in the palate region, as near as possible to the CRe of the maxilla (according to Tanne *et al.*⁷, 1995, located 2 mm above the apex of the premolar roots) and to the CRe of the upper first molars (located 1-2 mm apically from the trifurcation). This arch was inserted through the anteroposterior telescopic tube ending next to the palatal root of the first molars. The anterior portion of the extraoral appliance was at a 5-6 mm distance from the labial surfaces of the upper incisors to allow breadth of movement. A 0.8 mm wire Hawley-type vestibular arch (Dentaurum-Ispringen®, Germany) was attached to the plate when necessary, to aid in the uprighting of the upper incisors when they presented buccoverision (Figure 1).

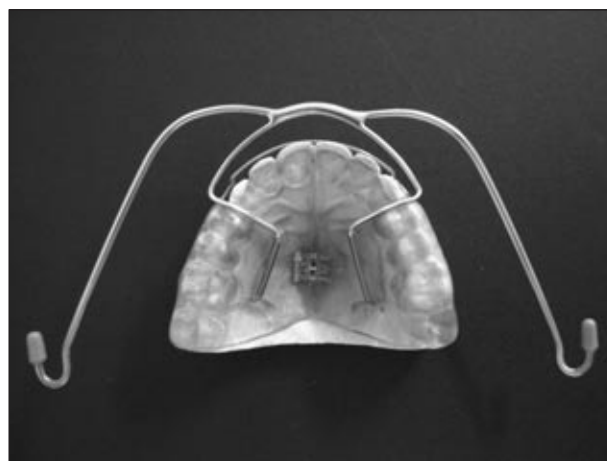


Figure 1 - Combined Extraoral Appliance.

The appliance was installed in such a way that the line of force of application was positioned over the CRe of the maxilla (Figures 2a and 2b), considering that this alignment was maintained by the traction applied by the Interlandi headgear. The force applied to each side was 250 g initially, gradually increasing up to 300 g. The patients were instructed to use the appliance 14 hours/day.

The cephalometric measurements used to assess vertical control were: Y-axis, occlusal plane angle,

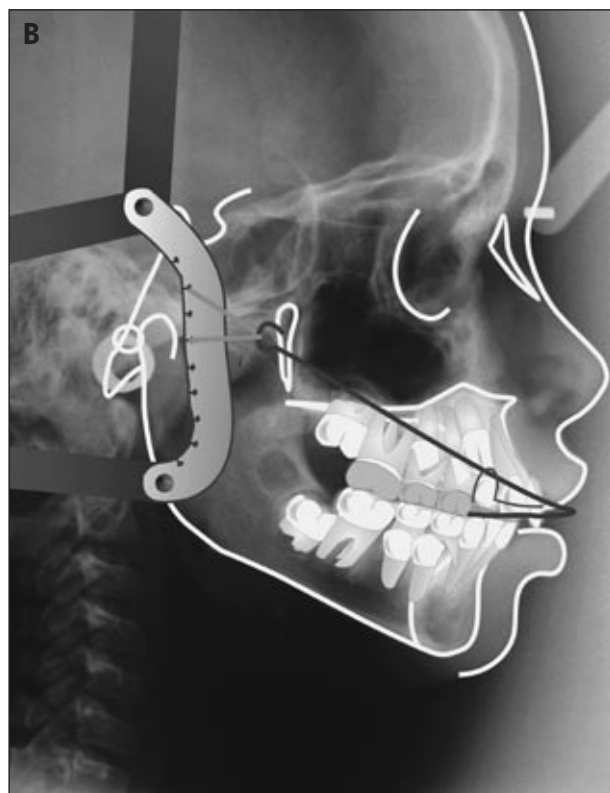
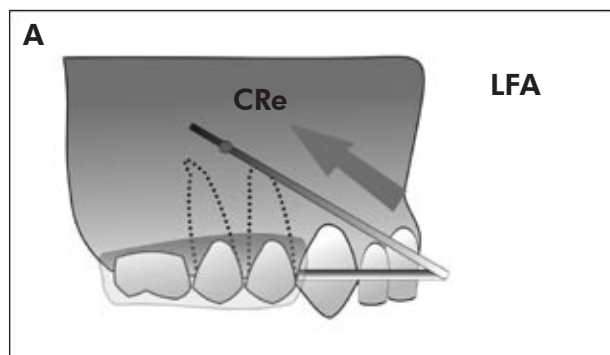


Figure 2 - A) Schematic of the direction of the line of force application (LFA) (Source: Nouer *et al.*⁶, 2004). **B)** Direction of the line of force application in the telerradiograph.

FMA, PP.MP, SN.MP, SN.PP, Co-Go, AFH, PFH and FHI (Figure 3). The cephalograms were traced by a single operator, and Dalhberg's error analysis was used to determine the method/operator error of the measurements (Table 1).

The errors obtained while making the measurements are summarized in Table 2. All values were within 30%, which is considered acceptable, and some were below 10%.

All the statistical calculations were performed using the Minitab software, version 14.2 (Minitab Inc., State College, PA, USA).

Results

The pre- and posttreatment mean ages of the subjects that took part in the present research are listed in Table 2.

Table 3 lists statistical analysis mean values and standard deviations of the measurements observed before and after treatment, as well as the result of

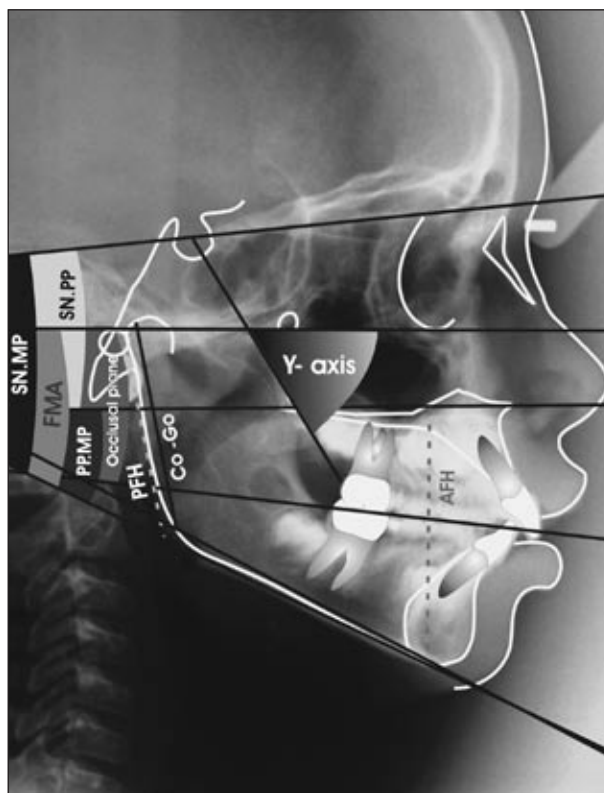


Figure 3 - Cephalometric measurements used to assess vertical control.

Table 1 - Operator precision while making measurements.

Measurements	Repeatability	Percentage
Y-axis	0.4183	19.22
OP	0.7416	19.01
ANB	0.0968	4.45
FMA	0.2500	16.24
SN.PP	0.2582	8.44
PP.MP	0.1369	7.23
AFH	0.9220	20.33
PFH	0.9487	19.34
Co-Go	0.8944	18.21
FHI	0.0027	18.61

Table 2 - Mean ages and standard deviations according to gender.

	Females	Males	Total
Start	9.60 ± 1.64	9.73 ± 1.91	9.67 ± 1.75
End	10.67 ± 1.88	11.00 ± 2.04	10.83 ± 1.93

Table 3 - Pre- and posttreatment measurement means and standard deviations according to gender, and statistical significance determined by the ANOVA method.

Variables	Females		Males		Descriptive Level	
	Pre	Post	pre	Post		
Angular (°)	Y-axis	64.10 ± 2.19	63.27 ± 2.77	63.67 ± 2.38	63.20 ± 2.68	0.038*
	OP	14.00 ± 3.96	13.53 ± 3.52	14.00 ± 3.00	13.27 ± 3.66	0.271
	FMA	32.43 ± 3.66	29.97 ± 4.38	33.20 ± 3.33	32.07 ± 3.92	0.000*
	PP.MP	32.67 ± 4.88	30.63 ± 4.19	34.50 ± 4.72	33.90 ± 5.47	0.006*
	SN.MP	40.00 ± 5.36	39.33 ± 6.55	40.53 ± 4.26	39.93 ± 5.01	0.155
	SN.PP	7.37 ± 3.11	8.13 ± 3.10	5.33 ± 3.48	5.57 ± 3.25	0.017*
Linear (mm)	Co-Go	51.13 ± 6.37	52.37 ± 6.59	48.67 ± 3.92	51.33 ± 3.83	0.000*
	AFH	61.67 ± 6.47	63.47 ± 5.11	62.80 ± 3.59	65.00 ± 4.60	0.000*
	PFH	41.40 ± 5.99	43.00 ± 5.44	40.07 ± 3.01	42.73 ± 3.26	0.000*
	FHI	0.664 ± 0.064	0.674 ± 0.054	0.632 ± 0.030	0.654 ± 0.047	0.042*

*statistically significant for $p < 0.05$.

the statistical significance of each measurement.

It can be observed that there was no significant difference between pre- and posttreatment measurements in either gender for the Occlusal Plane angle and for SN.MP.

On the other hand, there was a significant difference between before and after treatment values for Y-axis, FMA, PP.MP, SN.PP, AFH, PFH, Co-Go, and FHI in both genders.

Discussion

One of the fundamental goals of treating Angle Class II malocclusions with extraoral appliances at an early age, when the patient is still growing actively, is to exert vertical control during the corrective period. However, using extraoral appliances with internal arms inserted in buccal tubes in the upper molars requires double attention by the orthodontist, considering that, depending on the direction of

the applied force, the direction of growth of the nasomaxillary complex may also change as a result of a clockwise vector.

Between the 50s and the 80s, the study of biomechanics of extraoral traction appliances focused solely and exclusively on assessing the angle formed between the occlusal plane and the outer arms of the appliance, and on the effects produced on the maxilla.^{1,7-11} It was during this time that we gained the present knowledge that high traction forces result in better vertical control; that the resistance center of the nasomaxillary complex is located on the pterygomaxillary fissure, more specifically on its posterosuperior ridge; that the resistance center of the upper dental arch is a point resulting from the intersection of the prolongation of the dental axes; and that the combination of these factors determines the different vectors of displacement toward the maxilla and the teeth.

Thurrow² also reported on the changes inflicted on the upper molars, and, in 1975, designed an appliance that delivered the force generated by extraoral traction to all the upper teeth. Later, this appliance became known as the Thurrow maxillary splint. At first, it was designed with two inner arms embedded in the acrylic resin that covered the occlusal surfaces of the teeth, but changes were made through time to meet the individual needs of patients.

The present design of the appliance, as used in this study, is that of an acrylic plate that covers the palate and the occlusal and buccal surfaces of teeth, with removable inner arms inserted in the resin and extended up to the resistance center of the first molar.⁶

Analysis of the measurements for the vertical component shows that there is no statistically significant difference between the pre- and posttreatment values of the occlusal plane angle ($-0.47^\circ \pm 2.45^\circ$ for females and $-0.73^\circ \pm 3.34^\circ$ for males), suggesting that there is relative stability in the proportion of the middle third in relation to the face, since the occlusal plane maintained a constant position in relation to the Frankfort horizontal plane. In conjunction with the results for the SN.MP angle ($-0.67^\circ \pm 2.48^\circ$ for females and $-0.60^\circ \pm 2.26^\circ$ for males), it can further be suggested that there was no

significant clockwise rotation of the nasomaxillary complex or the jaw, indicating that there was no increase in facial divergence.

This observation can be reinforced by the reduction in the values for Y-axis ($-0.83^\circ \pm 1.38^\circ$ for women and $-0.47^\circ \pm 1.85^\circ$ for men), PP.MP ($-2.03^\circ \pm 1.89^\circ$ for women and $-0.60^\circ \pm 2.86^\circ$ for men) and FMA ($-2.46^\circ \pm 1.76^\circ$ for women and $-1.13^\circ \pm 2.06^\circ$ for men). These values presented little variation and even a slight increase in the growth of individuals in the same age bracket,¹² showing that there was no rotation at the base of the mandible. In regard to the SN.PP angle, a statistically significant increase was observed ($0.77^\circ \pm 1.02^\circ$ for women and $0.23^\circ \pm 1.13^\circ$ for men); nevertheless, clinically speaking, this increase may be considered small, thus propitiating closure of the anterior bite in individuals presenting it, since the face as a whole did not present clockwise growth after treatment.

The vertical control observed in the present study, considered very important in treating Class II malocclusions, has also been observed in other clinical reports^{4,13-15} in which the authors directed the line of force application toward the CRe of the maxilla, as was done in the present study. Disarticulating the occlusion favors the correction of Angle Class II malocclusion and prevents the extrusion of upper molars and incisors, an effect that is unwanted in the mechanics of retraction and that influences the rotation of the mandibular plane.¹⁵

The importance of vertical control ascertained up to now gains even greater ground when analyzing the behavior of facial heights. AFH values (1.80 ± 2.14 mm for women and 2.20 ± 1.74 mm for men) and PFH values (1.60 ± 2.26 mm for women and 2.67 ± 2.61 mm for men) had statistically significant increases, denoting a vertical growth expected in the lower third of the face,^{11,16} but still proportionally smaller if we consider the increase expected for these measurements in individuals in the same age bracket,¹² but remaining proportional to each other, as shown by the variation within the normal range observed for FHI values (0.010 ± 0.041 for women and 0.022 ± 0.041 for men), with no change in facial hyperdivergence. Furthermore, a greater increase in posterior facial height improves facial harmony, at-

tenuating the dolichocephalic facial pattern.

Retention of the vertical component is not always absolute when other dentoalveolar changes are associated to Class II malocclusion, in cases where low extraoral traction is applied.^{3,6,17}

How the line of force application (LFA) is directed is decisive in obtaining the desired response. In the present study, the LFA was directed to the resistance center of the maxilla, in order to gain distalization and intrusion of the upper molars, resulting in good vertical control. Therefore, the combined extraoral appliance is an option to be considered in treating Class II malocclusion in hyperdivergent in-

dividuals.¹⁸

Conclusions

It was concluded that there was vertical control of cephalometric measurements, shown by the absence of significant changes in the values for the occlusal plane and for SN.MP, and by a reduction in the values of the Y-axis, FMA and PP.MP angles. The results indicated that there was no increase in facial hyperdivergence and confirmed the efficacy of the CEA in correcting the malocclusion assessed in the treatment phase.

References

- Gould E. Mechanical principles in extraoral anchorage. *Am J Orthod.* 1957 May;43(5):319-33.
- Thurrow RC. Craniomaxillary orthopedic correction with en masse dental control. *Am J Orthod.* 1975 Dec;68(6):601-24.
- Henriques JFC, Freitas MR, Pinzan A. Estudo cefalométrico comparativo de dois tipos de ancoragem extrabucal (cervical e associada ao aparelho removível), em pacientes Classe II, divisão 1. *Ortodontia.* 1995;28(2):4-13.
- Almeida MR, Oliveira GF, Almeida RR, Almeida-Pedrin RR, Insabralde CMB. O tratamento da Classe II, divisão 1 com o uso do AEB conjugado e aparelho fixo. *Rev Clin Ortodon Dental Press.* 2002 Jun-Jul;1(3):63-71.
- Burstone CJ. The biomechanics of tooth movement. *In: Kraus BS, Riedel RA. Vistas in orthodontics.* Philadelphia: Lea & Febiger; 1962. p. 197-213.
- Nouer PRA, Rondelli CRM, Watanabe P, Miyamura ZY, Tavano O, Arsati YBOL. Arco extrabucal com inserção palatina conjugado com placa expansora encapsulada: considerações biomecânicas tridimensionais. *Rev Dent Press Ortodon Ortop Facial.* 2004;5(2 Suppl):5-20.
- Tanne K, Matsubara S, Sakuda M. Location of the centre of resistance for the nasomaxillary complex studied in a three-dimensional finite element model. *Br J Orthod.* 1995 Aug;22(3):227-32.
- Merrifield LL, Cross JJ. Directional forces. *Am J Orthod.* 1970 May;57(5):435-64.
- Joffe L, Jacobson A. The maxillary orthopedic splint. *Am J Orthod.* 1979 Jan;75(1):54-69.
- Dermaut LR, Kleutghen JP, De Clerck HJ. Experimental determination of the center of resistance of the upper first molar in a macerated, dry human skull submitted to horizontal headgear traction. *Am J Orthod Dentofacial Orthop.* 1986 Jul;90(1):29-36.
- Teuscher U. An appraisal of growth and reaction to extraoral anchorage. Simulation of orthodontic-orthopedic results. *Am J Orthod.* 1986 Feb;89(2):113-21.
- Martins DR, Janson GRP, Almeida RR, Pinzan A, Henriques JFC, Freitas MR. Atlas de Crescimento Craniofacial. São Paulo: Santos; 1998.
- Seçkin O, Surucu R. Treatment of Class II, division 1 cases with a maxillary traction splint. *Quintessence Int.* 1990 Mar;21(3):209-15.
- Castanha Henriques JF, Rodrigues Martins D, de Araújo Almeida G, Ursi WJ. Modified maxillary splint for Class II, division 1 treatment. *J Clin Orthod.* 1991 Apr;25(4):239-45.
- Uner O, Yücel-Eroglu E. Effects of a modified maxillary orthopaedic splint: a cephalometric evaluation. *Eur J Orthod.* 1996 Jun;18(3):269-86.
- You ZH, Fishman LS, Rosenblum RE, Subtelny JD. Dentoalveolar changes related to mandibular forward growth in untreated Class II persons. *Am J Orthod Dentofacial Orthop.* 2001 Dec;120(6):598-607; quiz 676.
- Fotis V, Melsen B, Williams S, Droschl H. Vertical control as an important ingredient in the treatment of severe sagittal discrepancies. *Am J Orthod.* 1984 Sep;86(3):224-32.
- Henriques JFC, Pinzan A, Almeida RR, Janson GRP, Takahashi R, Hayasaki SM. Controle da dimensão vertical com o aparelho removível conjugado à ancoragem extrabucal no tratamento da Classe II, 1ª divisão. *Rev Clin Ortodon Dental Press.* 2003 Aug-Sep;2(4):53-64