

Effectiveness of rotatory and reciprocating movements in root canal filling material removal

Emmanuel João Nogueira Leal SILVA^(a)
Nayra Bittencourt ORLOWSKY^(b)
Daniel Rodrigo HERRERA^(c)
Ricardo MACHADO^(d)
Renato Liess KREBS^(b)
Tauby de Souza COUTINHO-FILHO^(b)

^(a)Universidade Grande Rio, Faculdade de Odontologia, Department of Endodontics, Duque de Caxias, RJ, Brazil.

^(b)Universidade Estadual do Rio de Janeiro – UERJ, Faculdade de Odontologia, Department of Endodontics, Rio de Janeiro, RJ, Brazil.

^(c)University of Campinas – Unicamp, Piracicaba Dental School, Department of Restorative Dentistry, Piracicaba, SP, Brazil.

^(d)Private Practice, Navegantes, SC, Brazil.

Declaration of Interests: The authors certify that they have no commercial or associative interest that represents a conflict of interest in connection with the manuscript.

Corresponding Author:
Emmanuel João Nogueira Leal Silva
E-mail: nogueiraemmanuel@hotmail.com

DOI: 10.1590/1807-3107BOR-2015.vol29.0008

Submitted: Nov 30, 2013
Accepted for publication: Aug 27, 2014
Last revision: Oct 16, 2014

Abstract: The purpose of this study was to compare the efficacy of reciprocating and rotary techniques for removing gutta-percha and sealer from root canals. Forty straight and oval single-rooted premolars were prepared up to size 30, filled with gutta-percha and sealer, and then randomly allocated to two experimental retreatment groups: ProTaper Retreatment System (PTRS) and WaveOne System (WS). Procedural errors, time of retreatment and apically extruded material were recorded for all the roots. The roots were radiographed after retreatment. The percentage of residual material was calculated using image analysis software. The data were analyzed by Kolmogorov-Smirnov and t tests, with a significance level set at 5%. No system completely removed the root filling material from the root canal. No significant differences were observed between the systems, in terms of residual filling material in any tested third ($p > 0.05$). WS was faster in removing filling material than PTRS ($p < 0.05$). Extrusion was observed in 4 cases in PTRS and in 5 cases in WS. No procedural errors were observed in either group. It can be concluded that although no differences were observed in the efficacy of PTRS and WS for removing root filling material, WS was faster than PTRS.

Keywords: Endodontics; Retreatment; Gutta-Percha.

Introduction

Although root canal treatments have a success rate of higher than 90% when properly conducted,^{1,2} failures may occur and are often associated with poorly treated canals.² Problems related to canal anatomy,³ as well as microbial factors, can explain failure rates of about 8% for treated canals.⁴ In these cases, endodontic retreatment of the root canal system is necessary.⁵ This retreatment requires the removal of the original root canal filling, further cleaning, shaping, and refilling.⁶

Numerous techniques have been proposed for removing root filling materials, including stainless steel hand files,^{7,8} adjunctive solvents and/or ultrasonics,^{9,10} and nickel-titanium (NiTi) rotary systems.^{7,8,11,12} ProTaper Universal rotary system improved the previous ProTaper series by adding rotary retreatment instruments designed specifically to remove obturation material from root canals, and studies have reported their efficacy, cleaning ability and safety.^{7,11,12,13}

Recently, a new technique using reciprocating motion was proposed for endodontic treatment.¹⁴ The method relieves stress on the instrument by using special counterclockwise (cutting action) and clockwise (release of the instrument) movements. This extends the durability of the NiTi rotary instrument and increases its resistance to fatigue, in comparison with continuous rotation motion.^{15,16} WaveOne is one of the available reciprocating systems. It is a single-file reciprocating root canal preparation system that alternates different degrees of counterclockwise (CCW) and clockwise (CW) rotation movements, allowing the file to rotate 360° after performing 3 reciprocating movements. Even though there is growing evidence of safety and shaping effectiveness of the reciprocating motion,^{14,17,18,19,20,21} there is still limited knowledge of the potential benefits of using this system in retreatment cases.^{22,23}

The purpose of this study was to evaluate the efficacy of removing filling materials from oval-shaped root canals using the ProTaper Retreatment System (PTRS), and compare the results with those obtained with the WaveOne System (WS). The time required for gutta-percha removal, the apical extrusion of filling materials and the number of instrument fractures were also evaluated. The null hypothesis was that no differences regarding effectiveness of filling material removal could be found between WaveOne and ProTaper Retreatment systems.

Methodology

Tooth selection and preparation

Eighty-seven human permanent maxillary premolars were selected from a random collection of extracted teeth obtained after receiving the respective patients' informed consent, under a protocol approved by the local Ethics Committee Review Board. Digital periapical radiographs (IDA, Dabi Atlante, Ribeirão Preto, Brazil) were taken in the buccolingual and mesiodistal directions to select only teeth with complete formation of the apex, absence of endodontic treatment and presenting single, oval-shaped root canals, with a cross-section diameter ratio of ≥ 2.5 , as measured 5 mm from the apex.²⁴ After accessing the cavity, canal patency was established with a size 10 K-type file (Dentsply Maillefer, Ballaigues, Switzerland). Canals

showing patency greater than size 20, as defined by the International Standards Organization Regulation (ISO 3631-1) and/or showing more than 15 degrees root curvature were also discarded.

Root canal preparation and filling

The working length (WL) was established by deducting 1 mm of the length, making a size 15-K file visible at the apex. Initial root canal preparation was performed using the ProTaper Universal instruments (Dentsply Maillefer), according to the manufacturer's instructions. The following sequence was used: SX file (1/2 of the WL), S1 file (2/3 of the WL), S2 file (2/3 of the WL), and F1, F2, and F3 files (full WL). Root canal preparation was performed using a VDW silver engine (VDW, Munich, Germany) using the manufacturer's (Dentsply Maillefer) recommended torque and speed: SX and S1 file (300 rpm and 3 N cm); S2 file (300 rpm and 1 N cm); and F1, F2 and F3 files (300 rpm and 2 cm). The canals were irrigated during root canal preparation with 2 mL of 5.25% sodium hypochlorite (NaOCl) between each file. The smear layer was then removed with 5 mL of 17% ethylenediaminetetraacetic acid (EDTA) during 3 minutes, followed by rinsing with a total of 10 mL of twice-distilled water. Canals were dried with paper points after instrumentation, and filled with a .06 taper gutta-percha point size 35, coated with AH Plus sealer (Dentsply De Trey, Konstanz, Germany), using the continuous wave of condensation technique (System B, Analytic Technology, Redmond, USA). Access cavities were sealed with a temporary filling material (Coltosol F, Cöltene/Whaledent AG, Alstatten, Switzerland). The teeth were radiographed in the buccolingual and mesiodistal directions to assess the quality of the filling procedure and the presence of bubbles. One sample displaying a radiographic void inside the gutta-percha was discarded. Another tooth was included to replace this sample. The samples were then placed in 100% humidity for 14 days to ensure complete setting of the sealer.²⁵ After this period, the teeth were pair-matched according to their shape and size, and one tooth from each pair was randomly distributed (<http://www.random.org>) into 2 experimental groups (n = 20). A single operator carried out the initial treatment, another one, the retreatment procedures, and a third one, the evaluations.

Root Canal Retreatment

Canal filling material was removed from both PTRS and WS groups with files, using a crown-down technique with three, slow in-and-out pecking motions and a brushing action.

The instruments in the PTRS group (Dentsply-Maillefer, Ballaigues, Switzerland) were used as follows: D1 (size 20, .09 taper) for the cervical third, D2 (25/08) for the middle third and D3 (20/07) and F4 (40/06) for the apical third. The instruments were used with a VDW electric motor (VDW, Munich, Germany) at a speed of 600 rpm for D instruments, and at 300 rpm for the F4 instrument, with a torque of 2 N cm^{-1} , according to the manufacturer's instructions.

Canal filling material in the WS group was removed using a Large WaveOne file (Dentsply-Maillefer, Ballaigues, Switzerland), with size 40 at the tip and a taper of .06 over the first 3 mm, applied with reciprocating motion. The instruments were used with a VDW electric motor using the WaveOne motion program, according to the manufacturer's instructions.

No solvent was used in any group to prevent any interference with the removability of the materials in each system, and with the evaluation of this removability. Each time the instruments were withdrawn, they were wiped with gauze to remove the adherent filling material and debris. Canals were irrigated with 3 mL of 5.25% NaOCl at each change of file, and 10 mL of 5.25% NaOCl was used for the final flush. The root canals were then dried with paper points. Retreatment was considered complete when no gutta-percha or sealer was detected on the instrument surfaces or inside the root canal or dentinal walls. A dental operating microscope (DFV, Valença, Brazil) was used throughout.

Gutta-percha removal assessment

Digital radiographic images of the roots were captured in both the mesiodistal and buccolingual direction, at a fixed distance of 10 cm. The images were transferred to image analysis software (UTHSCSA Image Tool 3.0, San Antonio, USA) to measure the areas of residual filling material and root canal walls.

Starting from the cement-enamel junction, the roots were measured to determine the exact length, which was then divided into three equal parts (cervi-

cal, middle and apical third). The areas with remaining filling materials (gutta-percha/sealer) in each root canal third were identified, outlined and measured by one blinded observer using a manual threshold. Total canal areas and corresponding remaining filling material areas were calculated by adding the values obtained from the three thirds, as previously described.^{2,25} The area percentages of remaining filling material were calculated by dividing the filling-material-covered areas by the designated canal areas and multiplying by 100. The averages of the values obtained from the radiographic measurements for the mesiodistal and buccolingual directions were used.²⁵

Time required for gutta-percha removal

The total time needed to complete the procedure was recorded for each sample. Time measurements were performed by the same operator. Time included the irrigation protocol during the retreatment and file changes.

Apical extrusion

Extrusion of root canal filling material debris through the apical foramen was observed visually using an operating microscope. The samples where gutta-percha remnants could be observed beyond the apex were recorded.

Procedural errors

The number and type of fractured and deformed instruments were recorded. An operating microscope was used to verify the fracture and deformations.

Statistical analysis

The data were analyzed by Kolmogorov-Smirnov and *t* tests, with a significance level set at 5%.

Results

All the teeth had remnants of filling material in the canal, except for 2 teeth in the PTRS group and 1 in the WS group. Table 1 shows the averages of the residual filling material area in relation to the root canal area after instrumentation for each group. Analysis of the total area revealed no statistical differences between the two systems tested ($p > 0.05$) (Figure 1). Both groups also showed similar results in all tested thirds, without any statistical differences ($p > 0.05$).

Table 1. Area of residual filling material (means ± standard deviations) of each specimen third after instrumentation, as well as statistical significance*.

Group	Cervical	Middle	Apical	Total
WS	1.2% (2.2) ^{Aa}	5.9% (8.3) ^{Aa}	26.5% (23.1) ^{Ab}	9.0% (8.5) ^A
PTRS	2.2% (3.3) ^{Aa}	3.8% (6.4) ^{Aa}	23.3% (17.8) ^{Ab}	8.5% (9.2) ^A

*In each column, values followed by same capital letters are statistically similar ($p > .05$). In each row, different lowercases represent significant differences among the different root canal thirds in the same group ($p < .05$).

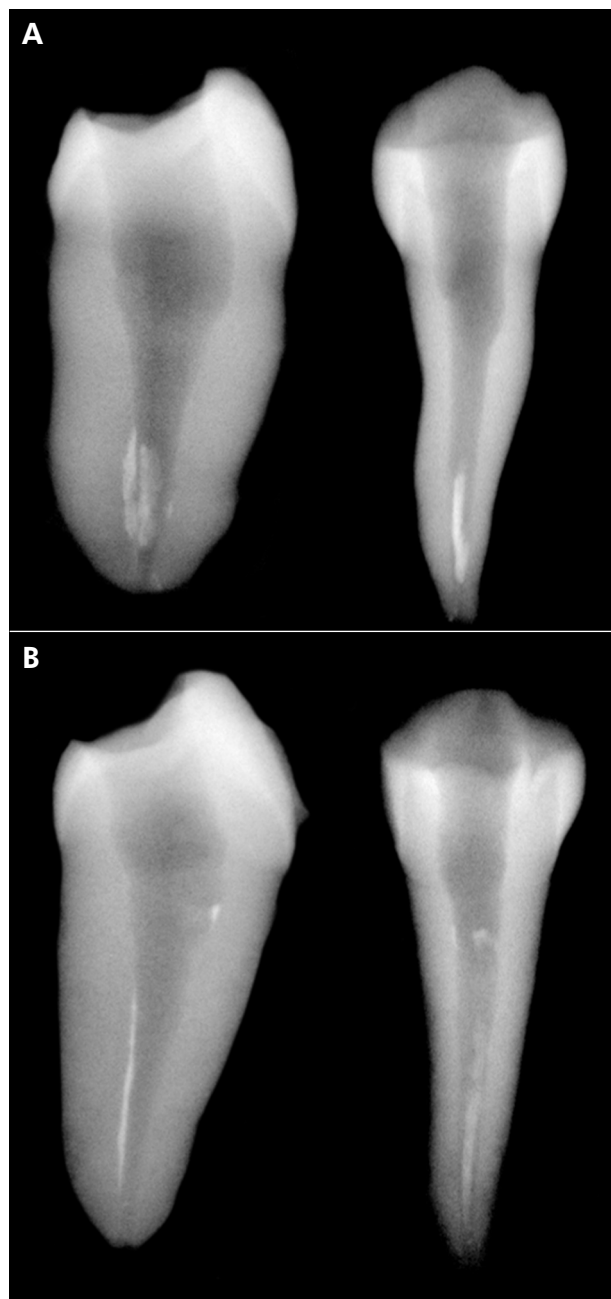


Figure 1. Representative radiographs of (A) PTRS and (B) WS in mesiodistal and buccolingual directions, showing filling remnants.

Regarding the retreatment mean time, WS removed gutta-percha significantly faster than PTRS ($p < 0.05$) (Table 2). PTRS and WS had apical extrusion of gutta-percha in four (20%) and five cases (25%), respectively ($p > 0.05$). No fractured instrument and no permanently deformed files were noted in either group.

Discussion

A major goal of root canal retreatment is to remove filling material, because doing so promotes the effective action of instruments and irrigating solutions on debris and microorganisms responsible for apical periodontitis.^{8,21,22,25} To date, it has not been proven that complete removal of filling materials will ensure success of root canal retreatment, or that any remaining material will cause retreatment failure. However, removing as much filling material as possible would seem essential in uncovering any remaining necrotic tissue or bacterial remnants that may be responsible for periapical inflammation and persistent disease.

New NiTi instruments designed to work with reciprocating motion have recently been marketed, including WS. This study set out to evaluate the effectiveness of this instrument in removing the filling material from within the root canal space, and to compare it with PTRS. To standardize the procedures, a single operator carried out the initial treatment, another one, the retreatment procedures, and a third one, the evaluations.

As in previous studies, none of the retreatment techniques allowed complete removal of filling material.^{7,22,23,25,26} These studies reported the virtual impossibility of removing 100% of the residual gutta-percha and sealer from root canal walls, irrespective of the technique used for filling material removal. In this study, no significant cleansing differences were found between WS and PTRS. The favorable results observed for the WaveOne system corroborated those reported

Table 2. Means \pm standard deviations of the time necessary for retreatment, number and percentage of specimens (%) that had apically extruded material, and number and percentage of specimens (%) that had file fracture recorded for the different groups, as well as statistical significance*.

Group	Time (s)	Extrusion (%)	Fracture (%)
WS	172.3 \pm 41.3 ^A	4 (20) ^A	0 (0) ^A
PTRS	245.0 \pm 62.9 ^B	5 (25) ^A	0 (0) ^A

*Different capital letters represent significant differences between the tested groups ($p < .05$)

previously,^{22,23} in which single-file reciprocating systems showed results similar to full-sequence rotary and hand systems. The reciprocating motion, together with the marked taper of WaveOne files, creates a greater contact area between the instrument and the gutta-percha, allowing filling removal as effective as that produced by full-sequence rotary systems. In addition, no differences between PTRS and WS were observed in apically extruded debris and procedural errors; however, WS needed less time to perform retreatment than PTRS. Therefore, the null hypothesis was rejected. The better time results for WS indicate that this system may have similar efficacy during endodontic retreatment, *i.e.*, it requires a shorter time than PTRS. The rationale to explain the better time-related results is that only one file was used in the WS group, whereas four files were needed to perform the retreatment in the PTRS group. The PTRS consisted of three files; however, as suggested in previous studies,^{3,8} further root canal refining is necessary because of the apical diameter of the D3 ProTaper Retreatment file (size 20). The last instrument designed to reach the working length does not permit complete cleansing action at the apical portion. In this study, ProTaper F4 was used to complete the removal of the PTRS and to match the tip of the used WaveOne file (WaveOne Large). Apical enlargement was performed from size 30 to a final size 40. The option to use this final size was based on previous investigations, which showed that apical enlargement by two sizes beyond the initial preparation size significantly reduced the amount of residual filling material.^{5,11}

According to the results of this study, apical debris extrusion occurred regardless of the instrument type used, with no differences between the two groups. A recent study showed statistically significant differences when comparing the ProTaper Treatment System and WS, with a greater amount of extruded debris in the WS group.²⁷ Moreover, different continuous

rotation systems and therapeutic procedures used in the studies can explain the differences observed.

One important methodological aspect that needs to be addressed is related to tooth selection. Oval canals were selected, because they represent a major challenge for performing endodontic retreatment. High anatomical variability exists regarding the shape, size, and dimensions of these teeth.²⁴ No standardization, such as tooth length, was performed in the present study; however, special care was taken to obtain groups that were as balanced as possible in terms of anatomical features. As previously suggested, pair-matching of the teeth was sought when the groups were formed, thus equalizing the challenge levels and boosting the statistical power of the study.²⁴

This study was carried out on teeth with straight root canals, and the conclusions cannot be directly extended to teeth with curved root canals. The efficacy, maintenance of original canal morphology and safety of the reciprocating instruments during retreatment of teeth with complicated root canal anatomy are issues that remain to be investigated.

Conclusion

No differences were observed in the efficacy of the ProTaper Retreatment System and the WaveOne System in removing root filling material. Apical thirds showed more residual filling than middle and cervical thirds, in both groups.

Acknowledgements

The authors deny any conflicts of interest related to this study, and assert that they have no financial affiliation (*e.g.*, employment, direct payment, stock holdings, retainers, consultancies, patent licensing arrangements or honoraria), or involvement with any commercial organization having any direct financial interest in the subject or materials discussed in this manuscript.

References

1. Imura N, Pinheiro ET, Gomes BP, Zaia AA, Ferraz CC, Souza-Filho FJ. The outcome of endodontic treatment: a retrospective study of 2000 cases performed by a specialist. *J Endod.* 2007 Nov;33(11):1278-82.
2. Mollo A, Botti G, Principi Goldoni N, Randellini E, Paragliola R, Chazine M, et al. Efficacy of two Ni-Ti systems and hand files for removing gutta-percha from root canals. *Int Endod J.* 2012 Jan;45(1):1-6.
3. Torabinejad M, Corr R, Handysides R, Shabahang S. Outcomes of nonsurgical retreatment and endodontic surgery: a systematic review. *J Endod.* 2009 Jun;35(7):930-7.
4. Masiero AV, Barletta FB. Effectiveness of different techniques for removing gutta-percha during retreatment. *Int Endod J.* 2005 Jan;38(1):2-7.
5. Friedman S. Considerations and concepts of case selection in the management of post-treatment endodontic disease (treatment failure). *Endod Topics.* 2002 Mar;1(1):54-78.
6. Stabholz A, Friedman S. Endodontic retreatment—case selection and technique. Part 2: treatment planning for retreatment. *J Endod.* 1988;14(12):607-14.
7. Bramante CM, Fidelis NS, Assumpção TS, Bernardineli N, Garcia RB, Bramante AS, et al. Heat release, time required, and cleaning ability of MTwo R and ProTaper Universal retreatment systems in the removal of filling material. *J Endod.* 2010 Nov;36(1):1870-3.
8. Takahashi CM, Cunha RS, De Martin AS, Fontana CE, Silveira CFM, Bueno CES. In vitro evaluation of the effectiveness of ProTaper Universal rotary retreatment system for gutta-percha removal with or without a solvent. *J Endod.* 2009 Nov;35(11):1580-3.
9. Giuliani V, Cocchetti R, Pagavino G. Efficacy of ProTaper Universal retreatment files in removing filling materials during root canal retreatment. *J Endod.* 2008 Nov;34(11):1381-4.
10. Ünal GC, Kaya BU, Taç AG, Keçeci AD. A comparison of the efficacy of conventional and new retreatment instruments to remove gutta-percha in curved root canals: an ex vivo study. *Int Endod J.* 2009 Apr;42(4):344-50.
11. Baratto Filho F, Ferreira EL, Fariniuk LF. Efficiency of the 0.04 taper ProFile during the re-treatment of gutta-percha-filled root canals. *Int Endod J.* 2002 Aug;35(8):651-4.
12. Gergi R, Sabbagh C. Effectiveness of two nickel-titanium rotary instruments and a hand file for removing gutta-percha in severely curved root canals during retreatment: an ex vivo study. *Int Endod J.* 2007 Jul;40(7):532-7.
13. Reis Sô MV, Saran C, Magro ML, Vier-Pelisser FV, Munhoz M. 2008 Efficacy of ProTaper retreatment system in root canals filled with gutta-percha and two endodontic sealers. *J Endod.* 2008 Oct;34(10):1223-5.
14. Yared G. Canal preparation using only one Ni-Ti rotary instrument: preliminary observations. *Int Endod J.* 2008 Apr;41(4):339-44.
15. De-Deus G, Brandão MC, Barino B, Di Giorgi K, Fidel RA, Luna AS. Assessment of apically extruded debris produced by the single-file ProTaper F2 technique under reciprocating movement. *Oral Surg Oral Med Oral Pathol Oral Radiol Endod.* 2010 Sep;110(3):390-4.
16. Varela-Patiño P, Ibañez-Párraga A, Rivas-Mundiña B, Cantatore G, Otero XL, Martín-Biedma B. Alternating versus continuous rotation: a comparative study of the effect on instrument life. *J Endod.* 2010 Jan;36(1):157-9.
17. Alves FR, Rôças IN, Almeida BM, Neves MA, Zoffoli J, Siqueira Júnior JF. Quantitative molecular and culture analyses of bacterial elimination in oval-shaped root canals by a single-file instrumentation technique. *Int Endod J.* 2012 Sep;45(9):871-7.
18. Arias A, Perez-Higueras JJ, de la Macorra JC. Differences in cyclic fatigue resistance at apical and coronal levels of Reciproc and WaveOne new files. *J Endod.* 2012 Sep;38(9):1244-8.
19. Bürklein S, Hinschitzka K, Dammaschke T, Schäfer E. Shaping ability and cleaning effectiveness of two single-file systems in severely curved root canals of extracted teeth: Reciproc and WaveOne versus Mtwo and ProTaper. *Int Endod J.* 2012 May;45(5):449-61.
20. Pirani C, Pelliccioni GA, Marchionni S, Montebugnoli L, Piana G, Prati C. Effectiveness of three different retreatment techniques in canals filled with compacted gutta-percha or Thermafil: a scanning electron microscope study. *J Endod.* 2009 Oct;35(10):1433-40.
21. Roggendorf MJ, Legner M, Ebert J, Fillery E, Frankenberger R, Friedman S. Micro-CT evaluation of residual material in canals filled with Activ GP or GuttaFlow following removal with NiTi instruments. *Int Endod J.* 2010 Mar;43(3):200-9.
22. Rios MA, Villela AM, Cunha RS, Velasco RC, De Martin AS, Kato AS, et al. Efficacy of 2 reciprocating systems compared with a rotary retreatment system for gutta-percha removal. *J Endod.* 2014 Apr;40(4):543-6.
23. Zuolo AS, Mello Junior JE, Cunha RS, Zuolo ML, Bueno CE. Efficacy of reciprocating and rotary techniques for removing filling material during root canal retreatment. *Int Endod J.* 2013 Oct;46(10):947-53.
24. De-Deus G, Accorsi-Mendonça T, Silva LC, Leite CAS, Silva D, Moreira EDJ. Self-adjusting file cleaning-shaping-irrigation system improves root-filling bond strength. *J Endod.* 2013 Feb;39(2):254-7.
25. Somma F, Cammarota G, Plotino G, Grande NM, Pameijer CH. The effectiveness of manual and mechanical instrumentation for the retreatment of three different root canal filling materials. *J Endod.* 2008 Apr;34(4):466-9.
26. Xu LL, Zhang L, Zhou XD, Wang R, Deng YH, Huang DM. Residual filling material in dentinal tubules after gutta-percha removal observed with scanning electron microscopy. *J Endod.* 2012 Mar;38(3):293-6.
27. Bürklein S, Schäfer E. Apically extruded debris with reciprocating single-file and full-sequence rotary instrumentation systems. *J Endod.* 2012 Jun;38(6):850-2.