

Associations between *orbicularis oris* thickness and skeletal and dental variables in mixed dentition

Associações entre espessura do orbicularis oris e variáveis esqueléticas e dentárias na dentição mista

Taís de Souza BARBOSA^a, Maria Beatriz Duarte GAVIÃO^a, Luciana Silveira PUPO^a,
Paula Mídori CASTELO^b, Luciano José PEREIRA^c

^aDepartamento de Odontologia Infantil, Faculdade de Odontologia de Piracicaba,
UNICAMP – Universidade Estadual de Campinas, 13414-903 Piracicaba - SP, Brasil

^bDepartamento de Ciências Biológicas, UNIFESP – Universidade Federal de São Paulo,
09972-270 Diadema - SP, Brasil

^cDepartamento de Medicina Veterinária, UFLA – Universidade Federal de Lavras,
37200-000 Lavras - MG, Brasil

Resumo

Objetivo: Verificar a associação entre a espessura do *orbicularis oris* e as variáveis esqueléticas e dentárias em crianças com dentição mista. **Material e método:** Foi selecionada uma amostra de conveniência de 22 crianças, de 7 a 12 anos, com maloclusões Classe I e Classe II esqueléticas e subdivisões. As espessuras dos fascículos superior e inferior do *orbicularis oris* foram mensuradas, em repouso e em contração, por um examinador treinado utilizando ultrassom. As medidas cefalométricas dos tecidos duros e moles foram calculadas por um examinador treinado. Os resultados foram analisados pelos coeficientes de Pearson e Spearman. **Resultado:** Houve correlação negativa entre os fascículos superior e inferior do *orbicularis oris* em contração e a distância entre a linha E de Ricketts e o lábio superior ($E \perp Ls$). Houve correlação positiva entre a altura inferior da face e a distância entre o plano AB e o lábio superior (AB-Ls) e entre o ângulo ANB e a distância entre $E \perp Ls$ e a linha E de Ricketts e o lábio inferior ($E \perp Li$). A distância do incisivo inferior do plano N-Pg correlacionou-se positivamente com a distância entre AB-Ls e a distância entre $E \perp Ls$ e $E \perp Li$. A sobremordida e o ângulo interincisal correlacionaram-se negativamente com a distância entre o pogônio e o pogônio mole e a distância entre $E \perp Li$, respectivamente. **Conclusão:** As variáveis esqueléticas e dentárias estiveram associadas à posição dos lábios superior e inferior e a espessura do pogônio, enquanto que as espessuras dos fascículos superior e inferior do *orbicularis oris* em contração estiveram associadas à retrusão do lábio superior.

Descritores: Cefalometria; criança; má oclusão, ultrassonografia.

Abstract

Aim: To evaluate the association between *orbicularis oris* thickness and skeletal and dental variables in children with mixed dentition. **Material and method:** A convenience sample of 22 children, aged 7 to 12 years, with skeletal Class I and Class II malocclusion and subdivisions were selected. The upper and lower fascicles of the *orbicularis oris* thicknesses were measured using ultrasound (US) by one calibrated examiner, at rest and in the contracted state. Cephalometric radiograph measurements of the hard and soft tissues were calculated by one trained examiner. The results were analyzed by the Pearson and Spearman coefficients. **Result:** The upper and lower fascicles of the *orbicularis oris* in the contracted state showed a negative correlation with the distance between Ricketts' E-line and the labrale superius ($E \perp Ls$). There were positive correlations between the lower face height and the distance between the AB plane and the labrale superius (AB-Ls) and between the ANB angle and the distance between $E \perp Ls$ and Ricketts' E-line and the labrale inferius ($E \perp Li$). The lower-incisor distance from the N-Pg plane correlated positively with the distance between AB-Ls and the distance between the $E \perp Ls$ and $E \perp Li$. Overbite and interincisal angle were negatively correlated with the distance between the pogonion and the soft tissue pogonion and the distance between $E \perp Li$, respectively. **Conclusion:** Skeletal and dental variables were associated with upper and lower lip position and pogonion thickness, while the upper and lower fascicles of the *orbicularis oris* thicknesses in the contracted state were associated only with upper lip retrusion.

Descriptors: Cephalometry; child; malocclusion; ultrasonography.

INTRODUCTION

The influence of the forces exerted by the lips, cheeks, and tongue on the positions of the teeth has been a subject of scientific debate. The teeth are positioned between the lips or cheeks on one side and the tongue on the other, and opposing forces or pressures from these structures can be determinants of tooth position¹. The main function of the lips, i.e., oral competence, is controlled by the *orbicularis oris* muscle², which is a concentric, sphincter-like muscle around the mouth that closes, withdraws, and protrudes the lips.

The effects of muscle thickness on bone morphology can be explained by a theory that is recognized in the field of biodynamics as Wolff's law³, which points out that the internal structure and the shape of the bone is closely related to function, defining the respective relationship³. Although bone is one of the hardest tissues in the body, it is one of the most responsive to change when the environmental balance is altered because the musculature exerts an influence on the size of their adjacent local skeletal sites in which the muscles are inserted or on which muscle force is exerted⁴. Moreover, the effect of muscle function on facial morphology is probably greatest during growth periods.

Past studies have demonstrated that the characteristics of the lips have an influence on lip responses to the retraction of the upper and lower incisors. Oliver⁵ (1982) found that patients with thin lips or a high lip strain displayed a significant correlation between incisor and lip retraction, which was not observed in patients with thick lips or low lip strain. Wisth⁶ (1974) found that lip response, as a proportion of incisor retraction, decreased as the amount of incisor retraction increased. These results suggest that the lips have some inherent spatial, functional, and structural features. However, the role of orofacial muscles in determining facial morphology and tooth position has not yet been elucidated.

In the past, the morphology of these muscles was based on studies of cadaver preparations. However, imaging with ultrasound (US) enables muscle thickness determination, even during muscle contraction⁷ in live subjects. US gives uncomplicated and reproducible access to jaw muscle function parameters and their interaction with the craniomandibular system⁸; it is a suitable method for children, with effectiveness and innocuity assured⁹⁻¹¹. Thus, the principal aims of this study were to determine ultrasonographic thickness of the lower and upper fascicles of the *orbicularis oris* muscle in pre-orthodontic children with mixed dentition having skeletal Class I and Class II malocclusion and subdivisions. Furthermore, the associations between muscle thickness and hard and soft tissue variables were evaluated using lateral cephalogram measurements.

MATERIAL AND METHOD

A convenience sample was selected from the files of the Department of Pediatric Dentistry and comprised 22 children, 13 boys and 9 girls, aged 7 to 12 years (mean 9.3 ± 1.3), with

skeletal Class I and Class II malocclusion and subdivisions. Oral and written explanations regarding the aim and research methodology were given to the children and their parents or guardians. The study was approved by the Ethical Research Committee of the Dental School (protocol n. 116/01). After reaching agreement, anamnesis was conducted to verify the medical and dental history and oral habits. The exclusion criteria were previous or current orthodontic treatment, tooth anomalies of structure or form, caries, crossbite, history and/or signs of clenching and bruxism, pacifier, or other parafunctional habits. The inclusion criteria indicated that children should be in good systemic health, without any alterations that could compromise the masticatory system and normal orofacial structures, the presence of fully erupted first permanent molars and central permanent incisors, and mandibular primary or permanent canines, maxillary primary canines, maxillary and mandibular first and second primary molars, or mandibular first premolars.

1. US Evaluation

The upper and lower fascicles of the *orbicularis oris* thicknesses were measured using the Just-Vision 200 Ultrasound System (Toshiba Corporation, Otawara, Japan). The images were obtained with a high-resolution real-time 56 mm/10-MHz linear-array transducer using an air-tight inert gel at the recording site. The measurements were taken directly on the screen with an accuracy of 0.1 mm (Figure 1). The transducer probe was positioned in the middle part of the muscle, with an inclination of about 100°, to demonstrate transverse sections. For the examination, the children remained seated in an upright position, head in a natural posture, under two different conditions: with the muscle relaxed (at rest) and during maximum isometric contraction of the lips, i.e., lip reciprocal contraction (contracted state). One of the authors carried out all scans (LSP) to eliminate inter-observer differences. The imaging and measurements were performed three times, with an interval of two minutes between them. The thickness per site was calculated as the average of the three measurements.

The method error (Se) for the ultrasound measurements was assessed on repeated measurements (m_1 , m_2) of 10 randomly selected participants (n) using Dahlberg's formula: $S_e = [\sum (m_1 - m_2)^2 / 2n]$. A period of about 15 days elapsed between the repeated measurements, and there were no significant differences between the two occasions. The error for upper *orbicularis oris* at rest was 0.6 mm and 0.27 mm in the contracted state. The corresponding values for the lower fascicle were 0.16 mm and 0.69 mm.

2. Cephalometric Radiograph Measurements

The records of each subject were chosen on the basis of their lateral cephalograms with good definition of both hard and soft tissues, molars in maximal occlusion with the lips closed, and soft tissues that were subjectively judged to be unstrained. All protective measures for taking radiographs were guaranteed in accordance with the recommendations of the International Commission on Radiological Protection and the National Commission of Nuclear

*Dibbets JMH. 1992. One century of Wolff's law. Bone biodynamics in orthodontic and orthopedic treatment. In: Carlson D S, Goldstein S A (eds) Bone biodynamics in orthodontic and orthopedic treatment. Monograph No. 27, Craniofacial Growth Series, Center for Human Growth and Development, University of Michigan, Ann Arbor, pp. 1-13.

Energy (Brazil) in relation to child, operator, and environmental radiation protection. All cephalometric radiographs were analyzed by one trained professional (TSB).

Table 1 shows the hard (skeletal and dental) and soft tissue variables studied.

3. Statistical Analysis

Statistical analysis was performed using SPSS 9.0 (SPSS, Chicago, IL, USA), and *p* values under 0.05 were considered statistically significant. The normality of the distributions was assessed by the Shapiro-Wilks *W*-test. The Pearson and Spearman

coefficients were applied among the US and hard and soft tissue variables where appropriate.

RESULT

The mean and standard deviation (SD) of each angular and linear measurement are shown in Table 1.

Table 2 shows the mean and standard deviation (SD) of the orbicular oris muscle thickness and the correlation between muscle and the distance of labrale superius and E-line. The skeletal and dental variables did not correlate significantly with

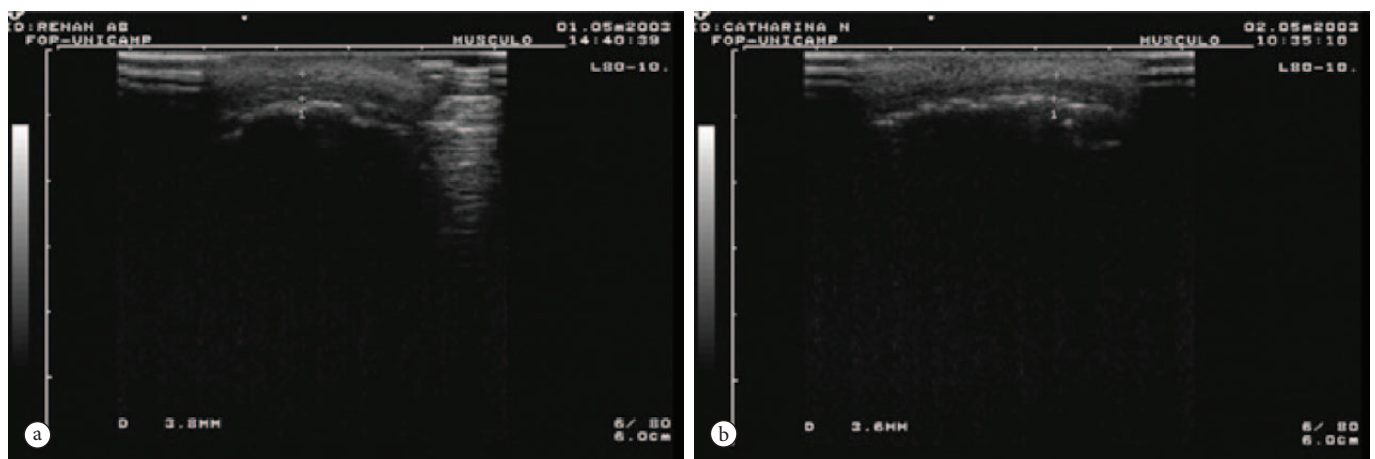


Figure 1. Ultrasonographic image of the upper (a) and lower (b) fascicles of the *orbicularis oris* muscle thickness in the contracted and rest states, respectively.

Table 1. Means (\pm SD) for angular and linear measurements

Variables	Description	Mean	SD	
Skeletal variables	FNA ($^{\circ}$)	Angle between the Frankfort horizontal plane and NA plane	85.59	4.28
	FMA ($^{\circ}$)	Angle between the Frankfort horizontal plane and mandibular plane	28.59	4.04
	ANB ($^{\circ}$)	Difference between the SNA and SNB angles	5.55	1.63
	AFAI (mm)	Distance between anterior nasal spine and menton	65.77	3.85
Dental angular and linear measurements	F.I/ ($^{\circ}$)	Angle between upper incisor and Frankfort horizontal plane	116.09	6.01
	NPg - /1 (mm)	Distance between N-Pg plane and /1	5.70	2.52
	ii-io (mm)	Overbite: vertical distance between the incisal tips of the maxillary and mandibular incisors traced on the occlusal plane	0.14	3.56
	is-io (mm)	Overjet: horizontal distance between the buccal surface of the mandibular central incisor and the incisal tips of the maxillary central incisor traced on the occlusal plane	4.64	1.92
	1/./1 ($^{\circ}$)	Interincisal angle: angle between the long axis of the maxillary central incisor and long axis of the mandibular incisor	117.32	8.41
Soft tissue measurements	A-A' (mm)	Upper Lip Thickness: the perpendicular distance between the two vertical and parallel planes drawn at 80 to S-N plane and passing through points subspinale and soft tissue A point.	13.23	1.77
	Pg-Pg' (mm)	Distance between pogonion and soft tissue pogonion (mental thickness)	12.50	2.30
	AB-Ls (mm)	Distance between AB plane and labrale superius	19.59	2.65
	AB-B' (mm)	Distance between AB plane and soft B	11.95	2.28
	E \perp Ls (mm)	Distance between Ricketts' E-line and labrale superius	1.18	2.13
	E \perp Li (mm)	Distance between Ricketts' E-line and labrale inferius	2.27	2.06

the orbicular oris thickness at rest, while the upper and lower fascicles of the orbicularis oris muscle in the contracted state showed a negative correlation with the distance between the labrale superius and Ricketts' E-line (Table 2).

Table 3 shows the correlation between the skeletal, dental, and soft tissue cephalometric measurements. The lower face height correlated positively with the distance between the AB plane and the labrale superius ($r = 0.58, p < 0.01$), and the ANB angle correlated positively with the distance between Ricketts' E-line and the labrale superius ($r = 0.51, p < 0.05$) and the inferius ($r = 0.56, p < 0.01$). The lower-incisor distance from the N-Pg plane correlated positively with the distance between the AB plane and the labrale superius ($r = 0.48, p < 0.05$) and the distance between the labrale superius ($r = 0.67, p < 0.001$) and the inferius ($r = 0.77, p < 0.0001$) to the Ricketts' E-line. Overbite and interincisal angle were negatively correlated with the distance between the pogonion and the soft tissue pogonion ($r = -0.44, p < 0.05$) and the distance between the labrale inferius and Ricketts' E-line ($r = -0.58, p < 0.01$), respectively.

DISCUSSION

Several studies have demonstrated the influence of the perioral muscle forces developed during physiological movements, especially the tongue and lips, on the positioning of the teeth in the dental arches^{5,6}; however, taking into consideration the different methodologies, their results differ greatly. In this context, different techniques and methods were introduced to studies, coupled with electromyography¹², yielding more consistent results, such as the measurement of force¹ and muscle thickness¹³.

Muscle dimension determination by ultrasonography has been used as a parameter of muscle form and function in many studies^{9-11,14,15}, and, interestingly, facial features are usually studied in profile. In this study, the relationship between hard and soft

tissue cephalometric variables was investigated and correlated with the orbicular oris thickness at rest and in the contracted state in subjects with Class I and Class II malocclusion.

Studies have shown that the upper and lower lips move slightly posteriorly following an orthodontic treatment with extractions^{16,17} since the soft tissue may be associated with sagittal changes in both the maxillary and mandibular incisor position¹⁶. However, changes in the soft facial profile also seem to be related to other variables, such as lip strain, structure, and thickness, together with incisor retraction¹⁸. The correction of a Class II division 1 malocclusion has been shown to be accompanied by a decrease in ANB measures and retraction of the lips relative to the esthetic plane^{19,20}. In the present study, the ANB angle was associated with upper and lower lip protrusion, that is, a more convex profile, which might compensate for a retruded mandible during lip closure.

The results indicated that the vertical dimension of the lower face is associated with the distance of the labrale superius in relation to the AB plane; that is, subjects with a long facial pattern presented lip protrusion in relation to the AB plane, which is in agreement with the results of Blanchette et al.²¹ (1996) and Boneco, Jardim²² (2005). Also, overbite showed a negative correlation with soft tissue chin. The protrusion of soft tissues may have the purpose of compensating for a vertical facial pattern^{22,23} and a lack of skeletal support. In the mixed dentition, both lips are on the Ricketts E-line, and over the years, their convexity reduces and they retract, moving behind the esthetic line in a young adult: the lower lip by 2 mm and the upper by 3 mm in both facial types (vertical and horizontal)²⁴.

As expected, it was observed that the protrusion of the lower incisors was associated with the upper and lower lip position in relation to the AB plane and the E-line. Moreover, the interincisal angle was associated negatively with lower lip prominence. According to Kasai²⁵ (1998), the lower lip is reduced to a greater

Table 2. Mean (\pm SD) of the orbicular oris muscle thickness and the correlation between muscle and the distance of labrale superius and E-line ($E \perp Ls$). Only statistically significant coefficients were included

Upper fascicle of the orbicular oris (mm)		Upper orbicular oris (contracted) $\times E \perp Ls$		Lower fascicle of the orbicular oris (mm)		Lower orbicular oris (contracted) $\times E \perp Ls$	
At rest	Contracted	r (Pearson)	p	At rest	Contracted	r (Spearman)	p
3.74 (0.62)	4.56 (0.72)	-0.45	<0.05	3.38 (0.73)	4.24 (0.84)	-0.58	<0.01

Table 3. Pearson correlation coefficients between the skeletal and dental variables and soft tissue measurements. Only statistically significant values are included

Soft tissue variables	Skeletal variables				Dental variables					
	ANB		AFAI		NPg - /I		ii-io		I/.I	
	r	p	r	p	r	p	r	p	r	p
Pg-Pg'	-	-	-	-	-	-	-0.44	0.05	-	-
AB-Ls	-	-	0.58	0.01	0.48	0.05	-	-	-	-
$E \perp Ls$	0.51	0.05	-	-	0.67	0.001	-	-	-	-
$E \perp Li$	0.56	0.01	-	-	0.77	0.0001	-	-	-0.58	0.01

degree in patients with lower- and upper-incisor retraction than in patients with lower-incisor retraction alone since the lower lip is supported by the upper incisors²⁶. In Class II malocclusion (Division 1 and 2), the poor anterior relationship of the dental arch allows the physical interference between the lower lip of the upper and lower incisors, which may also result in retroclination of the inferior arch.

A definite change in muscle thickness upon relaxation and contraction for both the lips was observed: that is, contracted muscle showed greater thickness than relaxed muscle, and only *orbicularis oris* thickness in the contracted state showed significant associations with soft tissue profile. The upper and lower fascicle thicknesses correlated negatively with upper lip protrusion in relation to the E-line. According to Tsang et al.²³ (1998), lip protrusion may have the purpose of compensating for lip incompetence, and an increase in *orbicularis oris* muscle thickness was demonstrated after lipseal therapy and exercises in children with lip incompetence, with a significant reduction in overjet¹⁰.

No associations between skeletal and dental variables were found with *orbicularis oris* thickness in this study. Also, past studies^{12,27} did not observe a correlation between *orbicularis oris* activity and craniofacial measurements. However, others have shown that lip form and function could influence incisor position²⁸. In the study conducted by Jung et al.¹ (2003), the lip closing force showed a great influence on the angulation of the maxillary incisors. Moreover, lip incompetence has been associated with a large ANB angle and a large overjet, which is related to greater activity of the *mentalis* muscle to reach an anterior oral seal²⁹. In an ultrasonographic examination of the circumoral muscles, Rasheed, Munshi¹³ (1996) observed that

open-bite subjects presented a thinner upper *orbicularis oris*, while deep-bite subjects presented a thicker lower *orbicularis oris* muscle and higher electromyographic activity compared to other types of occlusion.

Different results found in the literature can be attributed to variations in the ethnicity and age of the samples and the method of analysis among the studies. The relationship between the soft and hard tissues is complex, and some hard and soft tissue variables showed close relations, whereas others were relatively independent; thus, further studies dealing with structural aspects of the hard and soft profiles and orofacial musculature are required since methods for analyzing soft tissues play an important role in therapy planning and the achievement of the desired and anticipated results.

CONCLUSION

In the sample studied, it was observed that skeletal and dental variables were associated with upper and lower lip position and pogonion thickness, while the upper and lower fascicles of the *orbicularis oris* thickness in the contracted state was associated only with upper lip retrusion.

ACKNOWLEDGEMENTS

The authors gratefully acknowledge the financial support from the State of São Paulo Research Foundation (FAPESP, SP, Brazil, n. 2001/10002-3) and the volunteers for participating in this research.

REFERENCES

- Jung MH, Yang WS, Nahm DS. Effects of upper lip closing force on craniofacial structures. *Am J Orthod Dentofacial Orthop*. 2003;123:58-63. PMID:12532064. <http://dx.doi.org/10.1067/mod.2003.54>
- Zide BM. The mentalis action: an essential component of chin and lower lip position. *Plast Reconstr Surg*. 2000;105:1213-5. PMID:10724283. <http://dx.doi.org/10.1097/00006534-200003000-00061>
- Wolff J. Über die innere architectur der knochen und ihre bedeutung für die frage vom knochenwachstum. *Virchow's Archiv*. 1870;50:389-450. <http://dx.doi.org/10.1007/BF01944490>
- Kitai N, Fujii Y, Murakami S, Furukawa S, Kreiborg S, Takada K. Human masticatory muscle volume and zygomatico-mandibular form in adults with mandibular prognathism. *J Dent Res*. 2002;81:752-6. PMID:12407089. <http://dx.doi.org/10.1177/154405910208101106>
- Oliver BM. The influence of lip thickness and strain on upper lip response to incisor retraction. *Am J Orthod*. 1982;82:141-8. [http://dx.doi.org/10.1016/0002-9416\(82\)90492-4](http://dx.doi.org/10.1016/0002-9416(82)90492-4)
- Wisth PJ. Soft tissue response to upper incisor retraction in boys. *Br J Orthod*. 1974;1:199-204. PMID:4532612.
- Ikai M, Fukunaga T. A study on training effect on strength per unit cross-sectional area of muscle by means of ultrasonic measurement. *Int Z Angew Physiol*. 1970;28:173-80. PMID:5425330.
- Bakke M, Tuxen A, Vilmann P, Jensen BR, Vilmann A, Toft M. Ultrasound image of human masseter muscle related to bite force, electromyography, facial morphology, and occlusal factors. *Scand J Dent Res*. 1992;100:164-71. PMID:1631486.
- Martin RA, Hunter V, Neufeld-Kaiser W, Flodman P, Spence MA, Furnas D et al. Ultrasonographic detection of orbicularis oris defects in first degree relatives of isolated cleft lip patients. *Am J Med Genet*. 2000;90:155-61. [http://dx.doi.org/10.1002/\(SICI\)1096-8628\(2000117\)90:2<155::AID-AJMG13>3.0.CO;2-V](http://dx.doi.org/10.1002/(SICI)1096-8628(2000117)90:2<155::AID-AJMG13>3.0.CO;2-V)
- Kumar TV, Kuriakose S. Ultrasonographic evaluation of effectiveness of circumoral muscle exercises in adenotonsillectomized children. *J Clin Pediatr Dent*. 2004;29:49-55. PMID:15554404.
- van Hees NJ, Thijssen JM, Huyskens RW, Weijers G, Nillesen MM, de Korte CL, et al. Quantitative ultrasound imaging of healthy and reconstructed cleft lip: a feasibility study. *Cleft Palate Craniofac J*. 2007;44:261-8. PMID:1747756. <http://dx.doi.org/10.1597/06-051>

12. Kilic N. Associations between upper lip activity and incisor position. *Aust Orthod J*. 2010;26:56-60. PMID:20575201.
13. Rasheed SA, Munshi AK. Electromyographic and ultrasonographic evaluation of the circum-oral musculature in children. *J Clin Pediatr Dent*. 1996;20:305-11. PMID:9151623.
14. Castelo PM, Gavião MB, Pereira LJ, Bonjardim LR. Masticatory muscle thickness, bite force, and occlusal contacts in young children with unilateral posterior crossbite. *Eur J Orthod*. 2007;29:149-56. PMID:17317862. <http://dx.doi.org/10.1093/ejo/cjl089>
15. Andrade AS, Gavião MB, Derossi M, Gameiro GH. Electromyographic activity and thickness of masticatory muscles in children with unilateral posterior crossbite. *Clin Anat*. 2009;22:200-6. PMID:19031391. <http://dx.doi.org/10.1002/ca.20726>
16. Akyalçin S, Hazar S, Güneri P, Gögüs S, Erdiñç AM. Extraction versus non-extraction: evaluation by digital subtraction radiography. *Eur J Orthod*. 2007;29:639-47. PMID:17906308. <http://dx.doi.org/10.1093/ejo/cjm075>
17. Khan M, Fida M. Soft tissue profile response in extraction versus non-extraction orthodontic treatment. *J Coll Physicians Surg Pak*. 2010;20:454-9. PMID:20642945.
18. Battagel JM. Profile changes in Class II, division 1 malocclusions: a comparison of the effects of Edgewise and Fränkel appliance therapy. *Eur J Orthod*. 1989;11:243-53. PMID:2792214.
19. Zierhut EC, Joondeph DR, Artun J, Little RM. Long-term profile changes associated with successfully treated extraction and nonextraction Class II Division 1 malocclusions. *Angle Orthod*. 2000;70:208-19. PMID:10926430.
20. Sodagar A, Borujeni DG, Amini G. Prediction of soft tissue profile changes following orthodontic retraction of incisors in Iranian girls. *World J Orthod*. 2010;11:262-8. PMID:20877736.
21. Blanchette ME, Nanda RS, Currier GF, Ghosh J, Nanda SK. A longitudinal cephalometric study of the soft tissue profile of short- and long-face syndromes from 7 to 17 years. *Am J Orthod Dentofacial Orthop*. 1996;109:116-31. [http://dx.doi.org/10.1016/S0889-5406\(96\)70172-5](http://dx.doi.org/10.1016/S0889-5406(96)70172-5)
22. Boneco C, Jardim L. Estudo da morfologia labial em pacientes com padrão facial vertical alterado. *Rev Port Estom Med Dent Cir Maxilofac*. 2005;46:69-80.
23. Tsang WM, Cheung LK, Samman N. Cephalometric characteristics of anterior open bite in a southern Chinese population. *Am J Orthod Dentofacial Orthop*. 1998;113:165-72. [http://dx.doi.org/10.1016/S0889-5406\(98\)70288-4](http://dx.doi.org/10.1016/S0889-5406(98)70288-4)
24. Anić Milošević S, Šljaj M, Lapter Varga M. Osnovna načela snimanja ekstraoralnih fotografija (Basic Principles for Taking Extraoral Photographs). *Acta Stomatologica Croatica*. 2005; 39:195-205.
25. Kasai K. Soft tissue adaptability to hard tissues in facial profiles. *Am J Orthod Dentofacial Orthop*. 1998;113:674-84. [http://dx.doi.org/10.1016/S0889-5406\(98\)70228-8](http://dx.doi.org/10.1016/S0889-5406(98)70228-8)
26. Bishara SE, Cummins DM, Jakobsen JR, Zaher AR. Dentofacial and soft tissue changes in Class II, division 1 cases treated with and without extractions. *Am J Orthod Dentofacial Orthop*. 1995;107:28-37. [http://dx.doi.org/10.1016/S0889-5406\(95\)70154-0](http://dx.doi.org/10.1016/S0889-5406(95)70154-0)
27. Ambrosio AR, Trevilatto PC, Sakima T, Ignácio SA, Shimizu RH. Correlation between morphology and function of the upper lip: a longitudinal evaluation. *Eur J Orthod*. 2009;31:306-13. PMID:19289538. <http://dx.doi.org/10.1093/ejo/cjn112>
28. Capaccioli L, Antonini A, Franchi L, Tollaro I, Zecchi Orlandini S, Stecco A, Villari N. The correlations between the echographic aspect of the perioral and masticatory muscles and dento-skeletal characteristics. *Radiol Med*. 1998;95:567-72.
29. Simpson MM. Lip incompetence and its relationship to skeletal and dental morphology - an electromyographic investigation. *Br J Orthod*. 1976;3:177-9. PMID:1067870.

CONFLICTS OF INTERESTS

The authors declare no conflicts of interest.

CORRESPONDING AUTHOR

Maria Beatriz Duarte Gavião
Departamento de Odontologia Infantil, Faculdade de Odontologia de Piracicaba, UNICAMP – Universidade Estadual de Campinas, 13414-903 Piracicaba - SP, Brasil
e-mail: mbgavião@fop.unicamp.br

Recebido: 06/09/2012
Aprovado: 23/11/2012