

LETTER TO THE EDITOR

PORTAL VEIN ANEURYSM

Wellington Andraus, Ênio Campos Amico, Marcel Autran Machado, Telésforo Bacchella, Marcel Cerqueira César Machado

INTRODUCTION

Unlike arterial aneurysms, primary venous aneurysms are uncommon. Venous aneurysms have been found and described in the popliteal, jugular, and saphenous veins, but occur only rarely in other veins. Portal vein aneurysms represent less than 3% of all venous aneurysms.¹ This finding has been increasingly described in recent years probably because radiologic imaging exams are more available in clinical practice. Two forms, congenital and acquired, have been described. Acquired aneurysms are more frequent and associated commonly with hepatic cirrhosis and portal hypertension.²

In this report, we present a case of a patient with an asymptomatic portal vein aneurysm located at the truncus of the portal vein that was incidentally detected during an ultrasonography examination for dyspepsia and was treated conservatively.

CLINICAL CASE

A 32-year-old woman who had a 7-year history of lumbar pain was investigated with abdominal ultrasonography and laboratorial tests. Imaging resulted in an incidental diagnosis of a venous dilation in the hepatic hilus. Subsequent abdominal scanning and abdominal magnetic resonance imaging tests confirmed the hypothesis of a portal vein aneurysm.

The 5-cm diameter lesion was located in the hepatic hilus (Figures 1, 2), with a saccular configuration located at the truncus of the portal vein, which was significantly enhanced in the arterial phase at abdomen tomography and showed no thrombus inside. The intrahepatic branches of the portal vein and the mesenteric as well as the splenic vein were normal in caliber. The liver parenchyma was homogeneous, and the size and contours of the organ were normal. There was no portal caverna, nor were there other dilated veins in the hepatic hilum or beside the stomach.

Transplant and Liver Surgery Service, Hospital das Clínicas, São Paulo University Medical School – São Paulo/SP, Brazil.
Email: fdutra@iq.usp.br

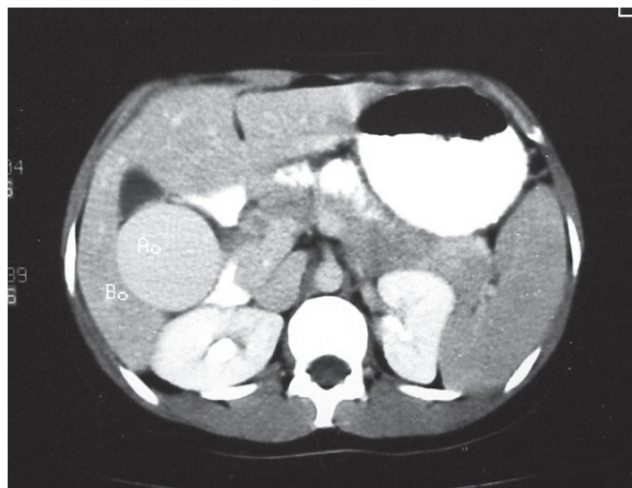


Figure 1 - Computed tomography showing a portal vein dilation measuring 50 mm in diameter in the hepatic hilus. There is no thrombus inside. The spleen has a normal size. Performed in 1998.

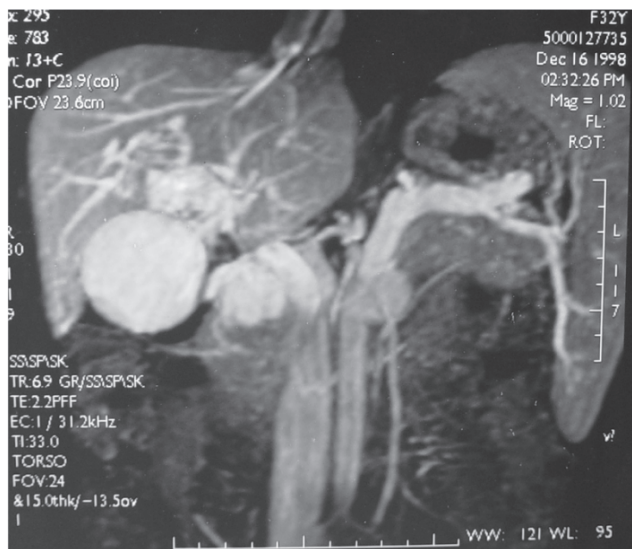


Figure 2 - Nuclear magnetic resonance, in a sagittal cut, showing the dilated portal vein with the maximum diameter being the same as that revealed by computed tomography. Performed in 1998.

The spleen was of normal size without any signs of portal hypertension. An upper gastrointestinal endoscopy was done and proved normal, with no esophageal varices. The patient's physical examination revealed no alterations,

showing a flaccid abdomen, no pain, and the absence of any palpable mass.

Her laboratory tests proved normal, showing no renal function alteration and a normal hemogram, without anemia or thrombocytopenia. There were no alterations in

liver function, with normal bilirubin, albumin, and prothrombin time. The transaminases and canalicular enzymes were also normal, showing no hepatic injury or cholestasis.

The patient had no history of other disease or of previous surgery. She has remained asymptomatic for 7 years, and her periodic imaging tests showed no alteration in the venous dilation of the portal vein (Figures 1-5), which has remained the same size (5 cm) in all scanning and magnetic resonance imaging that we did.

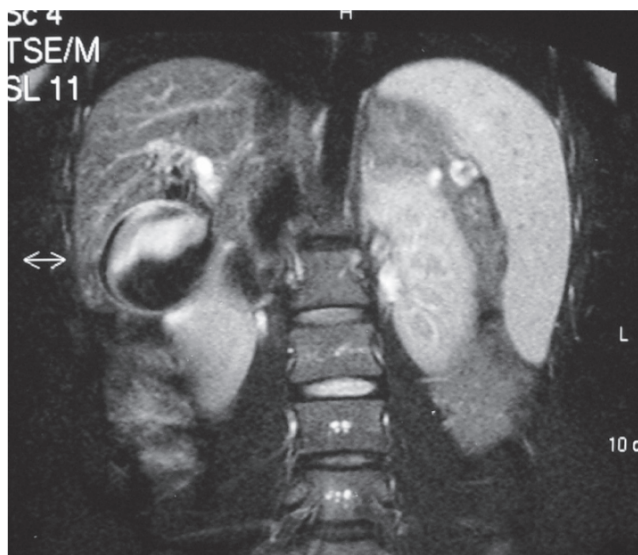
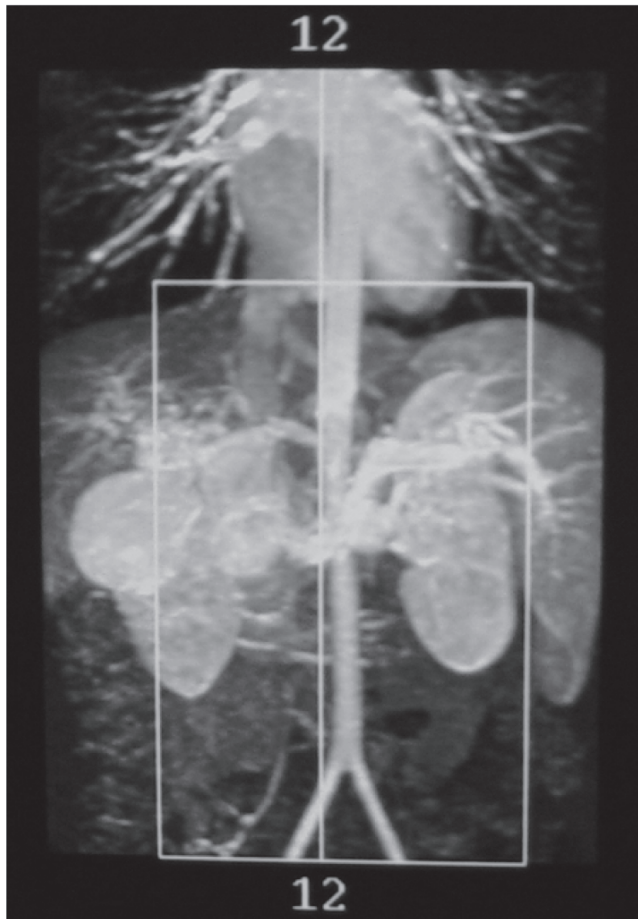


Figure 3 and 4 - Nuclear magnetic resonance showing the same dilation in the portal vein 4 years later, in 2002, and the splenic vein with normal caliber.

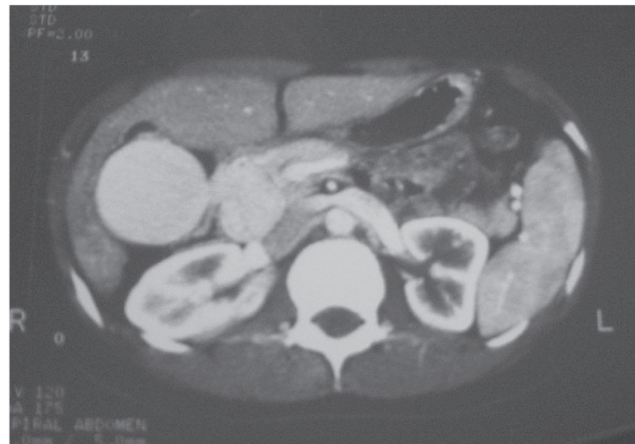

Figure 5 - Computed tomography showing the portal vein aneurysm with high signal similar to that of the aorta and the inferior vena cava and no significant change in size and shape. Performed in 2005.

DISCUSSION

Portal vein aneurysm (PVA) is considered a rarity, with only approximately 70 cases described in the literature.² Barzilai and Kleckner were the first to report a portal vein aneurysm, in 1956. The authors described the necropsy of a cirrhotic patient with a portal vein aneurysm and thrombus that ruptured into the biliary system.³ Gastrointestinal bleeding, which required urgent surgical exploration, was characteristic of the form of a portal vein aneurysm typically seen before the 1980s. Since then, pursuant to the new imaging modes such as ultrasonography, computed tomography, nuclear magnetic resonance, and arteriography that have become common in clinical practice, the number of diagnosed cases has increased.

Portal vein aneurysms can be diagnosed when the vein shows dimensions greater than those considered normal and especially when it displays fusiform or saccular configurations.⁴ The normal size of the portal vein has been studied by several authors. Reynolds describes the portal vein as having an average diameter of 1.2 cm, which may increase in cirrhotic patients.⁵ In an ultrasonographic study of the portal vein, Doust and Pearce found that the maximum anterior-posterior diameter never exceeded 1.5 cm in

normal patients, and 1.9 cm in cirrhotic patients.⁶

The histological examination of venous aneurysms reveals a decrease in the number and size of the elastic and muscle fibers of the vein's wall and fragmentation of the internal elastic layer, with replacement by fibrous connective tissue.⁷

The most common location is at the confluence of the splenic and upper mesenteric veins, followed by the portal vein and its ramifications.⁸

The etiology of portal vein aneurysms is controversial. Its congenital origin is suggested based on the discovery of variations in the embryologic development of the portal vein, as well as on reports of such aneurysms in youths without hepatic disease, in patients with multiple vascular malformations,⁹ and in fetuses.¹⁰ The origin of acquired portal vein aneurysms is more commonly secondary to cirrhosis and other hepatic diseases. Pancreatitis can be included as an extrahepatic cause. It is believed that the increase in intraluminal pressure observed in portal hypertension may lead to dilation of the relatively thin wall of the portal vein.⁴ However, the explanation for the significant disproportion between the incidence of portal hypertension and portal vein aneurysms suggests that there must be another associated cause.

In the great majority of cases, patients are clinically asymptomatic. A few display abdominal pain due to compression of adjacent structures, jaundice by compression of the biliary ducts, or gastrointestinal bleeding due to rupture of the biliary system.¹¹

The treatment of a portal vein aneurysm depends basically on the patient's initial clinical symptoms and on the presence or absence of associated portal hypertension. Should symptoms appear or the aneurysm increase during observation, surgical treatment is recommended.¹³ In the absence of portal hypertension, an aneurysmography for the fusiform variants, or the resection of the aneurysm in cases of saccular dilation should be preferred.¹⁴ In the presence of portal hypertension, the direct approach to the aneurysm is avoided due to the high risk of bleeding. Because a portal vein aneurysm can reduce portal pressure, decompression (derivation) surgeries may prevent the progression of aneurysmatic dilation, thus making them the preferred technique.¹⁴

In most of cases of disease-related forms of portal vein aneurysm, the patients are symptom-free, and there is no need for surgical procedures; therefore, as is suggested by others authors,¹² careful monitoring is the best treatment for such patients.

REFERENCES

1. Feliciano PD, Cullen JJ, Corson JD. The management of extrahepatic portal vein aneurysm: observe or treat? *HPB Surgery*. 1996;10:113-6.
2. Mucenic M, Rocha MS, Laudanna AA, Caçado ELR. Treatment by splenectomy of a portal vein aneurysm in hepatosplenic schistosomiasis. *Rev Inst Med Trop S Paulo*. 2002;44:261-4.
3. Barzilai R, Kleckner MS. Hemocholecyst following ruptured aneurysm of portal vein; report of a case. *AMA Arch Surg*. 1956;72:725-7.
4. Ohnishi K, Nakayama T, Saito M, Nomura F, Koen H, Tamaru J, et al. Aneurysm of the intrahepatic branch of the portal vein. Report of two cases. *Gastroenterology* 1984;86:169-73.
5. Reynolds RB. Portal hipertension. In: Shiff L. *Disease of the liver*. Philadelphia; Lippincott: 1975. p. 330-67.
6. Doust B, Perace J. Gray-scale ultrasonic properties of the normal and inflamed pancreas. *Radiology*. 1976;120:653-7.
7. Friedman SG, Krishnasastry KV, Doscher W, Deckoff SL. Primary venous aneurysms. *Surgery*. 1990;108:92-5.
8. Lopez-Machado E, Mallorquin-Jimenez F, Medina -Benitez A, Ruiz-Carazo E, Cubero-Garcia M. Aneurysms of the portal venous system: ultrasonography and CT findings. *Euro J Radiol*. 1998;26:210-4.
9. Ito Y, Tarao K, Tamai S, Ohkawa S, Kuni Y, Nagaoka T, et al. Portal vein aneurysm in the liver associated with multiple vascular malformations. *J Gastroenterol*. 1994;29:776-81.
10. Gallagher DM, Leiman S, Hux CH. In utero diagnosis of a portal vein aneurysm. *J Clin Ultrasound*. 1993;21:147-51.
11. Mhanna T, Bernard P, Pilleul F, Partensky C. Portal vein aneurysm: Report of two cases. *Hepatogastroenterology*. 2004;51:1162-4.
12. Hagiwara H, Kasahara A, Kono M, Kashio S, Kaneko A, Okuno A, et al. Extrahepatic portal vein aneurysm associated with a tortuous portal vein. *Gastroenterology*. 1991;100:818-21.
13. Brock PA, Jordan PH, Barth MH, Rose AG. Portal vein aneurysm: a rare but important vascular condition. *Surgery* 1997;121:105-8.
14. Lau H, Chew DK, Belkin M. Extrahepatic portal vein aneurysm: a case report and review of the literature. *Cardiovasc Surg*. 2002;10:58-61.