

## LETTER TO THE EDITOR

CORONARY ARTERY BYPASS SURGERY,  
ANGIOPLASTY AND LONG TERM ANTI-PLATELET  
TREATMENT IN A TYPE B HEMOPHILIA PATIENT

doi: 10.1590/S1807-59322009000800019

Antonio Eduardo Pesaro,<sup>1</sup>Marcus Vinicius Gaz,<sup>1</sup>Ralf Karbstein,<sup>1</sup>Marco Perin,<sup>1</sup>Carlos Vicente Serrano Jr.,<sup>II</sup>Élbio Damico<sup>I,III</sup>

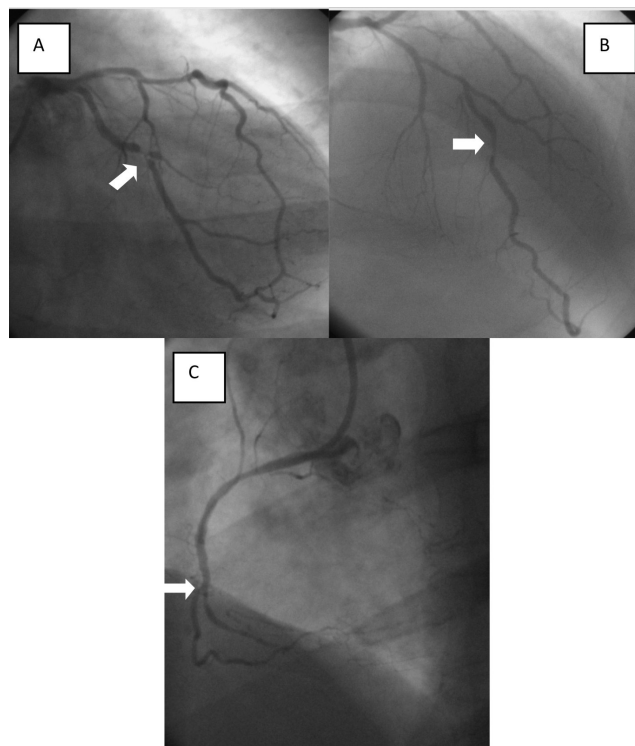
## INTRODUCTION

Hemophilia patients usually have a lower incidence of coronary artery disease (CAD).<sup>1</sup> However, as their life expectancy increases so does the incidence of CAD. Anti-platelet drugs, diagnostic coronary catheterization, angioplasty and coronary artery bypass surgery (CABG) have rarely been used in this population.<sup>2</sup>

## CASE DESCRIPTION

In this case-report, we describe the case of a 37-year-old man with severe type B hemophilia, HIV (on antiretroviral treatment) and activity-limiting angina unresponsive to clinical treatment. Myocardial cintilography detected ventricular dysfunction with lateral and inferior ischemia. Coronarography was performed with specific hematological support. The patient received enough factor IX to reach 100% plasma concentration (6,500 IU), followed by 3,500 IU the next day. Severe coronary obstructions were observed during coronarography (Figure 1).

The patient then underwent an off-pump CABG with an appropriate factor IX infusion (6,500 IU pre-surgery, 2,000 IU post-surgery with continuous infusion in order to keep the plasma concentration at 40% for the first 2 days, 30% for the third through sixth days, and 20% for the seventh through twelfth days). Two grafts were performed (left internal thoracic artery to anterior descending artery and saphenous graft to circumflex artery), and no adverse cardiac



**Figure 1** - A. Circumflex coronary artery with 95% obstruction. B. Anterior descending coronary artery with 70% obstruction. C. Right coronary artery with a 100% distal occlusion

or hematological events occurred. After surgery, the patient was not treated with anti-platelet drugs.

Six months after CABG, activity-limiting angina, ischemia and ventricular dysfunction persisted. An angiotomography showed obstruction of the saphenous vein graft. We performed an angioplasty of the circumflex coronary artery with a bare metal stent and used factor IX during the procedure, as described for the previous coronarography. The patient was treated with heparin, clopidogrel and acetyl salicylic acid (ASA). Clopidogrel

<sup>1</sup>CTI, Hospital Albert Einstein - São Paulo/ SP, Brazil

<sup>II</sup>Cardiology, Instituto do Coração do Hospital das Clinicas da Faculdade de Medicina da Universidade de São Paulo - São Paulo/SP, Brazil

<sup>III</sup>Hematology, Hospital das Clinicas da Faculdade de Medicina da Universidade de São Paulo - São Paulo/SP, Brazil

Email: eduardopesaro@hotmail.com

was administered for 30 days, and ASA was prescribed permanently. During the first month following stent placement, daily factor IX boluses were given in order to keep the factor IX plasma level at 30%. Six months following angioplasty, the patient remained asymptomatic, and his lateral ischemia had resolved. No hemorrhagic event was detected.

## DISCUSSION

In this case, the initial intervention indicated was a CABG based on the following: (1) Cardiac surgery is a relatively safe procedure for hemophilia patients; (2) The risks of using anti-platelet drugs are unknown in hemophiliacs; and (3) Multi-vessel angioplasty without anti-platelet treatment should be avoided. After the CABG, the

patient continued to have angina due to obstruction of the saphenous graft. We opted for a single angioplasty based on the fact that a second CABG was not indicated for treating the remaining single vessel disease. After that, we introduced ASA because reports of hemorrhagic complications while on ASA are based on a few anecdotal reports,<sup>3</sup> and stent thrombosis is still a major threat, even in hemophiliacs.<sup>4</sup>

This report highlights important issues surrounding the treatment of CAD in hemophilia patients: when indicated, angiography is a safe procedure and should not be delayed; CABG is a feasible option for patients who have multiple coronary obstructions, as long as factor IX is properly replaced.<sup>5</sup> Angioplasty may also be an option for treating this hemophilic population, but conclusive evidence is lacking.<sup>6</sup> More importantly, anti-platelet treatment should always be considered.

---

## REFERENCES

1. Rosendaal FR, Briët E, Stibbe J, van Herpen G, Leuven JA, Hofman A, et al. Haemophilia protects against ischaemic heart disease: a study of risk factors. *Br J Haematol* 1990;75:525-30.
2. Mackinlay N, Taper J, Renisson F, Rickard K. Cardiac surgery and catheterization in patients with haemophilia. *Haemophilia* 2000;6:84-8.
3. Quick AJ. No aspirin for haemophiliacs. *N Engl J Med*. 1971;284:218.
4. Bovenzi F, De Luca L, Signore N, Fusco F, de Luca I. Abciximab for the treatment of an acute thrombotic coronary occlusion during stent implantation in a patient with severe hemophilia B. *Ital Heart J*. 2003;4:728-30.
5. Scharfman WB, Rauch AE, Ferraris V, Burkart PT. Treatment of a patient with factor IX deficiency (hemophilia B) with coronary bypass surgery. *J Thorac Cardiovasc Surg*. 1993;105:765-6.
6. Smolka G, Kulach A, Dabek J, Szulc A, Gasior Z. Percutaneous coronary intervention with stent implantation in haemophilia A patient with unstable angina. *Haemophilia*. 2007;13:428-31.