

## BASIC RESEARCH

## S-NITROSO-N-ACETYLCYSTEINE AMELIORATES ISCHEMIA-REPERFUSION INJURY IN THE STEATOTIC LIVER

Wellington Andraus,<sup>I</sup> Gabriela Freitas Pereira de Souza,<sup>II</sup> Marcelo Ganzarolli de Oliveira,<sup>II</sup> Luciana B. P. Haddad,<sup>I</sup> Ana Maria M. Coelho,<sup>I</sup> Flavio Henrique Galvão,<sup>I</sup> Regina Maria Cubero Leitão,<sup>I</sup> Luiz Augusto Carneiro D'Albuquerque,<sup>I</sup> Marcel Cerqueira Cesar Machado<sup>I</sup>

doi: 10.1590/S1807-59322010000700011

Andraus W, Souza GFP, Oliveira MG, Haddad LBP, Coelho AMM, Galvão FH, Leitão RMC, D'Albuquerque LAC, Machado MCC. S-Nitroso-n-acetylcysteine ameliorates ischemia-reperfusion injury in the steatotic liver. Clinics. 2010;65(7):715-21.

**BACKGROUND:** Steatosis is currently the most common chronic liver disease and it can aggravate ischemia-reperfusion (IR) lesions. We hypothesized that S-nitroso-N-acetylcysteine (SNAC), an NO donor component, can ameliorate cell damage from IR injury. In this paper, we report the effect of SNAC on liver IR in rats with normal livers compared to those with steatotic livers.

**METHODS:** Thirty-four rats were divided into five groups: I (n=8), IR in normal liver; II (n=8), IR in normal liver with SNAC; III (n=9), IR in steatotic liver; IV (n=9), IR in steatotic liver with SNAC; and V (n=10), SHAN. Liver steatosis was achieved by administration of a protein-free diet. A SNAC solution was infused intraperitoneally for one hour, beginning 30 min. after partial (70%) liver ischemia. The volume of solution infused was 1 ml/100 g body weight. The animals were sacrificed four hours after reperfusion, and the liver and lung were removed for analysis. We assessed hepatic histology, mitochondrial respiration, oxidative stress (MDA), and pulmonary myeloperoxidase.

**RESULTS:** All groups showed significant alterations compared with the group that received SHAN. The results from the steatotic SNAC group revealed a significant improvement in liver mitochondrial respiration and oxidative stress compared to the steatotic group without SNAC. No difference in myeloperoxidase was observed. Histological analysis revealed no difference between the non-steatotic groups. However, the SNAC groups showed less intraparenchymal hemorrhage than groups without SNAC (p=0.02).

**CONCLUSION:** This study suggests that SNAC effectively protects against IR injury in the steatotic liver but not in the normal liver.

**KEYWORDS:** Fatty liver, S-nitrosothiol, S-nitroso-N-acetylcysteine, reperfusion injury, oxidative stress.

## INTRODUCTION

In the last thirty years, hepatic steatosis has been well-documented as the most common chronic liver disease in the general population. Its high prevalence is of epidemiological concern because it affects 31% of adults as evaluated by magnetic resonance imaging in the USA<sup>1</sup> and 33% of living donor candidates who underwent liver biopsy.<sup>2</sup> The prevalence is directly related to age and varies from 2.6% in

children to 26% in adults who are 40 to 59 years old.<sup>3</sup>

The pathophysiology of steatosis has not been completely ascertained. The condition may be a consequence of mitochondrial  $\beta$ -oxidation impairment, leading to increased free fatty acids inside the hepatocyte;<sup>4</sup> or it may be the cause of oxidative dysfunction, thus leading to structural and functional mitochondrial changes.<sup>5</sup> Liver inflammation can also be a trigger of steatosis. Either as isolated or cooperative factors, mitochondrial dysfunction, inflammatory cytokines, free fatty acids, bacterial endotoxins, microvascular injury, and oxidative stress may all be involved in the pathogenesis of ischemia-reperfusion (IR) injury.<sup>6-8</sup>

Previous studies have demonstrated that steatosis can worsen the effect of IR lesions in liver transplantation and hepatectomy.<sup>9-12</sup> These two factors, steatosis and IR lesions, are important because of the high prevalence of steatosis

<sup>I</sup> Department of Gastroenterology, Faculdade de Medicina da Universidade de São Paulo - São Paulo/SP, Brazil.

<sup>II</sup> Chemistry Institute, University of Campinas (UNICAMP) - Campinas/SP, Brazil.

Email: wellington@usp.br, wandraus@terra.com.br

Tel.:55 11 3061-8319

Received for publication on March 09, 2010

First review complete on March 30, 2010

Accepted for publication on April 30, 2010

in the general population and the common risk of IR injury in liver transplantation and other hepatic surgeries. Microvascular alterations, mitochondrial dysfunction, and a lower number of sinusoids in steatosis are factors that worsen the effect of IR injury in steatotic livers.<sup>7,13,14</sup> Moreover, fatty free acids inhibit acetyl coenzyme A, an important factor in the Krebs cycle and gluconeogenesis, thus leading to decreased production of ATP.<sup>14,15</sup>

Therefore, oxidative stress and hepatic microcirculatory damage are related to steatosis and the genesis of IR lesions.<sup>13,14,16,17</sup> Nitric oxide (NO) has conflicting effects on IR; it can improve hepatic microcirculation at low doses.<sup>5,18-22</sup> S-nitroso-N-acetylcysteine (SNAC) is an S-nitrosothiol that can act as an NO carrier and donor. NO has a systemic and tissue vasodilatation effect and also acts in hepatic microcirculation.<sup>23</sup> It is suggested that NO could ameliorate hepatic microcirculation, which is a pathophysiological factor in steatotic liver IR injury.

SNAC amelioration of oxidative stress in experimental models of steatosis<sup>24</sup> and IR injury of skeletal muscle<sup>25</sup> can also revert and inhibit the development of non alcoholic fat liver disease (NAFLD).<sup>39,26</sup> Although it has been studied in steatosis and IR injury of skeletal muscle, SNAC has not been studied in hepatic IR models or in steatotic liver IR models. In this study, we assessed the effect of SNAC in rats with normal and steatotic livers that had been submitted to ischemia.

## METHODS

### Animals

Thirty-five adult male Wistar rats that weighed 250 to 300 g were used for this study. All rats were maintained in a daily 12 h light-dark cycle. The rats were randomly distributed into five groups. Rats in group I (n=8) did not have steatosis (received a balanced diet) and were treated with saline solution. Rats in group II (n=8) did not have steatosis and were treated with SNAC. Rats in group III (n=9) had steatosis (received a protein-free diet) and were treated with saline solution. Rats in group IV (n=9) had steatosis and were treated with SNAC. Rats in group V (n=9) comprised the SHAN group; the same surgery was performed but without IR injury. A protein-free diet<sup>27</sup> was fed to rats for 21 days to induce steatosis. The control group was fed a balanced diet (*Nuvilab*) for the same period. After 21 days of treatment, the animals underwent IR injury.

The animals were handled under protocols approved by the Ethics Committee of the Clinical Hospital of Sao Paulo University in Brazil. The *Guide for the Care and Use of Laboratory Animals* (Institute of Laboratory Animal

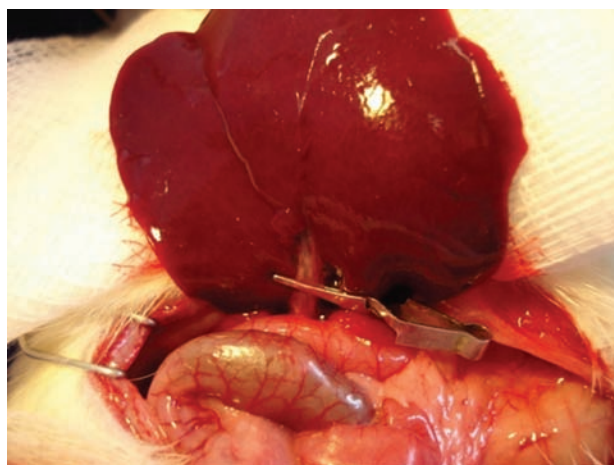
Resources, Commission on Life Sciences and National Research Council. National Academy Press, Washington, D.C., 1996) was used to ensure proper care and protection of the experimental animals.

### SNAC preparation

N-acetylcysteine (NAC) and sodium nitrite (Sigma, St. Louis, MO, USA) were used for SNAC preparation. Aqueous SNAC stock solution was prepared by combining an equimolar NAC solution with sodium nitrite. The final solution was stirred at room temperature for 20 min and was protected from light with aluminum foil. The SNAC solution was diluted in saline solution to a final concentration of 100 nM and used immediately.

### Induction of liver IR injury

The rats were anesthetized with intraperitoneal ketamine hydrochloride 5% (Park-Davis Lab, USA) and chloridrate of xylazine 2% (Rompum®, Bayer) at a dose of 30 mg/kg. Rats then underwent endotracheal intubation and were maintained at a rectal temperature of 35 to 37°C. A median laparotomy was performed, the ligaments of the liver were cut, all structures in the portal triad (hepatic artery, portal vein, and bile duct) of the median and left lateral hepatic lobes (70% of the liver) were clamped with an atraumatic microvascular clamp for 1 h (Figure 1), and the abdomen was closed. Then a second laparotomy was performed, the clamp was removed, and the animals were kept alive for 4 h after reperfusion. The SNAC solution (100 nM) was administrated intraperitoneally (i.p.) at a dose of 1 ml/100 g body weight for 1 h, starting 30 min after occlusion of the blood supply to the median and left hepatic lobes. Fifteen min before



**Figure 1** - Structures in the portal triad (hepatic artery, portal vein, and bile duct) in the median and left lateral hepatic lobes (70% of the liver) clamped with an atraumatic, microvascular clamp.

euthanasia by exsanguination, Evans blue (Sigma-Chemical Company, USA) was injected intravenously. The liver was removed, and both ischemic and non-ischemic portions were evaluated for histology, lipid peroxidation (MDA) and mitochondrial function. The lung was removed for Evans blue extraction and myeloperoxidase evaluation.

### Oxidative stress

The thiobarbituric acid method was used to quantify lipid peroxidation in tissue by measuring thiobarbituric acid-reactive substances (TBARS). The tissue was homogenized in 1.15% KCl buffer (100 mg/mL) and centrifuged at 14,000 g for 20 min. The supernatant was then stored at -70°C. An aliquot of the supernatant was added to a reaction mixture of 1.5 mL 0.8% thiobarbituric acid, 200  $\mu$ L 8.1% (v/v) solution (SDS), 1.5 mL 20% (v/v) acetic acid and 600  $\mu$ L distilled H<sub>2</sub>O. The new solution had a pH of 3.5 and was heated to 90°C for 45 min. After cooling to room temperature, the samples underwent centrifugation at 10,000 g for 10 min, and absorbance was measured at 532 nm using 1,1,3,3-tetramethoxypropane as an external standard. The quantity of lipid peroxide was reported as nmol of malondialdehyde (MDA) equivalents/mg protein.<sup>30</sup>

### Mitochondrial oxygenographic measurement

Liver tissue was prepared as previously described. Mitochondrial oxygen consumption was measured polarographically using a Gilson 5/6 H Oxygraph (Gilson Medical Electronics, Inc., Middleton, WI, USA) at 28°C. Respiration states 3 and 4 were defined and calculated according to the method of Chance<sup>31</sup> as ADP-stimulated and ADP-limited respiration, respectively. The respiratory control index (RCI) was measured and represented the ratio of state 3 to state 4 (S3/S4). Respiration states S3 and S4 were measured and reported as ng atoms of O<sub>2</sub> min<sup>-1</sup> mg protein<sup>-1</sup>. Mitochondrial protein content was determined using the method of Lowry et al.<sup>32</sup> The ratio of ADP added to oxygen consumed was calculated and recorded as the ADP/O ratio. The RCI and ADP/O ratio served as indices of oxidative and phosphorylative mitochondrial function, respectively.

### Histology

Both ischemic and non-ischemic parts of the liver were harvested for histological examination. Liver tissue was fixed in 10% formalin solution, processed, and stained with hematoxylin-eosin and Masson Trichrome. The following histological variables were assessed and scored from 0 to 3: macro- and microvacuolar fatty change, fatty zonal

distribution, foci of necrosis, portal and perivenular fibrosis, the inflammatory infiltrate and its zonal distribution.

### Statistical analysis

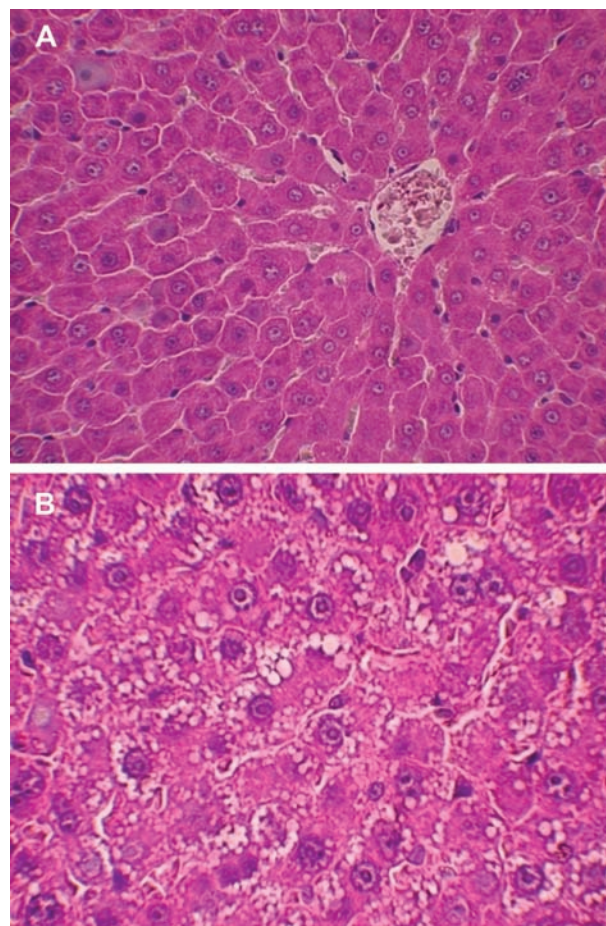
Results were expressed as the means  $\pm$  standard error (SE) and were statistically analyzed using the Mann-Whitney test and Fisher's exact test.  $p < 0.05$  was considered statistically significant.

## RESULTS

In general, all experimental groups (I, II, III and IV) showed a greater response than the SHAN group for all assessments measured ( $p < 0.05$ ).

### Experimental model of steatosis

Microscopically, the degree of steatosis in rats that received the protein-free diet (Figure 2a) was significantly greater than in rats that received the balanced diet (Figure 2b).



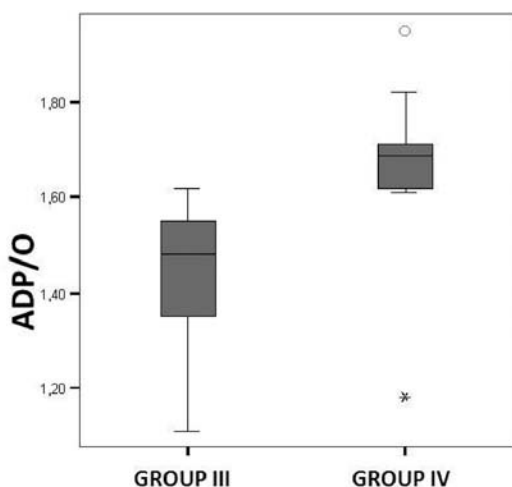
**Figures 2** - Representative histological sample of a liver from a control animal showing normal features (A) compared to a liver from an animal with a protein-free diet and severe steatosis (B) (HE 200x).



The animals on the protein-free diet developed malnutrition and lost approximately 30% of their body weight after 21 days.

### Liver mitochondrial oxygenic measurement

The RCI indicates oxidative phosphorylation activity. In the non-steatotic condition, the RCI revealed no difference between the control and SNAC groups. The ADP/O ratio indicates the level of coupling between the phosphorylation activity and the mitochondrial respiration. In the non-steatotic groups, there was no significant difference between the control and SNAC groups. However, in steatotic groups, SNAC treatment resulted in an improved ADP/O ratio in the liver ischemic samples ( $p=0.01$ ) (Figure 3).



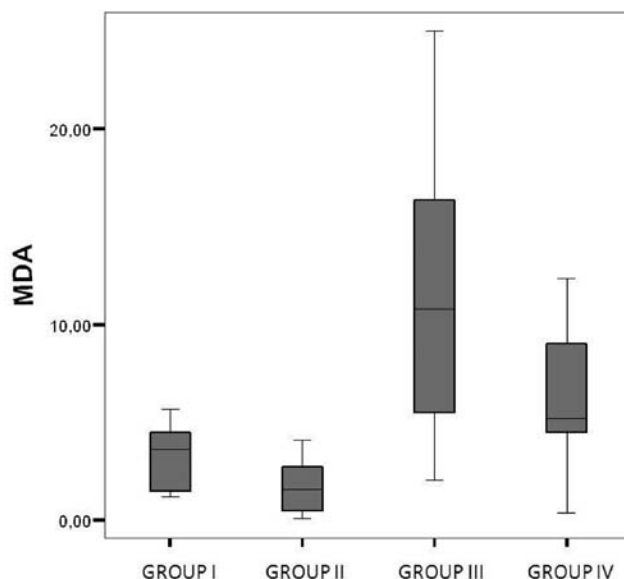
**Figure 3** - ADP/O ratio (ratio of ADP added to oxygen consumed) in ischemic livers of steatotic control group III and steatotic SNAC group IV;  $p=0.01$ .

### Liver oxidative stress

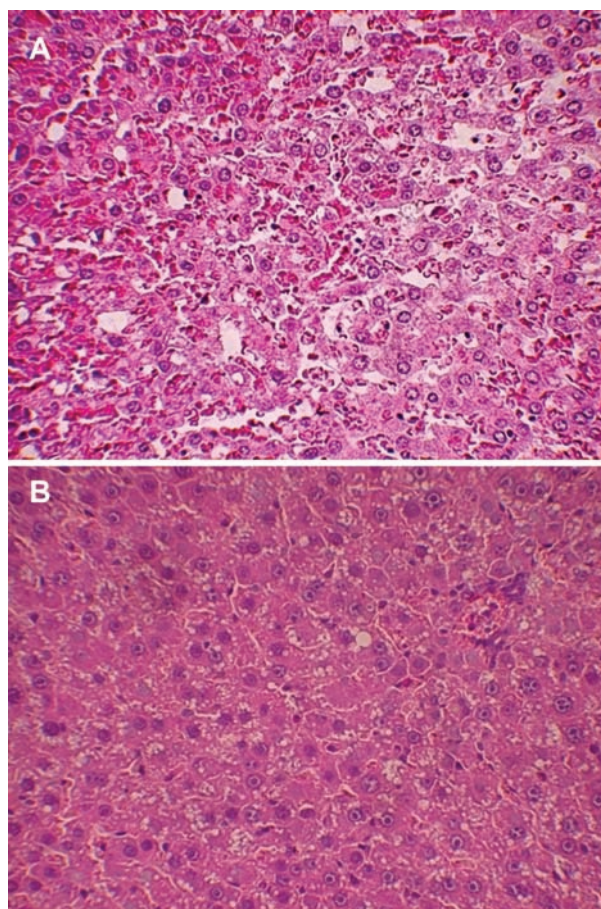
Treatment with SNAC appeared to result in decreased liver oxidative stress. Groups treated with SNAC showed no difference in lipid peroxidation as determined by the thiobarbituric acid method (MDA) compared to controls ( $p=0.07$ ). The oxidative stress was significantly higher in the steatotic groups than in the non-steatotic groups ( $p<0.01$ ) (Figure 4).

### Liver histology

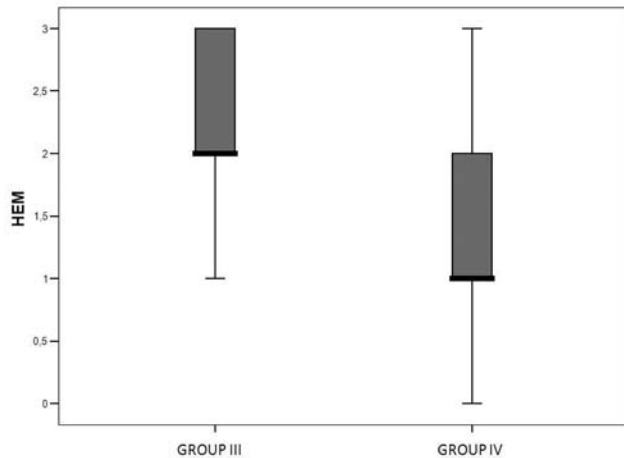
In the non-steatotic condition, all histological parameters were similar between the SNAC and control groups. Conversely, the steatotic groups showed less intraparenchymal hemorrhage in the ischemic liver ( $p=0.02$ ) (Figures 5a, 5b and 6). Moreover, the steatotic group had



**Figure 4** - Lipid peroxidase activity in liver tissue, measured as thiobarbituric acid-reactive substances (TBARS) and reported as nmol of malondialdehyde (MDA) equivalent/mg protein, of control group I, SNAC group II, steatotic control group III and steatotic SNAC group IV;  $p=0.07$ .



**Figures 5** - Representative histological sample of a steatotic, ischemic liver from a control animal with severe steatosis and hemorrhage (A) compared with a steatotic, ischemic liver from an animal treated with SNAC that shows moderate steatosis without hemorrhage (B) (HE 200x).



**Figure 6** - Histological score of intraparenchymal hemorrhage (HEM) in steatotic control group III and steatotic SNAC group IV;  $p=0.02$ .

higher levels of intraparenchymal hemorrhage than did the control group ( $p=0.02$ ) (Figures 2a and 2b).

## DISCUSSION

Steatosis is a risk factor for liver transplantation<sup>33</sup> and liver resection, and it is associated with higher morbidity and mortality rates.<sup>9,34</sup> Liver damage from steatosis is caused by hepatic mitochondrial impairment and oxidative stress.<sup>35</sup> In our study, higher levels of intraparenchymal hemorrhage and oxidative stress in the steatotic group confirmed the vulnerability and increased susceptibility of steatotic livers to IR injury (Figures 2a and 2b).

We analyzed the effects of an NO donor, SNAC, on IR injury in steatotic and non-steatotic livers. Endothelial dysfunction caused by IR injury may impair constitutive NO release<sup>37</sup> and therefore reduce NO production in the early reperfusion period. SNAC decreases the oxidative stress in experimental models of steatosis and in skeletal muscle that undergoes IR injury.<sup>24-26</sup> Therefore, S-nitrosothiol may be beneficial in cases of IR injury in steatotic livers. Our results also indicate that administration of SNAC after IR injury to steatotic livers can lead to improved mitochondrial function (Figures 3) and reduced oxidative stress (Figure 4).

Mitochondria are involved in fatty acid  $\beta$  oxidation and oxidative phosphorylation. Additionally, these organelles are an important source of reactive oxygen species (ROS). Impairment of their activity plays a central role in steatotic liver damage. SNAC may serve to decrease liver oxidative stress via two mechanisms. First, SNAC may improve mitochondrial function, thus leading to reduced ROS production. Second, SNAC may minimize damage

to circulation in the liver, thus reducing hemorrhage in ischemic livers, as we observed in our study.

Hepatic microcirculation and oxidative stress are important factors related to IR injury. These factors are already present in steatotic livers and are aggravated in ischemic liver injury during reperfusion. An interesting finding from our study was that SNAC did not substantially alter the IR lesions in non-steatotic livers. Meanwhile, in steatotic livers that had severe lesions, administration of SNAC resulted in improvement of the IR lesions.

In this study, we confirmed that steatosis increases susceptibility to severe lesions after IR injury. Additionally, we demonstrated that SNAC can ameliorate the response of steatotic livers to IR and reduce intraparenchymal hemorrhage. Intraparenchymal hemorrhage is a histological lesion that demonstrates severe damage. Among the histological changes that we observed after IR injury, this type of lesion was significantly different between the treated and non-treated groups.

Indeed, the present study confirmed greater IR injury in steatotic livers when compared to non-steatotic livers. Furthermore, hepatic IR lesions responded differently to treatment, regardless of whether steatosis was present.

Peroxynitrite is a highly reactive free radical formed by the combination of NO with a superoxide anion. Under normal conditions, this reaction is prevented by continuous removal of NO by hemoglobin.<sup>38</sup> Nonetheless, during the later stages of reperfusion, NO production increases as a result of the expression of intrinsic nitric oxide synthase (iNOS). Excessive NO production leads to the formation of peroxynitrite, which causes hepatic injury.<sup>37,39</sup> SNAC is an NO donor; therefore, a large quantity of this substance can itself produce peroxynitrite and nitrate stress. Thus, the timing of the administration of this drug is crucial to ameliorate IR injury in the liver and not cause further damage. In our study, we observed that administration of the NO donor SNAC led to a benefit in the final period of ischemia and in the early period of reperfusion.

In conclusion, this study confirms a poor outcome from IR injury in steatotic livers. Additionally, we show that SNAC effectively protects against IR injury in steatotic livers but not in normal livers.

## ACKNOWLEDGEMENT

The authors thank Sandra Nassa Sampietre for her valuable technical help.

## REFERENCES

1. Browning JD, Szczepaniak LS, Dobbins R, Nuremberg P, Horton JD, Cohen JC, et al. Prevalence of hepatic steatosis in an urban population in the United States: impact of ethnicity. *Hepatology*. 2004;40:1387-95.
2. Ryan CK, Johnson LA, Germin BI, Marcos A. One hundred consecutive hepatic biopsies in the workup of living donors for right lobe liver transplantation. *Liver Transpl*. 2002;8:1114-22.
3. Tominaga K, Kurata JH, Chen YK, Fujimoto E, Miyagawa S, Abe I, et al. Prevalence of fatty liver in Japanese children and relationship to obesity. An epidemiological ultrasonographic survey. *Dig Dis Sci*. 1995;40:2002-09.
4. Fromenty B, Pessayre D. Inhibition of mitochondrial beta-oxidation as a mechanism of hepatotoxicity. *Pharmacol Ther*. 1995;67:101-54.
5. Natarajan SK, Basivireddy J, Ramachandran A, Thomas S, Ramamoorthy P, Pulimood AB, et al. Renal damage in experimentally-induced cirrhosis in rats: Role of oxygen free radicals. *Hepatology*. 2006;43:1248-56.
6. Tilg H, Diehl AM. Cytokines in alcoholic and nonalcoholic steatohepatitis. *N Engl J Med*. 2000;343:1467-76.
7. Hui JM, Hodge A, Farrell GC, Kench JG, Kriketos A, George J. Beyond insulin resistance in NASH: TNF-alpha or adiponectin? *Hepatology*. 2004;40:46-54.
8. Feldstein AE, Werneburg NW, Canbay A, Guicciardi ME, Bronk SF, Rydzewski R, et al. Free fatty acids promote hepatic lipotoxicity by stimulating TNF-alpha expression via a lysosomal pathway. *Hepatology*. 2004;40:185-94.
9. Belghiti J, Hiramatsu K, Benoist S, Massault P, Sauvanet A, Farges O. Seven hundred forty-seven hepatectomies in the 1990s: an update to evaluate the actual risk of liver resection. *J Am Coll Surg*. 2000;191:38-46.
10. Vetelainen R, van Vliet A, Gouma DJ, van Gulik TM. Steatosis as a risk factor in liver surgery. *Ann Surg*. 2007;245:20-30.
11. Hui AM, Kawasaki S, Makuuchi M, Nakayama J, Ikegami T, Miyagawa S. Liver injury following normothermic ischemia in steatotic rat liver. *Hepatology*. 1994;20:1287-93.
12. Todo S, Demetris AJ, Makowka L, Teperman L, Podesta L, Shaver T, et al. Primary nonfunction of hepatic allografts with preexisting fatty infiltration. *Transplantation*. 1989;47:903-5.
13. Sun CK, Zhang XY, Zimmermann A, Davis G, Wheatley AM. Effect of ischemia-reperfusion injury on the microcirculation of the steatotic liver of the Zucker rat. *Transplantation*. 2001;72:1625-31.
14. Fukumori T, Ohkohchi N, Tsukamoto S, Satomi S. The mechanism of injury in a steatotic liver graft during cold preservation. *Transplantation*. 1999;67:195-200.
15. Berson A, De Beco V, Letteron P, Robin MA, Moreau C, El Kahwaji J, et al. Steatohepatitis-inducing drugs cause mitochondrial dysfunction and lipid peroxidation in rat hepatocytes. *Gastroenterology*. 1998;114:764-74.
16. Takahashi K, Hakamada K, Totsuka E, Umehara Y, Sasaki M. Warm ischemia and reperfusion injury in diet-induced canine fatty livers. *Transplantation*. 2000;69:2028-34.
17. Seifalian AM, Chidambaram V, Rolles K, Davidson BR. In vivo demonstration of impaired microcirculation in steatotic human liver grafts. *Liver Transpl Surg*. 1998;4:71-7.
18. Valko M, Leibfritz D, Moncol J, Cronin MT, Mazur M, Telser J. Free radicals and antioxidants in normal physiological functions and human disease. *Int J Biochem Cell Biol*. 2007;39:44-84.
19. Kimura H, Katsuramaki T, Isobe M, Nagayama M, Meguro M, Kukita K, et al. Role of inducible nitric oxide synthase in pig liver transplantation. *J Surg Res*. 2003;111:28-37.
20. Hines IN, Kawachi S, Harada H, Pavlick KP, Hoffman JM, Bharwani S, et al. Role of nitric oxide in liver ischemia and reperfusion injury. *Mol Cell Biochem*. 2002;234-235:229-37.
21. Zhang ZQ, Qiu JF, Luo M, Sun YW, Zhao G, Chen W, et al. Liposome-mediated gene transfer of endothelial nitric oxide synthase to cirrhotic rat liver decreases intrahepatic vascular resistance. *J Gastroenterol Hepatol*. 2007.
22. Phillips L, Toledo AH, Lopez-Neblina F, Anaya-Prado R, Toledo-Pereyra LH. Nitric oxide mechanism of protection in ischemia and reperfusion injury. *J Invest Surg*. 2009;22:46-55.
23. Glantzounis GK, Salacinski HJ, Yang W, Davidson BR, Seifalian AM. The contemporary role of antioxidant therapy in attenuating liver ischemia-reperfusion injury: a review. *Liver Transpl*. 2005;11:1031-47.
24. de Oliveira CP, Stefano JT, de Lima VM, de Sa SV, Simplicio FI, de Mello ES, et al. Hepatic gene expression profile associated with non-alcoholic steatohepatitis protection by S-nitroso-N-acetylcysteine in ob/ob mice. *J Hepatol*. 2006;45:725-33.
25. Chen LE, Seaber AV, Nasser RM, Stamler JS, Urbaniak JR. Effects of S-nitroso-N-acetylcysteine on contractile function of reperfused skeletal muscle. *Am J Physiol*. 1998;274(3 Pt 2):R822-29.
26. de Oliveira CP, Simplicio FI, de Lima VM, Yuahasi K, Lopasso FP, Alves VA, et al. Oral administration of S-nitroso-N-acetylcysteine prevents the onset of non alcoholic fatty liver disease in rats. *World J Gastroenterol*. 2006;12:1905-11.
27. Gonzalez Y, Machado MC, Da-Silva SM, Bettarello A. Protective effect of a protein-free diet in acute experimental pancreatitis. *Braz J Med Biol Res*. 1989;22:477-83.
28. Andraus W, Jukemura J, Dutra F, Bechara E, Cunha JE, Leite KR, et al. Oxidative stress is enhanced by hypothermia imposed on cerulein-induced pancreatitis in rats. *Clinics*. 2007;62:483-90.
29. Patel S, Pachter HL, Yee H, Schwartz JD, Marcus SG, Shamamian P. Topical hepatic hypothermia attenuates pulmonary injury after hepatic ischemia and reperfusion. *J Am Coll Surg*. 2000;191:650-6.
30. Soriano FG, Liaudet L, Szabo E, Virag L, Mabley JG, Pacher P, et al. Resistance to acute septic peritonitis in poly(ADP-ribose) polymerase-1-deficient mice. *Shock*. 2002;17:286-92.
31. Chance B, Thorell B. Fluorescence measurements of mitochondrial pyridine nucleotide in aerobiosis and anaerobiosis. *Nature*. 1959;184:931-4.
32. Lowry OH, Rosebrough NJ, Farr AL, Randall RJ. Protein measurement with the Folin phenol reagent. *J Biol Chem*. 1951;193:265-75.

33. Koneru B, Dikdan G. Hepatic steatosis and liver transplantation current clinical and experimental perspectives. *Transplantation*. 2002;73:325-30.
34. McCormack L, Petrowsky H, Jochum W, Furrer K, Clavien PA. Hepatic steatosis is a risk factor for postoperative complications after major hepatectomy: a matched case-control study. *Ann Surg*. 2007;245:923-30.
35. Natarajan SK, Thomas S, Ramamoorthy P, Basivireddy J, Pulimood AB, Ramachandran A, et al. Oxidative stress in the development of liver cirrhosis: a comparison of two different experimental models. *J Gastroenterol Hepatol*. 2006;21:947-57.
36. McLean AE. Hepatic failure in malnutrition. *Lancet*. 1962;2:1292-4.
37. Serracino-Inglott F, Virlos IT, Habib NA, Williamson RC, Mathie RT. Differential nitric oxide synthase expression during hepatic ischemia-reperfusion. *Am J Surg*. 2003;185:589-95.
38. Pryor WA, Squadrito GL. The chemistry of peroxynitrite: a product from the reaction of nitric oxide with superoxide. *Am J Physiol*. 1995;268(5 Pt 1):L699-722.
39. Abe Y, Hines I, Zibari G, Grisham MB. Hepatocellular protection by nitric oxide or nitrite in ischemia and reperfusion injury. *Arch Biochem Biophys*. 2009;484:232-7.