

## CASE REPORT

# Scurvy in an alcoholic malnourished cirrhotic man with spontaneous bacterial peritonitis

André Luiz Maltos,<sup>1</sup> Guilherme Vannucchi Portari,<sup>III</sup> João Carlos Saldanha,<sup>II</sup> Aderbal Garcia Bernardes Júnior,<sup>I</sup> Guilherme Rocha Pardi,<sup>I</sup> Daniel Ferreira da Cunha<sup>I</sup>

<sup>I</sup>Federal University of Triângulo Mineiro, Department of Internal Medicine, Uberaba/MG, Brazil. <sup>II</sup>Federal University of Triângulo Mineiro, Special Pathology Division, Uberaba/MG, Brazil. <sup>III</sup>Federal University of Triângulo Mineiro, Faculty of Nutrition, Uberaba/MG, Brazil.

Email: andremaltos@yahoo.com.br  
Tel.: 55 34 33185335

## INTRODUCTION

Decreased serum levels of vitamin C are quite common in elderly hospitalized patients (1), especially those who are malnourished (2) or those with recent hip fractures (3). Although full-blown scurvy is currently uncommon in industrialized societies, the literature has described sporadic cases of scurvy in psychiatric patients and in malnourished, alcoholic, homeless patients (4). Scurvy has also been reported in cases where reductions in serum vitamin C levels occur concomitantly with activation of the immune system and increased circulating interleukins, as occurs in HIV-infection, malignancies and sepsis (5,6).

Whereas patients with alcoholic cirrhosis often have several forms of malnutrition, including obesity, pellagra, protein-energy malnutrition, and folic acid or thiamine deficiency, in a literature search of the MEDLINE database using terms such as cirrhosis, liver failure or liver insufficiency, vitamin C or ascorbic acid, and scurvy, we found only two cases of scurvy associated with hepatic disease: a 15-year-old girl awaiting combined kidney and liver retransplantation (7) and a malnourished alcoholic patient with mild fatty liver, without clinical or ultrasound evidence of cirrhosis or portal hypertension (8).

In this paper, we report the case of a chronically malnourished patient with alcoholic cirrhosis (Child-Pugh class B) who developed spontaneous bacterial peritonitis, kwashiorkor-like acute malnutrition, a full-blown picture of scurvy, and refeeding syndrome despite his low-energy diet.

## CASE DESCRIPTION

A 38-year-old white male with alcoholic cirrhosis diagnosed 3 years prior was admitted to the University Hospital with a 30-day history of anorexia, asthenia, ascites, and edema of the legs. He also complained of fever, diarrhea (3-4 episodes per day), and a productive cough over the last two days. The patient was taking 100 mg of spironolactone/day. At the time of the physical examination, the patient did not

have a fever (axillary temperature: 37°C) and was cachectic, pale (+++), with rales in both lungs, which were more intense on the left side. The patient had tense ascites, spider angiomas, and caput medusae, in addition to palmar erythema, and leg and scrotal edema. His skin was dry, with ecchymosis around both knees, and he had thinning hair and lesions resembling pellagra. Neurologic examination revealed that the patient was alert without intellectual or motor impairments (West-Haven hepatic encephalopathy criteria: 0).

The laboratory data at admission were as follows: blood hemoglobin: 6.2 g/dL; hematocrit: 20.3%; red blood cells: 2,160,000/mm<sup>3</sup>; mean corpuscular volume: 94 fL; red cell distribution width: 16%; white blood cells: 18,080, with a neutrophil count of 16,091/mm<sup>3</sup>, and 1,446 band forms/mm<sup>3</sup>; platelets: 265,000/mm<sup>3</sup>; C-reactive protein: 128 mg/dL; aspartate aminotransferase: 34 IU/L; alanine aminotransferase: 25 IU/L; lactate dehydrogenase: 435 IU/L; serum total protein: 4.1 g/dL; albumin 1.07 g/dL; international normalized ratio: 1.35; prothrombin activity: 68%; serum total bilirubin: 1.1 mg/dL; serum sodium: 136 mEq/L; potassium: 4.3 mEq/L; calcium: 7.2 mg/dL; phosphorus: 3.8 mg/dL; magnesium: 1.9 mg/dL; urea: 36 mg/dL; creatinine: 0.54 mg/dL; fasting blood glucose: 86 mg/dL; serum iron: 15.5 µg/dL, total iron-binding capacity: 74.5 µg/dL; folic acid: 5.5 ng/mL; vitamin B<sub>12</sub>: >1,000 pg/mL. Ascitic fluid analysis revealed the following: pH 8.0; density: 1,010; cells: 950/mm<sup>3</sup>, with a neutrophil count of 646/mm<sup>3</sup>; glucose: 95 mg/dL; lactate dehydrogenase: 931 IU/L; albumin: 0.16 g/dL (serum/ascitic liquid albumin gradient: 0.91, suggestive of exudate). Cytopathological examination revealed no neoplastic cells, and the bacterial culture was negative. The abdominal ultrasound revealed a normal gallbladder and biliary tract and a homogeneous atrophic liver. Abdominal computed tomography revealed a calcified pancreas, voluminous ascites, and mild left pleural effusion. Esophagogastroduodenoscopy revealed esophageal varices and mild gastritis.

After the diagnosis of liver cirrhosis (Child-Pugh class B) and spontaneous bacterial peritonitis, the patient was treated with IV ceftriaxone (1 g b.i.d.), oral spironolactone (100 mg/day), IV albumin (1.5 g/kg on the 1st day and 1.0 g/kg on the 3rd day), furosemide (20 mg IV, b.i.d.), intramuscular phytomenadione (10 mg), oral vitamin B complex, and packed blood cells.

The Nutrology Support Team was consulted and found signs of chronic malnutrition, including a low body mass

**Copyright** © 2012 CLINICS – This is an Open Access article distributed under the terms of the Creative Commons Attribution Non-Commercial License (<http://creativecommons.org/licenses/by-nc/3.0/>) which permits unrestricted non-commercial use, distribution, and reproduction in any medium, provided the original work is properly cited.

No potential conflict of interest was reported.

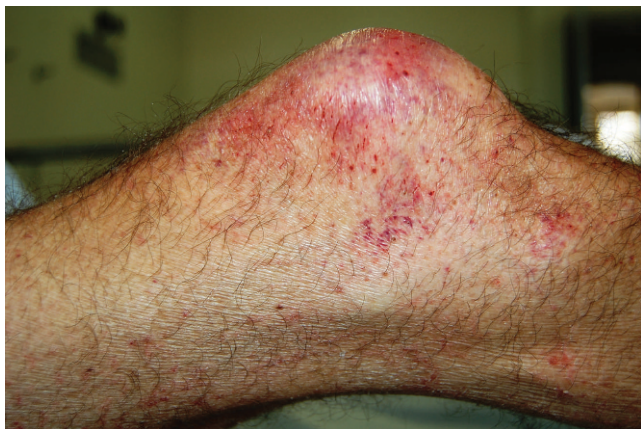index, 17.9 kg/m<sup>2</sup> (body weight: 48.8 kg) and signs of reduced corporal fat and muscle reserves (arm circumference: 15.5 cm; triceps skin fold: 3 mm). In addition to atrophic musculature in both thighs and lower legs, extensive bilateral subcutaneous edema with the presence of ecchymosis, corkscrew hairs, and perifollicular hemorrhage, mainly around the knees, were noted (Figure 1). A diagnosis of kwashiorkor (acute protein malnutrition) and scurvy was made, and because the patient was anorectic and consumed a diet that was low in energy and nutrients, enteral tube feeding was initiated. A skin biopsy and a blood sample to measure plasma ascorbic acid were obtained from the patient before the continuous IV infusion of 1.5 g of vitamin C/day was started.

The patient maintained a daily positive body water balance, experienced diarrhea, and developed serum electrolyte abnormalities, including hyponatremia (sodium: 130 mEq/L), hypokalemia (potassium: 2.99 mEq/L), hypomagnesemia (magnesium: 1.1 mg/dL), and hypophosphatemia (phosphorus: 1.98 mg/dL). A diagnosis of refeeding syndrome was made based on these electrolyte imbalances; the enteral nutrition that the patient was receiving (containing 1600 kcal (32 kcal/body weight) was tapered, and the electrolyte abnormalities were treated.

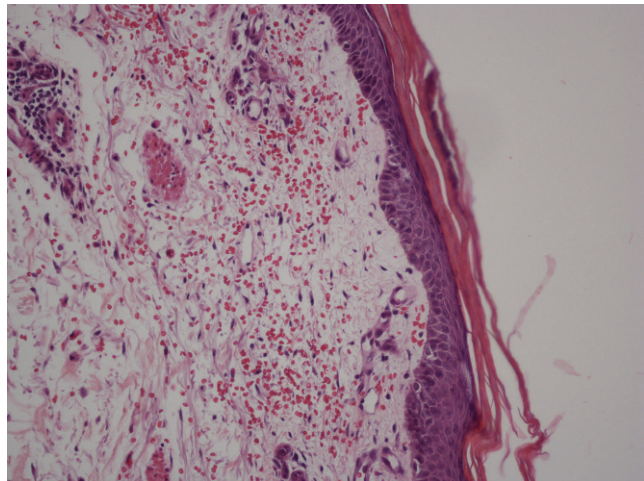
Despite hemodynamic support and medication treatment, the patient had a poor clinical evolution and died of septic shock 10 days after admission to the hospital. His initial serum level of vitamin C was <0.2 mg/dL, which increased to normal values (1.3 mg/dL) on the 4<sup>th</sup> day of IV vitamin C supplementation. The skin biopsy showed atrophic, hyperkeratosis epidermis. On the dermis, there were several hair follicles plugged with keratin, hemorrhage, and dermal atrophy, which are suggestive of scurvy (Figure 2).

## DISCUSSION

Although full-blown vitamin C deficiency is currently uncommon, sporadic cases of scurvy have been described, mainly among psychiatric, alcoholic, and HIV-AIDS patients or in children with bizarre food-intake habits (4,5,8). Although low ascorbic acid levels in leukocytes (a measure of tissue stores) are common in patients with alcoholic cirrhosis (9), this is the first reported case of scurvy in an alcoholic, malnourished man with cirrhosis and spontaneous bacterial peritonitis.



**Figure 1** - Ecchymosis, perifollicular hemorrhage, and corkscrew hairs in the right knee.



**Figure 2** - Scurvy: red cell extravasations around vessels in the upper dermis, dermal and epidermal atrophy and parakeratosis, and mild chronic perivascular inflammation.

In contrast to the typical features of scurvy in children, such as subperiosteal hematomas and gingival hypertrophy (10), adults with scurvy often manifest with weight loss, purpura, and other dermatologic lesions such as follicular hyperkeratosis and corkscrew hairs; in our case, the diagnosis was confirmed based on low serum vitamin C levels and a skin biopsy exhibiting the typical microscopic features of scurvy (6).

The presence of desquamative erythematous dermatitis suggestive of pellagra, anemia, and low albumin serum levels, as observed in our patient, suggests insufficient food intake and a chronic deficiency of vitamins, including ascorbic acid (11). Moreover, cirrhotic patients are at risk of vitamin deficiencies because of the reduced intake, malabsorption, diminished storage capacity, and increased renal excretion, in addition to increased tissue vitamin consumption due to infection or sepsis (9).

While the low albumin serum levels could be attributed to liver failure, this condition could also be caused by infection (12), as is the case for spontaneous bacterial peritonitis. Moreover, as often occurs in malnourished, vitamin A-deficient children, who can develop acute anatomical lesions such as xerophthalmia or keratomalacia during measles infection (13), it is also possible that a patient with a chronic vitamin C deficiency could develop the signs and symptoms of scurvy during an acute systemic inflammatory response, as was reported in a hospitalized patient with metastatic renal-cell carcinoma treated with high-dose of interleukin-2 (14). We also described the case of an AIDS patient with increased serum levels of C-reactive protein and multiple opportunistic infections, including neurotoxoplasmosis and acute pneumonia, who developed a full-blown case of scurvy (15). These findings are consistent with reports of an association between low serum vitamin C levels with the presence of an acute-phase response in intensive care units (16). It is noteworthy that in a critically ill patient, the drastic depletion of ascorbate is a direct result of the acute oxidative stress that is intrinsic to the systemic inflammatory response (16). Although our patient died of sepsis, it is noteworthy that high doses of vitamin C supplementation have been associated with better prognoses in critical care patients with low serum levels of

ascorbic acid because it helps to restore endothelial nitric oxide synthase, the expression of which is impaired in septic patients (16). In particular, high doses (3 g or more, administered parenterally) of ascorbic acid are required to achieve normal plasma levels in septic patients (18).

Refeeding syndrome can occur in patients with marasmus or kwashiorkor, alcoholism, or anorexia nervosa; after prolonged fasting; in the malnourished elderly; in cancer patients; and in obese patients after duodenal switch surgery (17). Our findings suggest that even when food intake is increased in a gradual and careful way, alcoholic cirrhotic patients with infection can develop electrolyte abnormalities and refeeding syndrome.

The limitations of this study include the measurements of serum ascorbic acid, instead of the intracellular leukocyte content of this vitamin. However, the skin biopsy showed characteristic features of scurvy, and although this patient had liver cirrhosis, the platelet count and the prothrombin activity, which were within normal values, suggest that the skin hemorrhage could not be ascribed to liver failure.

The description of this case of scurvy in a malnourished man with cirrhosis and infection should alert gastroenterologists to perform a careful skin examination, with ascorbic acid measurements when this exam is available.

## ACKNOWLEDGMENTS

This study was supported by the following: Fundação de Amparo à Pesquisa do Estado de Minas Gerais - FAPEMIG (process n° 3311/06) and Conselho Nacional de Pesquisa - CNPq (process n° 402832/2005-1).

## AUTHOR CONTRIBUTIONS

Cunha DF, Maltos AL, Bernardes Junior AG, Pardi GR designed the study, analyzed the data and wrote the paper. Saldanha JC conducted the histopathological analysis and analyzed the results. Portari GV carried out the vitamin C analysis and analyzed the results.

## REFERENCES

- Vannucchi H, da Cunha DF, Bernardes MM, Unamuno MR. Serum levels of vitamin A, E, C and B2, carotenoid and zinc in hospitalized elderly patients. *Rev Saude Publica.* 1994;28(2):121-6, <http://dx.doi.org/10.1590/S0034-89101994000200005>.
- Cunha DF, Cunha SF, Unamuno MR, Vancucchi H. Serum levels assessment of vitamin A, E, C, B2 and carotenoids in malnourished and non-malnourished hospitalized elderly patients. *Clin Nutr.* 2001;20(2):167-70, <http://dx.doi.org/10.1054/clnu.2000.0378>.
- Falch JA, Mowé M, Böhmer T. Low levels of serum ascorbic acid in elderly patients with hip fracture. *Scand J Clin Lab Invest.* 1998;58(3):225-8, <http://dx.doi.org/10.1080/00365519850186616>.
- Fain O, Paries J, Jacquart B, Le Moël G, Kettaneh A, Stirnemann J, et al. Hypovitaminosis C in hospitalized patients. *Eur J Intern Med.* 2003;14(7):419-25, <http://dx.doi.org/10.1016/j.ejim.2003.08.006>.
- Fain O. Vitamin C deficiency. *Rev Med Interne.* 2004;25(12):872-80, <http://dx.doi.org/10.1016/j.revmed.2004.03.009>.
- Burdette SD, Polenakovik H, Suryaprasad S. An HIV-infected man with odynophagia and rash. *Clin Infect Dis.* 2005;41(5):686-8, <http://dx.doi.org/10.1086/432575>.
- Samonte VA, Sherman PM, Taylor GP, Carricato MN, Fecteau A, Ling SC, et al. Scurvy diagnosed in a pediatric liver transplant patient awaiting combined kidney and liver retransplantation. *Pediatr Transplant.* 2008;12(3):363-7, <http://dx.doi.org/10.1111/j.1399-3046.2007.00800.x>.
- Léger D. Scurvy: reemergence of nutritional deficiencies. *Can Fam Physician.* 2008;54(10):1403-06.
- Beattie AD, Sherlock S. Ascorbic acid deficiency in liver disease. *Gut.* 1976;17(8):571-5, <http://dx.doi.org/10.1136/gut.17.8.571>.
- Akikusa JD, Garrick D, Nash MC. Scurvy: forgotten but not gone. *J Paediatr Child Health.* 2003;39(1):75-7, <http://dx.doi.org/10.1046/j.1440-1754.2003.00093.x>.
- Hodges RE, Baker EM, Hood J, Sauberlich HE, March SC. Experimental scurvy in man. *Am J Clin Nutr.* 1969;22(5):535-48.
- Monteiro JP, Cunha DF, da Cunha SF, dos Santos VM, Silva-Vergara ML, Correia D, et al. Iron status, malnutrition and acute phase response in HIV-positive patients. *Rev Soc Bras Med Trop.* 2000;33(2):175-80, <http://dx.doi.org/10.1590/S0037-8682200000200003>.
- Semba RD, Bloem MW. Measles blindness. *Surv Ophthalmol.* 2004;49(2):243-55, <http://dx.doi.org/10.1016/j.survophthal.2003.12.005>.
- Alexandrescu DT, Dasanu CA, Kauffman CL. Acute scurvy during treatment with interleukin-2. *Clin Exp Dermatol.* 2009;34(7):811-4, <http://dx.doi.org/10.1111/j.1365-2230.2008.03052.x>.
- Maltos AL, da Silva LL, Bernardes Júnior AG, Portari GV, da Cunha DF. Scurvy in patient with AIDS: case report. *Rev Soc Bras Med Trop.* 2011;44(1):122-3, <http://dx.doi.org/10.1590/S0037-86822011000100029>.
- Biesalski HK. Parenteral ascorbic acid as a key for regulating microcirculation in critically ill. *Crit Care Med.* 2008;36(8):2466-68, <http://dx.doi.org/10.1097/CCM.0b013e3181810494>.
- Crook MA, Hally V, Panteli JV. The importance of refeeding syndrome. *Nutrition.* 2001;17(7-8):632-7, [http://dx.doi.org/10.1016/S0899-9007\(01\)00542-1](http://dx.doi.org/10.1016/S0899-9007(01)00542-1).
- Long CL, Maull KL, Krishnan RS, Laws HL, Geiger J, Borghesi L, et al. Ascorbic acid dynamics in the seriously ill and injured. *J Surg Res.* 2003;109(2):144-8, [http://dx.doi.org/10.1016/S0022-4804\(02\)00083-5](http://dx.doi.org/10.1016/S0022-4804(02)00083-5).