

CLINICAL SCIENCE

A comparative radiographic investigation of femoroacetabular impingement in young patients with and without hip pain

Omar Ferreira Miguel,^I Henrique Berwanger de Amorim Cabrita,^{II} Marcelo Bordalo Rodrigues,^{III} Alberto Tesconi Croci^{IV}

^IFaculdade de Medicina da Universidade de São Paulo, Institute of Orthopedics and Traumatology, Arthroplasty Service, São Paulo/SP, Brazil. ^{II}Faculdade de Medicina da Universidade de São Paulo, Institute of Orthopedics and Traumatology, Emergency Group, São Paulo/SP, Brazil. ^{III}Faculdade de Medicina da Universidade de São Paulo, Institute of Orthopedics and Traumatology, Head of the Radiology Service of the Institute of Orthopedics and Traumatology, São Paulo/SP, Brazil. ^{IV}Faculdade de Medicina da Universidade de São Paulo, Institute of Orthopedics and Traumatology, Arthroplasty Service, São Paulo/SP, Brazil.

OBJECTIVE: To compare the existence of radiographic abnormalities in two groups of patients, those with and without hip pain.

METHODS: A total 222 patients were evaluated between March 2007 and April 2009; 122 complained of groin pain, and 100 had no symptoms. The individuals in both groups underwent radiographic examinations of the hip using the following views: anteroposterior, Lequesne false profile, Dunn, Dunn 45°, and Ducroquet.

RESULTS: A total of 1110 radiographs were evaluated. Female patients were prevalent in both groups (52% symptomatic, 58% asymptomatic). There were statistically significant differences between the groups in age ($p < 0.0001$), weight ($p = 0.002$) and BMI ($p = 0.006$). The positive findings in the group with groin pain consisted of the presence of a bump on the femoral head in the anteroposterior view ($p < 0.0001$) or in the Dunn 45° view ($p = 0.008$). The difference in the α angle in the anteroposterior, Dunn, Dunn 45°, and Ducroquet views for all of the cases studied was $p < 0.0001$. The joint space measurement differed significantly between groups in the Lequesne view ($p = 0.007$). The Lequesne anteversion angle (ρ) and the femoral offset measurement also differed significantly ($p = 0.005$ and $p = 0.0001$, respectively).

CONCLUSIONS: We conclude that the best views for diagnosing a femoroacetabular impingement are the anteroposterior pelvic orthostatic, the Dunn 45°, and the Ducroquet views. The following findings correlated with hip pain: a decrease in the femoral offset, an increase in the α angle, an increase in the Lequesne ρ angle, a decrease in the CE angle of Wiberg, a thinner articular space and the presence of a bump on the femoral head-neck transition.

KEYWORDS: Radiography; Articular Pain; Hip Joint; Femoral Head; Abnormalities; Femoroacetabular Impingement.

Miguel OF, Cabrita HB, Rodrigues MB, Croci AT. A comparative radiographic investigation of femoroacetabular impingement in young patients with and without hip pain. Clinics. 2012;67(5):463-467.

Received for publication on January 3, 2012; First review completed on January 27, 2012; Accepted for publication on January 27, 2012

E-mail: omarfmiguel@gmail.com

Tel.: 55 16 8111-8582

INTRODUCTION

Studies conducted on the pathogenesis of osteoarthritis show a gradual loss of the components of the cartilaginous matrix. This loss initially occurs via a decrease in the level of proteoglycans and through changes in the integrity of the collagen structure (1). Focal areas of damage to the joint cartilage, with fibrillation and loss of volume, are one of the hallmarks of osteoarthritis (OA). The localizations and

severity of those cartilaginous injuries are primarily defined by mechanical factors that are involved in the etiopathogenesis of OA (2).

The loss of the biomechanical properties associated with the events that produce repetitive injuries, and the subsequent deterioration of the cartilage, cause erosion of the joint surface extending as far as the subchondral bone (3).

The mechanisms related to axial overload alone cannot explain the full development of OA in individuals whose skeletal structures and intra-articular pressures are apparently normal.

The study of the deformities that give rise to abnormal collisions between the bone structures of the femur and the acetabulum have demonstrated that one of the main causes of hip cartilage degeneration are the biomechanical and

Copyright © 2012 CLINICS – This is an Open Access article distributed under the terms of the Creative Commons Attribution Non-Commercial License (<http://creativecommons.org/licenses/by-nc/3.0/>) which permits unrestricted non-commercial use, distribution, and reproduction in any medium, provided the original work is properly cited.

No potential conflict of interest was reported.

bone structural changes that affect the rotational movement of the joint, i.e., the femoroacetabular impact (FAI) (4-7). This field is an evolving area of research in hip OA.

According to Peixoto et al. (8), OA is responsible for 7.7% of all hospital admissions within the Brazilian National Health System and 7.6% of the healthcare funds in this country. Between 1997 and 2001, according to these same authors, there was a 194.4% increase in hospital admissions due to OA.

Hip OA is diagnosed based on the patient history and physical examination and is confirmed with plain radiographs that include anteroposterior (AP) panoramic radiography of the pelvis and AP and lateral views of the hip joint (4,8,9).

No consensus exists regarding the series of radiographic views that might demonstrate factors that would predispose individuals to the development of hip OA.

The early detection of anatomic and biomechanical abnormalities may result in early clinical or surgical interventions to prevent the degeneration of the joint (10).

The objective of the present study was to evaluate the utility of a radiographic series for the early detection of factors that may predispose individuals to developing hip OA.

MATERIALS AND METHODS

This study was approved by the Ethics Committee of Hospital das Clínicas, School of Medicine, University of São Paulo. A total of 222 patients were evaluated between March 2007 and April 2009.

One hundred twenty-two patients complained of groin pain and were followed for treatment in the Hip Group of our institution. One hundred patients without symptoms formed the control group and were followed for treatment in the Shoulder and Elbow Group of our institution.

Only one hip with a normal range of motion was studied per patient.

In patients with groin pain on both sides, only the most symptomatic hip was studied. If the pain intensity was similar or the same on both sides, one side was randomly selected to be radiographed. If the patient had only one painful hip, the asymptomatic hip was not included in the control group to avoid possible bias from patients who were influenced by their own control.

In the asymptomatic group, hips were randomly selected to ensure the randomization of sides.

The inclusion criteria for both groups were the following:

1. Age between 20 and 50 years.
2. The absence of prior hip disease, lumbar pain, or any orthopedic treatment (exceptions included diseases of the shoulder and elbow).
3. Normal range of motion of the hip (as measured with manual goniometric tools).
4. Agreeing to participate in the project by signing an informed consent form.

The exclusion criteria included the following:

1. Technical difficulties or the inability of the patient to remain on the table during radiographic procedures.
2. An expressed desire by the patient to withdraw from the study.

3. The presence of osteoarthritis up to a grade two on the Lawrence classification scale (34) and confirmed by the first radiographic image.

4. The presence of morphological and/or anatomical abnormalities compatible with childhood diseases, trauma sequelae, or tumoral disease.

Anthropometric data were obtained to calculate the body mass index (BMI).

This study and the accompanying informed consent statement were approved by the Ethics Committee for Research Project Analysis under protocol number 1342/06.

Radiographic evaluation

All of the radiographic procedures were performed with Phillips Medical Systems Duo Diagnost 800 mA equipment.

The sequence of radiographic images included the following: an AP view of the hip while the patient was standing upright on two feet (11), a Lequesne false profile view, a Dunn view, a Dunn view with 45 degrees of flexion (Dunn 45°), and a Ducroquet view (12,13).

Data Analysis

The sequence of evaluation for each view included the following:

1. AP: an orthostatic support was used to maintain the limbs at 20° of internal rotation, and the x-ray tube was centralized to the sacrum and parallel to the floor. The center-edge angle of Wiberg, the width of the joint space, the acetabular tilt (14), the acetabular retroversion or anteversion, the alpha angle (α) (6,7,13) (Figure 1A), and the presence or absence of a "bump" were evaluated.
2. Lequesne false profile: the patient was placed in the upright position with 65° of external rotation of the pelvis, and the tube was centered on the hip. We measured the vertical-central anterior Lequesne and Sèze angle (VCA) (25), the anterosuperior joint space, and the Lequesne femoral anteversion angle (ρ) (Figure 1B) (6,13,15).
3. Dunn: the patient was placed in the supine position with 90° flexion of the hip and knee and 20° abduction of the hip without any rotational deviation. We measured the alpha (α) angle (Figure 1C) and the presence or absence of a "bump" at the femoral head-neck junction (12).
4. Dunn 45°: the patient was placed in the supine position with 45° flexion and 20° abduction of the hip without any rotational deviation. The α angle (Figure 1D) and the presence or absence of a "bump" were measured (12).
5. Ducroquet: the patient was placed in the supine position with 90° flexion and 45° abduction of the hip without any rotational deviation. The femoral offset (the difference between the center of the femoral head and the axis of the neck), the α angle (Figure 1E), and the presence or absence of a "bump" were measured (12,13,15).

In each case, the α angle was measured as follows: the first line follows the long axis of the femoral neck and passes through the femoral head center, and the second line passes through the femoral head center and through the femoral head and neck junction (7).

The Lequesne femoral anteversion angle (ρ) is measured as follows: the first line passes through the femoral diaphysis

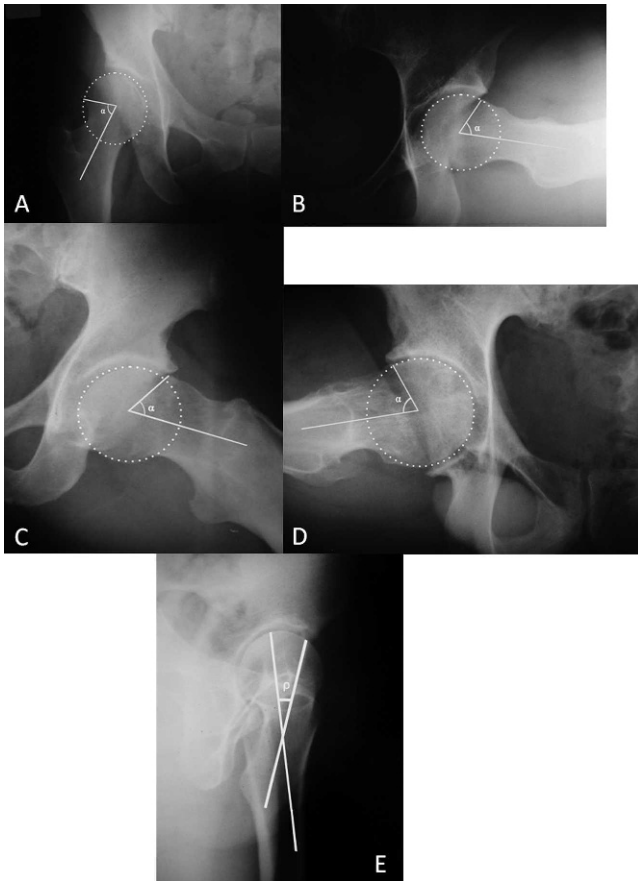


Figure 1 - Samples of the measurement of α and ρ angles: (A) α angle in the AP view, (B) Lequesne femoral anteversion angle (ρ) in the Lequesne false profile view, (C) α angle in the Dunn view, (D) α angle in the Dunn 45° view and (E) α angle in the Ducroquet view.

center, and the second line passes through the major diameter of the femoral neck. The angle formed by the junction of these two lines is referred to as the ρ angle (12).

Statistical analysis

The normality of the distributions was assessed using the Kolmogorov-Smirnov test for continuous variables. The distribution was accepted as parametric if the results of the Kolmogorov-Smirnov (KS) test were not significant. Parametric tests were used only for the comparison between distributions that were considered to be normal (Gauss curves).

The descriptive statistics and the results of the Kolmogorov-Smirnov (KS) test for each variable are presented in the statistical tables according to the groups (samples).

The Student's t test was used for unrelated samples with a parametric distribution to infer the differences between the means of the variables, and the Mann-Whitney U test was

used for independent samples with a nonparametric distribution.

A confidence level of 5% ($\alpha=0.05$) was used.

RESULTS

General Clinical Findings

The group of symptomatic patients consisted primarily of female patients (52%) with a mean age of 41 years, a mean height of 1.7 m, a mean weight of 71.4 kg and a mean BMI of 24.6.

The group of asymptomatic patients consisted primarily of female patients (58%) with a mean age of 31 years, a mean height of 1.68 m, a mean weight of 66.2 kg and a mean BMI of 23.3.

Statistically significant differences were observed between the groups in terms of age ($p<0.0001$), weight ($p=0.002$), and BMI ($p=0.006$).

In our study, we evaluated a total of 222 patients and 222 hips with 1110 radiographs. Our sample size was larger than those of prior studies according to our review of the literature (7,14,16-21).

Radiologic measurements of the hip joint

A bump in the AP view was more frequently present in the symptomatic cases ($p<0.0001$). A bump was observed in 3% of the asymptomatic cases and in 24% of the symptomatic cases. In the Dunn 45° view, a bump was visualized in 24% of the asymptomatic cases and in 41% of the symptomatic cases ($p=0.008$).

For the Ducroquet and Dunn views, no statistically significant differences were present in terms of the visualization of a bump ($p=0.35$ and $p=0.91$, respectively).

With regard to the acetabular version, there were no statistically significant findings in the AP view ($p=0.30$).

The evaluation of the α angle (Table 1) demonstrated statistical significance in all of the cases. For the AP view, the mean α angle was 53° (SD=11.6) for the asymptomatic cases and 72.7° ($p<0.0001$) (SD=9.1) for the symptomatic cases (Table 1). For the Dunn view, the mean α angle was 59.8° (SD=10.9) for the asymptomatic cases and 71.6° ($p<0.0001$) (SD=7.0) for the symptomatic cases (Table 1). For the Dunn 45° view, the mean α angle was 67.5° (SD=8.1) for the asymptomatic cases and 72.7° ($p<0.0001$) (SD=6.4) for the symptomatic cases (Table 1). For the Ducroquet view, the mean α angle was 59.1° (SD=8.2) for the asymptomatic cases and 71.2° ($p<0.0001$) (SD=7.1) for the symptomatic cases (Table 1).

The acetabular inclination data did not demonstrate any statistically significant differences in our study ($p=0.28$).

The joint space, which was also evaluated from the AP and Lequesne views, only revealed a significant difference in the Lequesne view ($p=0.007$) with a mean of 4.9 millimeters for the asymptomatic group (SD=0.9) and 4.5

Table 1 - Comparison of the Radiographic Measurements.

Measurements	Radiographic View	Asymptomatic	Symptomatic	p-value
α angle	Anteroposterior	53 +/- 11.6	72.7 +/- 9.1	$p<0.0001$
	Dunn	59.8 +/- 10.9	71.6 +/- 7	$p<0.0001$
	Dunn 45°	67.5 +/- 8.1	72.7 +/- 6.4	$p<0.0001$
	Ducroquet	59.1 +/- 8.2	71.2 +/- 7.1	$p<0.0001$
ρ angle	Lequesne	17 +/- 3.2	17.8 +/- 10.2	$p=0.005$

Table 2 - Comparison between the data from Meyer et al. 2006 and the data from our study.

Radiographic view	α angle (symptomatic), our study	α angle (asymptomatic), our study	α angle, Meyer et al. 2006
AP	72.7+/- 9.1°	53+/- 11.6°	50°
Dunn	71.6+/- 7°	59.8+/- 10.8°	50°
Dunn 45°	72.7+/- 6.4°	67.5+/- 8.1°	50°
Ducroquet	71.2+/- 7.1°	59.1+/- 8.2°	45°

millimeters for the symptomatic group (SD=1.2). However, no significant differences were observed on the AP view ($p=0.30$).

Using the AP view, the mean center-edge (CE) angle of Wiberg was 30° (SD=7.8) for the asymptomatic group and 27.5° (SD=9.9) for the symptomatic group. These findings were statistically significant ($p=0.03$).

No statistically significant differences were found between the groups in the Lequesne view with regard to the criterion of the VCA angle ($p=0.30$).

The measurement of the Lequesne anteversion angle (ρ) (Table 1) was significantly different between the two groups ($p=0.005$). The mean was 17° (SD=3.2) for the asymptomatic group and 18° (SD=10.2) for the symptomatic group.

A statistically significant difference was also demonstrated in the measurement of the femoral offset ($p=0.0001$). The patients in the asymptomatic group had a mean value of eight millimeters, whereas those in the symptomatic group had a mean value of seven millimeters.

DISCUSSION

A review of the literature reveals that many studies have analyzed the α angle, the femoral offset, the sphericity of the femoral head-neck, and the existence of a protuberance or bump (1,3,5,12,14,21,24-27). However, no prior studies analyzed and compared the radiographs of symptomatic and asymptomatic hips in reference to factors possibly associated with the development of osteoarthritis in young adults.

A large number of studies have noted that the presence of bumps promotes impingement (3,5,10,17,21,24,28-32), but no studies have evaluated the prevalence of cam impingement in radiographic examinations. In our study, the presence of bumps was evaluated using the AP, Dunn, Dunn 45°, and Ducroquet views. The data obtained from the AP and Dunn 45° views in the symptomatic cases were statistically significant, with a 24% ($p<0.0001$) prevalence of bumps in the AP view and a 41% ($p=0.008$) prevalence of bumps in the Dunn 45° view. No significant differences were present in the Dunn and Ducroquet views ($p=0.91$ and $p=0.35$, respectively). This analysis revealed the best views for diagnosing bumps to be the AP and Dunn 45° views (12). Other data obtained in this study showed the mean height of the bumps to be 4 mm.

The α angle (Figure 1) was measured in accordance with the descriptions of Nötzli et al. (7) and Meyer et al. (12) using the AP (Figure 1 A), Dunn (Figure 1C), Dunn 45° (Figure 1D), and Ducroquet (Figure 1E) views. Each of these views demonstrated statistically significant differences, all $p<0.0001$ (Table 1). However, in our study, we found that the observed values of the α angle for normal (asymptomatic) hips using these views were greater than what was previously described by Nötzli et al. (7), Meyer et al. (12) (Table 2), and Rackhra et al. (32). The values reported by these studies are closer to those of our study, particularly

the results for the femoroacetabular impingement cam type. The mean α angle in our study was 72.7°, compared to 74.1° in the Rackhra et al. (32) study. In our study, the mean α angles for normal (asymptomatic) hips for each view were as follows: the AP view, 53°; the Dunn view, 59.8°; the Dunn 45° view, 67.5°; and the Ducroquet view, 59.1°. For the symptomatic hips, the mean values for each view were as follows: the AP view, 72.7°; the Dunn view, 71.6°; the Dunn 45° view, 72.7°; and the Ducroquet view, 71.2°.

The measurements of the superolateral joint space in the AP view did not differ statistically between the groups ($p=0.3$). However, for the superolateral joint space measurements obtained using the Lequesne view, the mean value was 4.5 mm in the symptomatic group and 4.9 mm in the asymptomatic group ($p=0.007$). These values suggest the reduction in joint space to be a significant cause of hip pain.

According to Meyer et al. (12), the mean ρ angle measured in the Lequesne view (Figure 1B) for normal patients was 21° with a range from 12 to 30°. In our study, the mean value was 17° for the asymptomatic group and 17.8° for the symptomatic group, both values considered to be within the normal range. However, the difference between the groups was significant ($p=0.005$), which led to the conclusion that diseased hips have an abnormal ρ angle when compared with the control group (Table 1). Despite the small differences between the means, the symptomatic group had ρ angle variations ranging from 6 to 52°.

The evaluation of the femoral offset using the Ducroquet view revealed a statistically significant difference between the symptomatic group, with a mean of 7 mm, and the asymptomatic group, with a mean of 8.1 mm ($p=0.02$). Therefore, in painful hips, the space between the femoral head and the femoral neck is substantially smaller. The data in the literature suggest that the normal value should be 11 mm (21,33). However, Wenger et al. (1) suggested that normal values were as low as 7 mm.

We identified the following points related to painful conditions of the hip:

1. A diminished femoral offset.
2. An increase in the α angle.
3. An increase in the Lequesne ρ angle.
4. A decrease in the CE angle of Wiberg.
5. A decrease of the joint space.
6. The presence of a bump at the femoral head-neck transition.

The best views for diagnosing femoroacetabular impingement are the pelvic orthostatic AP, and the Dunn 45° and Ducroquet views.

AUTHOR CONTRIBUTIONS

Miguel OF contributed to the original idea, data collection, discussion and conclusions. Cabrita HB contributed to the original idea and project development. Rodrigues MB contributed to the orientation of the

radiographic examination and analysis of the images. Croci AT provided scientific advice and reviewed the manuscript.

REFERENCES

- Wenger DE, Kendall KR, Miner MR, Trousdale RT. Acetabular labral tears rarely occur in the absence of bony abnormalities. *Clin Orthop Relat Res.* 2004;(426):145-50, <http://dx.doi.org/10.1097/01.blo.0000136903.01368.20>.
- Brown CR. Arthritis and allied conditions. In: Callaghan JJ, Rosenberg AG, Rubash HE, editors. *The adult hip.* 2nd ed. Philadelphia: Lippincott Williams & Wilkins; 2007. p.572-84
- Correia AM. Estudo comparativo do posicionamento acetabular e sua relação com osteoartrite primária do quadril [dissertação]. São Paulo: Faculdade de Medicina. Universidade de São Paulo; 2007.
- Beall DP, Sweet CF, Martin HD, Lastine CL, Grayson DE, Ly JQ, et al. *Skeletal Radiol.* 2005;34(11):691-701.
- Goodman DA, Feighan JE, Smith AD, Latimer B, Buly RL, Cooperman DR. Subclinical slipped capital femoral epiphysis: Relation to osteoarthritis of the Hip. *J Bone Joint Surg Am.* 1997;79(10):1489-97.
- Klaue K, Durnin CW, Ganz R. The Acetabular Rim Syndrome: A Clinical presentation of dysplasia of the hip. *J Bone Joint Surg Br.* 1991;73(3):423-9.
- Nötzli HP, Wyss TF, Soecklin CH, Schmid MR, Treiber K, Hodler J. The contour of the femoral head-neck junction as a predictor for the risk of anterior impingement. *J Bone Joint Surg Br.* 2002; 84(4):556-60, <http://dx.doi.org/10.1302/0301-620X.84B4.12014>.
- Peixoto SV, Giatti L, Afradique ME, Lima-Costa MF. Custo das internações hospitalares entre idosos brasileiros no âmbito do Sistema Único de Saúde. *Epidem Serv Saúde.* 2004;13(3):239-46.
- Harris WH. Etiology of osteoarthritis of the hip. *Clin Orthop Relat Res.* 1986;(213):20-33.
- Siebenrock KA, Schoeniger R, Ganz R. Anterior femoro-acetabular impingement due to acetabular retroversion: treatment with periacetabular osteotomy. *J Bone Joint Surg Am.* 2003;85(2):278-86.
- Blankenbaker DG, Tuite MJ. The painful hip: new concepts. *Skeletal Radiol.* 2006;35(6):352-70, <http://dx.doi.org/10.1007/s00256-006-0105-5>.
- Meyer DC, Beck M, Ellis T, Ganz R, Leunig M. Comparison of six radiographic projections to assess femoral head/neck asphericity. *Clin Orthop Relat Res.* 2006;(445):181-5.
- Tönnis D, Heinecke A. Acetabular and femoral anteversion: Relationship with osteoarthritis of the hip. *J Bone Joint Surg Am.* 1999;81(12):1747-70.
- Tannast M, Goricki D, Beck M, Murphy SB, Siebenrock KA. Hip damage occurs at the zone of femoroacetabular impingement. *Clin Orthop Relat Res.* 2008;(466):273-80, <http://dx.doi.org/10.1007/s11999-007-0061-y>.
- Eijer H, Myers SR, Ganz R. Anterior femoroacetabular impingement after femoral neck fractures. *J Orthop Trauma.* 2001;15(7):475-81, <http://dx.doi.org/10.1097/00005131-200109000-00003>.
- Cooperman DR, Wallensten R, Stulberg SD. Acetabular dysplasia in the adult. *Clin Orthop Rel Res.* 1983;(175):79-85.
- Dudda M, Mamisich TC, Beck C. Do normal radiographs exclude asphericity of the femoral head-neck junction? *Clin Orthop Relat Res.* 2009;(467):651-9, <http://dx.doi.org/10.1007/s11999-008-0617-5>.
- Labronici JP, Alves SD, Silva AF, Giuberti GR, Hoffmann R, Azevedo Neto JN, et al. Estudo anatômico do terço proximal do fêmur: impacto femoroacetabular e o efeito cam. *Rev Bras Ortop.* 2009;44(2):120-4.
- Lloyd-Roberts GC. Osteoarthritis of the hip: a study of the clinical pathology. *J Bone Joint Surg Br.* 1955;37(1):8-47.
- Murray RO. The aetiology of primary osteoarthritis of the hip. *Br J Radiol.* 1965;38(455):810-24, <http://dx.doi.org/10.1259/0007-1285-38-455-810>.
- Peelle MW, Della Rocca GJ, Maloney WJ, Curry MC, Clohisy JC. Acetabular and femoral radiographic abnormalities associated with labral tears. *Clin Orthop Relat Res.* 2005;(441):327-33, <http://dx.doi.org/10.1097/01.blo.0000181147.86058.74>.
- Solomon L. Patterns of osteoarthritis of the hip. *J Bone Joint Surg Br.* 1976;58(2):176-83.
- Tannast M, Siebenrock KA, Anderson SE. Femoroacetabular impingement: radiographic diagnosis – what the radiologist should know. *AJR Am J Roentgenol.* 2007;188(6):1540-52, <http://dx.doi.org/10.2214/AJR.06.0921>.
- Clohisy JC, Knaus ER, Hunt DM, Leshner JM, Harris-Hayes M, Prathre H. Clinical presentation of patients with symptomatic anterior hip impingement. *Clin Orthop Relat Res.* 2009;(467):638-44, <http://dx.doi.org/10.1007/s11999-008-0680-y>.
- Delaunay S, Dussault RG, Kaplan PA, Alford BA. Radiographic measurements of dysplastic adult hips. *Skeletal Radiol.* 1997;26(2):75-81, <http://dx.doi.org/10.1007/s002560050197>.
- Lequesne M, Malghem J, Dion E. The normal hip joint space: variations in width, shape, and architecture on 223 pelvic radiographs. *Ann Rheum Dis.* 2004;63(9):1145-51.
- Reynolds D, Lucas J, Klaue K. Retroversion of the acetabulum: a cause of hip pain. *J Bone Joint Surg Br.* 1999;81(2):281-8, <http://dx.doi.org/10.1302/0301-620X.81B2.8291>.
- Crestani MV, Telöken MA, Gusmão PA. Impacto femoroacetabular: uma das condições precursoras da osteoartrose do quadril. *Rev Bras Ortop.* 2006;41(8):285-93.
- Ganz R, Parvizi J, Beck M, Leunig M, Nötzli H, Siebenrock KA. Femoroacetabular impingement: a cause for osteoarthritis of the hip. *Clin Orthop Relat Res.* 2003;(417):112-20.
- Graves ML, Mast JW. Femoroacetabular impingement do outcomes reliably improve with surgical dislocations? *Clin Orthop Rel Res.* 2009;(467):717-23.
- Leunig M, Beulé PE, Ganz R. The concept of femoroacetabular impingement current status and future perspectives. *Clin Orthop Relat Res.* 2009;(467):616-22, <http://dx.doi.org/10.1007/s11999-008-0646-0>.
- Rackhra KS, Sheikh AM, Allen D, Beaulé PE. Comparison of MRI alpha angle measurement planes in femoroacetabular impingement. *Clin Orthop Rel Res.* 2009;(467):660-5.
- Beck M, Kalhor M, Leunig M, Ganz R. Hip morphology influences the pattern of damage to the acetabular cartilage: femoroacetabular impingement as a cause of early osteoarthritis of the hip. *J Bone Joint Surg Br.* 2005;87(7):1012-8.
- Kellgren JH, Lawrence JS. Radiological assessment of osteo-arthrosis. *Ann Rheum Dis.* 1957;16(4):494-502, <http://dx.doi.org/10.1136/ard.16.4.494>.