

REVIEW

Surgical approach in patients with hyperparathyroidism in multiple endocrine neoplasia type 1: total versus partial parathyroidectomy

Francesco Tonelli,¹ Francesco Giudici,¹ Tiziana Cavalli,¹ Maria Luisa Brandi^{II}

^IUniversity of Florence, Department of Clinical Physiopathology, Surgical Unit, Florence, Italy. ^{II}University of Florence, Department of Internal Medicine, Florence, Italy.

Usually, primary hyperparathyroidism is the first endocrinopathy to be diagnosed in patients with multiple endocrine neoplasia type 1, and is also the most common one. The timing of the surgery and strategy in multiple endocrine neoplasia type 1/hyperparathyroidism are still under debate. The aims of surgery are to: 1) correct hypercalcemia, thus preventing persistent or recurrent hyperparathyroidism; 2) avoid persistent hypoparathyroidism; and 3) facilitate the surgical treatment of possible recurrences. Currently, two types of surgical approach are indicated: 1) subtotal parathyroidectomy with removal of at least 3–3½ glands; and 2) total parathyroidectomy with grafting of autologous parathyroid tissue. Transcervical thymectomy must be performed with both of these procedures. Unsuccessful surgical treatment of hyperparathyroidism is more frequently observed in multiple endocrine neoplasia type 1 than in sporadic hyperparathyroidism. The recurrence rate is strongly influenced by: 1) the lack of a pre-operative multiple endocrine neoplasia type 1 diagnosis; 2) the surgeon's experience; 3) the timing of surgery; 4) the possibility of performing intra-operative confirmation (histologic examination, rapid parathyroid hormone assay) of the curative potential of the surgical procedure; and, 5) the surgical strategy. Persistent hyperparathyroidism seems to be more frequent after subtotal parathyroidectomy than after total parathyroidectomy with autologous graft of parathyroid tissue. Conversely, recurrent hyperparathyroidism has a similar frequency in the two surgical strategies. To plan further operations, it is very helpful to know all the available data about previous surgery and to undertake accurate identification of the site of recurrence.

KEYWORDS: Primary hyperparathyroidism; MEN1; Surgery; Total parathyroidectomy; Subtotal parathyroidectomy.

Tonelli F, Giudici F, Cavalli T, Brandi ML. Surgical approach in patients with hyperparathyroidism in multiple endocrine neoplasia type 1: total versus partial parathyroidectomy. *Clinics*. 2012;67(S1):155-160.

E-mail: francesco.tonelli@unifi.it

Tel.: +39-055-7947559

INTRODUCTION

Usually, primary hyperparathyroidism (HPT) is the first endocrinopathy to be diagnosed in patients with multiple endocrine neoplasia type 1 (MEN1), and is the most common one (1). The optimal surgical timing and strategy in HPT/MEN1 are still under debate. The aims of surgery are to: correct hypercalcemia, and thus prevent persistent or recurrent hyperparathyroidism; avoid persistent hypoparathyroidism; and facilitate the surgical treatment of possible recurrences. Currently, two types of surgical approaches are indicated: subtotal parathyroidectomy (SPTX) with removal of at least 3–3.5 glands; and total parathyroidectomy with autologous graft of parathyroid tissue (TPTX). Transcervical thymectomy must be performed with both procedures.

However, controlled clinical trials comparing SPTX and TPTX are lacking. Review of the published surgical data shows that persistent HPT is more frequent after SPTX than after TPTX, and recurrent hyperparathyroidism has a similar percentage in both surgical options. The recurrence rate is strongly influenced by the lack of a pre-operative diagnosis of MEN1, the surgeon's experience, the timing of the surgery, and the possibility of performing intra-operative confirmation [histologic examination and rapid parathyroid hormone (PTH) assay] of the potential curative capacity of the surgical procedure. To plan further operations, it is very helpful to have all the available data about previous surgery and to undertake accurate identification of the possible site of the recurrence.

Penetrance in HPT/MEN1 is nearly 100% at the age of 50 years; the age of onset of biochemical alteration is usually 20–25 years (2).

As in sporadic HPT, diagnosis is usually prompted by the presence of hypercalcemia, with elevated serum levels of ionized calcium and PTH. Parathyroid gland involvement in MEN1 is asynchronous and asymmetrical; the change in volume varies, but the maximum/minimum mean volume ratio is 9.6 (3). Macroscopically normal parathyroid glands

Copyright © 2012 CLINICS – This is an Open Access article distributed under the terms of the Creative Commons Attribution Non-Commercial License (<http://creativecommons.org/licenses/by-nc/3.0/>) which permits unrestricted non-commercial use, distribution, and reproduction in any medium, provided the original work is properly cited.

No potential conflict of interest was reported.

make up 12–55% of all glands; sometimes the intra-operative findings may consist of just one or two enlarged glands (4–6). Moreover, the frequency of supernumerary glands (up to 20% in HPT/MEN1) (6,7) and of ectopic glands (often intrathymic, within the thyroid gland, in the anterior mediastinum) is higher than expected (5,8). Some reports describe the presence of parathyroid nests (embryonic parathyroid rests, a direct result of ontogenesis) embedded within the fatty tissue surrounding the trachea, esophagus, and carotid artery (8–11). Genetic testing is the gold standard to confirm diagnosis of MEN1, and should be performed in any young patient with hyperparathyroidism, even in the absence of a clear familial history of MEN1 syndrome.

Timing of surgery

The optimal timing for surgery in HPT/MEN1 is still under debate. It is possible to follow the same indications used for sporadic HPT, taking into account that cases of HPT/MEN1 often have only mildly elevated calcium and PTH levels. However, even when MEN1-related HPT has a long asymptomatic phase, it is important to note that it is the cause of a detectable bone mass decrease at a young age (12). Correction of hypercalcemia by prompt intervention is helpful in patients who show a decrease in bone mineral density, as it can prevent renal complications and may be of benefit for other concomitant endocrinopathies, such as hypergastrinemia (13).

In the case of concomitant multiple endocrinopathies in patients with HPT/MEN1, there is agreement among authors on the need to treat the HPT first, with the exception of cases of insulinoma.

Surgical strategy

The aims of surgery are to correct hypercalcemia, preventing persistent or recurrent HPT; avoid persistent hypoparathyroidism; and facilitate the surgical treatment of possible recurrences.

Less than subtotal parathyroidectomy, with removal of enlarged glands only, is associated with a high persistence/recurrence rate, so it is no longer used for diagnosed MEN1-HPT. Therefore, two surgical approaches are in routine use: SPTX, with removal of at least 3–3.5 glands, or TPTX. Transcervical thymectomy must be performed with both procedures as the thymus can harbor an ectopic parathyroid gland; thymectomy is also helpful in preventing thymic carcinoids possibly arising during the evolution of the syndrome.

Subtotal parathyroidectomy (SPTX). SPTX is defined as the removal of three glands and part of the fourth (usually the least involved one), preserving not more than 50 mg of parathyroid tissue. The fourth gland can also be completely preserved if normal in volume. SPTX is used with the main aim of avoiding permanent hypoparathyroidism and also of reducing the risk of early postoperative hypocalcemia.

SPTX becomes the surgical choice when a fourth parathyroid cannot be found out during surgery. This occurs in up to 20% of cases, even when treatment occurs in specialized centers (14,15). Nevertheless, there are many criticisms leveled at SPTX as, in most cases, all the parathyroid glands are found to be pathologic and it is difficult to establish which of them is less involved and can be preserved.

Furthermore, it can be difficult to preserve enough parathyroid tissue, particularly in the case of small glands. During this maneuver, the fine parathyroid vessels can easily be damaged, with consequent permanent hypoparathyroidism. In addition, surgery on these potentially pathologic glands could expose the patient to the risk of favoring the seeding of parathyroid cells into the nearest structures, thus favoring cervical recurrence of HPT (16).

All these considerations may explain the poor outcomes shown in several published studies, with high rates either of persistent and early recurrent HPT or of hypoparathyroidism (Table 1) (4,5,13–15,17–29).

Table 1 - Results after subtotal parathyroidectomy (SPTX) in multiple endocrine neoplasia type 1 (MEN1)-hyperparathyroidism (HPT).

Author	Year	Period	Pts	Mean follow-up (yrs)	Persistent HPT (%)	Recurrent HPT (%)	Hypoparathyroidism (%)
Edis et al. (23)	1979	1959–76	55	3.9	13	0	35
Prinz et al. (24)	1981	1955–76	12	9.5	33	0	25
Van Heerden et al. (25)	1983	1960–83	45	N.A.	6.6	6.6	13
Goretzki et al. (26)	1991	1986–90	18	N.A.	11	0	0
Hellman et al. (17)	1992	1982–91	11	11.9	0	27.3	27.3
Kraimps et al. (5)	1992	1966–88	14	8	14	36	10
O’ Riordain et al. (15)	1993	1970–91	54	10	0	16.4*	8
Janson et al. (18)	1994	1971–92	4	9.9	0	25	0
Thompson et al. (27)	1994	1972–92	14	20	7	7	0
Grant et al. (28)	1994	1980–93	15	4.7	0	13.3	0
Nilsson et al. (19)	1994	1971–92	2	9	0	0	0
Hellman et al. (20)	1998	1969–96	9	7.3	22	44	0
Goudet et al. (14)	2001	1986–97	73	N.A.	16.8	N.A.	N.A.
Dotzenrath et al. (21)	2001	1986–98	25	10	N.A.	8*	12
Arnalsteen et al. (4)	2002	1992–01	66	10	N.A.	33*	12.7
Elaraj et al. (22)	2003	1960–02	63	10	N.A.	51*	26
Hubbard et al. (29)	2006	1974–02	21	5	0	5	10
Norton et al. (13)	2008	1970–05	41	7.9	12	44	10

*Actuarial estimation.
N.A. = not applicable.

Table 2 - Results after total parathyroidectomy (TPTX) in multiple endocrine neoplasia type 1 (MEN1)-hyperparathyroidism (HPT).

Author	Year	Period	Pts	Mean follow-up (yrs)	Persistent HPT (%)	Recurrent HPT (%)	Hypoparathyroidism (%)
Wells et al. (31)	1980	1973–80	36	7	3	30	5.6
Malmæus et al. (36)	1986	1961–85	18	6.5	0	0	26
Hellman et al. (17)	1992	1982–91	23	6.1	0	22	30
Janson et al. (18)	1994	1971–92	6	9.9	0	0	0
Dralle et al. (35)	1994	1976–92	4	6.3	0	0	50
Nilsson et al. (19)	1994	1971–92	6	9	0	0	0
Hellmann et al. (20)	1998	1969–96	15	10.2	0	20	47
Elaraj et al. (22)	2003	1960–02	16	10	N.A.	16*	46
Hubbard et al. (29)	2006	1974–02	4	14	0	0	25
Norton et al. (13)	2008	1970–05	9	9.9	0	55	22
Tonelli et al. (6)	2007	1990–06	45	6.5	0	11	22

*Actuarial estimation.
N.A. = not applicable.

Total parathyroidectomy (TPTX). TPTX consists of total parathyroidectomy with transcervical thymectomy and autologous transplantation of parathyroid tissue. The aim of this technique is to radically remove all the parathyroid tissue, including the occult gland potentially present within the thymus and the surrounding fatty tissues, to avoid cervical recurrences that are difficult to treat, and to reduce the risk of permanent hypoparathyroidism by means of a graft, usually in the nondominant forearm.

The graft can be obtained at the end of surgery from fresh autologous tissue preserved at 4°C in Ringer lactate solution or days later (once it has been ascertained that the HPT has been cured) using cryopreserved tissue, using the technique described by Sonoda et al. (30) and Wells et al. (31). The tissue to graft should be chosen from the gland that appears most normal in volume, colour, and texture after analysis of frozen sections. The graft fragments should be the smallest possible (around 1 mm³) to facilitate the graft implant (32). The optimal grafting site is generally the brachio-radialis muscle of the nondominant forearm. This procedure will allow monitoring of the success of the autotransplantation through bilateral blood sampling from each basilic vein for measurement of PTH levels. After incision of the fascia of the brachio-radialis muscle, its fibers are bluntly divided in order to create small spaces in which to embed 2–3 fragments of parathyroid tissue. The fascia is then sutured with nonabsorbable wires to mark the site. The number of fragments that should be grafted is

Table 3 - Intraoperative parathyroid hormone (PTH) monitoring for prediction of multi-glandular parathyroid disease after removal of the first pathological parathyroid gland.

Author	Decrease of intra-operative PTH from baseline	False positive percentage*
Clerici et al. (44)	>50% at 10'	75%
Jaskowiak et al. (45)	>50% at 10'	50%
Kivlen et al. (43)†	>50% at 10'	14%
Arnalsteen et al. (4)†	>50% at 5'	5%
Thompson et al. (46)	>70% at 20'	0%

*Decrease below the cut-off point in the presence of other enlarged gland/s.

†Patients with MEN1 only.

still under debate, with various recommendations in the medical literature. Commonly 20–25 fragments (or more in the case of cryopreserved tissue) are considered the optimal number (33). Other series report 5–10 transplanted fragments (23,24), but with higher rates (50–60%) of nonworking grafts, either with fresh or cryopreserved parathyroid tissue (Table 2) (13,17–20,22,28–30,33,35,36). It is still unclear whether the success rate is associated with the technical procedure or with the parathyroid histopathology.

Interestingly, in the study by Janson and Tisell, no permanent hypoparathyroidism was seen and rapid parathyroid function restoration was observed after grafting parathyroid tissue within the abdominal subcutaneous fat in seven patients with MEN1 (18). In the past few years our center has moved towards implantation of eight fresh fragments instead of more than 12. This choice did not increase the number of cases of permanent hypoparathyroidism. We also implanted the autograft in the subcutaneous tissue of the nondominant forearm with the same optimal results. These data support the importance of local factors (i.e. angiogenesis) for the successful implantation of the graft (Table 2) (13,17–20,22,28,30,35,36).

Cause of failure of treatment of MEN1-HPT

Unsuccessful surgical treatment of HPT is more frequently observed in MEN1 than in sporadic HPT. Persistent hypoparathyroidism seems to be more frequent after SPTX than after TPTX (9% vs. 0.03%), and the cause may be related to hyperfunctioning parathyroid tissue in the portion of the gland preserved during SPTX. Conversely, recurrent hyperparathyroidism has a similar percentage in the two surgical strategies (18.6% vs. 18.5%); it is strongly dependent on the length of follow-up, and the cause may be related to the hyperfunctioning of the tissue if an excessive amount has been left in place after SPTX, or to the presence of supernumerary glands in cases treated with TPTX. There is no evidence in the literature of persistent or recurrent HPT/MEN1 cases caused by parathyreomatosis, although such cases have been reported in sporadic primary HPT (1–2%) and secondary HPT (12%) (37–39).

The recurrence rate is strongly influenced by:

1. Pre-operative diagnosis of MEN 1 significantly reduces the rate of surgical failures (5,40) and pre-operative

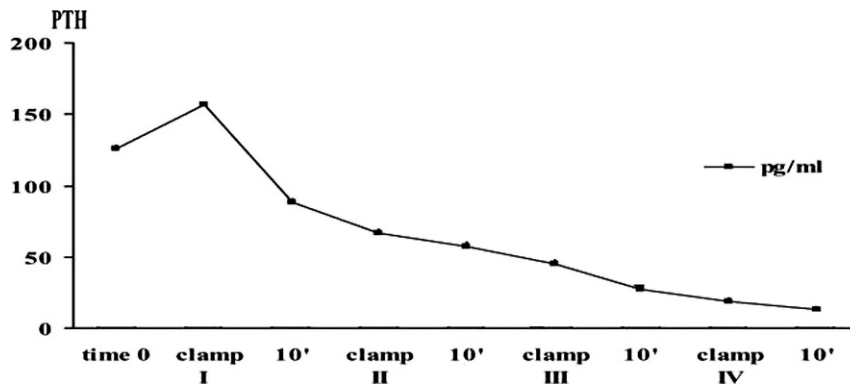


Figure 1 - Blood sampling after the removal of each parathyroid gland until the parathyroid hormone (PTH) values are practically undetectable in patients with HPT/MEN1 (6).

detection of a *MEN1* gene mutation is essential when the clinical history is suggestive of MEN1.

2. HPT/MEN1 persistence rates correlate with the experience of the surgeon, being significantly lower for surgeons working centers with high referral rates of HPT (17).

3. The optimal timing of surgery in asymptomatic cases with mild hypercalcemia is still debated. In fact, postponing surgery for some patients with MEN1 may increase the chances of identifying all the involved parathyroid glands, as over time, they become enlarged, making surgery easier and more effective.

4. Intra-operative histologic examination is useful to confirm the presence of parathyroid tissue in the specimen, especially in doubtful cases when ectopic glands are found. Histologic confirmation may be of value when grafting fresh parathyroid tissue is programmed, making it possible to avoid grafting of fragments of tissue with pathologic histologic features.

5. Rapid intra-operative PTH measurement has become important in clinical practice to guide the surgery (41,42). Its sensitivity is reported as nearly 95% in surgical treatment of sporadic adenoma (4,42,43). When used for the discrimination of HPT caused by hyperplasia or multiglandular disease, the rapid intra-operative PTH assay has shown substantially lower reliability, with a high rate of false positive values (43–45), probably due to the presence of glands suppressed (even if potentially neoplastic) by the most pathologic one. In fact, 10 minutes after removal of the first pathologic gland, PTH values can decrease by more than 50% from baseline. Using other criteria, such as evaluation after 20 minutes and a cut-off of 70%, Thompson et al. did not observe any false positive cases (Table 3) (46). In our opinion, the main role of intra-operative PTH should be to confirm removal of all the parathyroid tissue, so that the search for other parathyroid glands can be stopped and the graft of fresh parathyroid tissue performed. In our experience, stepwise venous sampling after the removal of each parathyroid gland until the PTH values are almost undetectable (i.e. near to the sensitivity limit of the PTH assay used) is a reliable method to confirm effective parathyroidectomy and to indicate that parathyroid autotransplantation can proceed (Figure 1) (6).

Treatment of persistent and recurrent MEN1-HPT

To plan further operations, it is very helpful to have all the available data regarding previous surgery and to undertake an accurate localization of the site of recurrence.

If a forearm graft is present, circulating PTH levels should be monitored after arm ischemia for 30 minutes produced by a tourniquet, in order to establish if such values decrease until they become undetectable (47). Re-operation is characterized by a substantial risk of inferior laryngeal nerve injury; therefore, it is indicated only when the recurrence is symptomatic, with high urinary calcium loss and significant bone mass reduction.

In the case of cervical or mediastinal recurrence, the surgical option is to remove the entire residual parathyroid tissue and then to perform heterotopic autologous transplantation. This technique carries a low risk of persistent HPT.

After TPTX with autograft, recurrence rates of 38% and 36%, respectively, were reported by Helmann et al. (20) and Kivlen et al. (43). However, TPTX without autograft is a possible choice for these patients after adequate informed consent, as they will need lifelong substitutive therapy with calcium and vitamin D.

If recurrence is diagnosed at the graft site, the removal of transplanted tissue is the treatment of choice, even if the best results cannot be always achieved; a 42% cure rate was reported by Kivlen et al. (43).

Recently, a pharmacologic approach was proposed for the cure of sporadic primary or secondary HPT, with the introduction of calcimimetics, a new class of drugs with the property of reducing PTH release (48,49). The efficacy of these molecules in HPT/MEN1, and particularly in its recurrence, needs to be proven through further studies and longer follow-up.

AUTHOR CONTRIBUTIONS

Tonelli F is the principal author of the discussion about the best surgical approach for MEN1 patients. He operated and followed the clinical course of MEN1 patients affected by hyperparathyroidism treated in our Centre. Giudici F has reviewed literature, analyzing the differences between different types of surgery in patients with hyperparathyroidism in MEN1 in terms of results and complications. Cavalli T has reviewed the literature on this subject and has contributed to the drafting of the article. Brandi ML has reviewed literature, contributing to the Article and the accuracy of the English language; she carried out the clinical and metabolic follow up of all the patients operated in our Centre.

REFERENCES

- Marx SJ, Simonds WF, Agarwal SK, Burns AL, Weinstein LS, Cochran C, et al. Hyperparathyroidism in hereditary syndromes: special expression and special managements. *J Bone Miner Res.* 2002;17(Suppl 2):37-43.
- Brandi ML, Gagel RF, Angeli A, Bilezikian JP, Beck-Peccoz P, Bordi C, et al. Guidelines for diagnosis and therapy of MEN type1 and type2.

- J Clin Endocrinol Metab. 2001;86(12):5658-71, <http://dx.doi.org/10.1210/jc.86.12.5658>.
3. Marx SJ, Mencil J, Campbell, Aurbach GD, Spiegel AM, Norton JA. Heterogeneous size of the parathyroid glands in familial multiple endocrine neoplasia type 1. Clin Endocrinol. 1991;35(6):521-6, <http://dx.doi.org/10.1111/j.1365-2265.1991.tb00938.x>.
 4. Arnalsteen LC, Alesina PF, Quireux JL, Farrel SG, Patton FN, Carnaille BM, et al. Long-term results of less than total parathyroidectomy for hyperparathyroidism in multiple endocrine neoplasia type 1. Surgery. 2002;132(6):1119-25, <http://dx.doi.org/10.1067/msy.2002.128607>.
 5. Kraimps JL, Quan-Yang Duh, Demeure M, Clark OH. Hyperparathyroidism in multiple endocrine neoplasia syndrome. Surgery. 1992;112(6):1080-8.
 6. Tonelli F, Marcucci T, Fratini G, Tommasi MS, Falchetti A, Brandi ML. Is total parathyroidectomy the treatment of choice for hyperparathyroidism in multiple endocrine neoplasia type 1? Ann Surg. 2007;246(6):1075-82, <http://dx.doi.org/10.1097/SLA.0b013e31811f4467>.
 7. Henry JF, Defechereux T, Raffaelli M, Lubrano D, Iacobone M. Supernumerary ectopic hyperfunctioning parathyroid gland: a potential pitfall in surgery for sporadic primary hyperparathyroidism. Ann Chir. 2000;125(3):247-52, [http://dx.doi.org/10.1016/S0003-3944\(00\)00247-9](http://dx.doi.org/10.1016/S0003-3944(00)00247-9).
 8. Wang CA. The anatomic basis of parathyroid surgery. Ann Surg. 1976;183(3):271-5.
 9. Akerstrom G, Malmaeus J, Bergstrom R. Surgical anatomy of human parathyroid glands. Surgery. 1984;95(1):14-21.
 10. Aly A, Douglas M. Embryonic parathyroid rests occur commonly and have implications in the management of secondary hyperparathyroidism. ANZ J Surg. 2003;73(5):284-8, <http://dx.doi.org/10.1046/j.1445-2197.2003.t011-1-02620.x>.
 11. Kollmorgen CF, Aust MR, Ferreira JA, McCarthy JT, van Heerden JA. Parathyromatosis: a rare yet important cause of persistent or recurrent hyperparathyroidism. Surgery. 1994;116(1):111-5.
 12. Burgess JR, David R, Greenaway TM, Parameswaran V, Shepherd JJ. Osteoporosis in multiple endocrine neoplasia type 1. Arch Surg. 1999;134(10):1119-23, <http://dx.doi.org/10.1001/archsurg.134.10.1119>.
 13. Norton JA, Venzon DJ, Berna MJ, Alexander HR, Fraker DL, Libutti SK, et al. Prospective study of surgery for primary hyperparathyroidism (HPT) in multiple endocrine neoplasia-type 1 and Zollinger-Ellison syndrome: long-term outcome of a more virulent form of HPT. Ann Surg. 2008;247(3):501-10, <http://dx.doi.org/10.1097/SLA.0b013e31815efda5>.
 14. Goudet P, Cougard P, Vergès B, Murat A, Carnaille B, Calender A, et al. Hyperparathyroidism in multiple endocrine neoplasia type I: surgical trends and results of a 256-patient series from groupe d'étude des néoplasies endocriniennes multiples study group. World J Surg. 2001;25(7):886-90, <http://dx.doi.org/10.1007/s00268-001-0046-z>.
 15. O'Riordain DS, O'Brian T, Grant CS, Weaver A, Gharib H, van Heerden JA. Surgical management of primary hyperparathyroidism in multiple endocrine neoplasia type 1 and 2. Surgery. 1993;114(6):1031-9.
 16. Sokol MS, Kavolius J, Schaaf M, D'Aviz J. Recurrent hyperparathyroidism from benign neoplastic seeding: A review with recommendations for management. Surgery. 1993;113(4):456-61.
 17. Hellman P, Skogseid B, Juhlin C, Akerström G, Rastad J. Findings and long-term results of parathyroid surgery in multiple endocrine neoplasia type 1. World J Surg. 1992;16(4):718-25, <http://dx.doi.org/10.1007/BF02067367>.
 18. Janson S, Tisell LE. Total parathyroidectomy and parathyroid transplantation into subcutaneous fat tissue in the treatment of hyperparathyroidism in multiple endocrine neoplasia type 1. Acta Chir Austriaca. 1994;26 (Suppl.112):23-6.
 19. Nilsson O, Ahlman H, Tisell LE. Autotransplantation of parathyroid tissue into subcutaneous fat in the treatment of hyperparathyroidism in MEN-1. Abstracts of the Fifth International Workshop on multiple endocrine neoplasia. Stockholm Archipelago, Sweden, June 29-July 2, 1994.
 20. Hellmann P, Skogseid B, Oberg K, Juhlin C, Akerström G, Rastad J. Primary and reoperative parathyroid operations in hyperparathyroidism of multiple endocrine neoplasia type 1. Surgery. 1998;124(6):993-9, [http://dx.doi.org/10.1016/S0039-6060\(98\)70040-6](http://dx.doi.org/10.1016/S0039-6060(98)70040-6).
 21. Dotzenrath C, Cupisti K, Goretzki PE, Yang Q, Simon D, Ohmann C, et al. Long-term biochemical results after operative treatment of primary hyperparathyroidism associated with multiple endocrine neoplasia types I and IIa: is a more or less extended operation essential? Eur J Surg. 2001;167(3):173-78, <http://dx.doi.org/10.1080/110241501750099294>.
 22. Elaraj DM, Skarulis MC, Libutti SK, Norton JA, Bartlett DL, Pingpank JF, et al. Results of initial operation for hyperparathyroidism in patients with multiple endocrine neoplasia type 1. Surgery. 2003;134(6):858-65, [http://dx.doi.org/10.1016/S0039-6060\(03\)00406-9](http://dx.doi.org/10.1016/S0039-6060(03)00406-9).
 23. Edis AJ, Van Heerden JA, Scholz DA. Results of sub-total parathyroidectomy for primary chief cell hyperplasia. Surgery. 1979;86:462-9.
 24. Prinz RA, Gamvros OP, Sellu D, Lynn JA. Subtotal parathyroidectomy for primary chief cell hyperplasia of the multiple endocrine neoplasia type 1 syndrome. Surgery. 1981;193(1):26-9.
 25. Van Heerden JA, Kent RB, Sizemore GW, Grant CS, ReMine WH. Primary hyperparathyroidism in patients with multiple endocrine neoplasia syndromes. Surgical experience. Arch. Surg. 1983;118(5):533-6.
 26. Goretzki PE, Dotzenrath C, Roehrer HD. Management of primary hyperparathyroidism caused by multiglandular disease. World J Surg. 1991;15(6):693-7, <http://dx.doi.org/10.1007/BF01665302>.
 27. Thompson NW, Sandelin K. Technical considerations in the surgical management of primary hyperparathyroidism caused by multiple gland disease (hyperplasia). Acta Chir. Austriaca. 1994;26(Suppl. 112):16-9.
 28. Grant CS, Weaver A. Treatment of primary parathyroid hyperplasia: representative experience at Mayo Clinic. Acta Chir. Austriaca. 1994;26 (Suppl. 112):41-4.
 29. Hubbard JGH, Sebag F, Maweja S, Henry JF. Subtotal parathyroidectomy as an adequate treatment for primary hyperparathyroidism in multiple endocrine neoplasia type 1. Arch Surg. 2006;141(3):235-9, <http://dx.doi.org/10.1001/archsurg.141.3.235>.
 30. Sonoda T, Ohkawa T, Takeuchi M, Yachiku S. Successful parathyroid preservation: experimental study. Surgery. 1968;64(4):791-5.
 31. Wells SA Jr, Farndon JR, Dale JK, Leight GS, Dille WG. Long term evaluation of patients with primary parathyroid hyperplasia managed by total parathyroidectomy and heterotopic autotransplantation. Ann Surg. 1980;192(4):451-8, <http://dx.doi.org/10.1097/00000658-198010000-00003>.
 32. Wagner PK, Seesko HG, Rothmund M. Replantation of cryopreserved human parathyroid tissue. World J Surg. 1991;15(6):751-5, <http://dx.doi.org/10.1007/BF01665310>.
 33. Feldman AL, Sharaf RN, Skarulis MC, Bartlett DL, Libutti SK, Weinstein LS, et al. Results of heterotopic parathyroid autotransplantation: a 13-year experience. Surgery. 1999;126:1042-48, <http://dx.doi.org/10.1067/msy.2099.101580>.
 34. Barnett HF, Thompson BW, Barbour GL. Parathyroid autotransplantation. Arch Surg. 1977;112(4):373-9, <http://dx.doi.org/10.1001/archsurg.1977.01370040025004>.
 35. Dralle H, Sheuermann GFW. How to handle the parathyroid glands in multiple endocrine neoplasia type 1 (MEN-1) and type 2 (MEN-2)? Surgical approach to uniglandular vs multiglandular disease in hereditary primary hyperparathyroidism. Acta Chir Austriaca. 1994;26 (Suppl. 112):35-8.
 36. Malmaeus J, Benson L, Johansson H, Ljunghall S, Rastad J, Akerström G, et al. Parathyroid surgery in the multiple endocrine neoplasia type 1 syndrome: choice of surgical procedure. World J Surg. 1986;10(4):668-72, <http://dx.doi.org/10.1007/BF01655552>.
 37. Arnalsteen L, Quievreux JL, Huglo D, Pattou F, Carnaille B, Proye C. Reoperation for persistent or recurrent primary hyperparathyroidism. Seventy-seven cases among 1888 operated patients. Ann Chir. 2004;129(4):224-31.
 38. Mariette C, Pellissier L, Combemale F, Quievreux JL, Carnaille B, Proye C. Reoperation for persistent or recurrent primary hyperparathyroidism. Langenbecks Arch Surg. 1998;383(2):174-9.
 39. Matsuoka S, Tominaga Y, Sato T, Uno N, Goto N, Katayama A, Uchida K, et al. Recurrent renal hyperparathyroidism caused by parathyromatosis. World J Surg. 2007;31(2):299-305, <http://dx.doi.org/10.1007/s00268-006-0391-z>.
 40. Metz DC, Jensen RT, Bale A, Skarulis MC, Eastman RC, Nieman L, et al. Multiple endocrine neoplasia type 1. In: Bilezikian JP, Marcus R, Levine MA. The parathyroids. Basic and clinical concepts. New York: Raven Press; 1994.pp.591-646.
 41. Tonelli F, Amorosi A, Tommasi MS, et al. Fisiopatologia e diagnosi dell'iperparatiroidismo. Atti 92° Congr. SIC; Roma, 21-25 ottobre 1990; Luigi Pozzi srl ed. Roma.
 42. Tonelli F, Spini S, Tommasi M, Gabbriellini G, Amorosi A, Brocchi A, et al. Intraoperative parathormone measurement in patients with multiple endocrine neoplasia type 1 syndrome and hyperparathyroidism. World J Surg. 2000;24(5):556-63, <http://dx.doi.org/10.1007/s002689910091>.
 43. Kivlen MH, Bartlett DL, Libutti SK, Skarulis MC, Marx SJ, Simonds WF, et al. Reoperation for hyperparathyroidism in multiple endocrine neoplasia type 1. Surgery. 2001;130(6):991-8, <http://dx.doi.org/10.1067/msy.2001.118379>.
 44. Clerici T, Brandle M, Lange J, Doherty GM, Gauger PG. Impact of intraoperative parathyroid hormone monitoring on the prediction of multiglandular parathyroid disease. World J Surg. 2004;28(2):187-92, <http://dx.doi.org/10.1007/s00268-003-7255-6>.
 45. Jaskowiak NT, Sugg SL, Helke J, Koka MR, Kaplan EL. Pitfalls of intraoperative rapid parathyroid hormone monitoring and gamma probe localization in surgery for primary hyperparathyroidism. Arch Surg. 2002;137(6):659-68, <http://dx.doi.org/10.1001/archsurg.137.6.659>.
 46. Thompson GB, Grant CS, Perrier ND, Harman R, Hodgson SF, Ilstrup D, et al. Reoperative parathyroid surgery in the era of sestamibi scanning and intraoperative parathyroid hormone monitoring. Arch Surg. 1999;134(7):699-705, <http://dx.doi.org/10.1001/archsurg.134.7.699>.
 47. Knudsen L, Brandi L, Daugaard H, Olgaard K, Lockwood K. Five to 19 years follow-up after total parathyroidectomy and autotransplantation of

- parathyroid tissue: evaluation of parathyroid function by use of ischaemic blockade manoeuvre. *Scand J Clin Invest.* 1996;56(1):47-50, <http://dx.doi.org/10.3109/00365519609088587>.
48. Silverberg SJ, Bone HG 3rd, Marriott TB, Locker FG, Thys-Jacobs S, Dziem Get al. Short-term inhibition of parathyroid hormone secretion by a calcium-receptor agonist in patients with primary hyperparathyroidism. *N Engl J Med.* 1997;337(21):1506-10, <http://dx.doi.org/10.1056/NEJM199711203372104>.
49. Block GA, Martin KJ, de Francisco AL, Turner SA, Avram MM, Suranyi MG, et al. Cinacalcet for secondary hyperparathyroidism in patients receiving hemodialysis. *N Engl J Med.* 2004;350(15):1516-25, <http://dx.doi.org/10.1056/NEJMoa031633>.