

REVIEW

Post-surgical follow-up of primary hyperparathyroidism associated with multiple endocrine neoplasia type 1

Flavia L. Coutinho,¹ Delmar M. Lourenco Jr.,¹ Rodrigo A. Toledo,¹ Fabio L. M. Montenegro,^{II} Sergio P. A. Toledo¹

¹Endocrine Genetics Unit (LIM-25), Endocrinology Division, Hospital das Clínicas da Faculdade de Medicina da Universidade de São Paulo. ^{II}Head and Neck Surgery Department, Hospital das Clínicas da Faculdade de Medicina da Universidade de São Paulo.

The bone mineral density increments in patients with sporadic primary hyperparathyroidism after parathyroidectomy have been studied by several investigators, but few have investigated this topic in primary hyperparathyroidism associated with multiple endocrine neoplasia type 1. Further, as far as we know, only two studies have consistently evaluated bone mineral density values after parathyroidectomy in cases of primary hyperparathyroidism associated with multiple endocrine neoplasia type 1. Here we revised the impact of parathyroidectomy (particularly total parathyroidectomy followed by autologous parathyroid implant into the forearm) on bone mineral density values in patients with primary hyperparathyroidism associated with multiple endocrine neoplasia type 1. Significant increases in bone mineral density in the lumbar spine and femoral neck values were found, although no short-term (15 months) improvement in bone mineral density at the proximal third of the distal radius was observed. Additionally, short-term and medium-term calcium and parathyroid hormone values after parathyroidectomy in patients with primary hyperparathyroidism associated with multiple endocrine neoplasia type 1 are discussed. In most cases, this surgical approach was able to restore normal calcium/parathyroid hormone levels and ultimately lead to discontinuation of calcium and calcitriol supplementation.

KEYWORDS: Primary Hyperparathyroidism; MEN1; Bone Mineral Density; Parathyroid Hormone; Total Parathyroidectomy.

Coutinho FL, Lourenco DM Jr, Toledo RA, Montenegro FL, Toledo SPA. Post-surgical follow-up of primary hyperparathyroidism associated with multiple endocrine neoplasia type 1. Clinics. 2012;67(S1):169-172.

E-mail: flacoutinho07@yahoo.com.br

Tel.: 55 11 3061 7252

INTRODUCTION

Primary hyperparathyroidism (HPT) is a common endocrine disorder, affecting 0.3% of the general population and 1–3% of postmenopausal women (1). It is characterized by hypercalcemia and elevated or inappropriately normal levels of parathyroid hormone (PTH). Most patients (80–95%) present with the sporadic form of the disease (s-HPT), whereas familial cases may be associated with multiple endocrine neoplasia type 1 (MEN1) and MEN type 2, jaw tumor syndrome, neonatal severe primary HPT, and familial isolated HPT (2–4). HPT disease associated with MEN1 (HPT/MEN1) differs in many aspects from s-HPT, including its clinical, pathological, and genetic characteristics, and it is therefore treated with different surgical protocols, and exhibits different cure rates and outcomes (2,5,6). In contrast to s-HPT, HPT/MEN1 presents as a

multiglandular parathyroid neoplasia (hyperplasia versus adenoma), has an earlier disease onset (20 versus 40 years of age), has a higher recurrence rate after parathyroidectomy (PTX), and is often less aggressive (2,5,7). A potentially more virulent form of HPT has also been reported in association with Zollinger–Ellison syndrome (8). We have found an increase in the frequency of HPT/MEN1 in recent years, since familial genetic screening for the *MEN1* gene was introduced into routine use in our hospital (9–11).

PTX IN HPT/MEN1

Instead of adenomectomy, the procedure recommended for s-HPT, two basic surgical procedures have been performed for the treatment of patients with HPT/MEN1: subtotal partial parathyroidectomy (SPTX) and total parathyroidectomy (TPTX). SPTX consists of the removal of at least 3–3.5 glands, leaving a normal parathyroid remnant of 20–30 mg, whereas TPTX consists of the removal of all four glands followed by autologous heterotopic implant of parathyroid tissue in the muscles of the non-dominant forearm (8,12–16). Ultimately, in the hands of skilled surgeons, both methods have been reported to achieve

Copyright © 2012 CLINICS – This is an Open Access article distributed under the terms of the Creative Commons Attribution Non-Commercial License (<http://creativecommons.org/licenses/by-nc/3.0/>) which permits unrestricted non-commercial use, distribution, and reproduction in any medium, provided the original work is properly cited.

No potential conflict of interest was reported.

euparathyroidism, maintaining correct PTH secretion and calcium metabolism, and preventing clinical complications.

BONE MINERAL DENSITY IN HPT/MEN1

Very few data on bone status in patients with HPT/MEN1 are available in the literature, which limits comparisons. Burgess et al. documented high rates of early and severe bone mineral loss in the femoral neck (FN) and lumbar spine (LS) of 29 women in a large MEN1 family from Tasmania (17). Of note, the authors used analysis of the bone mineral density (BMD) to evaluate bone status in the studied cases.

Similarly, in 2008, we confirmed the same demineralization pattern in affected cases from an extended MEN1 family harboring a founding *MEN1* germline heterozygous mutation. We also identified the proximal one-third of the distal radius (1/3 DR) as an early and severely compromised bone site in this MEN1 family (18). Patients with MEN1-related HPT usually have severe bone and kidney involvement despite a milder biochemical presentation compared with their s-HPT counterparts (19).

In 2010, our preliminary findings were confirmed in a larger series of HPT/MEN1 cases that we were able to study. In this latter investigation, we found that urolithiasis occurred early (<30 years) and frequently (75%) and that it was usually associated with kidney-related co-morbidities (50%), as well as with renal insufficiency in the older group (>50 years) (33%). We also verified that bone mineral-related and urolithiasis-related renal complications in HPT/MEN1 were of early onset, frequent, extensive, severe, and progressive (20). Notably, the trabecular bone mineral content in the studied cases was not protected, in contrast to the previously reported trend in s-HPT (21-25). Furthermore, it was recently suggested that the *Menin* protein, coded by the *MEN1* gene, may interfere in osteoblast differentiation (26-28), and may also have a direct demineralizing effect on trabecular bone in animal models (29).

The impact of PTX in s-HPT has been widely studied, and significant short-term bone mineral recovery of the LS and FN has been documented (22,30,31). Conversely, 1/3 DR BMD was previously thought to have no marked recovery one year after PTX (31), whereas long-term mineral recovery of the LS, FN and also 1/3 DR has been documented (22,25,30-33).

BMD AFTER PTX IN HPT/MEN1

Data on bone mineral recovery after PTX in the specific subset of patients with HPT/MEN1 have been published in only two papers so far (17,34).

Data from Burgess et al.

This first study addressed the LS and FN BMD before and after PTX in five women with HPT/MEN1. In this limited number of patients, significant recovery of BMD was seen in the femoral neck ($3.2 \pm 2.9\%$) and lumbar spine ($5.2 \pm 2.5\%$) after PTX (17).

Our data

We assessed the BMD changes in 16 patients with HPT/MEN1 11 years after total PTX followed by autologous parathyroid implant in the forearm, using dual-energy

X-ray absorptiometry (DXA, Hologic QDR-4500 S/N 45130, Waltham, MA) (34). Significant improvements in BMD were verified in all cases 15 months after PTX at both the LS and FN, but not at 1/3 DR. Hence, 15 months after PTX, the LS values increased from 0.843 to 0.909 g/cm², with a BMD increase of $+8.4 \pm 9.84\%$ ($p=0.001$). The FN values rose from 0.745 to 0.798 g/cm², and BMD increased by $+6.9 \pm 3.17\%$ ($p=0.0001$). Conversely, no significant changes were seen in the 1/3 DR BMD values 15 months after PTX (34).

It was noted that pre-surgical bone mineral mass was already compromised in the 16 patients with HPT/MEN1. Hence, there was a high prevalence of reduced BMD (Z-score < -2.0) for the 1/3 DR (50%), LS (43.7%), ultradistal radius (UDR; 43.7%), FN (25%), and total femur (TF) (18.7%) in these cases.

BMD DATA IN s-HPT and HPT/MEN1

The BMD values after PTX in our study were between those reported by Burgess et al. (17) in HPT/MEN1 cases, and those seen in s-HPT (32). Furthermore, in contrast to the short-term and long-term 1/3 DR BMD recovery reported by Rubin et al. (32) in cases with s-HPT, we could not document significant change in 1/3 DR BMD ($-0.6 \pm 15.73\%$) during follow-up of our cases (Table 1). These data indicate a trend for potential differences in BMD recovery after surgery in patients with HPT/MEN1 compared with patients with s-HPT.

PTH AND CALCIUM AFTER PTX IN HPT/MEN1

In this study, immediately after PTX, all cases presented transient signals and symptoms of hypocalcemia, associated with low serum calcium and PTH values. Therapy with oral calcium (~2-3 g/day) and calcitriol (~1 µg/day) supplements was instituted in all cases to achieve normal calcemia. This treatment was maintained for 4-5 months (with an average time of 8.3 months), although progressively lower therapeutic doses were needed over this time. The post-surgical pattern of increasing serum levels of PTH secreted by the parathyroid implant is shown in Figure 1. A slow biochemical (calcium, PTH) recovery after successful total PTX followed by autologous parathyroid implantation was verified in this series of patients. Fully viable parathyroid

Table 1 - Mean percentage change in bone mineral density at three sites in patients with hyperparathyroidism associated with multiple endocrine neoplasia type 1 (HPT/MEN1) and those with sporadic HPT, after parathyroidectomy.

	Burgess (17) (HPT/MEN1)	Coutinho (34) (HPT/MEN1)	Rubin (32) (s-HPT)
LS (%)	5.2	8.4	9
FN (%)	3.2	6.9	5
1/3 DR (%)	NA	-0.6	4
Post-surgical mean time (months)	18	15	12

LS, lumbar spine; FN, femoral neck; 1/3 DR, distal third of radius; NA, data not evaluated.

In all cases studied by Coutinho et al. (34) total parathyroidectomy was followed by autologous parathyroid implant, and bone mineral density values were assessed using dual-energy X-ray absorptiometry (Hologic apparatus).

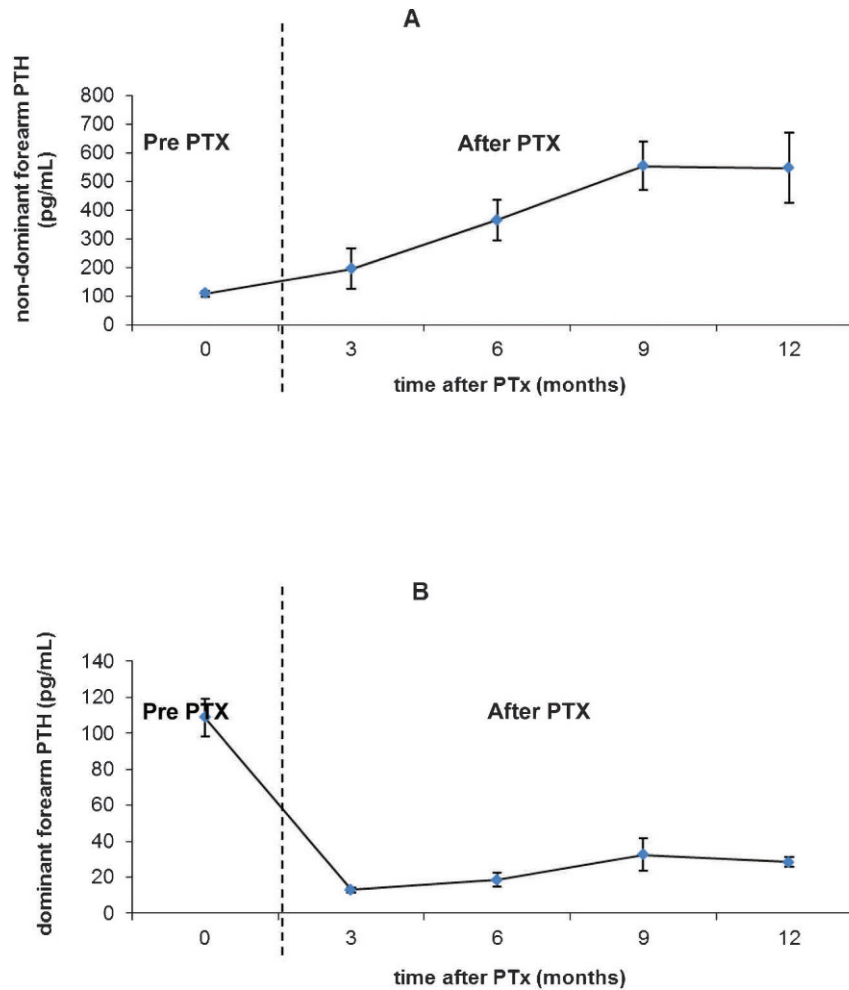


Figure 1 - Mean serum levels of parathyroid hormone (PTH; mean \pm SEM) before and after total parathyroidectomy (PTX) followed by autologous parathyroid implant in the non-dominant forearm in 16 cases of hyperparathyroidism associated with multiple endocrine neoplasia type 1. Serum samples were collected from both non-dominant (A) and dominant (B) forearms. These data are based on those of Coutinho et al. (34).

implants with consistent mean PTH secretion values (32.6 ± 9.1 ng/ml) were obtained 9 months after PTX (34).

Based on these data, we conclude that in patients with HPT/MEN1, bone demineralization is an important complication and should be routinely evaluated before PTX, and patients should be followed up for several years. Calcium and calcitriol supplementation is frequently needed for several months after PTX until efficient function of the autologous parathyroid implant is achieved.

In conclusion, in our experience there is a marked short-term improvement in BMD at the LS and FN in most patients with HPT/MEN1 after total PTX followed by autologous parathyroid implant into the forearm, although BMD at the 1/3 DR may take longer to recover (>18 months) after surgery. Hence, LS and FN BMDs are the better sites to investigate BMD after PTX in patients with HPT/MEN1.

ACKNOWLEDGMENTS

FLC is the recipient of a CNPq doctorate fellowship (142603/2010-4), RAT is the recipient of a FAPESP post-doctorate fellowship (2009/15386-6), and SPAT is the recipient of a CNPq fellowship and grant (401990/2010-9).

AUTHOR CONTRIBUTIONS

Coutinho FL was responsible for the clinical assessment, data collection and analysis, and manuscript writing. Lourenco DM Jr is the doctor who contributed to the clinical assessment of patients with MEN1. Toledo RA is the biologist who performed the molecular diagnosis of patients in the study. Montenegro FL is the surgeon responsible for the surgical treatment of all patients in the study. Toledo SPA guided the study.

REFERENCES

- Lundgren E, Rastad J, Thurfjell E, Akerström G, Ljunghall S. Population-based screening for primary hyperparathyroidism with serum calcium and parathyroid hormone values in menopausal women. *Surgery*. 1997;121:287-94, [http://dx.doi.org/10.1016/S0039-6060\(97\)90357-3](http://dx.doi.org/10.1016/S0039-6060(97)90357-3).
- Marx SJ, Simonds WF, Agarwal SK, Burns AL, Weinstein LS, Cochran C, et al. Hyperparathyroidism in hereditary syndromes: special expression and special managements. *J Bone Miner Res*. 2002;17:37-43.
- Lemos MC, Thakker RV. Multiple endocrine neoplasia type 1 (MEN1): analysis of 1336 mutations reported in the first decade following identification of the gene. *Hum Mutat*. 2008;29:22-32, <http://dx.doi.org/10.1002/humu.20605>.
- Eastell R, Arnold A, Brandi ML, Brown EM, D'Amour P, Hanley DA., et al. Diagnosis of asymptomatic primary hyperparathyroidism: proceedings of the third international workshop. *J Clin Endocrinol Metab*. 2009;94:340-50, <http://dx.doi.org/10.1210/jc.2008-1758>.
- Katai M, Sakurai A, Ikeo Y, Hashizume K. Primary hyperparathyroidism in patients with multiple endocrine neoplasia type 1: comparison with

sporadic parathyroid adenomas. *Horm Metab Res.* 2001;33:499-503, <http://dx.doi.org/10.1055/s-2001-16944>.

6. Stalberg P, Carling T. familial parathyroid tumors: diagnosis and management. *World J Surg.* 2009;33:2234-43.
7. Bilezikian JP, Silverberg SJ. Clinical spectrum of primary hyperparathyroidism. *Rev Endocr Metab Disord.* 2000;1:237-45, <http://dx.doi.org/10.1023/A:1026508829397>.
8. Norton JA, Venzon DJ, Berna MJ, Alexander HR, Fraker DL, Libutti SK, et al. Prospective study of surgery for primary hyperparathyroidism (HPT) in multiple endocrine neoplasia-type 1 and Zollinger-Ellison syndrome: long-term outcome of a more virulent form of HPT. *Ann Surg.* 2008;247:501-10, <http://dx.doi.org/10.1097/SLA.0b013e31815efda5>.
9. Toledo RA, Lourenco DM, Coutinho FL, Quedas E, Mackowiack I, Machado MC, et al. Novel MEN1 germline mutations in Brazilian families with multiple endocrine neoplasia type 1. *Clin Endocrinol (Oxf).* 2007;67:377-84, <http://dx.doi.org/10.1111/j.1365-2265.2007.02895.x>.
10. Lourenço DM Jr, Toledo RA, Coutinho FL, Margarido LC, Siqueira SA, dos Santos MA, et al. The impact of clinical and genetic screenings on the management of the multiple endocrine neoplasia type 1. *Clinics.* 2007;62:465-76, <http://dx.doi.org/10.1590/S1807-59322007000400014>.
11. Costa MH, Domenice S, Toledo RA, Lourenço DM Jr, Latronico AC, Pinto EM, et al. Glucose-dependent insulinotropic peptide receptor overexpression in adrenocortical hyperplasia in MEN1 syndrome without loss of heterozygosity at the 11q13 locus. *Clinics.* 2011;66:529-33.
12. Thompson NW. The surgical management of hyperparathyroidism and endocrine disease of the pancreas in the multiple endocrine neoplasia Type 1 patient. *J Intern Med.* 1995;238:269-80, <http://dx.doi.org/10.1111/j.1365-2796.1995.tb00934.x>.
13. Brandi ML, Gagel RF, Angeli A, Bilezikian JP, Beck-Peccoz P, Bordi C, et al. Consensus: guidelines for diagnosis and therapy of MEN type 1 type 2. *J Clin Endocrinol Metab.* 2001;86:5658-71, <http://dx.doi.org/10.1210/jc.86.12.5658>.
14. Goudet P, Cougard P, Vergès B, Murat A, Carnaille B, Calender A, et al. Hyperparathyroidism in multiple endocrine neoplasia type I: surgical trends and results of a 256-patient series from Groupe d'Etude des Néoplasies Endocriniennes Multiples Study Group. *World J Surg.* 2001;25:886-90.
15. Carling T, Udelsman R. Parathyroid surgery in familial hyperparathyroid disorders. *J Intern Med.* 2005;257:27-37, <http://dx.doi.org/10.1111/j.1365-2796.2004.01428.x>.
16. Tonelli F, Marcucci T, Fratini G, Tommasi MS, Falchetti A, Brandi ML. Is total parathyroidectomy the treatment of choice for hyperparathyroidism in multiple endocrine neoplasia type 1? *Ann Surg.* 2007;246:1075-82, <http://dx.doi.org/10.1097/SLA.0b013e31811f4467>.
17. Burgess JR, David RB, Greenaway TM, Parameswaran V, Shepherd JJ. Osteoporosis in multiple endocrine neoplasia type 1: severity, clinical significance, relationship to primary hyperparathyroidism and response to parathyroidectomy. *Arch Surg.* 1999;134:1119-23, <http://dx.doi.org/10.1001/archsurg.134.10.1119>.
18. Lourenco DM Jr, Toledo RA, Mackowiack II, Coutinho FL, Cavalcanti MG, Correia-Deur JEM, et al. Multiple endocrine neoplasia type 1 in Brazil: MEN1 founding mutation, clinical features and bone mineral density profile. *Eur J Endocrinol.* 2008;159:259-74.
19. Eller-Vainicher C, Chiodini I, Battista C, Viti R, Mascia ML, Massironi S, et al. Sporadic and MEN1-related primary hyperparathyroidism: differences in clinical expression and severity. *J Bone Miner Res.* 2009;24:1404-10, <http://dx.doi.org/10.1359/jbmr.090304>.
20. Lourenço DM Jr, Coutinho FL, Toledo RA, Montenegro FL, Correia-Deur JE, Toledo SP. Early-onset, progressive, frequent, extensive, and severe bone mineral and renal complications in multiple endocrine neoplasia type 1-associated primary hyperparathyroidism. *J Bone Miner Res.* 2010;25:2382-91, <http://dx.doi.org/10.1002/jbmr.125>.
21. Parisien M, Silverberg SJ, Shane E, Cruz L, Lindsay R, Bilezikian JP, et al. The histomorphometry of bone in primary hyperparathyroidism: preservation of cancellous bone structure. *J Clin Endocrinol Metab.* 1990;70:930-38, <http://dx.doi.org/10.1210/jcem-70-4-930>.
22. Christiansen P, Steiniche T, Brixen K, Hessov I, Melsen F, Heickendorff L, et al. Primary hyperparathyroidism: short-term changes in bone remodeling and bone mineral density following parathyroidectomy. *Bone* 1999;25:237-44.
23. Silverberg SJ, Gartemberg F, Jacobs TP, Shane E, Siris E, Staron RB, et al. Increased bone mineral density after parathyroidectomy in primary hyperparathyroidism. *J Clin Endocrinol Metab.* 1995;80:729-34, <http://dx.doi.org/10.1210/jc.80.3.729>.
24. Dempster DW, Müller R, Zhou H, Kohler T, Shane E, Parisien M., et al. Preserved three-dimensional cancellous bone structure in mild primary hyperparathyroidism. *Bone* 2007;41:19-24.
25. Mosekilde L. Primary hyperparathyroidism and the skeleton. *Clin Endocrinol (Oxf).* 2008;69:1-19, <http://dx.doi.org/10.1111/j.1365-2265.2007.03162.x>.
26. Sowa H, Kaji H, Canaff L, Hendy GN, Tsukamoto T, Yamaguchi T, et al. Inactivation of Menin, the product of the multiple endocrine neoplasia type 1 gene, inhibits the commitment of multipotential mesenchymal stem cells into the osteoblast lineage. *J Biol Chem.* 2003;278:21058-69, <http://dx.doi.org/10.1074/jbc.M302044200>.
27. Sowa H, Kaji H, Hendy GN, Canaff L, Komori T, Sugimoto T, et al. Menin is required for bone morphogenetic protein 2 and transforming growth factor beta-regulated osteoblastic differentiation through interaction with Smads and Runx2. *J Biol Chem.* 2004;279:40267-75, <http://dx.doi.org/10.1074/jbc.M401312200>.
28. Naito J, Kaji H, Sowa H, Hendy GN, Sugimoto T, Chihara K. Menin suppresses osteoblast differentiation by antagonizing the AP-1 factor, JunD. *J Biol Chem.* 2005;280:4785-91, <http://dx.doi.org/10.1074/jbc.M408143200>.
29. Kawamata A, Izu Y, Yokoyama H, Amagasa T, Wagner EF, Nakashima K, et al. JunD suppresses bone formation and contributes to low bone mass induced by estrogen depletion. *J Cell Biochem.* 2008;103:1037-45.
30. Christiansen P, Steiniche T, Mosekilde L, Hessov I, Melsen F. Primary hyperparathyroidism: changes in trabecular bone remodeling following surgical treatment – evaluated by histomorphometric methods. *Bone* 1990;11:75-79.
31. Silverberg SJ, Shane E, Jacobs TP, Siris E, Bilezikian JP. A 10-year prospective study of primary hyperparathyroidism with and without parathyroid surgery. *N Engl J Med.* 1999;341:1249-55.
32. Rubin MR, Bilezikian JP, McMahon DJ, Jacobs T, Shane E, Siris E, et al. The natural history of primary hyperparathyroidism with or without parathyroid surgery after 15 years. *J Clin Endocrinol Metab.* 2008;93:3462-70, <http://dx.doi.org/10.1210/jc.2007-1215>.
33. Abdelhadi M, Nordenstrom J. Bone mineral recovery after parathyroidectomy in patients with primary and renal hyperparathyroidism. *J Clin Endocrinol Metab.* 1998;83:3845-51, <http://dx.doi.org/10.1210/jc.83.11.3845>.
34. Coutinho FL, Lourenço DM Jr, Toledo RA, Montenegro FL, Correia-Deur JE, Toledo SP. Bone mineral density analysis in patients with primary hyperparathyroidism associated with multiple endocrine neoplasia type 1 after total parathyroidectomy. *Clin Endocrinol (Oxf).* 2010;72:462-8, <http://dx.doi.org/10.1111/j.1365-2265.2009.03672.x>.