

THE SPINE LATERAL BENDING AND THE DYNAMIC CHEST COMPRESSION PRINCIPLES FOR CONCOMITANT ORTHOTIC TREATMENT OF SCOLIOSIS AND PECTUS DEFORMITIES

OS PRINCÍPIOS DA INCLINAÇÃO LATERAL DA COLUNA E COMPRESSÃO DINÂMICA DO TÓRAX PARA TRATAMENTO ORTÓTICO CONCOMITANTE DA ESCOLIOSE ASSOCIADA A DEFORMIDADES PECTUS

LOS PRINCIPIOS DE INCLINACIÓN LATERAL DE LA COLUMNA VERTEBRAL Y COMPRESIÓN DINÁMICA DEL TÓRAX PARA TRATAMIENTO ORTÓTICO CONCOMITANTE DE LA ESCOLIOSIS ASOCIADA A DEFORMIDADES PECTUS

SYDNEY ABRÃO HAJE¹, DAVI DE PODESTÁ HAJE², GUSTAVO EDUARDO VIEIRA MARTINS³, MARIANA GONÇALVES FERRER³

ABSTRACT

Objective: To investigate a concomitant orthotic treatment for coexisting scoliosis and pectus deformities. No detailed study on such concomitancy was found in literature. **Methods:** A spine bending brace for use day and night, and dynamic chest compressor orthoses for use four hours a day, along with one hour of exercises, were prescribed. From 638 adolescents, 25 met the inclusion criteria for a retrospective study. Two groups of patients were identified: A (15 compliant patients) and B (10 non-compliant patients). The mean follow-up was 27 months for group A and 21 months for group B. Pre and post-treatment clinical signs of scoliosis and pectus were photographically compared. The scoliosis had radiologic evaluation by Cobb angle and Nash-Moe classification for vertebral rotation. **Results:** For both conditions, scoliosis and pectus deformities, the outcome was significantly better in the compliant group ($p < 0.001$ for both). One highly compliant adolescent with a 52° scoliosis and pectus carinatum, showed a surprising improvement to 27° after 40 months of treatment, when chest braces were interrupted and the weaning from the spine brace has started. A 34° scoliosis was maintained after 60 months of follow-up, with vertebral rotation improvement. **Conclusion:** The concomitant orthotic treatment yielded preliminary positive results for compliant patients, warranting investigation continuity.

Keywords: Spine; scoliosis; Chest wall; Pectus carinatum; Pectus excavatum; Funnel chest; Bone remodeling; Orthoses; Braces; Orthotic devices; Exercise therapy.

RESUMO

Objetivo: Investigar o tratamento concomitante com órteses para as escolioses e deformidades pectus coexistentes. Nenhum estudo detalhado sobre tal aspecto foi encontrado na literatura. **Métodos:** Um colete inclinado para uso diurno e órteses de compressão dinâmica do tórax para uso durante quatro horas diárias, sem serem retiradas para uma série diária de exercícios por uma hora, foram prescritas. De 638 adolescentes, 25 apresentaram critérios de inclusão para estudo retrospectivo. Foram identificados dois grupos de pacientes: A (15 pacientes colaboradores com o tratamento) e B (10 pacientes não-colaboradores). O tempo de seguimento médio foi de 27 meses para o grupo A e de 21 meses para o grupo B. Os sinais clínicos do pectus e da escoliose pré e pós-tratamento foram comparados fotograficamente. A escoliose foi avaliada radiograficamente através do ângulo de Cobb e do método de Nash-Moe para a rotação vertebral. **Resultados:** Para ambos, escoliose e deformidades pectus, os resultados foram significativamente melhores no grupo A ($p < 0.001$ em ambas). Uma adolescente altamente colaboradora, com escoliose de 52° e pectus carinatum, apresentou melhora surpreendente para 27° após 40 meses de tratamento, quando o uso das órteses torácicas foi interrompido e o desmame do colete para escoliose foi iniciado. Uma curva de 34° manteve-se após 60 meses de acompanhamento, com melhora da rotação vertebral. **Conclusão:** O tratamento ortótico concomitante mostrou resultados preliminares positivos para pacientes colaboradores, sugerindo continuidade de investigação.

Descritores: Coluna vertebral; Escoliose; Parede torácica; Pectus carinatum; Pectus excavatum; Tórax em funil; Remodelação óssea; Órteses; Coletes; Aparelhos ortopédicos; Terapia por exercício.

RESUMEN

Objetivo: Investigar un tratamiento concomitante con ortesis para las escoliosis y deformidades pectus coexistentes. No se ha encontrado ningún estudio detallado sobre tal aspecto en la literatura. **Métodos:** Se prescribió un chaleco inclinado para uso día y noche, y ortesis de compresión dinámica del tórax para utilización durante cuatro horas al día, sin ser retirados para una sesión diaria de una hora de ejercicios. De 638 adolescentes, 25 presentaron criterios de inclusión para estudio retrospectivo. Fueron identificados dos grupos de pacientes: A (15 pacientes colaboradores con el tratamiento) y B (10 pacientes no colaboradores). El tiempo de seguimiento promedio fue 27 meses para el

1. MD, Departments of Pediatric Orthopaedics and Physical Medicine and Rehabilitation, Centro Clínico Orthopectus, Hospital Regional da Asa Norte, Secretaria de Estado da Saúde do Distrito Federal, Brasília, Brazil. Fellowship in Paediatric Orthopaedics by the duPont Hospital for Children, Wilmington, DE, USA.

2. MD, PhD, Department of Pediatric Orthopaedics, Centro Clínico Orthopectus, Hospital de Base do Distrito Federal, Secretaria de Estado da Saúde do Distrito Federal, Brasília, Brazil. Doctorate in Orthopaedics by the Faculdade de Medicina da Universidade de São Paulo (USP), Ribeirão Preto, SP, Brazil.

3. MD, Department of Orthopaedics and Traumatology (Residency), Hospital de Base do Distrito Federal, Secretaria de Estado da Saúde do Distrito Federal, Brasília, Brazil.

grupo A y 21 meses para el grupo B. Los signos clínicos del pectus y de la escoliosis, pre y postratamiento, fueron comparados fotográficamente. La escoliosis fue evaluada radiográficamente mediante el ángulo de Cobb y el método de Nash-Moe para la rotación vertebral. Resultados: Para ambas deformidades, escoliosis y deformidades pectus, los resultados fueron significativamente mejores en el grupo A ($p < 0,001$ en los dos casos). Una adolescente muy colaboradora, con una escoliosis de 52° y pectus carinatum, presentó una mejoría sorprendente para 27° después de 40 meses de tratamiento, cuando se interrumpió el uso de las ortesis torácicas y se inició la retirada gradual del chaleco para escoliosis. Una curva de 34° se mantuvo después de 60 meses de seguimiento, con mejoría de la rotación vertebral. Conclusión: El tratamiento ortótico concomitante mostró resultados preliminares positivos para pacientes colaboradores, sugiriendo que se continúe la investigación.

Descriptores: Columna vertebral; Escoliosis; Pared torácica; Pectus carinatum; Pectus excavatum; Tórax en embudo; Remodelación ósea; Ortesis; Chalecos; Aparatos ortopédicos; Terapia por ejercicio.

INTRODUCTION

An association between pectus deformities and scoliosis has been described in the literature, but it is poorly defined¹⁻⁴. Such an association can be explained by the anatomic connexion, made by ribs and costal cartilages, between two vertical structures: the spine in the posterior part of the trunk and the sternum in the anterior chest wall. The overlapping of the spine in standard anteroposterior view makes the sternum a structure of hard radiographic evaluation, often leading to reports of normality when, indeed, irregularities are present⁵. Features suggesting disturbances in the formation, growth and development of the sternum in pectus deformities are described in a study of clinical and computed tomography (CT) correlation⁶. Two of them, the laterolateral asymmetry in the shape of the sternal body and the asymmetry of hemithoraces costal cartilages, can justify why eventually pectus patients with typical signs of scoliosis on clinical evaluation do not present scoliosis on radiographic exam, but show alterations on the sternal axis (Figure 1). On the other hand, the rotational component of a scoliosis can contribute to aesthetic alterations on the anterior chest wall.

Detailed descriptions on different conservative treatments in isolation for pectus deformities⁷⁻¹⁰ and scoliosis¹¹⁻¹³ exist, but there are no studies in literature showing the results of a concomitant orthotic treatment for patients who have both deformities, scoliosis and pectus.

Few authors have described the biomechanical bending principle¹⁴ as an important factor for improvement of rotational components of a scoliosis along with Cobb angle improvement when the spine is bent to the convexity side of the curve¹². The dynamic remodelling (DR) method, a term created to designate the practice of exercises that increase intra-thoracic pressure along with the use of Dynamic Chest Compressor (DCC) orthoses, under medical supervision, is reported in literature¹⁵. The concomitant use of the DR method and the night and day use of a bending brace for the spine, the Brasília Bending Brace (BBB)¹², has been described, but not studied in detail^{3,4}.

The purpose of this study was to investigate the results of a concomitant conservative treatment option using the principles of side bending for scoliosis and dynamic chest compression (DR method) for coexisting pectus deformities.

MATERIAL AND METHODS

Ethics

This retrospective study was approved by the Institutional Review Board of our institution.

Subjects

Between February 1997 and March 2011, 638 patients with concomitant idiopathic scoliosis and pectus deformities were assessed.

Twenty-five patients met the criteria for inclusion: (a) preadolescents and adolescents, Risser sign from 1 to 5¹⁶, who presented a minimum 20° Cobb angle scoliosis with some vertebral rotation of the main curve (up to grade 2+ reported by Nash and Moe¹⁷), all of them with an associated pectus deformity at the beginning of treatment; (b) signs of main curve angular and rotational improvement on standing side-bending pre-treatment radiographs¹²; (c) patients who were submitted to a concomitant treatment protocol that included the wearing of a BBB for scoliosis, one or two units of DCC orthoses – according to the type of pectus deformity – and exercises (Table 1); and (d) subjects with a follow-up of at least 12 months.

The remaining cases were excluded from the study because they did not meet all the inclusion criteria.

Two groups of patients were studied: group A, composed by those who followed correctly the medical instructions described in item 2 of Table 1, thus considered compliant patients, and group B, that included those who did not follow the program accordingly to such instructions and, therefore, were considered non-compliant patients. The information about compliance was obtained from parents and/or from the own patient. Patients who used the orthoses at least 80% of the time and who performed the prescribed exercises at least 80% of the recommended period were considered compliant patients.

Fifteen patients met criteria for inclusion in group A, five male (33.33%) and ten female (66.66%), with 27 months mean follow-up (range 12 to 60 months). The group B was composed by 10 patients, three male (30%) and seven female (70%), whose mean follow-up was 21 months (range 12 to 45 months). The mean age at beginning of treatment was 14.03 years old for group A and 13.31 years old for group B, ranging from 11.66 to 17.17 years old in group A, and from 11.41 to 15.58 years old in group B.

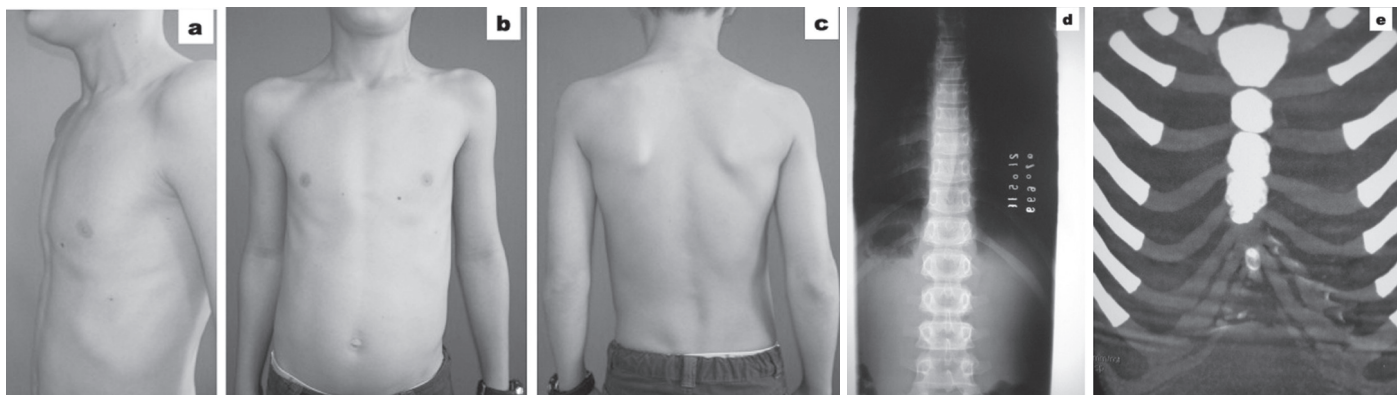


Figure 1. Twelve-year-old patient with mild pectus carinatum inferior and typical signs of scoliosis (a, b, c). The radiologic exam of his spine shows inexistence of scoliosis (d). The coronal reconstruction CT scan of his anterior chest wall shows laterolateral asymmetry in the shape of the sternal body and asymmetry of hemithoraces costal cartilages (e).

Table 1. Medical protocol for scoliosis and pectus concomitant orthotic treatment.

1. To make customized BBB and DCC orthoses (braces), according to previous radiographic scoliosis evaluation and pectus deformity type, always from previous plaster cast moulds, under medical supervision and detailed prescription regarding the spine bending level for the BBB and pads size and shape for DCC braces.
2. To explain to the patient that compliance, regarding braces use – BBB 19 hours/day and DCC(s) 4 hours/day – and regular performing of prescribed exercises (one hour, six days a week) along with the DCC brace(s), is essential for a successful treatment.
3. To explain to the patient that this is a long-term treatment, with medical supervision and gradual weaning/release from the braces, in one, two or more years.
4. To take and save clinical photographs from similar angles, before, during and after treatment.
5. To make medical follow-up every three or four months.
6. To make adjustments in the braces or manufacturing of new ones when necessary.
7. To prescribe exercises, always along with the wearing of the DCC(s), aiming no muscle hypertrophy, but to provoke movements that will result in an increase of the intra-thoracic pressure on the inner part of the anterior chest wall; and to prescribe lateral bending exercises in increased number of times to the convexity side of the scoliosis under treatment.
8. To train a team for an interdisciplinary work: physician (coordinator of the process), orthotist and physical therapist.

Orthoses and management

For treatment of pectus deformities alone the DCC wear is indicated for as much as possible in the 24 hours of a day time^{3,4,15}. As the scoliosis was seen as the harder deformity to be treated in this study, the use of DCC orthosis was indicated for 4 hours a day, and the BBB was recommended for 19 hours a day, being removed only for shower and swimming. Both DCC and BBB were made after plaster cast moulds. The mould for the DCC was taken with the patient in neutral standing position. The mould for the BBB was taken with the patient in a standing position, with hands on the head and the trunk tilted to the curve convexity, accordingly to the improvement previously checked by side-bending standing spine radiographs¹². For scoliosis with double major curves, only the main segment, usually the one with greater vertebral rotation, was selected to be treated. In such cases, during the mould, the physician always attempted to attain the corrective tilt of the primary curve without any worsening of the secondary curve. An example of a patient with the DCC and

with the BBB is shown in Figure 2. The DR method exercises were prescribed for everyday practice, during 30 to 60 minutes, always along with the use of DCC orthoses^{3,15}, and included vertical spine stretching and side bending exercises in increased amount to the convexity side of the main scoliotic curvature (Figure 3). In case of double curves, the level of side bending exercise took in consideration the level of each curve.

The DCC has lateral screws for the control of compression by anterior pads on protruded areas, with a counter-pressure pad on the spine and paravertebral muscles⁷. The BBB has a flexible anterior part made of ethylene-vinyl acetate (EVA) that is moulded below the breasts, and a rigid posterior part, made of polyvinyl chloride (PVC), higher than the anterior part, extending on the sides of the patient's body. The coupling between the parts is made with the flexible anterior part entering into both sides about two centimeters beneath the sides of the rigid posterior part, being the parts hold firmly in place by Velcro straps¹².

Scoliosis classification and assessment of evolution

Traditional classifications of scoliosis types, as those from King¹⁸ or Lenke¹⁹, are directed for surgical management of curves and were, therefore, not used in this study that deals with a conservative approach. Standing anteroposterior spine radiographs, in neutral and side-bending positions were used in the present study. The angular value of the scoliosis, measured by Cobb method, was described as reported by Haje et al¹²: the initial letter of the upper vertebra and of the lower vertebra of each curve to designate the corresponding spinal segment, followed by the number of the vertebra, and by Lt (in case of left-sided convex curves), or Rt (in case of right-sided convex curves). Thus, for instance, a patient having a 25° left-sided scoliosis between the fifth thoracic vertebra and the third lumbar vertebra, was described as having a T5-L3 Lt 25° scoliosis.

Besides radiographic assessment, clinical scoliosis signs were compared by clinical photographs.

Scoliotic curves were observed for the presence or absence of progression, as stated by the Scoliosis Research Society, being progression defined as an increase in curve magnitude of 5–10° on serial radiographs²⁰.

Vertebral rotation, which is maximal at the apex of a curve²¹, was evaluated on the radiographic films, using reported criteria^{17,20}.

Pectus classification and assessment of evolution

Pectus deformities were described, according to their predominant

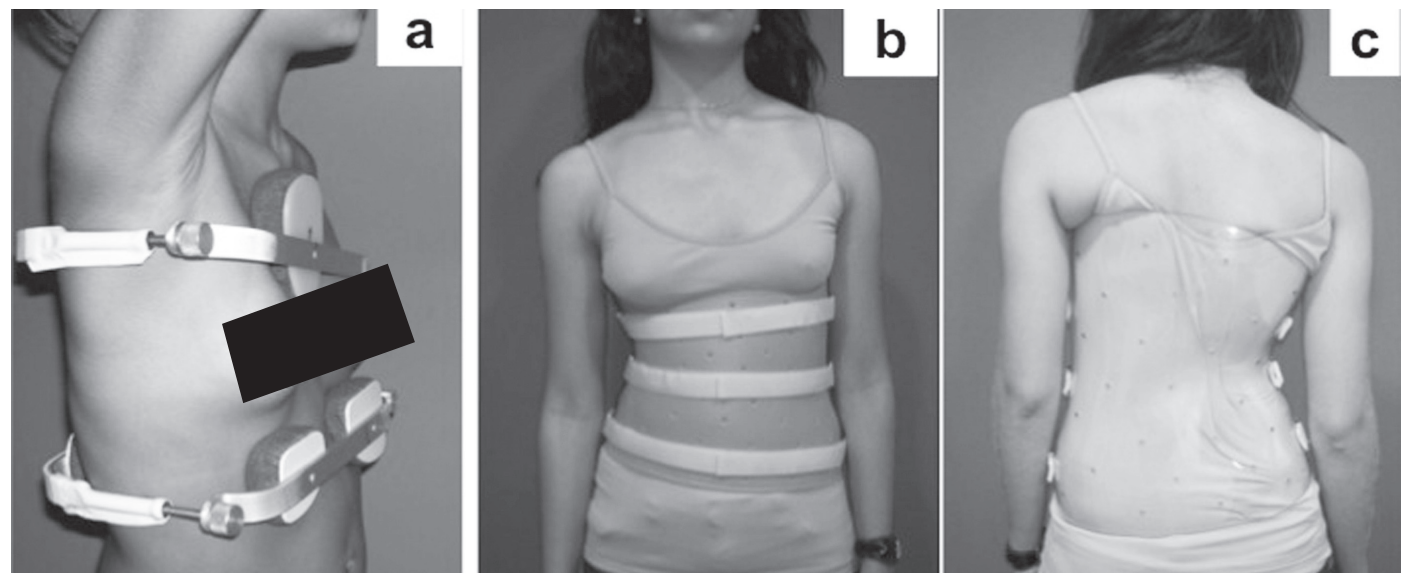


Figure 2. Patient wearing two units of the Dynamic Chest Compressor: the DCC I (upper orthosis) and the DCC II (lower orthosis) at beginning of the treatment in March 2006 (a)*; and with her fifth Brasília Bending Brace (BBB) in March 2011 (b,c). The evolution of this patient with the concomitant treatment is shown in Figures 4, 5, 6 and 7.

*(a) source: Rev Bras Ortop4.

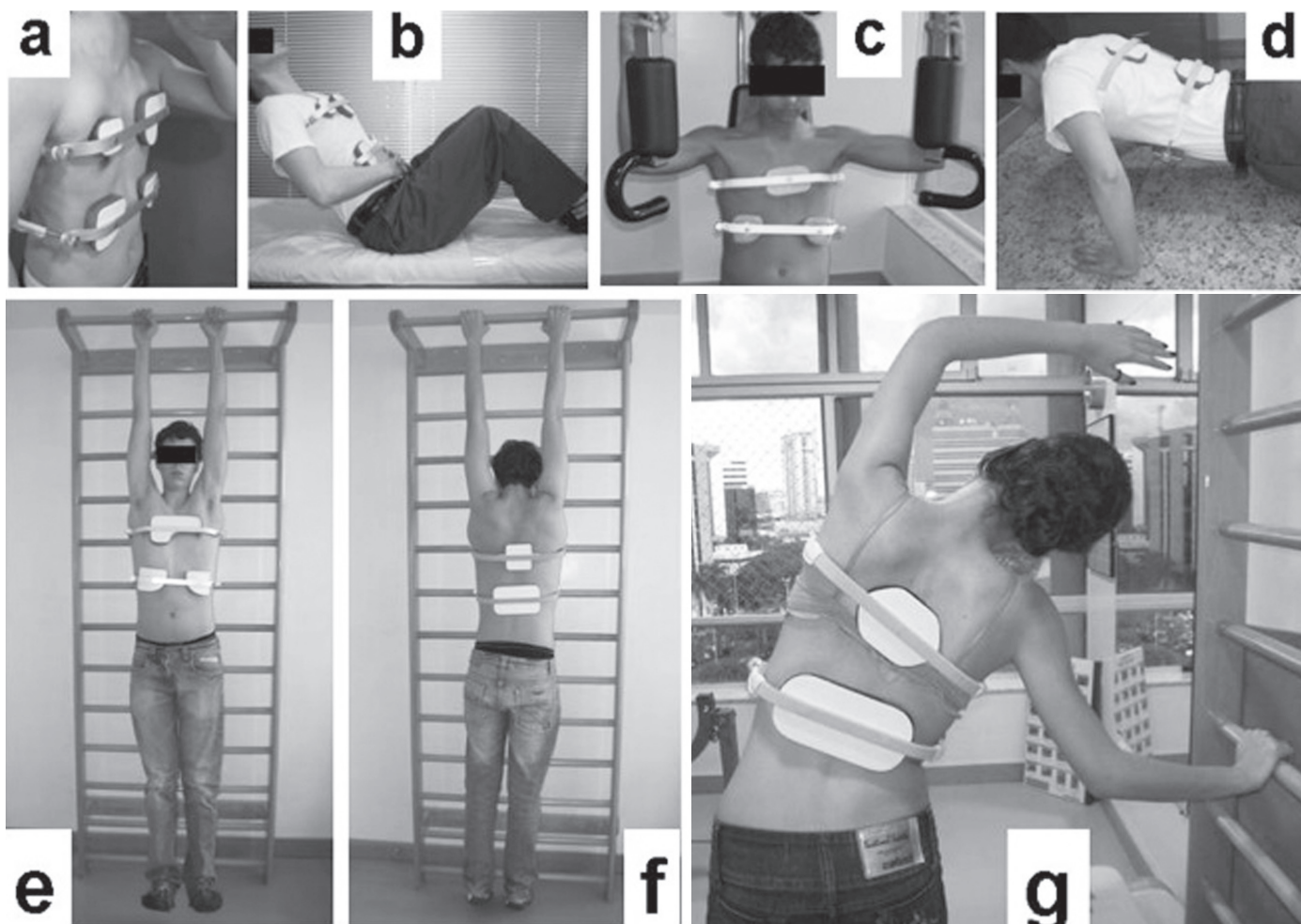


Figure 3. Some of the exercises of the Dynamic Remodeling (DR method) (a,b,c,d), plus others that are included in presence of scoliosis (e,f,g), highlighting the trunk side bending, that must be done predominantly to the convexity side of the curve.

type of deformity, into pectus carinatum inferior (PCI), pectus carinatum lateral (PCL), pectus carinatum superior (PCS), pectus excavatum wide (PEW), and pectus excavatum localized (PEL), as cited in literature^{5,6,15}. The severity of the deformities was clinically assessed as previously reported¹⁵ and classified as severe or s3, moderate or s2, and mild or s1. According to reported flexibility tests⁷, very flexible pectus deformities were classified as f3, deformities with moderate flexibility as f2, and deformities with slight flexibility as f1. So, a severe pectus carinatum inferior with a very flexible protrusion, was described as PCI s3 f3.

Oblique standing photographs from the chest area registered the clinical aspects of pectus deformities. Pectus evolution was classified as: 1 = got worse, 2 = the same, 3 = partial improvement, and 4 = remarkable improvement⁷.

STATISTICAL ANALYSIS

The final outcome for scoliosis (Cobb angle) and for pectus deformities (anteriorly cited gradation) was analysed by analysis of variance (ANOVA). Such tests compared the mean results of group A and B. The software SPSS 17.0 was employed in data analyses. A P value equal or smaller than 0.05 was considered to be statistically significant.

RESULTS

Table 2 shows compliant patients (group A) with their respective data and results. Table 3 shows the same data for non-compliant patients (group B).

Table 2. Compliant patients (Group A), scoliosis and pectus classification, follow-up, results.

Group A Patients	Age (decimal years)	Gender ^a	Main scoliosis ^b	Follow-up (months)	Cobb angle (degrees)			VRI ^c	PTSF ^d	PEV ^e
					Initial	Final	Evolution			
1	16.17	F	T11-L3 (Rt)	19	28°	28°	0°	N	PCI s1 f2	3
2	14.25	F	T11-L4 (Lt)	29	25°	24°	-1°	N	PCI s2 f3	4
3	12.08	F	T10-L4 (Lt)	14	28°	23°	-5°	N	PCL s1 f2	4
4	11.75	M	T11-L3 (Lt)	33	28°	27°	-1°	N	PCL s1 f3	4
5	13.91	F	T6-L1 (Rt)	60	52°	34°	-18°	Y	PCL s1 f2	4
6	12.00	F	T5-T11 (Lt)	12	21°	16°	-5°	N	PCI s1 f2	4
7	12.50	F	T8-L1 (Lt)	60	28°	23°	-5°	N	PCL s1 f3	4
8	17.17	F	T12-L4 (Lt)	50	35°	29°	-6°	Y	PEW s1 f2	4
9	16.75	M	T11-L4 (Lt)	13	28°	18°	-10°	N	PEW s3 f1	3
10	16.58	M	T12-L4 (Lt)	22	36°	24°	-12°	N	PEW s3 f1	4
11	15.08	M	T12-L3 (Lt)	12	20°	19°	-1°	N	PEW s2 f1	4
12	11.66	F	T11-L3 (Rt)	24	37°	33°	-4°	N	PCL s1 f1	4
13	13.66	M	T9-L3 (Rt)	20	36°	25°	-11°	N	PEW s2 f2	4
14	13.17	F	T9-L3 (Rt)	12	39°	28°	-11°	Y	PCI s1 f1	4
15	13.75	F	T10-L4 (Lt)	23	39°	38°	-1°	N	PCI s1 f2	4
Mean	14.03			27	32°	26°	-6° [§]			3.87 [§]

^aF = female, M = male. ^bSee scoliosis classification in Material and Methods. ^cVRI = Vertebrae Rotation Improvement, Y = noted, N = non-noted. ^dPTSF = Pectus type, severity and flexibility: Type: PCI = pectus carinatum inferior, PCL = pectus carinatum lateral, PCS = pectus carinatum superior, PEW = pectus excavatum wide, PEL = pectus excavatum localized (see Material and Methods). Severity: s3 = severe, s2 = moderate, s1 = mild. Flexibility: f3 = great flexibility, f2 = moderate flexibility, f1 = slight flexibility. ^ePEV = Pectus evolution: 1 = got worse, 2 = the same, 3 = partial improvement, 4 = remarkable improvement. [§] = significant value in statistical analysis, when compared to equivalent mean of Table 3.

Table 3. Non-compliant patients (Group B), scoliosis and pectus classification, follow-up, results.

Group B Patients	Age (decimal years)	Gender ^a	Main scoliosis ^b	Follow-up (months)	Cobb angle (degrees)			VRI ^c	PTSF ^d	PEV ^e
					Initial	Final	Evolution			
1	13.58	F	T12-L4 (Lt)	20	40°	50°	+10°	N	PCI s1 f3	3
2	13.50	F	T12-L4 (Lt)	12	25°	25°	0°	N	PEW s1 f2	3
3	13.25	F	T9-L3 (Rt)	45	25°	27°	+2°	N	PCI s1 f2	3
4	12.41	F	T8-L2 (Lt)	12	20°	28°	+8°	N	PEL s2 f2	2
5	15.58	M	T7-L1 (Rt)	28	24°	30°	+6°	N	PEW s2 f3	1
6	15.25	F	T11-L3 (Rt)	17	28°	28°	0°	N	PCI s1 f3	1
7	11.41	M	T5-T11 (Rt)	29	20°	26°	+6°	N	PEL s2 f2	1
8	13.41	F	T4-T10 (Rt)	12	32°	36°	+4°	N	PCL s2 f1	1
9	11.5	F	T11-L4 (Lt)	24	22°	22°	0°	N	PEL s2 f2	1
10	13.25	M	T5-T11 (Rt)	12	20°	30°	+10°	N	PEL s2 f2	1
Mean	13.31		-	21	25°	30°	+5° [§]			1.8 [§]

^aF = female, M = male. ^bSee scoliosis classification in Material and Methods. ^cVRI = Vertebrae Rotation Improvement, Y = noted, N = non-noted. ^dPTSF = Pectus type, severity and flexibility. Type: PCI = pectus carinatum inferior, PCL = pectus carinatum lateral, PCS = pectus carinatum superior, PEW = pectus excavatum wide, PEL = pectus excavatum localized (see Material and Methods). Severity: s3 = severe, s2 = moderate, s1 = mild. Flexibility: f3 = great flexibility, f2 = moderate flexibility, f1 = slight flexibility. ^ePEV = Pectus evolution: 1 = got worse, 2 = the same, 3 = partial improvement, 4 = remarkable improvement. [§] = significant value in statistical analysis, when compared to equivalent mean of Table 2

For both, scoliosis Cobb angle and pectus clinical aspect evolution, there was a significant difference in the mean end result between the compliant group A and the non-compliant group B, with a better outcome for the compliant patients ($p < 0.001$ in either of them).

For scoliosis alone, six patients in group A (40%) presented a decrease superior to 5° in the Cobb angle (improvement), while five patients in group B (50%) had a progression of their curves superior to 5° (# 5, 8, 9, 10, 13 and 14 of Table 2) showed an apparent clinical improvement in the rotational component of the scoliosis as well in the clinical photographs, but in three of them (# 9, 10 and 13) no rotational improvement was detected in radiography. Three patients (# 5, 8 and 14 of Table 2) showed rotational improvement grade 2+ to 1+. The results for patient number 5 are presented in Figures 4, 5, 6 and 7.

DISCUSSION

Although studies on pectus deformities report a higher prevalence of those deformities in male gender (73%)⁴, our study presented the typical female predominance described in the adolescent idiopathic scoliosis²².

Both pectus deformities³ and idiopathic scoliosis^{20,23} are usually progressive in the growing period, thus the importance to manage them properly.

Pectus carinatum and excavatum are complex deformities anatomically subdivided into several and sometimes mixed types of various degrees of severity. Photographic documentation is, therefore, reported as the ideal method to demonstrate the protrusion and depression components of a given deformity¹⁵. Successful outcome to pectus deformities alone with dynamic compressive orthoses and exercises (DR method), in a protocol that involves adequate medical follow-up, is reported^{3,4,7,15}. The good results observed in the present study corroborate the cited studies and appeared to be highly related to patient treatment compliance. Lower rib bulges are observed accompanying either pectus carinatum or pectus excavatum, and their correction can also be attained by the DR method⁴. The authors postulate that asymmetric ribs bulges can eventually be related to scoliosis, and demonstrate that the concomitant treatment presently studied can help correction of both deformities, from the spine and from the thoracic cage, as shown in Figures 4 to 7. The improvement of vertebral rotation occurring when the scoliosis is bent to the

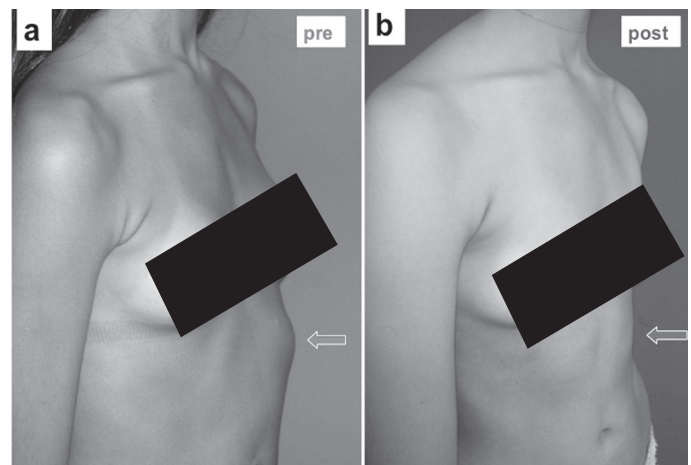


Figure 4. Case # 5 of Table 2. Female patient, 13.91 years of age, with high PCL deformity plus asymmetric inferior ribs flaring (arrow) (a)*. Her anterior chest wall post-treatment clinical aspect after 60 months is displayed in (b). The same patient is shown in Figures 2, 5, 6 and 7.

* (a) source: Rev Bras Ortop4.

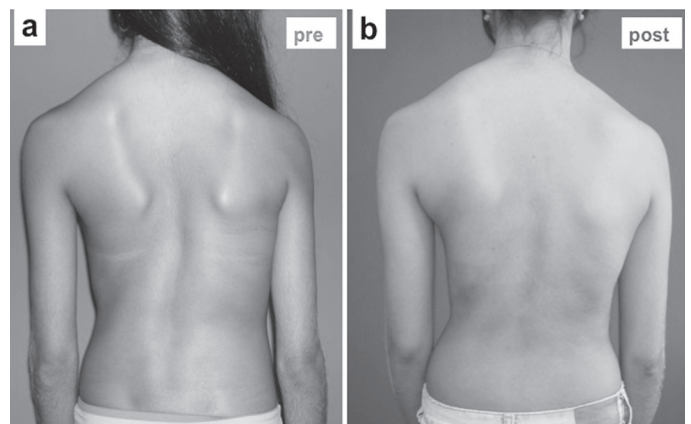


Figure 5. Back clinical signs of scoliosis of the same patient shown in Figures 2, 4, 6 and 7. In (a)* one can see the pre-treatment aspects and in (b) the 60 months post-treatment clinical aspects of her back. Less asymmetric flanks and a thoracic lordosis apparently decreased can be observed in (b).

* (a) source: Rev Bras Ortop4.

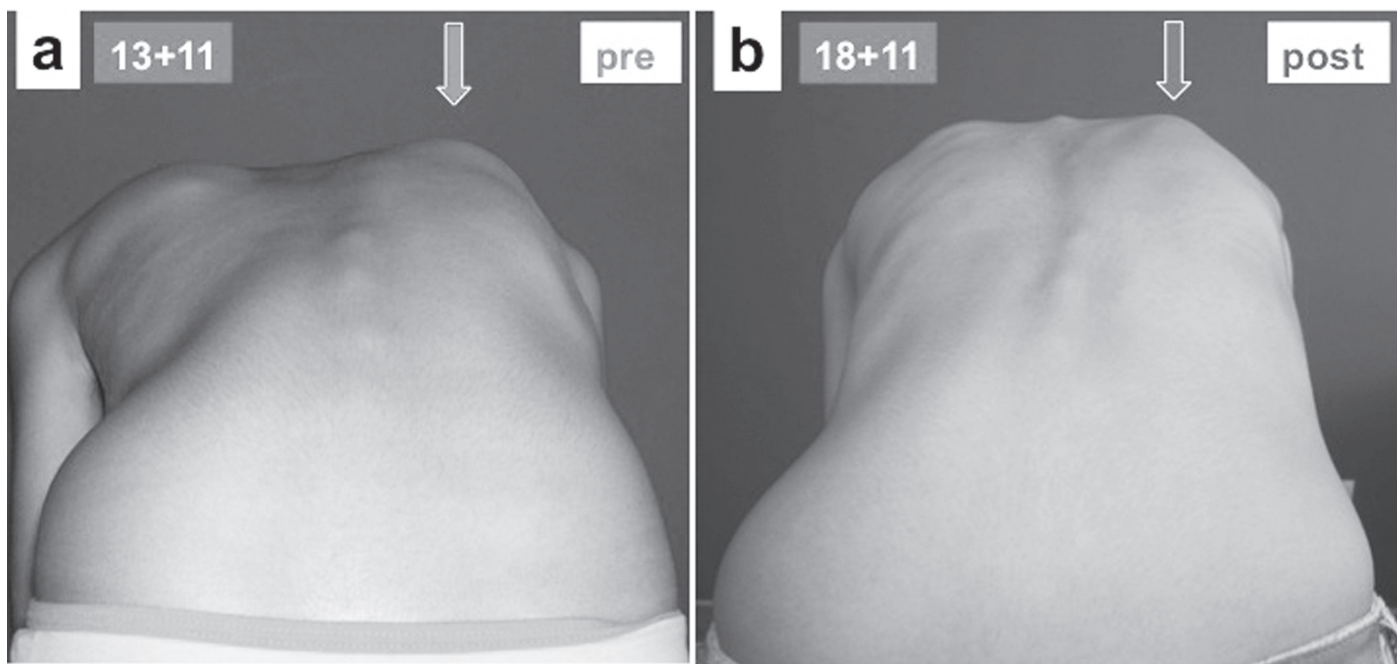


Figure 6. Pre- and post-treatment Adams forward bending test of the same patient shown in Figures 2, 4, 5 and 7. A right side gibbosity, indicating vertebral rotation, can be seen in (a*, arrow). The post-60-month-treatment improvement of such a clinical sign can be seen in (b, arrow). Her pre and post radiographic control is shown in Figure 7 (case #5 of Table 2).

*(a) source: Rev Bras Ortop4.

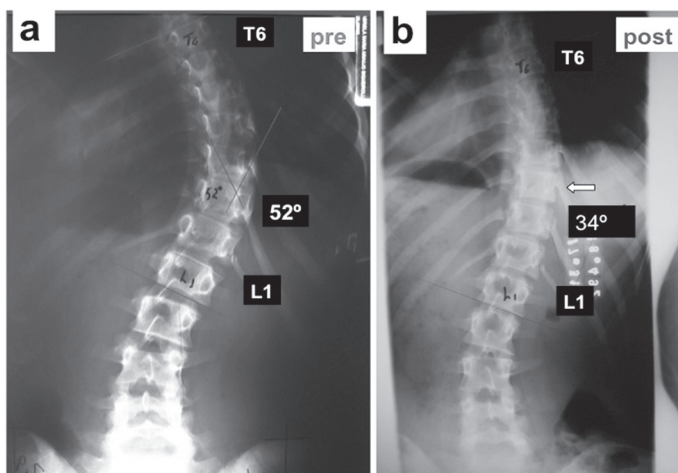


Figure 7. Standing radiographic exams of the spine of the same patient shown in Figures 2, 4, 5 and 6. The pre-treatment radiograph demonstrates a 52° T6-L1 Rt scoliosis with vertebral rotation (a*). A 34° Cobb angle was observed after 60 months treatment, demonstrating a stable correction of 18° (b). An accurate observation of the apical vertebra T10 (arrow in b) shows improvement of the rotational component 2+ to 1+. See more details in discussion section.

*(a) source: RevBrasOrtop4.

convexity side is a biomechanical principle that can be explained by the description of Prat and Burniol: "When the spine is bent to one side, an automatic rotation of the vertebrae occurs to the same side"¹⁴. So, the authors believe that the bending principle is a key element for correction of the two principal aspects of a scoliosis, the curve itself and the rotational component. In this way, they support the idea of a bending brace designed for being used day and night¹² and prescribe exercises that include lateral inclinations of the trunk in greater number of times to the convexity side of the curve. Other evidences exist supporting exercises effects in patients with adolescent idiopathic scoliosis^{24,25}. In the authors experience exercises are valid only as a complement of an orthotic treatment.

As opposed to the idea of a weak response to brace wear in patients with more advanced skeletal maturity, an improvement was observed in such cases in this series. Just as other studies that claim the possibility to treat scoliosis in Risser IV and V patients^{12,26,27}, we believe that the concomitant treatment by the studied method can be extended to those older patients, provided they present some anterior chest wall and spinal flexibility, and are eager to follow the proposed therapeutic protocol. As pectus flexibility is an important factor for treatment prognosis^{3,7}, the scoliosis flexibility, rather than maturation, should be considered for the presently proposed method. The concomitant orthotic treatment involves application of dynamic forces on deformed structures of both, spine and chest, aiming a simultaneous beneficial remodelling.

Compliance is essential for a brace treatment. In a previous study of Haje and colleagues, patients who followed the proposed program correctly (43.3%) obtained a 5.43° mean improvement in their curves; those who gave up treatment (10%) showed a 9.33° average worsening of their scoliosis, while those who followed the program irregularly (46.7%) did not show any significant change in their curves¹². The authors recognize that the selection of the groups in the present study was done subjectively, based on patients and/or parents information, but the importance of brace compliance in different scoliosis treatment programs was also demonstrated objectively by Rahman et al²⁸ and by Katz and colleagues²⁹. Protocol items 2 and 3 (Table 1) are very important and the total treatment time depends on the spine and anterior chest wall flexibilities as well as on how the patient follows the medical instructions.

The primary aim of scoliosis management is to stop curvature progression¹¹. Since there was no significant (> 5°) progression in any of our compliant patients, we could state that all of them were treated properly.

Surprisingly, the best result obtained in our series was that of a very compliant female patient, 13.91 years of age, with a predominantly thoracic 52° curve and a high PCL deformity plus asymmetric inferior ribs flaring (case # 5 of Table 2). After 40 months treatment she was released from the DCC orthoses and the chest correction was maintained up to the last time the patient was seen at 18 years 11 months old, after 60 months follow-up (Figures 4 to 7). Five BBB were made after cast moulding for this patient, in intervals of approxi-

mately 12 months, aiming a gain in curve flexibility and correction. She followed strictly the prescriptions she received, without interruptions. After 40 months of treatment the Cobb angle decreased to 27° and weaning from the BBB was indicated. Six months later, after 46 months of treatment, a 34° Cobb angle was observed. Twenty months later, after a total of 60 months treatment, a 34° Cobb angle was still observed, demonstrating a stable correction of 18°. The pre and post clinical aspects of her back are shown in Figure 5. The clinical improvement of the rotational component of her scoliosis is shown in Figure 6. Radiological aspects on the evolution of her scoliosis can be seen in Figure 7.

Despite the small number of patients (25) obtained from a larger population (638), according to the inclusion criteria for this study, and despite the relatively short follow-up to some of them, we noted that pectus deformity as well as scoliosis showed relatively quick trend towards improvement in compliant patients, with few months of treatment. It is interesting to observe that all Group A patients (Table 2) with follow-up <18 months got improvement 3 or 4 of their pectus deformity and had no progression of their scoliosis (some got improvement), while progression of Cobb angle was

detected for patients with similar short follow-up in Group B (non-compliant / Table 3). We believe that the longer the treatment is done correctly the better the result and the smaller the chance of recurrence. Corrective forces, applied during a long-term period, presumably can promote the remodeling of deformed structures of the anterior chest wall and spine. So, the tendency to hold correction depends on the total duration of treatment.

CONCLUSION

The concomitant orthotic treatment using the spine lateral bending and the dynamic chest compression principles for patients who present scoliosis and pectus deformity showed positive preliminary results for compliant patients, justifying a continued investigation.

ACKNOWLEDGMENT

The authors would like to acknowledge the efforts of Rubens P. Souza, MD, for the initial survey that resulted in partial data used in the present study.

REFERENCES

- Waters P, Welch K, Micheli LJ, Shamberger R, Hall JE. Scoliosis in children with pectus excavatum and pectus carinatum. *J Pediatr Orthop* 1989;9(5):551-6.
- Frick SL. Scoliosis in children with anterior chest wall deformities. *Chest Surg Clin N Am* 2000;10(2):427-36.
- Haje S, Haje DP. Tórax e cintura escapular. In: Hebert SK, Barros Filho TEP, Xavier R, Pardini Jr AG, ed. *Ortopedia e traumatologia: princípios e prática*. 4th ed. Porto Alegre: Artmed Editora, 2009:147-65.
- Haje SA, Haje DP. Abordagem ortopédica das deformidades pectus: 32 anos de estudos [Orthopaedic approach to pectus deformities: 32 years of studies]. *Rev Bras Ortop* 2009;44:193-200. Web Reference: <http://www.scielo.br/pdf/rbort/v44n3/v44n3a03.pdf> (date last accessed 1Dec2011).
- Haje SA, Harcke HT, Bowen JR. Growth disturbance of the sternum and pectus deformities: imaging studies and clinical correlation. *Pediatr Radiol* 1999;29:334-41. Web Reference: <http://www.ncbi.nlm.nih.gov/pubmed/10382210> (date last accessed 1Dec 2011).
- Haje SA, Haje DP, Silva Neto M, Cassia GS, Batista RC, et al. Pectus deformities: tomographic analysis and clinical correlation. *Skeletal Radiol* 2010;39(8):773-82. Web Reference: <http://www.springerlink.com/content/7408458888102745/> (date last accessed 1Dec2011).
- Haje SA, Bowen JR. Preliminary results of orthotic treatment of pectus deformities in children and adolescents. *J Pediatr Orthop* 1992;12:795-800.
- Mielke CH, Winter RB. Pectus carinatum successfully treated with bracing - a case report. *Int Orthop* 1993;17:350-2.
- Egan CJ, Du Bois JJ, Morphy M. Compressive orthotics in the treatment of asymmetric pectus carinatum: a preliminary report with an objective radiographic marker. *J Pediatr Surg* 2000;35:1183-6.
- Frey AS, Garcia VF, Brown RL, Inge TH, Ryckman FC, et al. Nonoperative management of pectus carinatum. *J Pediatr Surg* 2006;41:40-5.
- Price CT, Scott DS, Reed Jr FR, Sproul JT, Riddick MF. Nighttime bracing for adolescent idiopathic scoliosis with the Charleston bending brace: long-term follow-up. *J Pediatr Orthop* 1997;17(6):703-7.
- Haje SA, Haje DP, Guerra JB, Petrenko Jr AG. Órtese inclinada de uso contínuo e exercícios para tratamento da escoliose idiopática: uma nova proposta. [Day and night bending brace and exercises for treatment of idiopathic scoliosis: a new proposal]. *Brasília Med* 2008;45(1):10-20. Web Reference: http://www.ambr.com.br/rb/arquivos/04_artigo_original_ortese%20inclinada....pdf (date last accessed 1Dec2011).
- Katz DE, Richards S, Browne R, Herring JA. A comparison between the Boston brace and the Charleston bending brace in adolescent idiopathic scoliosis. *Spine* 1997;22:1302-12.
- Prat AG, Burniol JR. Biomecánica de la columna vertebral. In: Viladot A, ed. *Lecciones básicas de biomecánica del aparato locomotor*. Barcelona: Masson, 2004:112.
- Haje SA, Haje DP. Overcorrection during treatment of pectus deformities with DCC orthoses: experience in 17 cases. *Int Orthop* 2006;30:262-7. Web Reference: <http://www.pubmedcentral.nih.gov/articlerender.fcgi?artid=2532136> (date last accessed 1Dec2011).
- Risser J. The iliac apophysis: an invaluable sign in the management of scoliosis. *Clin Orthop* 1958;11:111-9.
- Nash C, Moe JH. A study of vertebral rotation. *J Bone Joint Surg Am* 1969;51:223-9.
- King HA, Moe JHY, Bradford DS, Winter RB. The selection of fusion levels in thoracic idiopathic scoliosis. *J Bone Joint Surg* 1983;65-A:1302-13.
- Lenke LG, Betz RR, Harms J, Bridwell KH, Clements DH, et al. Adolescent idiopathic scoliosis: a new classification to determine extent of spinal arthrodesis. *J Bone Joint Surg Am* 2001;83-A(8):1169-81.
- Richards BS, Bernstein RM, D'Amato CR, et al. Standardization of criteria for adolescent idiopathic scoliosis brace studies: SRS Committee on Bracing and Nonoperative Management. *Spine* 2005;30:2068-75.
- Stokes, IAE. Axial rotation component of thoracic scoliosis. *J Orthop Res* 1989;7:702-8.
- Goldberg CJ, Moore DP, Fogarty EE, Dowling FE. Scoliosis: a review. *Pediatr Surg Int* 2008;24(2):129-44.
- Lonstein JE, Carlson JM. The prediction of curve progression in untreated idiopathic scoliosis during growth. *J Bone Joint Surg Am* 1984;66:1061-71.
- Negrini S, Fusco C, Minozzi S, Atanasio S, Zaina F, et al. Exercises reduce the progression rate of adolescent idiopathic scoliosis: results of a comprehensive systematic review of the literature. *Disabil Rehabil* 2008;30(10):772-85.
- Weiss HR, Weiss G, Petermann F. Incidence of curvature progression in idiopathic scoliosis patients treated with scoliosis in-patient rehabilitation (SIR): an age- and sex-matched controlled study. *Pediatr Rehabil* 2003;6(1):23-30.
- Montgomery F, Willner S. Prognosis of brace-treated scoliosis: comparison of the Boston and Milwaukee methods in 244 girls. *Acta Orthop Scand* 1989;60:383-5.
- Negrini S, Atanasio S, Fusco C, Zaina F. Efficacy of bracing immediately after the end of growth: final results of a retrospective case series. *Scoliosis* 2009;4(Suppl 2):O49.
- Rahman T, Bowen JR, Takemitsu M, et al. The association between brace compliance and outcome for patients with idiopathic scoliosis. *J Pediatr Orthop* 2005;25:420-2.
- Katz DE, Herring JA, Browne RH, Kelly DM, Birch JG. Brace wear control of curve progression in adolescent idiopathic scoliosis. *J Bone Joint Surg Am* 2010;92:1343-52. doi:10.2106/JBJS.I.01142.