

MINIMALLY INVASIVE CIRCUMFERENTIAL ARTHRODESIS OF THE FOURTH LUMBAR LEVEL FOR SPONDYLOLISTHESIS TREATMENT

ARTRODESE CIRCUNFERENCIAL MINIMAMENTE INVASIVA DE 4º NÍVEL LOMBAR PARA TRATAMIENTO DE ESPONDILOLISTESE

ARTRODESIS CIRCUNFERENCIAL MINIMAMENTE INVASIVA DEL CUARTO NIVEL LUMBAR PARA TRATAMIENTO DE ESPONDILOLISTESIS

JOSE ENRIQUE SALCEDO OVIEDO¹, LUIS MUÑOZ LUNA¹, MARCO ANTONIO MARBAN HEREDIA¹, LUIS IVAN HERRERA ALCARAZ¹, HUGO VILCHIS SÁMANO¹, JUVENAL ORDAZ VEGA¹, YADIRA BAHENA SALGADO¹, MARIO ALONSO CIENEGA VALERIO¹

1. Instituto Mexicano Del Seguro Social, Unidad Médica de Alta Especialidad Lomas Verdes, Spine Surgery Service. Av Lomas Verdes, sn, Naucalpan de Juarez, Estado de México, CP 53125, Mexico.

ABSTRACT

Objective: To know the clinical and radiographic results of patients with L4-L5 degenerative spondylolisthesis grade I, II, and III surgically treated with minimally invasive 360-degree arthrodesis. To determine the clinical and radiographic results according to the Oswestry Index 6 months after surgery and the percentage of postsurgical reduction in these patients. **Methods:** The present study was developed in the Department of Spinal Surgery of the Unidad Médica de Alta Especialidad Lomas Verdes, from October 2016 to August 2017. It is a prospective, cross-sectional, comparative observational study. We evaluated the reduction of the listhesis using pre and post-operative radiographs, as well as the Oswestry Disability Index. **Results:** The sample was composed of 12 patients, eight females and four males, showing a statistical significance in the Student's t test, with $p=0.05$ for both variables. **Conclusions:** Degenerative spondylolisthesis of the 4th lumbar level is a very frequent pathology that affects groups of productive age and represents a burden not only for the patient, but also for the community. This surgical technique showed a high level of security and confidence for its resolution, showing results comparable to the literature. However, it requires certain technical resources and training to be performed. **Evidence Level II; Prospective comparative study.**

Keywords: Spine; Surgery; Minimally invasive surgical procedures; Treatment outcome; Prospective studies.

RESUMO

Objetivo: Conhecer os resultados clínicos e radiográficos de pacientes com espondilolistese degenerativa L4-L5 de grau I, II e III, tratados cirurgicamente com artrodeose minimamente invasiva de 360 graus. Determinar os resultados clínicos e radiográficos segundo o Índice de Oswestry seis meses após a cirurgia e a porcentagem de redução pós-operatória nesses pacientes. **Métodos:** Este estudo se desenvolve na Unidade Médica de Alta Especialidade "Lomas Verdes", Cirurgia de coluna, no período de outubro 2016 a agosto de 2017. É um estudo transversal prospectivo, observacional seccional. Avaliamos a lista de redução através de estudos radiográficos pré e pós-operatórios e escala de incapacidade Oswestry. **Resultados:** Observamos 12 pacientes, oito homens e quatro mulheres, mostrando significancia estatística pelo teste t de Student com $p = 0,05$, para ambas as variáveis. **Conclusão:** Espodilolistesis degenerativa de 4º nível lombar são muito frequentes, afetam grupos etários produtivos e afetam tanto o paciente quanto o seu ambiente social. Esta técnica cirúrgica mostra um alto nível de segurança e confiança para solução, mostrando resultados comparáveis com a literatura. No entanto, ele requer recursos técnicos e nível de formação para a sua execução. **Nível de Evidência II; Estudo prospectivo comparativo.**

Descritores: Coluna vertebral; Cirurgia; Procedimentos cirúrgicos minimamente invasivos; Resultado do tratamento; Estudos prospectivos.

RESUMEN

Objetivo: Conocer los resultados clínicos y radiográficos en pacientes con espondilolistesis degenerativa L4-L5 grado I, II y III operados con artrodesis 360 minimamente invasivo. Determinar los resultados clínico y radiográficos de pacientes con espondilolistesis degenerativa L4-L5 grado I, II y III con la escala de Oswestry después de 6 meses de operados. Determinar el porcentaje de reducción postquirúrgico de pacientes con espondilolistesis degenerativa L4-L5 grado I, II y III operados con artrodesis 360 minimamente invasivo. **Métodos:** El presente estudio se desarrolló en la Unidad Médica de Alta Especialidad Lomas Verdes, módulo de Cirugía de Columna en el periodo de Octubre de 2016 a Agosto del 2017. Es un estudio prospectivo, observacional transversal y comparativo. Evaluamos la reducción de la listesis mediante estudios radiográficos pre y posoperatorios, así como la escala de discapacidad Oswestry. **Resultados:** La muestra fue de 12 pacientes, ocho del sexo femenino y cuatro del masculino, mostrando una significancia estadística mediante la prueba T de Student con una $p=0,05$ para ambas variables. **Conclusiones:** La espondilolistesis degenerativa en el cuarto nivel lumbar

Study conducted at the Spine Surgery Service of the Unidad Médica de Alta Especialidad Lomas Verdes Traumatology and Orthopedics Hospital, of the Mexican Social Security Institute. Mexico. Correspondence: Mariano escobedo 221 .el Huerto Cuautitlan mexico, cp 54807. drsalcedo1969@yahoo.com

es una entidad patológica muy frecuente, que afecta grupos en edad productiva y representa una carga no solo para el paciente, sino también para la sociedad. Esta técnica quirúrgica mostró un alto nivel de seguridad y confianza para su resolución, mostrando resultados equiparables a la literatura. Sin embargo, requiere ciertos recursos técnicos y nivel de adiestramiento para su ejecución.

Nivel de Evidencia II; Estudio prospectivo comparativo.

Descriptor: Columna vertebral; Cirugía; Procedimientos quirúrgicos mínimamente invasivos; Resultado del tratamiento; Estudios prospectivos.

INTRODUCTION

The term degenerative spondylolisthesis was coined by Newman and Stonel to describe anterior vertebral slippage caused by degenerative changes in the facet joints with an intact neural arch.

The incidence of degenerative spondylolisthesis is observed predominantly in people older than 40 years of age, with an average age of 61 years, with a predominance of 4:1 of females to males, having a prevalence of 7.5% in men and 28% in women in patients over 50 years of age with lumbalgia.^{1,2}

The etiopathogenesis of degenerative spondylolisthesis is multiple.

The most frequently affected segment is L4-L5 (in 85% of cases), followed by L3-L4 and very rarely L5-S1.

The conjunction of two systems, one active (muscles and tendons) and one passive (vertebrae, discs, ligaments, and joint capsules) allow the spine to be a very stable structure, but any change to either of these two systems leads to compensation on the part of the other.

Anterolisthesis occurs when the posterior joints are more degenerated than the disc, ultimately causing central and lateral stenosis of the lumbar canal.

The marked horizontalization of the laminae and facet joints in patients with degenerative spondylolisthesis is also noted.³ This degeneration causes the subluxation of the facet joints allowing the displacement of the vertebral body, the reduction of the intervertebral foramina and of the vertebral foramen causing nerve root compression manifested by sciatica that is accentuated by movements of extension and reduced when sitting and even disappearing when lying down. This condition is more common in the L4 and L5 vertebral bodies. Its onset is slow and progressive. It is rarely severe and it is present during many years, even for prolonged periods with no symptoms.^{1,3}

Most patients with degenerative spondylolisthesis are asymptomatic (around 85%).⁴ The symptoms occur due to its association with lumbar spine stenosis that results in compression of the nerve root.^{4,5} Lumbar pain, which may present with or without pain in the legs, is the most common complaint. Typical sciatica with evidence of changes in the conduction of the nerve root, mainly in L5, with or without back pain, may occur. The degree of compression and the progression of the slippage do not necessarily correspond to the patient's clinical condition. Other symptoms are intermittent claudication, unilateral sensory deficits in the L5 dermatome, and involvement of the hips.

The diagnosis of degenerative spondylolisthesis is obviously radiological. It should include radiographs in anterior-posterior, lateral (which should be taken in a standing position), oblique and dynamic projections in flexion and extension.

White and Panjabi developed a method for measuring translation and displacement in the sagittal plane. If the translation is equal to or greater than 4.5 or greater than 15% of the sagittal diameter of the adjacent vertebra, it is considered abnormal.

In 1931, Henry W. Meyerding described lumbar subluxation as a percentage, assigning each to different grades. Grade I represents a translation of up to 25%, grade II between 25% and 50%, grade 3 between 50% and 75%, grade IV between 75% and 100% and grade V greater than 100% (also called spondyloptosis). We refer to high-grade spondylolisthesis when the grade of the displacement is greater than or equal to grade III of this classification. Magnetic resonance imaging is ideal for determining the severity of the narrowing of the spinal canal and of the foramina.^{3,5}

Fitzgerald and Newman recommended spinal fusion under two circumstances: first, in young patients with clear symptoms and signs of instability (angulations greater than 11 degrees) and with degenerative

changes limited to a single level and second, in cases where, after decompression is performed in young patients, facet joint insufficiency occurs.

Instrumented lumbar interbody fusion is a commonly used procedure to treat several spine pathologies in the lumbar region, including spondylolisthesis. The objective of fusion is to achieve a stable fusion of the spinal segments with good height and alignment.^{6,7} Instrumented fusion is considered the surgical method for the treatment of spondylolisthesis with grade IV displacement.⁸

The surgical approaches for fusion include Posterior Lumbar Interbody Fusion (PLIF) and Transforaminal Lumbar Interbody Fusion (TLIF). TLIF reduces to a certain extent the trauma to the lumbar musculature, the facet joints, and the laminae as compared to PLIF, so it has increased in relative popularity. PLIF is associated with moderate and high rates of perioperative complications. Transforaminal lumbar interbody fusion (TLIF) eliminates the risk of retroperitoneal lesion associated with Anterior Lumbar Interbody Fusion (ALIF) techniques. Comparing TLIF and PLIF, TLIF is a procedure that allows access to the disc space through elimination of the facet joint. This permits less movement of the thecal sac and lowers the risk of nerve lesions.⁶⁻⁸

Lumbar fusion can be performed as open or minimally invasive (MIS) surgery. Open TLIF has been proven to be safe in achieving spinal fusion and restoring both disc height and spinal alignment in patients with symptomatic spondylolisthesis and degenerative disc.

The disadvantage of Open TLIF is the extensive dissection of the soft tissues necessary for the insertion of the pedicle screws, causing a significant iatrogenic lesion. Damage to the tissues during the surgery can result in an increase in postoperative pain, recovery time, delay in rehabilitation, and deterioration of spinal function.^{2,6,8}

Minimally Invasive TLIF (MIS TLIF) is comparable to Open TLIF in terms of clinical outcomes and fusion rates, with the additional benefits of less postoperative pain, less blood loss, earlier rehabilitation, and a shorter hospitalization. The indications of MIS TLIF are generally the same as for the open procedure.¹³ However, MIS TLIF is a challenging technique, as it requires working in a smaller area to achieve decompression and interbody fusion. This technique requires a learning curve and thus, has been associated with a longer surgical time, but this can be overcome with dedication, repetition, and experience.

Another advantage of MIS TLIF is a reduction in blood loss of approximately two and a half times compared to open TLIF.⁹⁻¹² The complications rate for Open TLIF was 13.8% compared to 6.9% for MIS TLIF, although they were minor complications.^{9,12}

Both MIS TLIF and Open TLIF show significant improvement in the clinical results at six months and two years as compared to the preoperative clinical data.¹⁴ All the series had fusion rates well above 90% without significant difference between the two techniques at six months.¹⁵

The direct and indirect costs associated with surgical intervention can decrease directly. While MIS TLIF requires specialized additional instrumentation to achieve minimal tissue disruption, the financial cost is compensated by the benefits of minimally invasive surgery. The patient undergoing the open technique may spend twice as long in the hospital and take three times longer to be able to stand and walk than the patient who undergoes the minimally invasive technique. Reduction in the risk of nosocomial infection, rehabilitation time, postoperative pain, and analgesic medications used also translate into reduced costs.¹⁶

It is in our best interests to know the effectiveness of surgical treatment of circumferential spondylolisthesis using minimally invasive techniques in well-studied patients with this pathology, to know the

clinical results and the percentage of reduction of listhesis through an indirect reduction of the spinal canal affected in the Unidad Médica de Alta Especialidad Lomas Verdes.

There is no experience at the present time in treating this pathology with this surgical technique, thus improving the conditions of life as measured by the Oswestry index and radiographic measurements, achieving a better quality of life for these patients.

Methods

The research was conducted in a tertiary reference center, the Spine Surgery Service of the Unidad Médica de Alta Especialidad Lomas Verdes Traumatology and Orthopedics Hospital, of the Mexican Social Security Institute.

It was approved by the Institutional Review Board and the informed consent form was signed by all the research participants.

This observational, prospective, cross-sectional, comparative study was conducted from October 2016 to August 2017, according to the data collected in this period.

The patients were diagnosed with degenerative Grade I, II, and III L4-L5 lumbar spondylolisthesis and underwent minimally invasive 360 arthrodesis surgery (PLIF) of a single level (L4-L5), using transpedicular instrumentation (Sextant) and minimally invasive interbody cages (Typal). Clinical-functional evaluation was conducted preoperatively and six months following surgery using the Oswestry Disability Index.

Pre- and postoperative evaluations of the radiographic studies were conducted to assess the reduction obtained. A descriptive statistical analysis was performed using measures of central tendency, distribution of the variables, as well as the Student's t test.

RESULTS

The study was developed between October 2016 and August 2017. The sample consisted of 12 patients, 8 of whom (66.6%) had grade II spondylolisthesis and 4 of whom (33.4%) had grade III spondylolisthesis. They underwent minimally invasive transpedicular instrumentation (Sextant) of L4-L5, osteotomy of the pars interarticularis of L4, discectomy, manual and instrumental displacement reduction, fixation with two circular rods, placement of an autologous interbody bone graft between L4-L5, and placement of an interbody cage (T-PAL™).

The ages ranged from a minimum of 40 years to a maximum of 68, with an average of 58 years of age with a standard deviation of 5.9. There were 5 male patients (41.66%) and 7 female patients (58.33%). (Figure 1, Table 1). We used the WebServex system of the institution (IMSS) to analyze the pre- and postoperative radiological studies. The most-identified diagnosis prior to surgery was degenerative grade II lumbar spondylolisthesis in 8 patients (66.6%), with grade III identified in 4 patients (33.4%). The reduction evaluated radiologically after surgery was complete without signs of vertical displacement in 11 patients (91.6%) and a reduction to grade I or less than 25% displacement in 1 patient (8.4%), with a difference of averages between the two evaluations of one (p=0.05). (Figure 2. Table 2). In the assessment with the Oswestry index, we compared the pre- and postoperative clinical statuses in which the preoperative scores of the 12 patients ranged from a minimum of 25 to a maximum of 90 points. We found that the patients improved an average of 51 points on the scale, 11 of them with a moderate degree of disability and one patient with severe disability. (Figure 3, Table 3).

Based on the data obtained and using the Student's t test, we obtained a level of significance of p=0.05, so that the null hypothesis was accepted, a result of the clinical improvement at 6 months following surgery.

DISCUSSION

In reference to the study objective of knowing the clinical functional outcome of patients with degenerative grade I, II, and III,

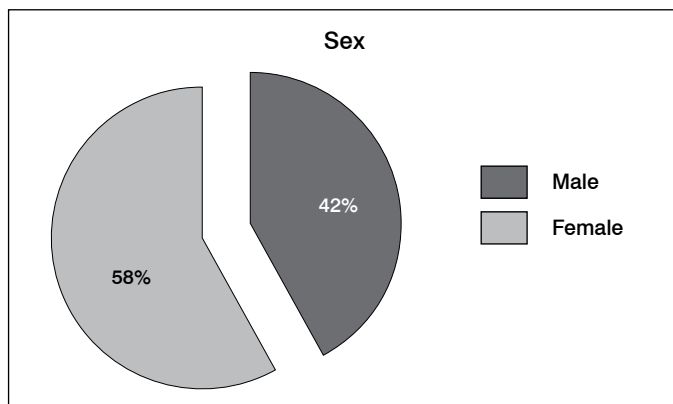


Figure 1. Patient characteristics.

Table 1. Patient characteristics.

Sex	Number of patients	Percentage
Male	5 patients	42%
Female	7 patients	58%

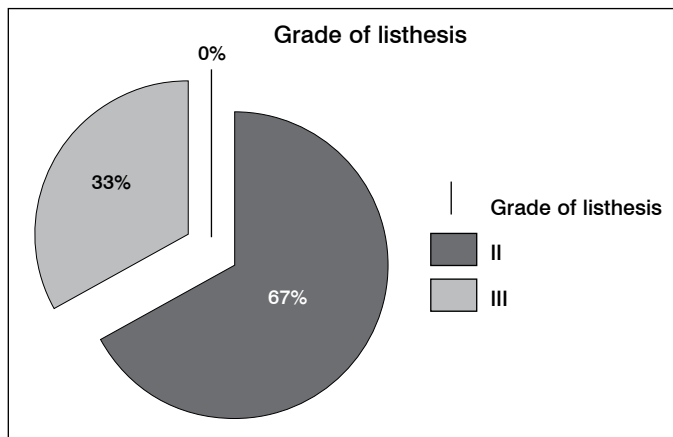


Figure 2. Grade of listhesis in the Preoperative period.

Table 2. Grade of listhesis in the Preoperative period.

Grade of listhesis	Number of patients	Percentage
II	8 patients	67%
III	5 patients	33%

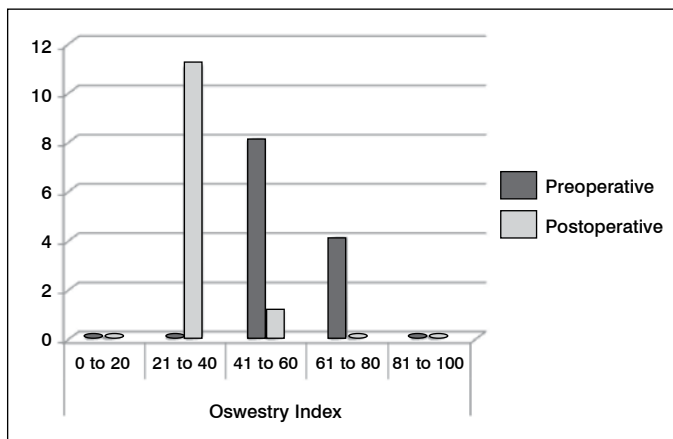


Figure 3. Preoperative and postoperative Oswestry index.

Table 3. Preoperative and postoperative Oswestry index.

Oswestry index	0 to 20	21 to 40	41 to 60	61 to 80	81 to 100
Preoperative	0	0	0	8	4
Postoperative	0	11	1	0	0

lumbar spondylolisthesis who underwent PLIF and fixation with transpedicle screws, evaluated with the Oswestry functional disability scale, we found that the patients had favorable results with a moderate degree of disability.

Females were predominant in this study, similar to the predominance of females over males that exists in the international literature. The average age was between 45 and 80 years. In terms of the degenerative pathology that occurs during these decades, the most affected group was between 51 and 70 years of age.

Another objective of this study was to determine the reduction achieved after the surgical intervention for degenerative vertebral slippage, which could be assessed with radiological exams before and after surgery allowing us to estimate the degree of reduction achieved, which was almost complete in most of the patients, in addition to determining the formation of interbody bony bridges and the presence of adequate intervertebral space without a loss of height between L4-L5.

CONCLUSION

We can say that the treatment of degenerative lumbar spondylolisthesis by means of posterior fusion with an interbody cage

(PLIF) and minimally invasive transpedicular instrumentation is very safe and effective as it yields good postoperative results in terms of clinical and radiological improvement.

This study sets the agenda for more extensive patient follow-up to evaluate the biomechanics of the implant and to be able to determine the presence of pseudoarthrosis, vertebral deformities, and the presence of adjacent segment degeneration.

As well as to evaluate long-term clinical and functional results using the same Oswestry Index or including quality of life scales that should be evaluated accurately for up to two years.

The results demonstrate statistical significance, which makes us conclude that minimally invasive surgery for patients with degenerative grade I, II, and III spondylolisthesis of L4-L5 is a very good option, however, incorporating a new surgical technique requires a learning curve and procedural training to thus obtain experience.

We consider minimally invasive surgery to be the future in the treatment of degenerative spine pathology in the middle term given its good postoperative evolution, reduced damage to patient tissue, and probably, in the long term, the lower cost in caring for these patients.

All authors declare no potential conflict of interest related to this article.

CONTRIBUTION OF THE AUTHORS: Each author made significant individual contributions to this manuscript. JESO (0000-0001-8009-2432)* and LML (0000-0003-2363-5589)* were responsible for performing the surgeries, as well as patient recruitment and preparing the conclusions for the final article. MAMH (0000-0002-0718-5445)* and LIHA (0000-0003-3963-9875)* conducted data collection, compiled the bibliography, and prepared the introduction. HVS (0000-0002-8059-3701)* and JOV (0000-0002-9686-9135)* compiled and analyzed the results. YBS (0000-0003-3777-4387)* and MACV (0000-0001-7301-1681)* conducted the statistical analysis, the statistical tests, and the radiographical analysis of the results. *ORCID (Open Researcher and Contributor ID).

REFERENCES

- Fitzgerald JA, Newman PH. Degenerative spondylolisthesis. *J Bone Joint Surg Br.* 1976;58(2):184-92.
- Lagarda-Cuevas J, Chdvez-Maqueda MF, Ladewig-Bemidez GI. Singler-segment degenerative lumbar spondylolisthesis treated with an interspinous spacer. *Acta Ortop Mex.* 2014; 28(2):88-94.
- Kalichman L, Hodges P, Li L, Guermazi A, Hunter DJ. Changes in paraspinal muscles and their association with lowback pain and spinal degeneration: CT study. *Eur Spine J.* 2010;19(7):1136-44.
- Hu SS, Tribus CB, Diab M, Ghanayem AJ. Spondylolisthesis and Spondylolysis. *J Bone Joint Surg Am.* 2008;90(3):656-71.
- Schöller K, Alimi M, Cong GT, Christos P, Härtl R. Lumbar Spinal Stenosis Associated With Degenerative Lumbar Spondylolisthesis: Systematic Review and Metaanalysis of Secondary Fusion Rates Following Open vs Minimally Invasive Decompression. *Neurosurgery.* 2017;80(3):355-67.
- Mochida J, Suzuki K, Chiba M. How to stabilize a single level lesion of degenerative lumbar spondylolisthesis. *Clin Orthop Relat Res.* 1999;(368):126-34.
- Bin Abd Razak HR, Dhoke P, Tay KS, Yeo W, Yue WM. Single-Level Minimally Invasive Transforaminal Lumbar Interbody Fusion Provides Sustained Improvements in Clinical and Radiological Outcomes up to 5 Years Postoperatively in Patients with Neurogenic Symptoms Secondary to Spondylolisthesis. *Asian Spine J.* 2017;11(2):204-12.
- Lee KH, Yue WM, Yeo W, Soeharno H, Tan SB. Clinical and radiological outcomes of open versus minimally invasive transforaminal lumbar interbody fusion. *Eur Spine J.* 2012;21:2265-70.
- Mobbs RJ, Phan K, Malham G, Seex K, Rao PJ. Lumbar interbody fusion: techniques, indications and comparison of interbody fusion options including PLIF, TLIF, MI-TLIF, OLIF/ATP, LLIF and ALIF. *J Spine Surg.* 2015;1(1):2-18.
- Peng CW, Yue WM, Poh SY, Yeo W, Tan SB. Clinical and Radiological Outcomes of Minimally Invasive Versus Open Transforaminal Lumbar Interbody Fusion. *Spine (Phila Pa 1976).* 2009;34(13):1385-9.
- Wu MH, Dubey NK, Li YY, Lee CY, Cheng CC, Shi CS et al. Comparison of minimally invasive spine surgery using intraoperative computed tomography integrated navigation, fluoroscopy, and conventional open surgery for lumbar spondylolisthesis: a prospective registry-based cohort study. *Spine J.* 2017;17(8):1082-90.
- Vazan M, Gempt J, Meyer B, Buchmann N, Ryang YM. Minimally invasive transforaminal lumbar interbody fusion versus open transforaminal lumbar interbody fusion: a technical description and review of the literature. *Acta Neurochirurgica.* 2017;159(6):1137-46.
- Phan K, Rao PJ, Kam AC, Mobbs RJ. Minimally invasive versus open transforaminal lumbar interbody fusion for treatment of degenerative lumbar disease: systematic review and meta-analysis. *Eur Spine J.* 2015;24(5):1017-30.
- Hu W, Tang J, Wu X, Zhang L, Ke B. Minimally invasive versus open transforaminal lumbar fusion: a systematic review of complications. *Int Orthop.* 2016;40(9):1883-90.
- Assaker R, Zairi F, Allaoui M. Minimally Invasive Transforaminal Lumbar Interbody Fusion (TLIF): Indications and Techniques. In: Pinheiro-Franco J, Vaccaro A, Benzel E, Mayer H (eds). *Advanced Concepts in Lumbar Degenerative Disk Disease.* Berlin: Springer; 2016. p. 503-512.
- Adogwa O, Parker SL, Bydon A, Cheng J, McGirt MJ. Comparative effectiveness of minimally invasive versus open transforaminal lumbar interbody fusion: 2-year assessment of narcotic use, return to work, disability, and quality of life. *J Spinal Disord Tech.* 2011;24(8):479-84.