

Epithelial-myoeplithelial carcinoma in the ventral surface of the tongue

Felipe Rodrigues de Matos¹, João Luiz de Miranda², Ana Teresinha Marques Mesquita³, Cássio Roberto Rocha Santos⁴, Roseana de Almeida Freitas⁵

Keywords: salivary glands, tongue, tongue neoplasms.

INTRODUCTION

Myoepithelial-epithelial carcinoma (MEC) is a low malignancy grade neoplasia which has a prevalence of 1% to 2% among all primary tumors of the salivary gland¹. It has a higher incidence at 60 years of age. About 60% of the patients are females. The parotid gland is the most often reported anatomical site; nonetheless, other sites have been reported, such as the submandibular gland, minor salivary glands, paranasal sinus, trachea, lacrymal gland and nasal cavity^{1,2,3}. Rare are the instances in which this tumor involves the tongue¹. Clinically speaking, the well outlined swelling is the only signal, associated or not with pain¹.

Microscopic findings reveal a solid tubular growth which is usually made up of a group of internal epithelial cells with eosinophilic cytoplasm and another group of external myoepithelial cells (MC) with clear cytoplasm^{1,4,5}.

CASE REPORT

A 48 female, Caucasian patient came to our stomatology clinic on September of 2002, complaining of a growth on her tongue. During the interview she reported she had been feeling a discomfort in the region for a month. During intraoral examination we noticed a normal-looking mucosa, with normal color, without any visible change. However, during

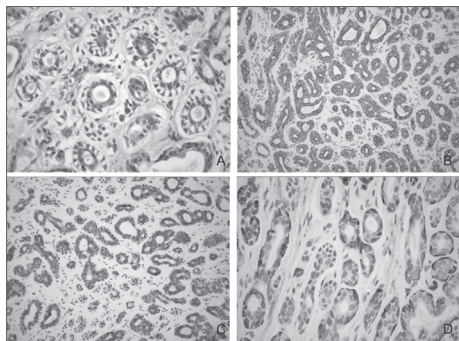


Figure 1. Histopathology findings - (A) Parenchyma with ductiform structures, made up of internal cells with eosinophilic and cubic cytoplasm and the external layer made up of clear cells - HE; (B) Immunopositiveness for CK 7 - SABC; (C) Immunopositiveness for CK 8 - SABC; (D) Immunopositiveness for SMA - SABC.

palpation we felt an endophytic nodular, soft lesion, measuring approximately 1cm. The diagnostic hypothesis was lypoma. We did an excisional biopsy. During microscopy with HE dye, we noticed that the specimen had ductiform structures in its parenchyma, made up of internal cells with eosinophilic and cubic cytoplasm and an external layer made up of clear cells (Fig. 1A). In the immunohistochemistry, the internal cells of the ductiform structures were positive for cytokeratin (CK) 7 (Fig. 1B) and 8 (Fig. 2C), thus being epithelial cells. The external cells were reactive to the smooth muscle actin (SMA) antibody (Fig. 2D), showing the phenotype of myoepithelial cells. The histopathological diagnosis was MEC. The patient was then referred to the Oncology Clinic, and the physician decided for not doing another surgery, but rather to observe her. Nonetheless, the patient had a recurrence on August of 2006, four years after the first surgery and she was submitted only to a new surgery with safety margins. In three years of follow up there was no recurrence noticed.

DISCUSSION

MEC is a rare malignant tumor of the salivary gland^{1,2,3}. The patient is 48 years old, which is below the mean age of incidence³. Clinically, it can happen both in the minor as well as in the greater salivary glands^{2,3}. The case here deals on a tongue belly MEC, which are rare in this site¹. Localized swelling is the only clinical sign, which can lead the physician towards a diagnosis of a benign³ or malignant¹ lesion. So far, there are no reports on the association of risk factors such smoking, alcohol and radiations in the development of MEC^{1,3}.

The MEC diagnosis is based on the light microscopy and was confirmed by immunohistochemistry^{1,4,5}. In this cases, the microscopic findings were important as per described in the literature.

As far as treatment goes, most of authors agree on surgical excision with proper safety margins, preservation and, in some cases, adjuvant radiotherapy when there is difficulty in outlining the surgical margins^{1,3,6}. Because of the very rarity of the lesion, we

do not have a clear cut protocol for recurrences, and the only thing that is done is a new surgical intervention with patient close follow up^{1,3}. In the case hereby presented, we did an excisional biopsy and four years after the first procedure the patient developed a recurrence, and the second procedure was done with proper safety margins.

FINAL REMARKS

It is mandatory to be aware of cases, such as the one presented here, so as not to underestimate tongue lesions and include neoplasia among differential diagnosis so that the surgical approach can be as accurate as possible. In cases of recurrence, the patient must be educated on the fact that it is a rare lesion which needs long follow up.

REFERENCES

1. Kumai Y, Ogata N, Yumoto E. Epithelial-myoeplithelial carcinoma in the base of the tongue: a case report. *Am J Otolaryngol Head Neck Surg.* 2006;27: 58-60.
2. Chetty R. Intercalated duct hyperplasia: possible relationship to epithelial-myoeplithelial carcinoma hybrid tumours of salivary gland. *Histopathology.* 2000;37:260-3.
3. Senis L, Sahuquillo E, Davó R, Hamad P, Flória LM, Baquero M. Carcinoma epitelial-mioepitelial de glândulas salivares: comportamento, diagnóstico y tratamiento. *Med Oral.* 2002;7:391-5.
4. Grenko RT, Abendroth CS, Davis AT, Levin RJ, Dardick I. Hybrid tumors or salivary gland tumors sharing common differentiation pathways? Reexamining adenoid cystic and epithelial-myoeplithelial carcinomas. *Oral Surg Oral Med Oral Pathol Oral Radiol Endod.* 1998;86:188-95.
5. Seethala RR, Barnes EL, Hunt JL. Epithelial-myoeplithelial carcinoma. A review of the clinicopathologic spectrum and immunophenotypic characteristics in 61 tumors of the salivary glands and upper aerodigestive tract. *Am J Surg Pathol.* 2007;31:44-57.
6. Yamada H, Kawaguchi K, Yagi M, Morita Y, Mishima K, Uno K, et al. Epithelial-myoeplithelial carcinoma of the submandibular gland with a high uptake of 18F-FDG: a case report and image diagnosis. *Oral Surg Oral Med Oral Pathol Oral Radiol Endod.* 2007;104:243-8.

¹ DDS. MSc. Student in Oral Pathology.

² PhD in Oral Pathology – Professor at the Federal University of the Jequitinhonha and Mucuri river valleys.

³ MSc in Stomatology, Professor at the Federal University of the Jequitinhonha and Mucuri river valleys.

⁴ PhD in Maxillo-Facial Surgery, Professor at the Federal University of the Jequitinhonha and Mucuri river valleys.

⁵ PhD in Oral Pathology. Professor of the Graduate Program in Oral Pathology – Federal University of Rio Grande do Norte.

Universidade Federal do Rio Grande do Norte

Send correspondence to: Dra. Roseana de Almeida Freitas - Departamento de Odontologia - Patologia Oral - Av. Sen. Salgado Filho 1787, Lagoa Nova Natal RN 59056-000.

E-mail: roseana@dod.ufrn.br

Paper submitted to the BJORL-SGP (Publishing Management System – Brazilian Journal of Otorhinolaryngology) on July 8, 2009;

and accepted on December 15, 2009. cod. 6552