



## CASE REPORT

# Closed rhinoseptoplasty in patient with Van der Hoeve-De Klein Syndrome<sup>☆</sup>

## Rinosseptoplastia fechada em portador de síndrome de Van der Hoeve-de Klein

Raíssa Ferreira Gonçalves<sup>a,b,\*</sup>, Rafael Alves Cordeiro<sup>a,c</sup>,  
Charisse Assuane de Araujo Patrício<sup>a,b</sup>, Camila Atallah Pontes da Silva<sup>b,c</sup>,  
Priscila Bogar Rapoport<sup>a,b,c</sup>

<sup>a</sup> Faculdade de Medicina do ABC, Santo André, SP, Brazil

<sup>b</sup> Associação Brasileira de Otorrinolaringologia e Cirurgia Cervicofacial (ABORLCCF), São Paulo, SP, Brazil

<sup>c</sup> Hospital das Clínicas, Faculdade de Medicina, Universidade de São Paulo (USP), São Paulo, SP, Brazil

Received 13 September 2012; accepted 15 December 2012

## Introduction

Osteogenesis imperfecta (OI) is a genetic disorder of the connective tissue caused by defective synthesis of type I collagen.<sup>1</sup> It is a rare disease, with one case per 15,000 to 20,000 live births, and its prevalence is one in 200,000 individuals.<sup>2</sup> The most remarkable characteristic of this condition is the occurrence of multiple fractures resulting from minor trauma. In some patients, it is also associated with facial disproportion, requiring surgical interventions for esthetic and functional reasons.<sup>3</sup>

Van der Hoeve-de Klein (VHK) syndrome occurs in patients with osteogenesis imperfecta who have brittle bones, blue sclerae, and conductive hearing loss.<sup>4</sup> According to the Sillence classification, this is a more benign and usual form of OI, occurring in approximately 70% of cases.<sup>2</sup>

In the literature, there are few reports of nasal surgeries in patients with genetic bone disorders. Regarding osteogenesis imperfecta, only three cases of rhinoseptoplasty have been reported in this group of patients.

The authors report the case of a patient with VHK syndrome undergoing a closed rhinoseptoplasty to repair bone deformities and improve esthetic and respiratory conditions (Fig. 1).

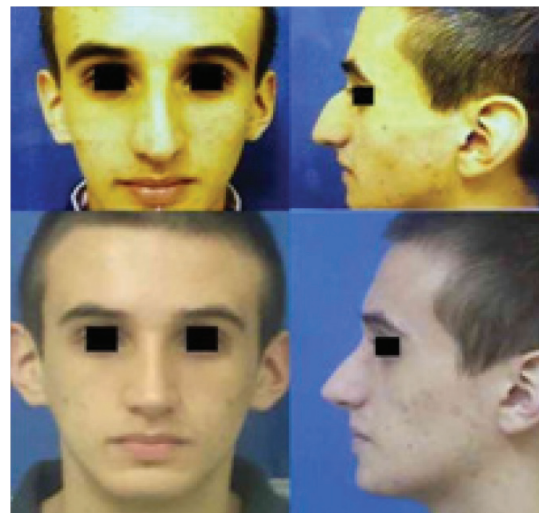


Figure 1 Upper, preoperative anterior and left lateral views; lower, postoperative anterior and left lateral views.

<sup>☆</sup>Please cite this article as: Gonçalves RF, Cordeiro RA, Patrício CAA, Silva CAP, Rapoport PB. Closed rhinoseptoplasty in patient with Van der Hoeve-De Klein Syndrome. Braz J Otorhinolaryngol. 2014;80:270-1.

\* Corresponding author.

E-mail: raissa\_goncalves@hotmail.com (R.F. Gonçalves).

## Case presentation

ECMS, a 16-year-old white male patient, was attended to at the otorhinolaryngology clinic with esthetic complaints regarding his prominent nasal bridge, nightly snoring, and oral respiration. He described a history of multiple bone fractures and also reported a medical and familial history of osteogenesis imperfecta. Physical examination revealed blue sclerae, nasal septum deviation to the right, and prominent nasal bridge. Otoscopy was bilaterally normal. Audiometry, demonstrated a moderate bilateral symmetrical and flat conductive dysacusis, with an air-bone gap of 30 dB, a speech recognition rate of 100%, and a speech reception threshold of 50 dB bilaterally.

A closed rhinoseptoplasty was performed with a 4-mm excision from the osteocartilaginous bridge. The tip was managed via delivery with a 3-mm domal lateralization and the placement of a columellar strut from a septal source, secured with an intercrural suture. Furthermore, a bilateral nasal splint was applied, and lateral and paramedian osteotomies were performed. Nasal bones and the frontal process of the maxilla were not easily fractured during osteotomies, nor were they comminuted.

The surgery was uneventful. A careful fixation of the nasal cartilage and limited mobility of nasal bones were maintained for ten days. The postoperative course occurred with good fracture healing and high patient satisfaction level, assessed by the rhinoplasty outcomes evaluation (ROE) questionnaire.<sup>5</sup> Every question was answered prior to the surgery, resulting in a score of 37.5. Six months after the surgery, the questionnaire was again applied, and the score was 87.5, which was considered an excellent outcome according to the scale.

## Discussion

Despite the fact that rhinoplasty is one of the most common surgical procedures throughout the world, guidelines regarding nasal surgeries in patients with bone disorders are lacking. In the literature, only three cases of rhinoseptoplasty were reported in patients with osteogenesis imperfecta, with two of them reported before 1977, and the third in

2000. In this third case, greenstick fractures were chosen instead of complete osteotomies.<sup>6</sup> The current case consists of a closed rhinoseptoplasty with greenstick osteotomies, in which the difficulty of fracture and removal of the osteocartilaginous nasal bridge matched that of a patient free of disease. The bone healing was confirmed by tomography and the patient's satisfaction level was considered excellent according to the ROE questionnaire.

## Final comments

A successful closed rhinoplasty was demonstrated in a patient with VHK syndrome, with the performance of osteotomies. Despite the demineralized and thin bone structure typical of the disease, bone healing occurred within the expected time, with good functional and esthetic outcomes.

## Conflicts of interest

The authors declare no conflicts of interest.

## References

1. Quisling RW, Moore GR, Jahrsdoerfer RA, Cantrell RW. Osteogenesis imperfecta: a study of 160 family members. *Arch Otolaryngol Head Neck Surg.* 1979;105:207-11.
2. Sillence DO, Senn A, Danks DM. Genetic heterogeneity in osteogenesis imperfecta. *J Med Genet.* 1979;16:101-16.
3. Ormiston IW, Tideman H. Orthognathic surgery in osteogenesis imperfecta: a case report with management. *J Craniomaxillofac Surg.* 1995;23:261-5.
4. Fukuda Y, Baleeiro EM, Souza Junior AA, Resnik RK, Ganaça MM, Almeida CR, et al. Principais síndromes e doenças osteocartilaginosas com participação auditiva e/ou vestibular. *Braz J Otorhinolaryngol.* 1974;40:83-8.
5. Arima LM, Velasco LC, Louzeiro RS. Avaliação de Resultados em Rinoplastia de Redução. *Intl Arch Otorhinolaryngol.* 2011;15:79-83.
6. Bilkay U, Tiftikcioglu YO, Mezili C. Management of nasal deformity in osteogenesis imperfecta. *J Craniofac Surg.* 2010;21:1465-7.