

# COVID-19 Associated Mucormycosis with Newly Diagnosed Diabetes Mellitus in Young Males – A Tertiary Care Experience

Sahil Kapoor<sup>1</sup>  Poonam Kumar Saidha<sup>1</sup>  Ayushi Gupta<sup>1</sup>  Urvi Saini<sup>1</sup>  Sneha Satya<sup>2</sup> 

<sup>1</sup>Department of Otorhinolaryngology, Faculty of Medicine and Health Sciences, Shree Guru Gobind Singh Tricentenary University, Haryana, India

<sup>2</sup>Department of Anesthesia, Faculty of Medicine and Health Sciences, Shree Guru Gobind Singh Tricentenary University, Gurugram, Haryana, India

Address for correspondence Ayushi Gupta, MS ENT, Department of ENT, FMHS, SGT University, Gurugram, Haryana, 122505, India (e-mail: [gayushi818@gmail.com](mailto:gayushi818@gmail.com)).

Int Arch Otorhinolaryngol 2022;26(3):e470–e477.

## Abstract

**Introduction** Patients with a history of or active COVID-19 infection are predisposed to the development of opportunist bacterial and fungal infections. A rising incidence of a rare occurring fungal infection earlier, called mucormycosis, has been reported in abundance across the globe since March 2021, especially in India just as the second wave of COVID-19 began, caused by the trifecta of hyperglycemia (new-onset or exacerbation of pre-existing diabetes), oxygen therapy (invasive or noninvasive ventilation), and prolonged intake of steroids.

**Objective** The present study aimed at assessing the prevalence of post-COVID mucormycosis in males of younger age group and spread of rhino-orbital-cerebral mucormycosis (ROCM).

**Methods** A case-control study was performed over a period of 3 months among 60 male patients with confirmed diagnosis of mucormycosis. Individuals < 40 years old were included in the case group ( $n = 30$ ), while those > 40 years old were included as controls ( $n = 30$ ). Disease spread was assessed in three types of ROCM, that is, rhinomaxillary, rhino-orbital, and rhino-orbito-cerebral mucormycosis.

**Results** In the control group, the mean age was 48.47 years old, the mean HbA1c was  $10.62 \pm 1.88\%$ , with most of them suffering from rhino-orbital mucormycosis. In the case group, the mean age was 31.57 years old, with a mean HbA1c of  $10.11 \pm 2.46\%$ , and most patients had rhinomaxillary mucormycosis. The duration of steroid intake and mode of oxygen therapy were found to be significant in the severity of ROCM.

**Conclusion** Rising cases of post-COVID mucormycosis have brought to light the fatal consequences of prolonged use of steroids and oxygen therapy towards the development and spread of ROCM among young and middle-aged males.

## Keywords

- ▶ mucormycosis
- ▶ COVID-19
- ▶ SARS-CoV-2
- ▶ opportunistic infections

received  
October 19, 2021  
accepted after revision  
March 20, 2022

DOI <https://doi.org/10.1055/s-0042-1748927>.  
ISSN 1809-9777.

© 2022. Fundação Otorrinolaringologia. All rights reserved.  
This is an open access article published by Thieme under the terms of the Creative Commons Attribution-NonDerivative-NonCommercial-License, permitting copying and reproduction so long as the original work is given appropriate credit. Contents may not be used for commercial purposes, or adapted, remixed, transformed or built upon. (<https://creativecommons.org/licenses/by-nc-nd/4.0/>)  
Thieme Revinter Publicações Ltda., Rua do Matoso 170, Rio de Janeiro, RJ, CEP 20270-135, Brazil

## Introduction

With the emergence of SARS-CoV-2 in 2019, COVID-19 disease has been plaguing the masses all over the world. Apart from acute respiratory distress syndromes (ARDS), immunosuppression caused by SARS-CoV-2 decreases CD4 + T and CD8 + T cell counts, predisposing COVID-19 patients to other opportunistic infections.<sup>1</sup> A variety of bacterial and fungal infections have been found to be associated with COVID-19, especially in diabetic, immunocompromised, or severely ill patients.<sup>2</sup> Opportunistic fungal infections, especially mucormycosis post-Covid-19 infection, have been reported in alarming numbers during the current second wave of the pandemic.<sup>3</sup> Mucormycosis is an acute, invasive and potentially life-threatening fungal infection caused by ubiquitous, saprophytic, and filamentous fungal species belonging to the Mucorales order.<sup>4,5</sup> This is a highly aggressive disease with a tendency for contiguous spread and poor prognosis, requiring prompt diagnosis and emergency treatment.<sup>4,6</sup> Globally, the incidence of mucormycosis varies from 0.005 to 1.7 per million individuals, with a fatality rate of 46%.<sup>7,8</sup> A total of 0.14 per 1,000 cases have been reported among the Indian population, that is, 80 times higher than those of developed countries.<sup>9</sup>

Hypoxia, diabetes mellitus, new-onset hyperglycemia, steroid-induced hyperglycemia, metabolic acidosis, diabetic ketoacidosis, increased ferritin levels, decreased phagocytic activity of white blood cells due to immune suppression, and other immunosuppressive conditions such as hematologic malignancies, transplant recipients, neutropenia, and corticosteroid therapy along with prolonged hospitalization with or without mechanical ventilators facilitate Mucorales spores to germinate in people with COVID-19, leading to the development of mucormycosis.<sup>10,11</sup> Inhalation of airborne spores of *Rhizopus*, *Mucor*, and *Rhizomucor* upon interaction with ketone reductase enzyme aids the growth of these organisms in glucose-rich, acidic environments.<sup>12</sup>

Mucormycosis is primarily seen among patients in the intensive care unit (ICU) and can be fatal. Clinically, greyish-black pigmentation in the nose or in the oral cavity with symptoms of blockage of the nasal cavity, jaw or dental pain, nasal block, or epistaxis often appear first. This may be followed by involvement of the eyes and the cheeks, causing facial swelling or pain, eye swelling or pain, visual disturbances like double vision, restriction of eye movements, or sudden vision loss. As the disease spreads, it can cause severe headache, altered sensorium, and fever, indicating involvement of the brain as well.<sup>13</sup> On nasal endoscopy, blackish discoloration or necrotic eschar over the nasal turbinates, blackish foul-smelling crusts, or avascular pale nasal mucosa are seen. Oral examination with biopsy from suspected areas of ulceration or blackish discoloration over the palate or the upper alveolus or loosening of teeth is seen if the maxilla is involved. Complete ophthalmology and neurological evaluation should also be performed. On the basis of various sites involved, there are six clinical forms: Rhino-orbito-cerebral, pulmonary, gastrointestinal, cutaneous, disseminated, and miscellaneous.<sup>14</sup> Most of these patients initially present with

symptoms similar to those of acute bacterial sinusitis, but rapid worsening occurs with vision abnormalities, facial edema, and necrotic areas in the nose, the paranasal sinuses, the orbit, the face, or intraorally, indicating acute invasive fungal sinusitis. Orbit involvement is seen in between 66 and 100% of the cases.<sup>15</sup>

Due to the rapid progression and destructive nature of the infection, a suspected case of mucormycosis requires urgent intervention.<sup>16</sup> The diagnosis of mucormycosis is often difficult, since it depends on recognizing disease patterns and the available diagnostic tools, which differ between the regions of the world.<sup>16</sup> Contrast-enhanced magnetic resonance imaging (MRI) of the paranasal sinuses, the orbit, and the brain is the investigation of choice, showing ischemia and non-enhancement, isointense or hypointense lesions in the involved paranasal sinuses and turbinates (black turbinate sign).<sup>14</sup> Potassium hydroxide (KOH) mount and fungal cultures show aseptate ribbon-like fungal hyphae.<sup>14</sup> The management of mucormycosis differs between healthcare settings; however, the mainstay treatment remains surgical debridement combined with antifungal therapy. Intravenous liposomal amphotericin-B (5–10 mg/kg/day) is the first-line antifungal drug, and the second-line antifungal drug used as salvage therapy is intravenous or oral posaconazole, given over a course of 4 to 6 weeks. Strict glycemic control is of utmost importance since diabetes mellitus is an independent risk factor for both severe COVID-19 and mucormycosis.<sup>16</sup>

Given the rise in cases of mucormycosis in the current COVID-19 scenario, new-onset diabetes mellitus has been reported in most of these patients.<sup>3,11</sup> We undertook this study to highlight the effects of COVID-19 infections and steroid therapy in the development of mucormycosis with new-onset of diabetes mellitus, especially in younger male populations.

## Aims and Objectives

1. To study the prevalence of post-COVID mucormycosis in young adult males with new-onset diabetes mellitus.
2. To analyze the role of steroids and oxygen therapy in the spread of ROCM.
3. To study the interval period between COVID-19 infection and mucormycosis.

## Materials and Methods

The present case-control study was undertaken by the Department of ear, nose, and throat (ENT) at a tertiary care center in Haryana, India, after obtaining clearance from the Institutional Ethical Committee. Over a period of 3 months, 60 cases of mucormycosis who presented to the ENT Out Patient Department (OPD) and to the emergency department were included in the present study.

## Inclusion Criteria

1. Male patients.
2. Age group ranging from 18 to 60 years old.

3. History of COVID-19 infection.
4. Patients with newly diagnosed diabetes mellitus.
5. Confirmed diagnosis of mucormycosis on KOH mount and contrast enhanced MRI suggestive of invasive fungal sinusitis.

### Exclusion Criteria

1. Age < 18 years old and > 60 years old.
2. Patients with pre-existing diabetes mellitus.
3. Patients diagnosed with mucormycosis with no history of COVID-19 infection.
4. Coexisting comorbidities such as heart disease, thyroid disease, hypertension.

Patients < 40 years old were included in the case group (Group A), and those > 40 years old were included in the control group (Group B). Detailed history and ENT examination were performed for all patients along with ophthalmology, dental, and neurological evaluation. Diagnostic nasal endoscopy was performed in all patients, and significant features such as discoloration of the nasal mucosa, blackish secretions along with the status of the turbinates, and any other nasal pathologies were noted. The provisional diagnosis of mucormycosis according to the KOH mount was confirmed by histopathology and radiological imaging (contrast-enhanced MRI). The comparison between the case and control groups (Groups A and B) was performed on the basis of HbA1c level, history of steroid intake, route and duration of steroid intake, requirement and mode of oxygen supplementation, time duration between COVID-19 infection and mucormycosis, and disease spread on the basis of the site involved. On the basis of presenting features and the sites involved, patients in the present study were broadly classi-

fied into 3 groups: Rhino-orbital, rhino-orbito-cerebral, and rhinomaxillary mucormycosis (–Table 1). All patients underwent surgical debridement under general anesthesia. Postoperatively, intravenous antifungal liposomal amphotericin-B (300mg/kg body weight/day dose up to a cumulative dose of 3 g) and oral antifungal posaconazole (loading dose of 1,200 mg; 300 mg/day for 4 days, followed by a maintenance dose of 100 mg/day for 3 months), along with antibiotics, were given.

### Statistical Analysis

The data was collected in Microsoft Office Excel 2010 (Microsoft Corporation, Redmond, WA, USA). All statistical analyses were performed with IBM SPSS 22.0 Statistics for Windows (IBM Corp., Armonk, NY, USA). The qualitative data were expressed in numbers and percentages for categorical variables and the quantitative data were expressed as mean and standard deviations (SDs) for continuous variables. The difference in proportion was analyzed by using the chi-squared and the Fischer exact tests. The difference in the mean among the groups was analyzed using the Mann-Whitney U-test and analysis of variance (ANOVA). A p-value < 0.05 was considered statistically significant.

### Result

The present case-control study was performed among 60 male patients divided into 2 groups: the case group (Group A), in which 30 patients in the age group between 18 and 40 years old (mean age of 31.57 years old) were observed, and the control group (Group B), comprised of 30 patients in the age group between 40 and 60 years old (mean age of 48.47 years old). The mean HbA1c level in Group A was

**Table 1** Types of mucormycosis categorized based on clinical presentation to assess disease spread

Type of mucormycosis	Rhino-orbital (n = 22)	Rhino-orbital-cerebral (n = 8)	Rhinomaxillary (n = 30)
<i>Clinical features</i>	Headache	Altered sensorium	Palatal necrosis
	Nasal discharge	Ophthalmoplegia	Dental pain
	Nasal bleeding	Vision loss	Loosening of teeth
	Nasal congestion	Corneal anesthesia	
	Sinus tenderness	Facial anhidrosis	
	Retro-orbital headache	Contralateral hemiplegia	
	Facial (periorbital) swelling		
	Facial palsy		
	Facial numbness		
	Eye pain		
	Lacrimation		
	Proptosis		
	Vision loss		
	Diplopia		
	Bulbar palsy		
	Restricted ocular movement		

**Table 2** Correlation with age

Variables		Case group (Group A)	Control group (Group B)	p-value
		≤ 40 years old (n = 30)	> 40 years old (n = 30)	
HbA1c level		10.11 ± 2.46	10.62 ± 1.88	0.273
History of steroid intake	Yes	23 (76.67%)	23 (76.67%)	1.000
	No	7 (23.33%)	7 (23.33%)	
Disease spread based on the site involved	Odontogenic mucormycosis	19 (63.33%)	11 (36.67%)	0.025*
	Rhino-orbital mucormycosis	9 (30%)	13 (43.33%)	0.121
	Rhino-orbito-cerebral mucormycosis	2 (6.67%)	6 (20%)	0.100
Duration of steroid intake (in days)		12.26 ± 4.72	14.47 ± 4.49	0.068
Route of steroid intake	Injectable (n = 26)	12 (40%)	14 (46.67%)	0.551
	Oral (n = 20)	11 (36.37%)	9 (30%)	
Oxygen support required	Yes	16 (53.33%)	20 (66.67%)	0.291
	No	14 (46.67%)	10 (33.33%)	
Where did you receive oxygen	Hospital	13 (43.33%)	13 (43.33%)	0.170
	At home	3 (10%)	7 (23.33%)	
Mode of oxygenation/ ventilation	Oxygen supplementation	11 (36.67%)	9 (30%)	0.086
	BIPAP/NIV	5 (16.67%)	6 (20%)	
	Ventilator	0	5 (16.67%)	
Time duration between COVID-19 infection and mucormycosis		28.00 ± 10.55	30.3 ± 10.02	0.415

Abbreviations: BIPAP, bilevel positive airway pressure; NIV, non-invasive ventilation.

10.11 ± 2.46%, while in group B it was 10.62 ± 1.88%. A total of 46 patients reported a history of steroid intake for COVID-19 treatment, equally distributed among both the case and control groups. A total of 26 patients took steroid intravenously and 20 patients took steroids orally. A total of 36 patients required oxygen support during their COVID-19 treatment, out of which 20 received oxygen supplementation, 11 were on BIPAP/NIV, and 5 patients were on ventilator. A total of 26 patients received oxygen therapy while their treatment for COVID-19 in the hospital and 10 received oxygen supplementation at home. On comparing the study variables between Groups A and B (→ **Table 2**), we found that rhinomaxillary mucormycosis was more common (63.33%) in group A (< 40 years old; *p* = 0.025); while rhino-orbital mucormycosis was more common (43.33%) in group B (between 40 and 60 years old; *p* = 0.121).

To assess the spread of the disease, the study population was divided into 3 categories, namely rhinomaxillary mucormycosis (*n* = 30), rhino-orbital mucormycosis (*n* = 22), and rhino-orbito-cerebral mucormycosis (*n* = 8). → **Table 3** shows the correlation between these categories based on the study variables, where the correlation of age with rhinomaxillary mucormycosis (44.9 ± 8.75 years old), with rhino-orbital mucormycosis (33.45 ± 6.38 years old), and rhino-orbito-cerebral mucormycosis (39.75 ± 13.48 years old) was found to be significant (*p* = 0.0001). Other variables that were found to be significant upon correlation among the 3 categories were mean HbA1c level (*p* = 0.003), mean duration of

steroid intake in days (*p* = 0.014), and oxygen supplementation during COVID-19 treatment (*p* = 0.009). We also observed that the mode of oxygenation received during COVID-19 treatment was found to have a significant correlation with the type of mucormycosis (*p* = 0.005). However, a history of steroid intake and the mean duration between COVID-19 infection and mucormycosis showed no significant correlation neither among the case and control groups nor among the 3 categories of disease spread.

### Discussion

In recent years, a significant change has been observed in the epidemiology of mucormycosis. The rise in incidence of this highly morbid and fatal disease has been seen globally, but it is higher in Asian countries.<sup>17</sup> What was earlier a rare occurrence has now become one of the widespread and common diseases in the wake of the COVID-19 pandemic. While the first wave of COVID-19 led to mucormycosis cases in 2020 with not many cases being reported, the second wave in 2021 led to a multifold rise in cases of mucormycosis.<sup>18</sup> As of June 7, 2021, India recorded its highest number (28,252) of mucormycosis cases, out of which 24,370 cases had a history of COVID-19 and 17,601 cases had a history of diabetes.<sup>13</sup> A total of 1,719 cases were recorded in the Haryana state in India.<sup>19</sup> On May 15, mucormycosis was declared as a notified disease under section 2 of the Epidemic Diseases Act 1897.<sup>20</sup> It is an aggressive and potentially fatal infection more

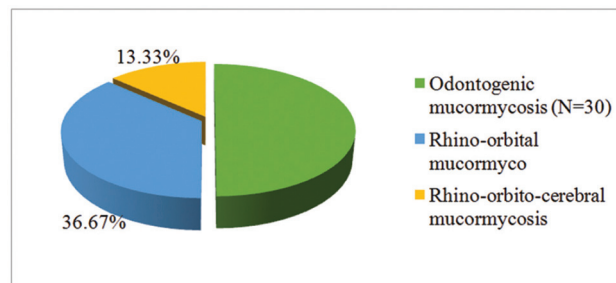
**Table 3** Correlation of types of mucormycosis

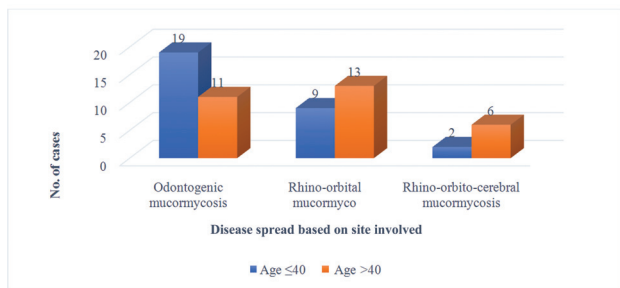
Variables		Odontogenic mucormycosis (n = 30)	Rhino-orbital mucormycosis (n = 22)	Rhino-orbito-cerebral mucormycosis (n = 8)	p-value
Age (years old)		44.9 ± 8.75	33.45 ± 6.38	39.75 ± 13.48	< 0.0001*
HbA1c level		10.78 ± 2.16	9.25 ± 1.71	11.88 ± 2.21	0.003*
History of steroid intake	Yes	20 (66.67%)	18 (81.82%)	8 (100%)	0.108
	No	10 (33.33%)	4 (18.18%)	0	
Oxygen support required	Yes	13 (43.33%)	15 (68.18%)	8 (100%)	0.009*
	No	17 (56.67%)	7 (31.82%)	0	
Route of steroid intake	Injectable	9 (30%)	11 (50%)	6 (75%)	0.136
	Oral	11 (36.67%)	7 (31.82%)	2 (25%)	
	None	10 (33.33%)	4 (18.18%)	0	
Duration of steroid intake		12.15 ± 3.46	12.88 ± 5.31	17.62 ± 3.88	0.014*
Where did you receive oxygen	Hospital	7 (23.33%)	11 (50%)	8 (100%)	0.071
	At home	6 (20%)	4 (18.18%)	0	
Mode of oxygenation/ventilation	Oxygen supplementation	10 (33.33%)	8 (36.36%)	2 (25%)	0.005*
	BIPAP /NIV	2 (6.67%)	7 (31.82%)	2 (25%)	
	Ventilation	1 (33.33%)	0	4 (50%)	
Time duration between COVID-19 infection and mucormycosis		28.6 ± 10.61	31.00 ± 9.98	26.12 ± 10.07	0.481

commonly observed in immunocompromised patients. Diagnostic procedures such as diagnostic nasal endoscopy, histopathological examination, and radiological imaging positively impact clinical outcomes in patients with mucormycosis, including improved survival. However, the poor availability and accessibility of resources for diagnostic and therapeutic options has reduced the survival rates of mucormycosis patients in underdeveloped and developing countries. It is surprising how the causative organism also varies geographically. *Rhizopus arrhizus* has been isolated as the commonest agent for mucormycosis worldwide; however *Apophysomyces variabilis* is predominant in Asia and the *Lichtheimia* species in Europe. *Rhizopus homothallicus*, *Mucor irregularis*, and *Thamnostylum lucknowense* are now being reported from Asia.<sup>17</sup> An entire spectrum ranging from sinonasal, rhinomaxillary, rhino-orbital, and rhino-orbito-cerebral disease (with central nervous system [CNS] involvement) depends upon the area of involvement of the fungal infection.<sup>21</sup> *Rhizopus Oryzae* accounts for 90% of the rhino-orbito-cerebral (ROCM) form. Most patients in the present study presented with the rhino-maxillary type (50%), followed by the rhino-orbital and rhino-orbito-cerebral types (—Fig. 1). A systematic review of 101 cases reported from India until May 2021 was performed by Singh et al. and reported a 78.9% male predominance among both active and recovered cases of COVID-19, 80% of whom had diabetes mellitus and 76.3% reported having a history of corticosteroid intake for the treatment of COVID-19.

Ismaiel et al<sup>22</sup> found that the incidence of post-COVID-19 mucormycosis was statistically significant in the older age group (58.38 ± 12.2 years old), while in our study the incidence was common in the younger age group, with a mean age of 40.01 ± 10.09 years old. As shown in —Fig. 2, we observed that rhinomaxillary mucormycosis was more common in the case group (≤ 40 years old), while rhino-orbital mucormycosis was common in the control group.

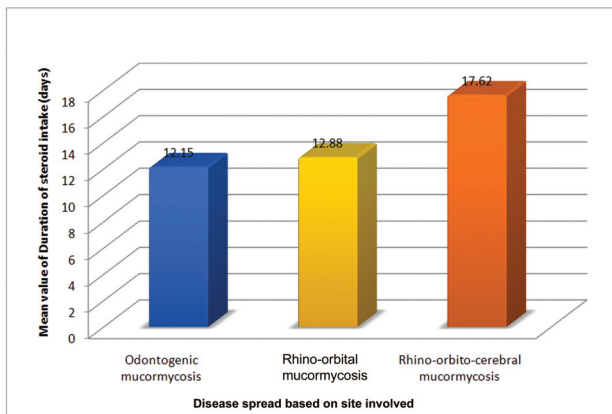
According to the literature, there are several risk factors that can lead to the development of mucormycosis, but diabetes mellitus overshadows all the other risk factors especially in Asian countries like India and China. Post-tuberculosis and chronic renal failure have also emerged in recent times. On the other hand, hematological malignancies and organ transplants have been documented as the common predisposing factors of mucormycosis in Europe and in

**Fig. 1** Incidence of different types of mucormycosis based on clinical features and sites involved.



**Fig. 2** Correlation of age with type of mucormycosis.

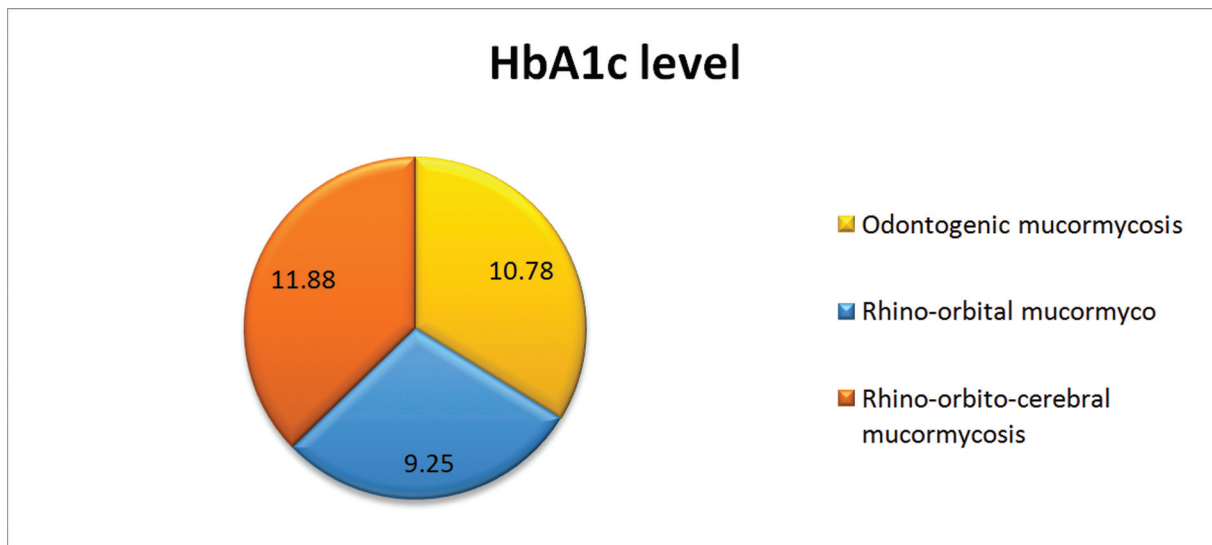
the United States.<sup>17</sup> Interestingly, diabetes mellitus has been a known predisposing factor for both COVID-19 and ROCM. In a multicenter study from India, diabetes was reported in 77% of the cases of ROCM. Around 80 to 100% of the cases of ROCM were reported as presenting with diabetes as a risk factor.<sup>22</sup> John et al. conducted a review in which 41 confirmed cases of mucormycosis were reported in patients with COVID-19, of which 93% had diabetes mellitus and 88% received corticosteroids.<sup>23</sup> These findings were similar to those of Singh et al.<sup>11</sup> However, with the ongoing epidemic of ROCM in the COVID-19 pandemic,<sup>13</sup> not only pre-existing or known diabetics but also new onset or acute onset diabetes has been reported. New onset hyperglycemia and acute metabolic decompensation of pre-existing diabetes have emerged as a complication of COVID-19. SARS-CoV-2 enters the pancreatic β cells by expressing ACE-2 receptors, impairing pancreatic insulin secretion, thus triggering new onset diabetes mellitus. Contributing factors toward insulin resistance are increased levels of IL-6 and TNF-α along with corticosteroids.<sup>24</sup> In our study, 60 cases of confirmed mucormycosis had a history of COVID-19 infection and were diagnosed with diabetes for the first time (mean HbA1c of 10.37%). There was no significant statistical difference ( $p=0.273$ ) between the case ( $10.11 \pm 2.46\%$ ) and the control group ( $10.62 \pm 1.88\%$ ). The main defense mechanism of the body against the existing Mucorales in the environment is based on chemotaxis



**Fig. 4** Duration of steroid intake is found to be directly proportional to the spread and severity of rhino-orbital-cerebral mucormycosis.

and oxidative and nonoxidative fungicidal mechanism of phagocytic cells, which get hampered in hyperglycemic states. However, acidosis along with hyperglycemia helps Mucorales to acquire the readily available free iron in the serum, enhancing, in turn, their virulence.<sup>13</sup> Varying HbA1c levels have been noted amongst the three types of mucormycosis. (→Fig. 3) It is important to highlight here that diabetes mellitus with ketoacidosis is the commonest reported risk factor in non-COVID-19 mucormycosis. Between 54 and 76% of these cases have been reported in India, Iran, and Mexico.<sup>25</sup>

In critically ill patients, such as those with severe COVID-19, the use of dexamethasone had been recommended by the National Institute of Health in those requiring supplemental oxygen or ventilation. But this, in turn, predisposed these patients to the risk of developing secondary infections.<sup>26</sup> However, a rampant use of steroids was seen during the second wave of COVID-19, which led to steroid-induced hyperglycemia in many previously nondiabetic patients, making them exceptionally vulnerable to the development



**Fig. 3** Mean HbA1c levels in different types of rhino-orbital-cerebral mucormycosis.

of mucormycosis. Ahmadikia et al. said that an interval of ~ 20 days was found between dexamethasone therapy and the occurrence of mucormycosis as a noticeable risk factor, but this was not significant enough to prove an association between the two variables.<sup>6</sup> In our study, the time interval between COVID-19 infection and the occurrence of mucormycosis was  $31.36 \pm 10.58$  days. There was no statistically significant difference between the two age groups in our study or among the types of mucormycosis (→ **Tables 2 & 3**) to form an association between the two variables. However, the total duration for which steroids were taken during the COVID-19 treatment when assessing the different types of ROCM was significant. (→ **Fig. 4**)

Another association found between COVID-19 and mucormycosis is the mode of spread of infection through the inhalational route, making the nose and the paranasal sinuses the primary sites for the development of mucormycosis. The fear of aerosol generation and airborne transmission of SARS-CoV-2 while performing examination of oral and nasal cavities and during surgical procedures has led to delayed clinical examination and diagnosis, thereby increasing the risk of development of advanced mucormycosis.<sup>27</sup> Prolonged hospital stay, especially for patients in the ICU with invasive or noninvasive ventilation with severe cases of COVID-19, is more likely to predispose patients to the development of fungal coinfections.<sup>18</sup> Khatri et al. stated that presence of fungal spores in this type of equipment may contribute towards the development of hospital-acquired mucormycosis.<sup>28</sup> Most of our mucormycosis patients received oxygenation in a hospital setup during their COVID-19 treatment. However, there was no significant statistical difference between those who received ventilation at hospital or at home ( $p = 0.170$ ). As rightly stated by Sarkar et al., doctors treating COVID-19 need to be more vigilant and mindful while prescribing corticosteroids or immunosuppressants for any other illness. It is also important to make a periodical check and maintenance of the air quality in hospital wards and oxygen therapy machines to prevent the inoculation of spores.<sup>13,29</sup> Training ICU technicians to change flow meters frequently and to sterilize the oxygen tubing is necessary.<sup>13</sup>

## Conclusion

The fatal combination of COVID-19 and mucormycosis has been increasing in alarming numbers across the globe, especially among the Indian population, with male predominance. As the virus exhibited mutations in the second wave of COVID-19, affecting most young and middle-aged people with severe forms of the illness and prolonged hospital stays. It was among many of these patients that the trifecta of hyperglycemia (new-onset or exacerbation of pre-existing diabetes), oxygen therapy (invasive or noninvasive ventilation), and prolonged misuse of corticosteroids that brought about the rise of cases of mucormycosis in these immunocompromised patients. Manifold reasons play a role in the development and spread of mucormycosis in COVID-19 infected and recovered patients. A multidisciplinary ap-

proach including prompt diagnosis, treatment with intravenous and oral antifungals, and surgical debridement along with medical management of underlying conditions is of utmost importance to fight this epidemic of mucormycosis in COVID-19 pandemic.

### Ethics Clearance

Clearance was obtained from the Institutional Ethics Committee.

### Conflict of Interests

The authors have no conflict of interests to declare.

## References

- 1 Yang W, Cao Q, Qin L, et al. Clinical characteristics and imaging manifestations of the 2019 novel coronavirus disease (COVID-19): A multi-center study in Wenzhou city, Zhejiang, China. *J Infect* 2020;80(04):388–393. Doi: 10.1016/j.jinf.2020.02.016
- 2 Nehara HR, Puri I, Singhal V, Iy S, Bishnoi BR, Sirohi P. Rhinocerebral mucormycosis in COVID-19 patient with diabetes a deadly trio: Case series from the north-western part of India. *Indian J Med Microbiol* 2021;39(03):380–383. Doi: 10.1016/j.ijmmb.2021.05.009
- 3 Bashar MA. Mucormycosis infection in COVID-19 patients in India: An emerging lethal threat. *J Clin Ophthalmol* 2021;5(04):433–434
- 4 Hoang K, Abdo T, Reinersman JM, Lu R, Higuaita NIA. A case of invasive pulmonary mucormycosis resulting from short courses of corticosteroids in a well-controlled diabetic patient. *Med Mycol Case Rep* 2020;29:22–24. Doi: 10.1016/j.mmcr.2020.05.008
- 5 Badali H, Cañete-Gibas C, McCarthy D, et al. Epidemiology and Antifungal Susceptibilities of Mucoralean Fungi in Clinical Samples from the United States. *J Clin Microbiol* 2021;59(09):e0123021. Doi: 10.1128/JCM.01230-21
- 6 Ahmadikia K, Hashemi SJ, Khodavaisy S, et al. The double-edged sword of systemic corticosteroid therapy in viral pneumonia: A case report and comparative review of influenza-associated mucormycosis versus COVID-19 associated mucormycosis. *Mycoses* 2021;64(08):798–808. Doi: 10.1111/myc.13256
- 7 Jeong W, Keighley C, Wolfe R, et al. The epidemiology and clinical manifestations of mucormycosis: a systematic review and meta-analysis of case reports. *Clin Microbiol Infect* 2019;25(01):26–34. Doi: 10.1016/j.cmi.2018.07.011
- 8 Werthman-Ehrenreich A. Mucormycosis with orbital compartment syndrome in a patient with COVID-19. *Am J Emerg Med* 2021;42:264.e5–264.e8
- 9 Chander J, Kaur M, Singla N, et al. Mucormycosis: Battle with the Deadly Enemy over a Five-Year Period in India. *J Fungi (Basel)* 2018;4(02):46. Doi: 10.3390/jof4020046
- 10 Hamilos G, Samonis G, Kontoyiannis DP. Pulmonary mucormycosis. *Semin Respir Crit Care Med* 2011;32(06):693–702. Doi: 10.1055/s-0031-1295717
- 11 Singh AK, Singh R, Joshi SR, Misra A. Mucormycosis in COVID-19: A systematic review of cases reported worldwide and in India. *Diabetes Metab Syndr* 2021;15(04):102146. Doi: 10.1016/j.dsx.2021.05.019
- 12 Chatterjee P. Mucormycosis in Context of the COVID-19 Pandemic. *Acta Scientific Otolaryngology*. 2021;3(06):135–136
- 13 Mahalaxmi I, Jayaramayya K, Venkatesan D, et al. Mucormycosis: An opportunistic pathogen during COVID-19. *Environ Res* 2021;201:111643. Doi: 10.1016/j.envres.2021.111643
- 14 Ajith A. Mucormycosis - The Dark Shadow of Coronavirus. *Acta Scientific Otolaryngology*. 2021;3(06):101–102
- 15 Sabobeh T, Mushtaq K, Elsotouhy A, Ammar AA, Rashid S. Invasive rhinocerebral mucormycosis in a patient with liver cirrhosis

- leading to fatal massive stroke. *Med Mycol Case Rep* 2018; 22:69–73
- 16 Cornely OA, Alastruey-Izquierdo A, Arenz D, et al; Mucormycosis ECMM MSG Global Guideline Writing Group. Global guideline for the diagnosis and management of mucormycosis: an initiative of the European confederation of medical mycology in cooperation with the mycoses study group education and Research consortium. *Lancet Infect Dis* 2019;19(12):e405–e421
  - 17 Prakash H, Chakrabarti A. Global Epidemiology of Mucormycosis. *J Fungi (Basel)* 2019;5(01):26
  - 18 Singh A, Gupta A. Surviving Mucormycosis: Impact on Psychological Well-Being and Quality of Life. *Acta Scientific Otolaryngology*. 2021;3(07):90–92
  - 19 Covid-19 Associated Mucormycosis. National Centre for Disease Control Directorate General of Health Services, Government Of India. 2230179/2021/O/O IDSP-NCDC. June 2021. <https://ncdc.gov.in/index1.php?lang=1&level=1&sublinkid=183&lid=97>
  - 20 Saini M. 100 days of mucormycosis in Haryana: 1719 new cases, 254 deaths. *The times of India*. Aug 5, 2021 <https://timesofindia.indiatimes.com/city/chandigarh/100-days-of-mucormycosis-in-haryana-1719-cases-254-deaths/articleshow/85054001.cms>
  - 21 Peterson KL, Wang M, Canalis RF, Abemayor E. Rhinocerebral mucormycosis: evolution of the disease and treatment options. *Laryngoscope* 1997;107(07):855–862
  - 22 Ismaiel WF, Abdelazim MH, Eldsoky I, et al. The impact of COVID-19 outbreak on the incidence of acute invasive fungal rhinosinuitis. *Am J Otolaryngol* 2021;42(06):103080. Doi: 10.1016/j.amjoto.2021.103080
  - 23 John TM, Jacob CN, Kontoyiannis DP. When Uncontrolled Diabetes Mellitus and Severe COVID-19 Converge: The Perfect Storm for Mucormycosis. *J Fungi (Basel)* 2021;7(04):298
  - 24 Papachristou S, Stamatou I, Stoian AP, Papanas N. New-Onset Diabetes in COVID-19: Time to Frame Its Fearful Symmetry. *Diabetes Ther* 2021;12(02):461–464. Doi: 10.1007/s13300-020-00988-7
  - 25 Vaezi A, Moazeni M, Rahimi MT, de Hoog S, Badali H. Mucormycosis in Iran: a systematic review. *Mycoses* 2016;59(07):402–415. Doi: 10.1111/myc.12474
  - 26 Mehta S, Pandey A. Rhino-Orbital Mucormycosis Associated With COVID-19. *Cureus* 2020;12(09):e10726. Doi: 10.7759/cureus.10726
  - 27 Klimko NN, Khostelidi SN, Volkova AG, et al. Mucormycosis in haematological patients: case report and results of prospective study in Saint Petersburg, Russia. *Mycoses* 2014;57(Suppl 3):91–96. Doi: 10.1111/myc.12247
  - 28 Khatri A, Chang KM, Berlinrut I, Wallach F. Mucormycosis after Coronavirus disease 2019 infection in a heart transplant recipient - Case report and review of literature. *J Mycol Med* 2021;31(02):101125. Doi: 10.1016/j.mycmed.2021.101125
  - 29 Sarkar S, Gokhale T, Choudhury SS, Deb AK. COVID-19 and orbital mucormycosis. *Indian J Ophthalmol* 2021;69(04):1002–1004