

Extraction of supernumerary teeth in a hospital setting: case report in pediatric dentistry

Exodontia de dentes supranumerários em ambiente hospitalar: relato de caso na Odontopediatria

Anne Caroline de Lima **PAASHAUS**¹  0000-0003-3914-9745

Vanêssa **FAZOLI**¹  0000-0002-1748-1643

Thays Ferreira **GISFREDE**¹  0000-0001-6051-3957

Bruno Pereira das **POSSES**¹  0000-0003-4767-5059

Kelly Maria Silva **MOREIRA**²  0000-0002-1137-3908

Thais **GIMENEZ**³  0000-0002-1528-0370

José Carlos Pettorossi **IMPARATO**¹  0000-0002-1990-2851

ABSTRACT

The diagnosis and treatment of supernumerary teeth pose a challenge for dental clinicians and pediatric dentists. These teeth are asymptomatic and may cause the delayed eruption of the permanent dentition, altered bone growth and ectopic positioning. This paper reports a case of the surgical removal of supernumerary teeth in the anterior region of the maxilla of a child under general anesthesia in a hospital setting. A six-year-old female patient visited a private dental office in the city of Garanhuns, Brazil, accompanied by her mother, who reported a tooth with a "strange shape" in the anterior region as the main complaint and also reported that her daughter's first dental experience was negative. The clinical examination and imaging tests were performed under general anesthesia to confirm the diagnosis. In view of the patient's dental and behavioral history, surgical treatment was performed in a hospital setting and assisted by a multidisciplinary team. Care in the hospital setting was found to be feasible, providing greater comfort for uncooperative patients.

Indexing terms: Pediatric dentistry. Surgery, oral. Tooth, supernumerary.

RESUMO

Os dentes supranumerários representam um desafio para clínicos e odontopediatras quanto ao diagnóstico e tratamento. São assintomáticos, podendo gerar atraso na dentição permanente, alteração do crescimento ósseo e posicionamento ectópico. Assim, o

▼ ▼ ▼ ▼ ▼

¹ Faculdade São Leopoldo Mandic, Instituto de Pesquisas São Leopoldo Mandic, Odontopediatria. Rua José Rocha Junqueira, 13, 13045-755, Swift, Campinas, SP, Brasil. Correspondence to: V FAZOLI. E-mail: <nessafazoli@gmail.com>.

² Universidade Estadual de Campinas, Faculdade de Odontologia de Piracicaba, Departamento de Odontopediatria. Piracicaba, SP, Brasil.

³ Universidade Ibirapuera, Professor titular do Mestrado e Doutorado em Odontologia. São Paulo, SP, Brasil.

▼ ▼ ▼ ▼ ▼

How to cite this article

Paashaus ACL, Fazoli V, Gisfrede TF, Posses BP, Moreira KMS, Gimenez T, et al. Extraction of supernumerary teeth in a hospital setting: case report in pediatric dentistry. RGO, Rev Gaúch Odontol. 2022;70:e20220024. <http://dx.doi.org/10.1590/1981-86372022002420200208>

presente trabalho teve como objetivo apresentar um relato de caso de remoção cirúrgica de dentes supranumerários na região anterior da maxila de um paciente infantil, em ambiente hospitalar sob anestesia geral. O paciente do sexo feminino, 6 anos, compareceu ao consultório apresentando como queixa a presença de um dente "estranho" na região anterior. Foram realizados o exame clínico e exames de imagem com a confirmação do diagnóstico de dentes supranumerários na região do incisivo central superior direito (11) e do incisivo central superior esquerdo (21). Tendo em vista o histórico odontológico e comportamental da paciente, optou-se em realizar o tratamento cirúrgico em ambiente hospitalar, auxiliado por equipe multidisciplinar. Dessa forma, ao final dos procedimentos foi verificado que o atendimento em ambiente hospitalar é viável para maior conforto do paciente não colaborador.

Termos de indexação: Odontopediatria. Cirurgia bucal. Dente supranumerário.

INTRODUCTION

The formation of dental tissues is a delicate, complex phenomenon. Dental abnormalities can occur due to anomalies in the number, size, shape, position or structure of the teeth. Among numerical abnormalities, supernumerary teeth are the most common, the prevalence of which ranges from 0.2 and 3%, with a greater frequency in the male sex [1,2].

The etiology of supernumerary teeth is heterogeneous, highly variable and idiopathic in a large portion of cases [3-5]. This condition is normally asymptomatic and may be diagnosed by a routine radiographic exam [6,7]. Age at diagnosis varies with the diversity of cases due to differences in the number, positioning (straight, inverted, erupted or impacted), shape and size of supernumerary teeth [2]. A radiographic exam and proper collection of the patient history are indispensable to the diagnosis, since this anomaly can have negative consequences [7,8].

The complications of supernumerary teeth are eruption delays, diastemas, cysts, ectopic eruption, root resorption of adjacent teeth, dental crowding, inflamed gums, periodontal abscess, displacement, rotation and pulp necrosis [9-11]. The scientific literature reports numerous treatment options for supernumerary teeth ranging from conservative treatment, such as follow-up, to more invasive methods, such as surgical removal. The latter option requires the evaluation of several factors, including the age of the patient and his/her degree of cooperation [12].

The extraction of a supernumerary tooth should be performed as soon as possible after it is diagnosed. However, very small children may have psychological difficulties accepting a surgical intervention [13-15]. Thus, surgical removal under general anesthesia in a hospital setting may be indicated.

This paper reports the case of the surgical removal of supernumerary teeth in the anterior region of the maxilla of a pediatric patient in a hospital setting.

CASE REPORT

A six-year-old female patient visited a private practice in the city of Garanhuns, Brazil, accompanied by her mother. The main complaint was the presence of a tooth with a "strange shape" in the anterior region. The mother reported that the patient had a history of headaches and that her first dental experience had been negative. The patient had been submitted to an invasive procedure, but the mother was unable to explain what procedure had been performed. The clinical examination revealed a tooth with an enamel abnormality in the region of the left maxillary central incisor (figure 1a).

A panoramic radiograph of the jaw was requested to complement the diagnosis (figure 1b). During the evaluation of the radiograph, two supernumerary teeth were detected in the anterior region, impeding the eruption of teeth 11 and 21. Cone beam computed tomography was requested (figure 1c,d), which confirmed the presence of the two supernumerary teeth causing a delay in the eruption of the permanent teeth. Considering the patient's dental history, the decision was made to perform surgical treatment in a hospital setting with the participation of a multidisciplinary team composed of an anesthesiologist, oral-maxillofacial surgeon and pediatric dentist. After a risk assessment, the patient was cleared for the surgical intervention.

Treatment was performed at a private hospital, where the patient was submitted to general anesthesia. During the procedure, two primary teeth (51 and 52) and the two supernumerary teeth were extracted (figure 2). For such, a palatal incision was made and a piezoelectric device was used for greater safety and precision. There was no need for a bone graft. The post-surgical recommendations included the use of an analgesic, cold foods and habitual cleaning/brushing. Post-operative follow-up was performed and the mother reported no complications. After seven days, the patient was reevaluated and the suture was removed (figure 3a). Further reevaluations were performed 15 and 30 days after surgery. The patient is currently in monthly follow-up until the eruption of the permanent teeth (figure 3b).

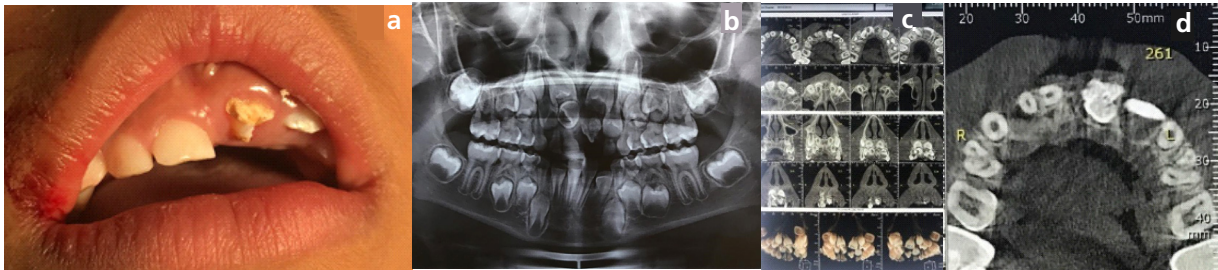


Figure 1. Intraoral image showing tooth with enamel defect in anterosuperior region (a); panoramic radiograph (b); computed tomogram (c) and axial slice (d).

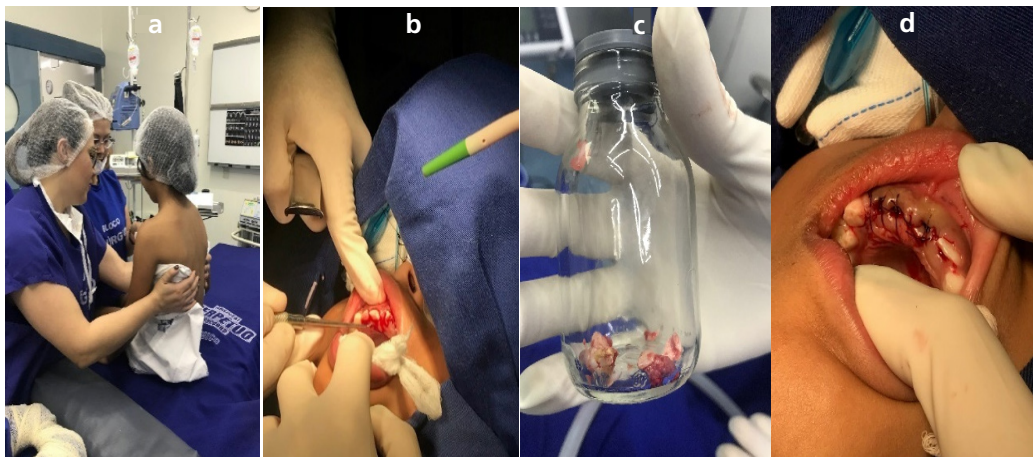


Figure 2. Operatory procedure: receiving patient (a), extraction of supernumerary teeth (b,c) and finalization with suture (d).

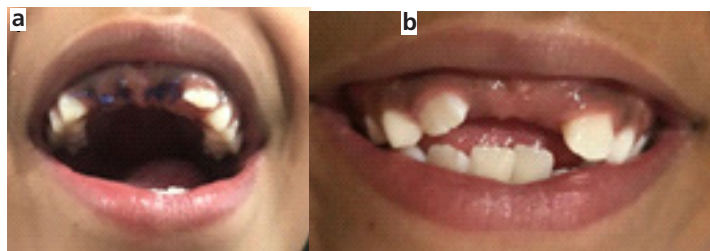


Figure 3. Postoperative follow-up: seven days (a), six months (b).

DISCUSSION

Many studies have investigated the occurrence of numerical dental anomalies in different populations. Variations are found depending on the continent, type of population and race, with higher frequencies among youths and adults.

Supernumerary teeth are considered important dental anomalies that can generate eruption, occlusion and esthetic problems [1,16]. Thus, the early diagnosis and removal of supernumerary teeth, especially those classified as mesiodens, can significantly reduce the occurrence of future complications and the need for orthodontic treatment [17].

This paper reported a case of the late identification of a supernumerary tooth in a young child after the mother sought a specialist due to the occurrence of a tooth with an unusual shape. This is in agreement with data described in the literature, which reports that parents are unable to detect an anomaly in small children because the primary dentition has spaces that enable supernumerary teeth to erupt relatively aligned. Moreover, the first dental appointment generally only occurs when a child already has permanent teeth, which hinders the early diagnosis of this anomaly [1,17].

Divergences are found in the literature regarding sex, as some studies report the predominance of the male sex [7,18], whereas other state that supernumerary teeth are more prevalent in the female sex [11], as occurred in the present report. Thus, there is a need for prevalence studies, as supernumerary teeth affect the most diverse populations.

Regarding location, the maxilla is more affected than the mandible and mesiodens is the most commonly detected type, accounting for 60% of cases, followed by supernumerary teeth in the region of the maxillary incisors [18,19]. However, there are exceptions in which this anomaly is found in the region of the mandibular premolars, involving a larger number of teeth [18]. We describe a case of two supernumerary teeth in the maxilla, which is in line with the more common findings reported in the literature.

The removal of supernumerary teeth is recommended when causing eruption disorders, pathologies or when affecting orthodontic treatment, implants and/or grafts. It is also important to determine the best time for surgical intervention – whether immediate surgery should be performed or whether it is better to wait until the patient is more psychologically prepared. Therefore, the patient's age should be considered, as surgical trauma can have a negative effect [1,12]. Confirming reports in the literature, the patient in the present case exhibited clinical signs suggesting the need for an immediate intervention, as the analysis of the imaging exams revealed the possibility of delays in the eruption chronology and the impaction of the permanent teeth.

The patient exhibited resistance to dental treatment due to previous experiences with trauma reported by the mother. Therefore, the decision was made to perform treatment in a hospital setting to enable greater patient comfort and greater safety for the surgeon during the procedure. As the literature states, general anesthesia and a computed tomographic evaluation eliminate concerns regarding whether a child will cooperate and minimizes the risk of harm to the adjacent permanent teeth during the surgical intervention [17].

After the decision for treatment and orientations given to the parents regarding the procedure, the surgery and postoperative period occurred in a satisfactory manner for both the patient and the health professionals involved in the process. The presence of a multidisciplinary team was valuable to the success of the proposed treatment. What may make this type of care unviable is the high cost of the procedure stemming from the use of a hospital environment and the involvement of several health professionals. Regarding patient comfort, the hospital setting provided positive reinforcement for the behavior of the patient after surgery, enabling her to overcome the trauma of the dental appointment.

CONCLUSION

The surgical intervention of supernumerary teeth in a hospital setting is indicated in cases of an uncooperative patient to ensure the proper execution of the procedure as well as the safety of the both the patient and surgeon.

Collaborators

ACL PAASHAUS, performed clinical care, conducted the case and wrote the article. V FAZOLI, TF GISFREDE and K MOREIRA, assisted in conducting the case and writing the article. BP POSSES, assisted in conducting the case and writing the article. K MOREIRA: Assisted in writing and reviewing the article. T GIMENEZ, assisted in writing and reviewing the article. JCP IMPARATO, assisted in writing and reviewing the article.

REFERENCES

- Moura WLD, Cravinhos JCDP, Moura CDVSD, Freire SADS, Monteiro AMO, Pinheiro SDA, et al. Prevalência de dentes supranumerários em pacientes atendidos no Hospital Universitário da UFPI: um estudo retrospectivo de cinco anos. *Rev Odontol UNESP*. 2013;42(3):167-171.
- Stringhini Junior E, Bento S, Oliveira LB. Dentes supranumerários impactados: relato de caso clínico. *Rev Assoc Paul Cir Dent*. 2015;69(1):89-94.
- Guedes Pinto AC, Myaki I. Manual de odontopediatria. 10ª ed. São Paulo: Ed. Pancast; 1999.
- Albu ŞD, Pavlovici R-C, Imre M, Ion G, Tăncu A, Albu C-C. Phenotypic heterogeneity of non-syndromic supernumerary teeth: genetic study. *Rom J Morphol Embryol*. 2020;61(3):853-861. <https://dx.doi.org/10.47162/RJME.61.3.23>
- Cammarata-Scalisi F, Avendaño A, Callea M. Main genetic entities associated with supernumerary teeth. *Arch Argent Pediatr*. 2018;116(6):437-444. <http://dx.doi.org/10.5546/aap.2018.eng.437>
- Segundo AVL, Faria DLB de, Silva UH da, Vieira ITA. Epidemiologic study of supernumerary teeth diagnosed by panoramic radiography. *Rev Cir Traumatol Buco-Maxilo-Fac*. 2006; 6(2):53-56.
- Corrêa FG, Ferreira FV, Roggia LF, Pistóia AD, Pistóia GD. Prevalência de dentes supranumerários: estudo retrospectivo. *Int J Dent*. 2009;8(1):11-15.
- Jung YH, Kim J-Y, Cho B-H. The effects of impacted premaxillary supernumerary teeth on permanent incisors. *Imaging Sci Dent*. 2016;46(4):251-258. <http://dx.doi.org/10.5624/isd.2016.46.4.251>
- Couto Filho CEG, Santos RL, Lima ARG. Supranumerários: revisão de literatura: relato de casos clínicos. *BCI*. 2002;9(34):150-155.
- Cancio AV, Farias JG, Rodrigues AAA, Gonçalves FMQ, Santos RM. Quarto molar retido: revisão de literatura e relato de casos clínicos. *Rev Int Cir Traumatol Buco-Maxilo-Fac*. 2004;2(8):225-229.
- Sharma A, Singh VP. Supernumerary teeth in Indian children: a survey of 300 cases. *Int J Dent*. 2012;2012:745265. <http://dx.doi.org/10.1155/2012/745265>
- Giotti A, Osorio SG, Kelmer F, Franzin LCS. Supranumerário: diagnóstico e planejamento de um caso clínico. *Braz J Surg Clin Res*. 2014;8(2):37-40.
- Corteleti JF, Ota CM, Sarmento LC, Chisté R, Novaes TF, Imparato JCP. Retenção prolongada de dente decíduo por impactação de dente supranumerário em criança de 12 anos. *Rev Assoc Paul Cir Dent*. 2016;70(3):268-272.
- Bengtson CRG, Bengtson NG, Bengtson AL, Pinheiro SL, Mendes FM. O uso da anestesia geral em odontopediatria. *Rev Inst Ciênc Saúde*. 2006;24(4):319-325.
- Blinkhorn, AS, Kay EJ, Atkinson JM, Millar K. Advice for the dental team on coping with the nervous child. *Dental Update*. 1990;17(10):415-419.
- Bahadure, Rakesh N, Eesha SJ, Vidhi K, Rahul G. Supernumerary teeth in primary dentition and early intervention: a series of case reports. *Case Rep Dent*. 2012; 2012:614652. <http://dx.doi.org/10.1155/2012/614652>
- Shih WY, Hsieh CY, Tsai TP. Clinical evaluation of the timing of mesiodens removal. *J Chin Med Assoc*. 2016; 79(6):345-350. <http://dx.doi.org/10.1016/j.jcma.2015.10.013>
- Oliveira R de, Alves AGC, Marson GBDO, Hasse PN. Remoção cirúrgica de 5 dentes retidos em região anterior de mandíbula em posição ectópica. *Rev Uningá Rev*. 2015;23(3).
- Coelho A, Macho V, Andrade D, Macedo P, Areias C. Prevalência e distribuição de dentes supranumerários numa população pediátrica: um estudo radiográfico. *Rev Port Estomatol Med Dentária Cir Maxilofac*. 2011; 52(4):189-192. <https://doi.org/10.1016/j.rpemd.2011.09.005>

Received on: 23/11/2020

Approved on: 6/2/2021

Assistant editor: Fabiana Mantovani Gomes França