





Relation of Dental Anomalies with Occlusal Alterations in the Pediatric Patients


Tereza Cristina Roschel Giffoni¹, Glenda Zaguini Brandt², Isabela Silva Rocha³, Adilson Luis Ramos⁴, Maria Gisette Arias Provenzano⁵, Marina de Lourdes Calvo Fracasso⁶


¹Post-graduate Program, School of Dentistry, State University of Maringá, Maringá, PR, Brazil.  0000-0003-4086-5327

²School of Dentistry, State University of Maringá, Maringá, PR, Brazil.  0000-0002-9132-4996

³Post-graduate Program, School of Dentistry, State University of Maringá, Maringá, PR, Brazil.  0000-0002-5746-4127

⁴Department of Orthodontics, School of Dentistry, State University of Maringá, Maringá, PR, Brazil.  0000-0003-2505-4251

⁵Department of Pediatric Dentistry, School of Dentistry, State University of Maringá, Maringá, PR, Brazil.  0000-0001-5792-7876

⁶Department of Pediatric Dentistry, School of Dentistry, State University of Maringá, Maringá, PR, Brazil.  0000-0003-1112-3156

Author to whom correspondence should be addressed: Tereza Cristina Roschel Giffoni, Rua Pioneira Regina Marson Badan, 416, Jardim Iguaçú, Maringá, PR, Brazil. 87060-160. Phone: +55 44 99124-2485. E-mail: teris.giffoni@gmail.com.

Academic Editors: Alessandro Leite Cavalcanti and Wilton Wilney Nascimento Padilha

Received: 06 June 2018 / Accepted: 13 March 2019 / Published: 30 March 2019

Abstract

Objective: To identify the dental anomalies that can modify the occlusal characteristics and their distribution in these occlusal alterations in the skeletal patterns of children. **Material and Methods:** We analyzed charts, panoramic and periapical radiographs of children aged 5 to 12 years from 2009 to 2012. The facial pattern was evaluated through subjective face analysis and cephalometric data, as well as the occlusion of patients with and without (control) dental anomalies. The relationship between the presence of dental anomalies and malocclusion was analyzed by the Chi-square test with significance level of 5%. **Results:** 73 children (27.8%) presented dental anomalies, being 49.3% in girls and 50.7% in boys in a total of 88 teeth involved. Anomalies observed in decreasing order were: enamel hypoplasias, eruptive ectopias, agenesis, supernumerary teeth, corono-radicular dilaceration, microdontia, transposition and imperfect amelogenesis. Of these, 22.2% presented associated dental anomalies, whose ectopic eruption with enamel hypoplasia were the most frequently encountered. When comparing the control group with children with dental abnormalities it was observed a significant relationship between the presence of dental anomalies and malocclusion ($p < 0.05$). The most frequent alteration among patients with dental anomalies was deep overbite (24.6%), followed by crowding (23.3%), posterior crossbite (14.2%), anterior open bite (12.9%) and anterior crossbite (0.3%). **Conclusion:** Dental dysgenesis interferes with the development of occlusion and the resulting occlusal problems are distributed differently, taking into account the skeletal facial pattern in patients with and without dental anomalies.

Keywords: Tooth Abnormalities; Tooth, Supernumerary; Malocclusion.

Introduction

The complex and significant biological processes of replacement of deciduous teeth by permanent teeth are observed during the development of the occlusion, being very common in this period to face the presence of dental anomalies, which are expressed in different degrees of severity [1]. Dental anomalies can manifest from the mildest to the most severe, occurring respectively due to the chronological delay in odontogenesis and the complete absence of the dental germ or agenesis [1]. There are a myriad of expressions of dental agenesis, including microdontia, deviations in dental morphology and ectopic [1]. Dental developmental anomalies may have their etiology related by factors of traumatic nature, genetic and environmental factors in particular during the stages of morphodifferentiation or histodifferentiation of dental development, these changes in odontogenesis being characterized as deviations from normality [1-8].

The influence of genetic and environmental factors is also observed in the etiology of malocclusion in children, a subject of great relevance in Orthodontics [9,10]. The greater the genetic contribution in the origin of a dentofacial irregularity, the less the possibility of preventing it and, as a rule the worse the prognosis of orthodontic / orthopedic treatment [11].

Despite the variation of the ethnicities of the population studies, they reveal that the prevalence of hypodontia in the permanent ranges from 2,7 to 10,1%, excluding third molars [7,9, 12-14]. While in the deciduous dentition, the prevalence varies from 0 to 1% [15-17]. Frequently, in one patient, some dental anomalies may appear associated [9,18]. This is due to the fact that the same genetic defect can give rise to different manifestations or phenotypes, including agenesis, microdontia, ectopias and developmental delays [11,18]. Study conducted at the University of Rome reports that the prevalence of dental anomalies was 20.9% where approximately 17.9% showed only one anomaly, 2.7% two anomalies, when only 0.3% had more than two anomalies [7]. There are important clinical implications, especially when they occur in an associated way, and these anomalies may be present in the same individual or in their relatives [9,11,14]. The use of radiographic imaging during clinical dental examination is essential for the early detection of these abnormalities. Since most of these disorders are asymptomatic, panoramic radiographs are essential for diagnosis [1,13,19,20].

Evidence indicates the importance of early diagnosis of dental anomalies, since it favors prognosis, better planning of orthodontic and / or surgical-prosthetic treatment, and may prevent or minimize extensive interventions and / or intercept in problems of development of permanent dentition [6,9,10,15,21]. However, previous studies report only the association and the frequency between dental agenesis and other dental anomalies, and few studies have identified, through evidence, the relation of dental anomalies with malocclusion in the infant patient [8], without considering the findings with the skeletal facial pattern of each child patient.

In view of this, the objective of this study was to identify dental anomalies that alter the occlusal characteristics and the distribution of these occlusal alterations in the children's facial skeletal patterns.

Material and Methods

Study Design and Sample

This retrospective observational study evaluated 562 records of patients between 5 and 12 years of age, of both genders, belonging to the Children's Clinic of the Dentistry Course of the State University of Maringá, from 2009 to 2012. Of this total, 277 children had panoramic radiographs in which 73 dental anomalies were diagnosed in the test group. Children in the same age group and without dental anomalies were randomly selected through clinical and radiographic examination. This sample formed the control group, composed of 76 children with an average age of 8.4 ± 1.8 years.

Data Collection

The registry of the dental anomalies was initially carried out by the collection of the information contained in the medical records and by the radiographic evaluation. For radiographic analysis, the panoramic radiographs made using the orthodontic radiographic method (Gendex Orthoralix 9200) contained in the medical records were used. When necessary, for better detailing of the diagnosis of the anomaly, periapical radiographs were performed for diagnostic purposes.

The records referring to the age group, stage of the dentition and identification of the dental anomaly (s) were recorded and tabulated according to the criterion of scientific research [2,3], with the exception of the criterion of distal angulation of the second premolar: number anomalies (hypodontia and hyperdontia), shape (root lacerations, supernumerary root incisors, lateral conoid incisors and taurodontism), size (microdontia and macrodontia), eruption (impaction, transposition, ectopic eruption, and ankylosis) and structure (enamel hypoplasia and imperfect amelogenesis). Hypodontia was recorded only after the possibility of early exodontia being discarded.

The upper lateral incisor was considered with microdontia when the greater mesiodistal diameter of the crown was smaller compared to the same dimension of the lower lateral incisor in the same patient [22]. The third molars were excluded from this investigation due to the age of the patients that constituted the sample of this research.

After the radiographic evaluation, a clinical exam was performed by a single trained examiner, with the aid of the light from the equipment reflector, probe and mirror. In this clinical examination, the following occlusal features were analyzed: overbite, overjet, dental crowding, overbite, anterior and posterior cross bite, anterior open bite and midline deviation. For the classification of the vertical trespass, the criterion of other research [23] was used, whose vertical overlap would be positive above 4 mm and the anterior open bite would present a negative vertical overlap of at least 1 mm.

In order to characterize the sample, children with dental anomalies were grouped according to the facial pattern of each patient determined through the cephalometric measurements obtained by lateral cephalograms, which were performed in the dental clinic of the State University of Maringá. To evaluate the maxillo-mandibular relationship, angular measurements were recorded: ANS; SNB

and ANB. For analysis of facial growth, the angle of the mandibular plane, measured by the confluence of the S-N and Go-Gn lines, was measured. To determine whether the patient was Class II or Class III skeletal, $ANB > 4$ and $ANB < 2$, respectively were considered.

To verify the error of the method, the cephalograms were randomly chosen, the cephalometric points were again demarcated, and the measurements were remeasured using the same methodology. The values obtained in the first and second measurements were submitted to the t test for the systematic error study and to the Dahlberg formula for the evaluation of the casual error. According to the estimation of the method error, no statistically significant differences were detected for the systematic error, while the values of the casual error obtained were within a tolerable limit. The intra-examiner agreement was measured during the data collection, by evaluating approximately 11% of the sample, with a value of 0.84, indicating a variable agreement between good and perfect.

Data Analysis

Data were analyzed using IBM SPSS Statistics Software, version 11 (IBM Corp., Chicago, IL, USA). Descriptive statistics were used to calculate the absolute and relative frequencies. The relationship between the presence of dental anomalies and malocclusion was analyzed by the Chi-square test with significance level of 5%.

Ethical Aspects

In accordance with the determination of the Brazilian National Health Council, this study was approved by the Permanent Committee on Ethics and Research involving Human Beings of the State University of Maringa (Protocol No. 260/2011) and all procedures followed were in accordance with the Helsinki Declaration.

Results

Of the 277 children with panoramic radiographs, 73 children (27.8%) presented dental anomalies, being 49.3% in girls ($n = 36$) and 50.7% in boys ($n = 37$) in a total of 88 teeth involved, since 16 children presented more than one teeth affected by some anomaly. Table 1 corresponds to the prevalence of the abnormalities, and Table 2 shows the prevalence of the different dental anomalies was distributed according to the gender.

Table 1. Distribution of types of dental anomalies.

Types of Dental Anomalies	N	%
Enamel Hypoplasia	27	9.7
Ectopic Eruption	21	7.5
Agnesys	14	5.0
Supranumerary	6	2.1
Dilaceration Corono-Root	5	1.8
Microdontia	3	1.0
Macrodontia	2	0.7

Ankylosis	2	0.7
Impactation	2	0.7
Transposition	2	0.7
Tooth Fusion	2	0.7
Supranumerary Root	1	0.3
Amelogenesis Imperfecta	1	0.3

Table 2. Distribution of the prevalence of dental anomalies according to gender.

Types of Dental Anomalies	Female		Male		Total	
	N	%	N	%	N	%
Enamel Hypoplasia	11	25.5	16	35.5	27	30.6
Ectopic Eruption	10	23.2	11	24.4	21	23.8
Agenesys	9	21.0	5	11.1	14	15.9
Supranumerary	0	0.0	6	13.3	6	6.8
Dilaceration Corono-Root	1	2.3	4	9.0	5	5.6
Microdontia	2	4.6	1	2.2	3	3.4
Macrodontia	2	4.6	0	0.0	2	2.2
Ankylosis	2	4.6	0	0.0	2	2.2
Impactation	2	4.6	0	0.0	2	2.2
Transposition	1	2.3	1	2.2	2	2.2
Tooth Fusion	2	4.6	0	0.0	2	2.2
Supranumerary Root	0	0.0	1	2.2	1	1.1
Amelogenesis Imperfecta	1	2.3	0	0.0	1	1.1

Considering the distribution of dental anomalies according to the age group, it was observed that children between 5 and 6 years of age did not present dental anomalies. Dental anomalies were observed in children aged 7 to 8 years, 9 to 10 years and 11 and 12 years, with a percentage of 21.9% (n = 16), 46.5% (n = 34) and 31, 5% (n = 23), respectively. The age with the highest prevalence for dental anomalies was between 9 and 10 years during the intertransitory period of the mixed dentition (Figure 1).

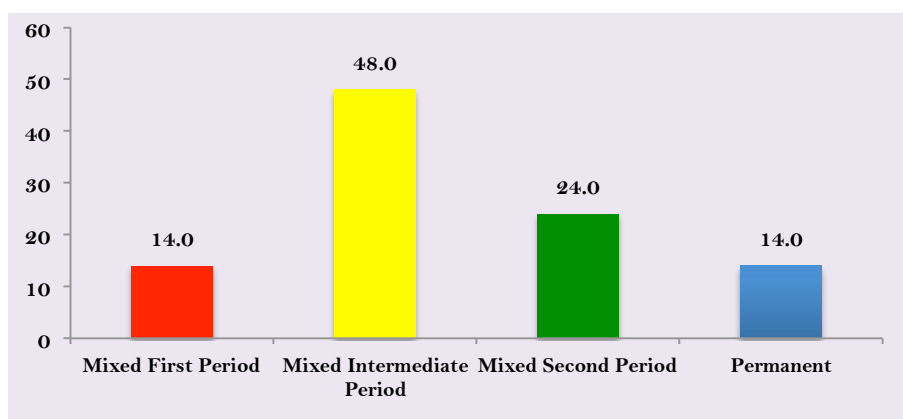


Figure 1. Distribution of patients with dental anomalies according to the stage of development of the dentition.

Table 3 expresses the analysis of occlusal alterations, considering the control groups and group with abnormalities.

Table 3. Percentage distribution of skeletal and dental alterations according to group.

Skeletal and Dental Changes	Control Group			Anomalies Group		
	Class I	Class II	Class III	Class I	Class II	Class III
Skeletal Class						
Total	57.8	35.5	6.5	31.5	53.4	15.0
Occlusal Changes						
Overbite		18.9			24.6	
Anterior Crossbite		1.2			0.3	
Posterior Crossbite		5.0			14.2	
Anterior Open Bite		11.3			12.9	
Anterior Inferior Crowding		16.4			14.2	

When considering the occlusion of children with dental anomalies, there was a significant relationship between malocclusion and the presence of dental anomalies ($p = 0.0009$) (Table 4).

Table 4. Association between malocclusion and the group involved.

Groups	Malocclusion				p-value
	Absence		Presence		
	N	%	N	%	
G I	60	78.9	16	21.0	0.0009*
G II	36	46.7	41	53.3	

The control group revealed a malocclusion of 21.0%, while the group with dental anomalies revealed 53.3% of children with malocclusion dental anomalies. It was observed that malocclusion occurred in 37.0% of the agenesis. Children with ectopic eruption presented malocclusion in 28.5%, characterized mainly by posterior crossbite, with a Class II molar relationship.

The most frequent alteration among patients with dental anomalies was deep overbite (> 4 mm) in 24.6% of the patients, followed by crowding (23.3%), posterior crossbite (14.2%), anterior open bite (12.9%) and the least frequent was anterior crossbite (0.3%).

Discussion

The prevalence of dental anomalies has been observed through routine clinical and imaging exams and may show variations between studies [2,7,13,16,17,19,20]. It is believed that the prevalence may be influenced by the racial differences and the diagnostic criteria used in the studies [24].

The dental anomalies, in this study, did not happen to the deciduous dentition. In addition, there was a greater occurrence of dental anomalies of structure (enamel hypoplasia), a result different from that observed in the literature, whose number anomalies are the most pointed [24]. This difference may have occurred because some studies use a research methodology restricted to the radiographic aspects, without inclusion of the structure changes.

As for the anomalies of number, in the agenesis it was observed predilection by the feminine gender. The lower second premolars were the most commonly affected teeth (50%), followed by the upper lateral incisors (27.7%) and the lower lateral incisors, (16.6%). In 33.3% of the patients, an agenesis was found bilaterally. The agenesis index in our study (5.05%) was like another research

carried out with Brazilian children (6.5%) [19], but far from that found by other studies [25-27]. Agensis may also be associated with other dental malformations such as taurodontism, transposition, microdontia, ectopic eruption and supernumerary teeth [1,3,6,18,21]. Supernumerary teeth are teeth that exceed the normal serial number [28]. Six children with supernumerary (2.1%) were registered as one mesiodens. The number found differs significantly of previous findings [20] (1.1%), but corroborates with the the results obtained in Rio de Janeiro, Brazil (2.8%) [13].

Ectopic irruption corresponds to the deviation from the usual path of eruption of the tooth, which commonly occurs in the maxillary canines and first permanent molars [29,30]. In this study, ectopic irruption reached 27.9% of the sample, a finding that was discordant with the study with Indian population [4] (7.9%) and Saudi Arabia children [16] (2.3%). In 4% of the children, the upper first molar "errates" its trajectory, with an irruptive deviation in the mesial direction, promoting the partial resorption of the root of the second deciduous molars [30], a change observed in this study in 47.6% of all ectopias found.

Transposition is a positional anomaly and can present itself in complete and incomplete form. In this study, the only condition found was incomplete transposition, when the teeth were not in a totally changed position [12]. Only two patients (0.7%) presented incomplete transposition, results that approximated the studies with Brazilian's children, who found percentages of 0.2% and 0.9%, respectively, for incomplete transposition [8,12,20].

Considering size anomalies, microdontia occurred in only 1% of the upper lateral incisor anomalies, very similar to the findings of this researcher [21]. Several studies suggest a genetic and hereditary tendency in the etiology of dental anomalies of number, size, position, as well as in eruption disorders [11,22]. Microdontia is on the list of genetically regulated anomalies and is often associated with agensis and ectopic eruptions. The reduction in tooth size represents a partial expression of the same genetic defect that defines agensis. This explains the classic association between unilateral superior lateral incisor agensis and contralateral tooth microdontia [11]. This event occurred in 40% of the sample studied.

Dental anomalies can be easily detected by careful routine inspection in orthodontic diagnostic records and their management should be considered in the treatment plan. Moreover, data indicate that 40.3% of orthodontic patients may present at least one type of anomaly [8,10,21,29]. However, there are few studies that associate dental anomalies and occlusal features in children. In our study, when comparing the control group with children with dental anomalies, there was a significant relationship between the presence of dental anomalies and occlusal alterations.

In some studies [8,10,21,29] it was tested whether there was an association between dental anomalies and malocclusions. Study conducted in 2015 observed that Class II division 2 malocclusions are closely related to congenital dental anomalies and that Class III patients show a significant increase in the levels of congenital dental anomalies that patients with Class II division 1 [9].

However, there are no reports of studies that mention occlusal alterations of dental anomalies and their relationship with the skeletal facial pattern of each patient. In our study, it was

observed that children with dental anomalies present a higher occurrence of malocclusion compared to both the control group, very close to that observed in a previous study [29]. However, in the Class II skeletal pattern, the values of the group with dental anomalies were higher in relation to the control group. In the Class III skeletal pattern, the control group presented a small difference of occurrence compared to the previously published study [29], but with a higher occurrence when compared to the group of anomalies.

Considering the records of the present study, it is possible to infer the importance of early diagnosis of dental anomalies, considering the important clinical implications in the development of occlusion, since it favors orthodontic intervention at the appropriate moment [8,10,21,29]. Among the advantages of early identification of dental anomalies are the economic benefits, since intercepting the malocclusions in a timely manner reduces the cost of subsequent orthodontic treatment [18] because malocclusions are frequently present in children, both in deciduous dentition and mixed dentition. Among the limitations of the present study, one can point out the difficulty in comparing the present findings with other studies, caused by the methodological differences and the multifactorial etiological aspects that comprise the malocclusion, as well as the expansion of the sample.

Conclusion

Dental anomalies interfere in the development of occlusion, and early diagnosis for the planning of orthodontic approaches in the most appropriate period is fundamental. Occlusal changes within the Class II skeletal facial pattern are more frequent in patients with abnormalities than in patients in the control group. Occlusal changes within the Class I skeletal pattern are more frequent in patients in the control group than in patients with abnormalities. Occlusal changes within the Class III skeletal pattern are more frequent in patients with abnormalities than in patients without abnormalities.

Financial Support: None.

Conflict of Interest: The authors declare no conflicts of interest.

References

- [1] Medina A, Del Pozo R, Cedres LB. Radiographic assessment of dental maturation in children with dental agenesis. *J Clin Pediatr Dent* 2016; 40(3):227-34 <https://doi.org/10.17796/1053-4628-40.3.227>
- [2] Bacetti T. A controlled study of associated dental anomalies. *Angle Orthod* 1998; 68(3):267-74.
- [3] Garib DG, Peck S, Gomes SC. Increased occurrence of dental anomalies associated with second-premolar agenesis. *Angle Orthod* 2009; 79(3):436-41. <https://doi.org/10.2319/021308-87.1>
- [4] Gupta T, Manuja N. Bilateral fusion of primary mandibular incisors: A rare case report. *J Clin Diagn Res* 2015; 9(12):ZJ01. <https://doi.org/10.7860/JCDR/2015/16077.6933>
- [5] Sajnani AK, King NM. Dental anomalies associated with buccally- and palatally-impacted maxillary canines. *J Investig Clin Dent* 2014; 5(3):208-13. <https://doi.org/10.1111/jicd.12035>
- [6] Citak M, Cakici EB, Benkli YA, Cakici F, Bektas B, Buyuk SK. Dental anomalies in an orthodontic patient population with maxillary lateral incisor agenesis. *Dental Press J Orthod* 2016; 21(6):98-102. <https://doi.org/10.1590/2177-6709.21.6.098-102.oar>

- [7] Laganà G, Venza N, Borzabadi-Farahani A, Fabi F, Danesi C, Cozza P. Dental anomalies: Prevalence and associations between them in a large sample of non-orthodontic subjects, a cross-sectional study. *BMC Oral Health* 2017; 17(1):62. <https://doi.org/10.1186/s12903-017-0352-y>
- [8] Pedreira FR, de Carli ML, Pedreira RP, Ramos PS, Pedreira MR, Robazza CR, et al. Association between dental anomalies and malocclusion in Brazilian orthodontic patients. *J Oral Sci* 2016; 58(1):75-81. <https://doi.org/10.2334/josnurd.58.75>
- [9] Isman E, Isman O, Aktan AM, Ciftci E, Topcuoglu T. Multiple tooth anomalies in a nonsyndromic patient with class II division 2 malocclusions: A case report and a literature review. *Niger J Clin Prac* 2015; 18(4):563-8. <https://doi.org/10.4103/1119-3077.154225>
- [10] Dwijendra KS, Parikh V, George SS, Kukkunuru GT, Chowdary GN. Association of dental anomalies with different types of malocclusions in pretreatment orthodontic patients. *J Int Oral Health* 2015; 7(6):61-4.
- [11] Shahid M, Balto HA, Al-Hammad N, Joshi S, Khalil HS, Somily AM, Sinjilawi NA, et al. Mutations in MSX1, PAX9 and MMP20 genes in Saudi Arabian patients with tooth agenesis. *Eur J Med Gen* 2016; 59(8):377-85. <https://doi.org/10.1016/j.ejmg.2016.06.004>
- [12] Gebert TJ, Palma VC, Borges AH, Volpato LER. Dental transposition of canine and lateral incisor and impacted central incisor treatment: A case report. *Dental Press J Orthod* 2014; 19(1):106-12. <https://doi.org/10.1590/2176-9451.19.1.106-112.oar>
- [13] Coutinho TCL, Tostes MA, Santos MEO, Bastos VAS. Dental anomalies in children: A radiographic survey. *Rev Odontol Univ São Paulo* 1998; 12(1):51-55. <https://doi.org/10.1590/S0103-06631998000100009>
- [14] Polder BJ, Van't Hof MA, Van der Linden FP, Kuijpers-Jagtman AM. A meta-analysis of the prevalence of dental agenesis of permanent teeth. *Community Dent Oral Epidemiol* 2004; 32(3):217-26. <https://doi.org/10.1111/j.1600-0528.2004.00158.x>
- [15] Temilola DO, Folayan MO, Fatusi O, Chukwumah NM, Onyejaka N, Oziegbe E, et al. The prevalence, pattern and clinical presentation of developmental dental hard-tissue anomalies in children with primary and mix dentition from Ile-Ife, Nigeria. *BMC Oral Health* 2014; 14:125. <https://doi.org/10.1186/1472-6831-14-125>
- [16] Yassin SM. Prevalence and distribution of selected dental anomalies, among Saudi children in Abha, Saudi Arabia. *J Clin Exp Dent* 2016; 8(5):e485-90. <https://doi.org/10.4317/jced.52870>
- [17] Lochib S, Indushekar kR, Saraf BG, Sheoran N, Sardana D. Occlusal characteristics and prevalence of associated dental anomalies in the primary dentition. *J Epidemiol Glob Health* 2015; 5(2):151-7. <https://doi.org/10.1016/j.jegh.2014.07.001>
- [18] Peck S, Peck L, Kataja M. Concomitant occurrence of canine malposition and tooth agenesis: Evidence of orofacial genetic fields. *Am J Orthod Dent Orthop* 2002; 122(6):657-60. <https://doi.org/10.1067/mod.2002.129915>
- [19] Girondi JR, Pereira MF, Campos PSF, Panella J. Study of the prevalence of dental development anomalies in a population sample through panoramic x-rays. *Rev Odontol Univ Cid São Paulo* 2006; 18(1):15-21.
- [20] Lee KB, Campos PSF, Panella J, Arita ES. Estudo da prevalência de anomalias dentárias de desenvolvimento, através de radiografias panorâmicas, numa amostra populacional da cidade de São Paulo: Parte II. *Rev Pós Grad* 2005; 12(1):85-93. [In Portuguese]
- [21] Higashihori N, Takada J, Katayanagi M, Takahashi Y, Moriyama K. Frequency of missing teeth and reduction of mesiodistal tooth width in Japanese patients with tooth agenesis. *Prog Orthod* 2018; 19(1):30. <https://doi.org/10.1186/s40510-018-0222-4>
- [22] Garib DG, Alencar BM, Ferreira FV, Ozawa TO. Associated dental anomalies: The orthodontist decoding the genetics, which regulates the dental development disturbances. *Dental Press J Orthod* 2010; 15(2):138-57. <https://doi.org/10.1590/S2176-94512010000200017>
- [23] Almeida MR, Pereira ALP, Almeida RR, Almeida-Pedrin RR, Silva Filho OG. Prevalence of malocclusion in children aged 7 to 12 years. *Dental Press J Orthod* 2011; 16(4):123-31. <https://doi.org/10.1590/S2176-94512011000400019>
- [24] Baron C, Houchmand-Cuny M, Enkel B, Lopez-Cazaux S. Prevalence of dental anomalies in French orthodontic patients: A retrospective study. *Arch Pediatr* 2018; 25(7):426-30. <https://doi.org/10.1016/j.arcped.2018.07.002>

- [25] Uslu O, Akcam M, Evirgen S, Cebeci L. Prevalence of dental anomalies in various malocclusions. *Am J Orthod Dent Orthop* 2009; 135(3):328-35. <https://doi.org/10.1016/j.ajodo.2007.03.030>
- [26] Kim YH. Investigation of hypodontia as clinically related dental anomaly: Prevalence and characteristics. *ISRN Dent* 2011; 2011:246135. <https://doi.org/10.5402/2011/246135>
- [27] Polder BJ, Van't Hof MA, Van der Linden FP, Kuijpers-Jagtman AM. A meta-analysis of the prevalence of dental agenesis of permanent teeth. *Community Dent Oral Epidemiol* 2004; 32(3):217-26. <https://doi.org/10.1111/j.1600-0528.2004.00158.x>
- [28] Ata-Ali F, Ata-Ali J2, Peñarrocha-Oltra D, Peñarrocha-Diago M. Prevalence, etiology, diagnosis, treatment and complications of supernumerary teeth. *J Clin Exp Dent* 2014; 6(4):e414-8. <https://doi.org/10.4317/jced.51499>
- [29] Ramos AL, Gasparetto A, Terada HH, Furquim LZ, Basso P, Meireles RP. Preventive-interceptive orthodontic care to school children from the city area of Porto Rico Part I: Prevalence of malocclusions. *Rev Dental Press Ortodon Ortop Maxilar* 2000; 5(3):9-13.
- [30] Hwanga S, Choib Y J, Leec J Y, Chungd C, Kim K. Ectopic eruption of the maxillary second molar: Predictive factors. *Angle Orthod* 2017; 87(4):583-9. <https://doi.org/10.2319/020917-95>