

Cryptosporidium infections in birds - a review

Infecção por *Cryptosporidium* em aves - uma revisão

Alex Akira Nakamura¹; Marcelo Vasconcelos Meireles^{*}

¹Faculdade de Medicina Veterinária, Universidade Estadual Paulista – UNESP, Campus de Araçatuba, Araçatuba, SP, Brasil

Received April 17, 2015
 Accepted August 24, 2015

Abstract

Cryptosporidiosis is one of the main protozoan infections in birds. It manifests as either a respiratory or a digestive illness, and it affects a very large number of avian species across several continents. The aim of this review is to report on the main results of studies on cryptosporidiosis among birds and the importance of these results to veterinary medicine and public health.

Keywords: *Cryptosporidium* spp., wild birds, poultry.

Resumo

A criptosporidiose constitui-se em uma das principais infecções por protozoários em aves, manifestando-se como enfermidade respiratória ou digestiva, em dezenas de espécies aviárias, em vários continentes. O objetivo desse trabalho foi relatar, por meio de revisão de literatura, os principais resultados de estudos sobre criptosporidiose em aves e sua importância para a medicina veterinária e saúde pública.

Palavras-chave: *Cryptosporidium* spp., aves selvagens, aves domésticas.

Introduction

Protozoa of the genus *Cryptosporidium* parasitize fish, amphibians, reptiles, birds and mammals. Protozoan biological cycles take place on the surface of the epithelial cells in the gastrointestinal and respiratory tracts, in the bursa of Fabricius, and, less frequently, in other organs (CURRENT et al., 1986; BARTA & THOMPSON, 2006; VALIGUROVÁ et al., 2008), causing clinical and subclinical infections (SANTÍN, 2013).

The first description of *Cryptosporidium* infection among birds was reported by Tyzzer (1929) and involved the cecal epithelium of chicken. Slavin (1955) described a new species of *Cryptosporidium* that was causing mortality among young turkeys and suggested the name *Cryptosporidium meleagridis*. Nearly two decades later, cryptosporidiosis was diagnosed among domestic geese (*Anser anser*) (PROCTOR & KEMP, 1974) and broiler chickens (FLETCHER et al., 1975). Current et al. (1986) described the biological cycle of *Cryptosporidium* in domestic chickens and named the species *Cryptosporidium baileyi*. The third valid species of this parasite, *Cryptosporidium galli*, was described by Pavlásek (1999) from the proventriculi of chickens and was later revised by Ryan et al. (2003a).

Cryptosporidiosis is one of the main protozoan infections among birds. It manifests as either a respiratory or a digestive

disease, and it affects a very large number of avian species across all continents except Antarctica (Table 1). Various aspects of cryptosporidiosis among humans and animals have been addressed (RAMIREZ et al., 2004; XIAO et al., 2004; JEX et al., 2008; BOWMAN & LUCIO-FORSTER, 2010; RYAN, 2010), but the literature regarding the occurrence of *Cryptosporidium* infection among avian species is demonstrably sparse.

The objective of the present study was to report on the main results of studies on cryptosporidiosis among birds and the importance of these results to veterinarian medicine and public health by reviewing the literature.

Etiological Agent and Host Specificity

Cryptosporidium spp. are parasites classified as members of the phylum Apicomplexa, class Sporozoa, subclass Coccidia, order Eucoccidiida and family Cryptosporidiidae, which contains a single genus, *Cryptosporidium* (FAYER, 2008). However, there is evidence that the genus *Cryptosporidium* might be more closely related to the Gregarina than to the Coccidia (BARTA & THOMPSON, 2006; CAVALIER-SMITH, 2014).

The classification of species within the genus *Cryptosporidium* is constantly being updated using molecular methods and data on morphology, biology and host specificity. There are descriptions of 27 to 30 different species of *Cryptosporidium*, although there is still

***Corresponding author:** Marcelo Vasconcelos Meireles. Faculdade de Medicina Veterinária, Universidade Estadual Paulista – UNESP, Rua Clóvis Pestana, 793, Bairro Dona Amélia, CEP 16050-680, Araçatuba, SP, Brasil. e-mail: marcelo@fmva.unesp.br

Table 1. *Cryptosporidium* species and genotypes identified in birds using molecular diagnostic techniques.

Species/genotype	Host Order	Site of infection	Gene target	Geographic origin	Reference
<i>Cryptosporidium baileyi</i>	Anseriformes, Cathartiformes, Charadriiformes, Columbiformes, Falconiformes, Galliformes, Gruiformes, Passeriformes, Piciformes, Psittaciformes, Strigiformes, Struthioniformes	Bursa of Fabricius, conjunctiva, kidneys, respiratory tract, cloaca, rectum	18S rRNA, Actin, HSP-70, COWP	Africa, Asia, Europe, North America, South America	Morgan et al. (2001), Ryan et al. (2003b), Chvala et al. (2006), Ng et al. (2006), Huber et al. (2007), Van Zeeland et al. (2008), Nakamura et al. (2009), Molina-López et al. (2010), Sevá et al. (2011), Qi et al. (2011), Wang et al. (2011), Coldwell et al. (2012), Schulze et al. (2012), Wang et al. (2012), Baroudi et al. (2013), Bougiouklis et al. (2013), Nakamura et al. (2014), Qi et al. (2014), Wang et al. (2014b), Li et al. (2015), Máca & Pavlásek (2015)
<i>Cryptosporidium meleagridis</i>	Columbiformes, Galliformes, Passeriformes, Psittaciformes	Small intestine, large intestine	18S rRNA, Actin, HSP-70, COWP, GP60	Africa, Asia, Europe, Oceania, North America, South America	Morgan et al. (2000), Morgan et al. (2001), Ryan et al. (2003b), Huber et al. (2007), Pagès-Manté et al. (2007), Nakamura et al. (2009), Qi et al. (2011), Silverlås et al. (2012), Wang et al. (2012), Baroudi et al. (2013), Wang et al. (2014b), Li et al. (2015), Máca & Pavlásek (2015), Reboredo-Fernández et al. (2015)
<i>Cryptosporidium galli</i>	Bucerotiformes, Galliformes, Passeriformes, Psittaciformes, Phoenicopteriformes	Proventriculus	18S rRNA, Actin, HSP-70	Asia, Europe, Oceania, South America	Ryan et al. (2003a), Ng et al. (2006), Antunes et al. (2008), Nakamura et al. (2009), Silva et al. (2010), Sevá et al. (2011), Qi et al. (2011), Nakamura et al. (2014)
Avian genotype I	Galliformes, Passeriformes	nd	18S rRNA, Actin	Oceania, South America	Ng et al. (2006), Nakamura et al. (2009)
Avian genotype II	Galliformes, Psittaciformes, Struthioniformes,	Cloaca, rectum, bursa of Fabricius	18S rRNA, Actin, HSP-70	Asia, Oceania, South America	Santos et al. (2005), Meireles et al. (2006), Ng et al. (2006), Nakamura et al. (2009), Sevá et al. (2011), Nguyen et al. (2013), Wang et al. (2014b)
Avian genotype III	Passeriformes, Psittaciformes,	Proventriculus	18S rRNA, Actin, HSP-70, COWP	Asia, Oceania, North America, South America	Abe & Makino (2010), Ng et al. (2006), Nakamura et al. (2009), Makino et al. (2010), Qi et al. (2011), Gomes et al. (2012), Nakamura et al. (2014), Ravich et al. (2014)
Avian genotype IV	Psittaciformes	nd	18S rRNA	Europe	Ng et al. (2006)
Avian genotype V	Psittaciformes	nd	18S rRNA, actin, HSP-70	Asia, South America	Abe & Makino (2010), Qi et al. (2011), Nakamura et al. (2014)
Goose genotypes I-V	Anseriformes	nd	18S rRNA	North America	Jellison et al. (2004), Zhou et al. (2004)
Black duck genotype	Anseriformes	nd	18S rRNA	Oceania	Morgan et al. (2001)
Eurasian Woodcock genotype	Charadriiformes	Proventriculus	18S rRNA, HSP-70	Europe	Ryan et al. (2003b)
<i>Cryptosporidium andersoni</i>	Galliformes	nd	18S rRNA, Actin	Europe	Ng et al. (2006)
<i>Cryptosporidium muris</i>	Caprimulgiformes, Struthioniformes	nd	18S rRNA, HSP-70, Actin	Asia, Europe	Ng et al. (2006), Qi et al. (2014)
<i>Cryptosporidium parvum</i>	Accipitriformes, Anseriformes, Charadriiformes, Galliformes, Passeriformes, Psittaciformes	Small intestine, caecum	TRAP-C2, beta-tubulin, 18S rRNA, COWP	Asia, Europe, North America, South America	Graczyk et al. (1998), Zhou et al. (2004), Zylan et al. (2008), McEvoy & Giddings (2009), Nakamura et al. (2009), Gomes et al. (2012), Reboredo-Fernández et al. (2015)
<i>Cryptosporidium hominis</i>	Anseriformes	nd	18S rRNA	North America	Zhou et al. (2004)

nd: the site of infection was not reported.

some debate regarding which species are valid (ŠLAPETA, 2013; RYAN & HIJJAWI, 2015).

In birds, three species of *Cryptosporidium* have been reported, including *C. baileyi*, *C. galli* and *C. meleagridis*. Many genotypes have also been described, mainly based on molecular data (SMITH et al., 2007; XIAO & FAYER, 2008; XIAO & FENG, 2008; RYAN et al., 2014). The lack of biological, morphological or host specificity data has prevented the naming of new species related to *Cryptosporidium* avian genotypes (FAYER, 2010).

Cryptosporidium baileyi is the species most frequently diagnosed among birds, with reports of clinical or subclinical disease in 12 avian orders. Moreover, this is the most frequent species among the order Galliformes. *Cryptosporidium galli* has been found in several species of five different orders of birds, most frequently among Passeriformes and Psittaciformes, whereas *C. meleagridis* has been detected in four orders of birds, with infection occurring preferentially among the Galliformes (Table 1). *Cryptosporidium meleagridis* is the only avian species that infects mammals, and both natural and experimental infections have been reported (DARABUS, 1997; SRÉTER et al., 2000; AKIYOSHI et al., 2003; DARABUS & OLARIU, 2003).

Avian genotypes I, II, III, IV and V have been reported in birds (SANTOS et al., 2005; MEIRELES et al., 2006; NG et al., 2006; ABE & MAKINO, 2010), as have five goose genotypes (JELLISON et al., 2004; ZHOU et al., 2004), the black duck genotype and the Eurasian woodcock genotype (MORGAN et al., 2001) (Table 1).

There is still little information on the host specificity of the *Cryptosporidium* avian genotypes (Table 1). Avian genotype I has been found in canaries (*Serinus canaria*) and Indian peafowl (*Pavo cristatus*) (NG et al., 2006; NAKAMURA et al., 2009), whereas the presence of avian genotype III has been reported in several species of Psittaciformes and Passeriformes (NG et al., 2006; NAKAMURA et al., 2009; MAKINO et al., 2010; QI et al., 2011; GOMES et al., 2012; NAKAMURA et al., 2014).

The avian genotype II has been described in ostriches and in several Psittaciformes species (SANTOS et al., 2005; MEIRELES et al., 2006; NG et al., 2006; SEVÁ et al., 2011; NGUYEN et al., 2013). Although Wang et al. (2014b) reported the presence of avian genotype II in 0.78% (3/385) of fecal samples from chickens in China, Meireles et al. (2006) did not observe infection among chickens that were experimentally infected with avian genotype II and screened for *Cryptosporidium* infection using cytology, histology and oocyst screening in feces.

Infections by avian genotype IV and the Eurasian woodcock genotype have only been described once each: in the Japanese white-eye (*Zosterops japonicus*) and the Eurasian woodcock (*Scolopax rusticola*), respectively (NG et al., 2006). Regarding avian genotype V, which was first described by Abe & Makino (2010) among cockatiels (*Nymphicus hollandicus*), there have been two additional reports among birds of the order Psittaciformes (QI et al., 2011; NAKAMURA et al., 2014) and one report in reptiles (*Iguana iguana*) (KIK et al., 2011). The black duck genotype and the geese genotypes I to V have been described in the order Anseriformes and seem to have a narrower spectrum of hosts (JELLISON et al., 2004; ZHOU et al., 2004).

The infectivity of *C. parvum* to domestic chickens was assessed by Lindsay et al. (1987a) and Palkovič & Maroušek (1989), who observed clinical signs after intratracheal inoculation with oocysts. However, parasite colonization was found to be restricted to the respiratory tract, and low numbers of oocysts were produced. *Cryptosporidium* species that are more common among mammals are sporadically found in birds, either in association with clinical signs, such as *C. parvum* in the stone curlew (*Burhinus oediacnemus*) (ZYLAN et al., 2008), or asymptotically in birds, as reported by Qi et al. (2014) for ostriches with *Cryptosporidium muris* present in their feces.

Epidemiological, Clinical and Pathological Aspects of *Cryptosporidium* spp. Infection in Birds

Although many recently reported *Cryptosporidium* infections in the intestinal and respiratory tracts and the bursa of Fabricius in birds are related, respectively, to the presence of *C. meleagridis* and *C. baileyi* (RYAN, 2010), the possible roles of other species or genotypes of *Cryptosporidium* in the etiology of infections that were not characterized molecularly cannot be disregarded. For this reason, in the present review, the denomination *Cryptosporidium* sp. was used for cases where molecular characterization was not performed, unless the authors defined the species of *Cryptosporidium*, as in several studies regarding *C. baileyi*.

There are numerous descriptions of infection by *Cryptosporidium* among several avian species, particularly dating from the 1980s and 1990s, in which the diagnoses were accomplished only through cytological or histopathological observations without molecular characterization of the species or the genotype (GOODWIN, 1989; SRÉTER & VARGA, 2000). The reported clinical signs were mostly related to the respiratory tract and the gastrointestinal tract and were sometimes associated with mortality. However, other tissues have been found to be colonized by *Cryptosporidium* sp. in clinical or subclinical infections: the bursa of Fabricius, ocular conjunctiva, middle ear, pancreas and kidneys (DHILLON et al., 1981; THAM et al., 1982; HOERR et al., 1986; MASON, 1986; RITTER et al., 1986; O'DONOGHUE et al., 1987; GOODWIN, 1988; NAKAMURA & ABE, 1988; GOODWIN, 1989; GOODWIN & BROWN, 1989; JARDINE & VERWOERD, 1997; MURAKAMI et al., 2002; SRÉTER & VARGA, 2000; RYAN, 2010).

The importance of cryptosporidiosis in commercial poultry production has not yet been determined because few studies on the influence of natural infection by *Cryptosporidium* spp. on the production parameters of these birds have been conducted. Snyder et al. (1988) investigated antibodies against *Cryptosporidium* spp. by means of the indirect ELISA technique among broiler chickens in the United States and observed that the flocks that presented the best performance were negative for *Cryptosporidium*. However, positive *Cryptosporidium* serology was not clearly correlated with poor performance. Other authors have reported positive correlations between the presence of *C. baileyi* infection in broiler chickens and decreased weight gain, greater

incidence of airsacculitis, increased mortality and greater carcass condemnation rates in slaughterhouses (GORHAM et al., 1987; GOODWIN et al., 1996).

Infection by *Cryptosporidium* spp. in several species of wild and domestic birds has been demonstrated by many studies, with the reported prevalence values ranging from 0.8 to 44.4% (Table 2).

Intestinal Infection by *Cryptosporidium* sp., *C. meleagridis* and *C. parvum*

In turkeys, infection by *C. meleagridis* either presents subclinical characteristics (BERMUDEZ et al., 1988; WOODMANSEE et al., 1988) or has a clinical manifestation in the form of enteritis (SLAVIN, 1955; GOODWIN et al., 1988). In some cases, the infection is associated with other infectious agents (WAGES & FICKEN, 1989). Clinical infection is characterized by decreased weight gain, diarrhea, small intestine distention by gas and mucus, and the presence of evolutionary stages of *Cryptosporidium* in the proximal and distal portions of the small intestine (GOODWIN et al., 1988; GHARAGOZLOU et al., 2006).

Although *C. meleagridis* infects domestic chickens (LINDSAY et al., 1989), clinical cryptosporidiosis related to intestinal infection

occurs infrequently. Additionally, there are only occasional reports of intestinal cryptosporidiosis in domestic chickens, which is usually subclinical or associated with clinical signs in co-infections with other etiological agents (TYZZER, 1929; ITAKURA et al., 1984; GOODWIN, 1988; GOODWIN & BROWN, 1989).

Infection by *Cryptosporidium* sp. has been correlated with the occurrence of enteritis and high mortality among quail, with the presence of diarrhea, small intestine containing clear aqueous fluid, cecum containing brown and foamy fluid, atrophy of the intestinal villi and presence of detached enterocytes in the intestinal lumen, as well as epithelial colonization by *Cryptosporidium* (HOERR et al., 1986). *Cryptosporidium* sp. in either natural infections (RITTER et al., 1986) or experimental infections (GUY et al., 1987), with or without associations with reoviruses, causes severe intestinal infection and high mortality among quail, in addition to presenting synergism with reoviruses.

One report described *C. meleagridis* infection in a breeding farm of red-legged partridges (*Alectoris rufa*) with clinical signs characterized by diarrhea and coughing, morbidity of 60-70% and mortality of 50% (100/200). On the same farm, during a later outbreak, mortality reached 89% (400/450). Evolutionary stages of *Cryptosporidium* were present in the respiratory tracts and intestines of these birds. Because molecular characterization was only

Table 2. Worldwide prevalence of *Cryptosporidium* spp. in wild and domestic birds.

Host species	Geographic origin	Species/genotype	% positive for <i>Cryptosporidium</i> spp. (No. positive/No. sampled)	References	
<i>Alectoris rufa</i>	Czech Republic	<i>C. baileyi</i> , <i>C. meleagridis</i>	22 (145/663)	Máca & Pavlásek (2015)	
<i>Anas platyrhynchos</i>	China	<i>C. baileyi</i>	16.6 (92/564)	Wang et al. (2010)	
<i>Columba livia domestica</i>	Iran	<i>Cryptosporidium</i> spp.	2.94 (3/102)	Radfar et al. (2012)	
	China	<i>C. baileyi</i> , <i>C. meleagridis</i>	0.8 (2/244)	Li et al. (2015)	
<i>Coturnix coturnix japonica</i>		<i>C. baileyi</i> , <i>C. meleagridis</i>	13.1 (239/1818)	Wang et al. (2012)	
<i>Gallus gallus domesticus</i>	China	<i>C. baileyi</i> , <i>C. meleagridis</i>	8.9 (179/2015)	Wang et al. (2010)	
	Algeria	<i>C. baileyi</i> , <i>C. meleagridis</i>	34.4 (31/90)	Baroudi et al. (2013)	
	China	Avian genotype II, <i>C. baileyi</i> , <i>C. meleagridis</i>	9.87 (38/385)	Wang et al. (2014b)	
<i>Meleagris gallopavo</i>	Iran	<i>Cryptosporidium</i> spp.	35.3 (17/60)	Gharagozlou et al. (2006)	
	USA	<i>C. parvum</i>	6.3 (5/79)	McEvoy & Giddings (2009)	
	Algeria	<i>C. meleagridis</i>	43.9 (25/57)	Baroudi et al. (2013)	
	Australia	Avian genotypes I, II, III, <i>C. andersoni</i> , <i>C. baileyi</i> , <i>C. galli</i> , <i>C. muris</i>	6.25 (27/430)	Ng et al. (2006)	
	Brazil	Avian genotypes I, II, III, <i>C. baileyi</i> , <i>C. galli</i> , <i>C. meleagridis</i> , <i>C. parvum</i>	4.86 (47/966)	Nakamura et al. (2009)	
Several species	China	Avian genotypes I, II, III, V, <i>C. baileyi</i> , <i>C. galli</i> , <i>C. meleagridis</i> , <i>C. parvum</i>	8.1 (35/434)	Qi et al. (2011)	
	Brazil	Avian genotype II, <i>C. baileyi</i> , <i>C. galli</i>	6.6 (16/242)	Sevá et al. (2011)	
	Nigeria	<i>Cryptosporidium</i> spp.	7.4 (66/890)	Bamaiyi et al. (2013)	
	Spain	<i>C. meleagridis</i> , <i>C. parvum</i>	8.3 (36/433)	Reboredo-Fernández et al. (2015)	
		Brazil	<i>Cryptosporidium</i> spp.	44.4 (50/77)	Oliveira et al. (2008)
		China	<i>C. baileyi</i>	11.7 (53/452)	Wang et al. (2011)
<i>Struthio camelus</i>	Vietnam	Avian genotype II	23.7 (110/464)	Nguyen et al. (2013)	
	China	<i>C. baileyi</i> , <i>C. muris</i>	10.2 (31/303)	Qi et al. (2014)	

performed on the intestinal content, from which *C. meleagridis* was identified, the authors of the study suggested that the respiratory infection could have been caused by *C. meleagridis*, although it was an unusual location, or could have been due to co-infection with *C. baileyi* (PAGÈS-MANTÉ et al., 2007).

Enteritis due to *Cryptosporidium* sp. has been reported among pigeons, with clinical signs such as diarrhea, hyperemia and intestinal distension and the presence of evolutionary stages of the parasite in the epithelium of the small intestine (ÖZKUL & AYDIN, 1994).

The importance of the prevalence of intestinal infection among Psittaciformes has not been determined. However, intestinal cryptosporidiosis associated with clinical signs has been observed among budgerigars (*Melopsittacus undulatus*) (GOODWIN & KRABILL, 1989), cockatiels (*Nymphicus hollandicus*) (GOODWIN & KRABILL, 1989; LINDSAY et al., 1990), ring-necked parrots (*Psittacula krameri*) (MORGAN et al., 2000) and lovebirds, which exhibited a high mortality rate (*Agapornis* sp.) (BELTON & POWELL, 1987).

Although infection by *C. parvum* is not common among birds, Zylan et al. (2008) described a case of catarrhal enteritis and mortality among stone curlews (*Burhinus oediacnemus*) in Saudi Arabia.

Infection by *Cryptosporidium* sp., *C. baileyi* and Avian Genotype II in the Ocular Conjunctiva, Respiratory Tract, Bursa of Fabricius, Rectum and Cloaca

Cryptosporidium sp. and *C. baileyi* are frequently regarded as etiological agents for infections in the upper respiratory system, middle ear and ocular conjunctiva of wild birds, such as owls (*Otus scops*), swallows (*Petrochelidon pyrrhonota*), falcons (*Falco cherrug* and *Falco rusticolus* X *Falco cherrug*) and red grouse (*Lagopus lagopus scoticus*) (VAN ZEELAND et al., 2008; MOLINA-LÓPEZ et al., 2010; COLDWELL et al., 2012; LEY et al., 2012; BOUGIOUKLIS et al., 2013; BAINES et al., 2014), and of domesticated birds, such as domestic chickens (BLAGBURN et al., 1991), geese (*Anser anser* f. *domestica*) (CHVALA et al., 2006), turkeys (GLISSON et al., 1984), ducks (MASON, 1986; O'DONOGHUE et al., 1987), peacocks (MASON & HARTLEY, 1980) and pheasants (RANDALL, 1986).

Respiratory infection may be restricted to the upper respiratory tract, or it may disseminate to the lower respiratory tract, including the bronchia, lungs and air sacs (Figure 1a - c). This may occur with *C. baileyi* alone or in association with other etiological agents of respiratory infections in chickens, such as *Escherichia coli* (Figure 1d) and the infectious bronchitis virus, and can result in high mortality (GOODWIN, 1989; BLAGBURN et al., 1987; BLAGBURN et al., 1991; MEIRELES et al., 1999). Several reports have been published on infections by *Cryptosporidium* sp. in turkeys and quails, with or without associations with other etiological agents (THAM et al., 1982; TARWID et al., 1985; MURAKAMI et al., 2002).

Oral infection by *C. baileyi* is generally subclinical, although there may be decreased weight gain, which may only be transitory (BLAGBURN et al., 1987; LEVY et al., 1988; MEIRELES et al., 1998a). After oral or intratracheal infection, *C. baileyi* colonizes the

bursa of Fabricius, which presents slight hyperemia and mucus on the mucosal surface. The exudation of products generated from the inflammation, especially heterophils, plasma and cell residues, results in the deposition of a caseous exudate in the lumen of the bursa of Fabricius (Figure 2a) (GUY et al., 1988; MEIRELES et al., 1998b).

Divergent reports exist on the effects of cryptosporidiosis on the immune system. *Cryptosporidium baileyi* causes a severe infection in the bursa of Fabricius (Figure 2b), which is the organ responsible for the humoral immune response in birds (SCOTT, 2004). Although experimental infections with *C. baileyi* have been found to present diffuse chronic superficial purulent bursitis with epithelial hyperplasia and hypertrophy (Figure 2c) and slight lymphoid atrophy (GUY et al., 1988; LEVY et al., 1988; GOODWIN & BROWN, 1989; MEIRELES et al., 1998b), no influence on the humoral immune response of chickens has been observed (BLAGBURN et al., 1987; MEIRELES et al., 1998b; ABBASSI et al., 2000). Nevertheless, other reports have shown that *C. baileyi* infection had a suppressive effect on the humoral immune response of birds to the pathogenic virus or vaccine virus for Marek's disease (NACIRI et al., 1989), the Gumboro disease vaccine virus (LEVY et al., 1988), reoviruses (GUY et al., 1988), the Newcastle disease vaccine virus (RHEE et al., 1998a; ELADL et al., 2014), the infectious bronchitis vaccine virus (RHEE et al., 1998b), *Brucella abortus* (RHEE et al., 1998c) and the avian influenza vaccine virus (HAO et al., 2008; ELADL et al., 2014).

In addition to the possible immunosuppression caused by *C. baileyi*, even if only transitory, the association of *C. baileyi* with other infectious agents may result in high mortality and decreased weight gain among chickens. Among the agents that may present synergistically with *C. baileyi* are the virus vaccine (Rispen) for Marek's disease (ABBASSI et al., 2000), the avian infectious anemia virus (HORNOK et al., 1998), the Gumboro disease virus (LEVY et al., 1988) and reoviruses (GUY et al., 1988). In contrast, Meireles et al. (1995) did not observe any synergism among broiler chickens that were experimentally infected with *Toxoplasma gondii* and *C. baileyi*.

There have been reports that infection by *Cryptosporidium* sp. in ostriches resulted in prolapse of the phallus and cloaca (ALLWRIGHT & WESSELS, 1993; BEZUIDENHOUT et al., 1993; PENRITH & BURGER, 1993; PENRITH et al., 1994) and in pancreatic necrosis (JARDINE & VERWOERD, 1997). The avian genotype II colonizes the epithelium of the cloaca (Figure 2d) and, less frequently, the rectum and bursa of Fabricius of ostriches. The infection results in prolapse of the cloaca (Figure 3a), particularly if stressful conditions lead to immunosuppression or if there are poor husbandry practices relating to feed, water or hygiene (SANTOS et al., 2005).

Infection in the Proventriculus by *Cryptosporidium* sp., *Cryptosporidium galli*, *C. muris*, Avian Genotype III and the Eurasian Woodcock Genotype

Cryptosporidium galli infects several species of birds of the orders Bucerotiformes, Galliformes, Passeriformes, Phoenicopteriformes and Psittaciformes (Table 1). The pathogenicity of the gastric

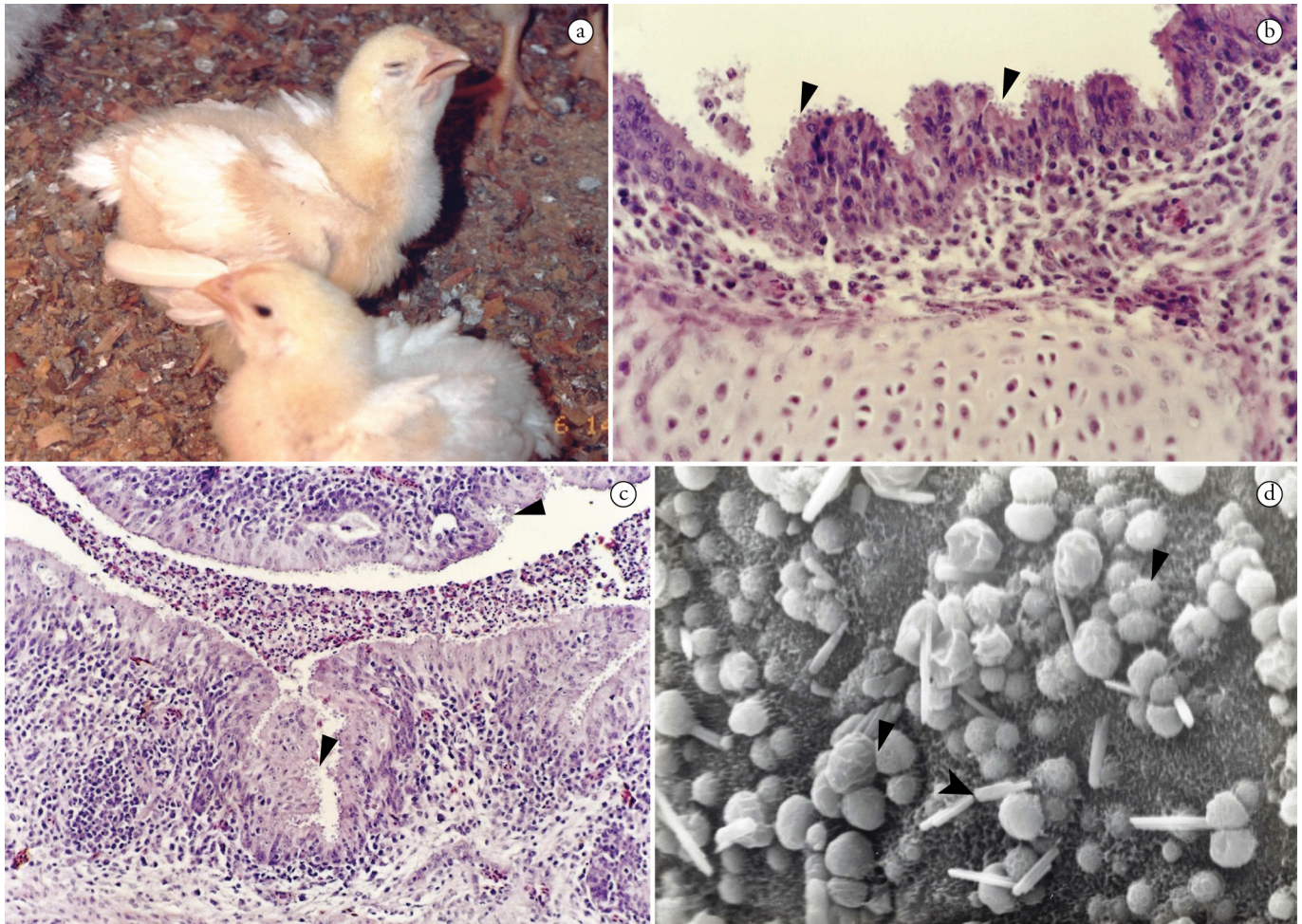


Figure 1. **a:** Chicken showing dyspnea after intratracheal inoculation of *C. baileyi* oocysts. **b:** Light micrograph of chicken trachea. Developmental stages of *C. baileyi* adhered to the epithelial surface (arrows), epithelial hyperplasia and infiltration of inflammatory cells in the submucosa (H&E stain, 400x). **c:** Light micrograph of chicken lung tissue. Developmental stages of *C. baileyi* adhered to the bronchial epithelial surface (arrows), inflammatory cells infiltrating both submucosa and epithelium, and inflammatory exudate filling the bronchial lumen (H&E stain, 200x). **d:** Scanning electron micrograph of chicken tracheal epithelium showing severe loss of cilia and concomitant infection with *C. baileyi* (arrow) and *Escherichia coli* (arrowhead) (2,000x).

species of *Cryptosporidium* has not yet been determined. Gastric infections by *C. galli* or *Cryptosporidium* sp. may be subclinical or associated with clinical signs characterized by apathy, diarrhea, weight loss, and sporadic mortality (BLAGBURN et al., 1990; CLUBB, 1997; MORGAN et al., 2001; ANTUNES et al., 2008; SILVA et al., 2010).

Infection with *C. galli* is characterized by intermittent and chronic shedding of oocysts in the feces. *C. galli* is able to infect young and adult birds and cause chronic gastric infection similar to *C. serpentis* in snakes (SILVA et al., 2010). Thus, Antunes et al. (2008) and Silva et al. (2010) suggested that infections by *C. galli* could be responsible for chronic proventriculitis in birds, which would predispose them to secondary infections by other pathogens.

The avian genotype III has also been found among several species of Passeriformes and Psittaciformes (Table 2). As with *C. galli*, avian genotype III causes chronic gastric disease, with clinical

signs that include vomiting, weight loss and macroscopic and microscopic lesions in the proventriculus (MAKINO et al., 2010; RAVICH et al., 2014).

Cryptosporidium muris and *C. andersoni* infect several species of mammals and are occasionally related to clinical signs (SANTÍN, 2013). In birds, *C. muris* and *C. andersoni* oocysts may be present in fecal samples, possibly due to an actual infection or to being mechanically transported (NG et al., 2006). Subclinical infection by *C. muris*, which has apparently adapted to a new host, has been described among adult ostriches in China (QI et al., 2014).

There is only one report of infection in the proventriculus that was caused by the Eurasian woodcock genotype; this infection was described in the Czech Republic in a Eurasian woodcock (*Scolopax rusticicola*) that died during the quarantine period (RYAN et al., 2003b).

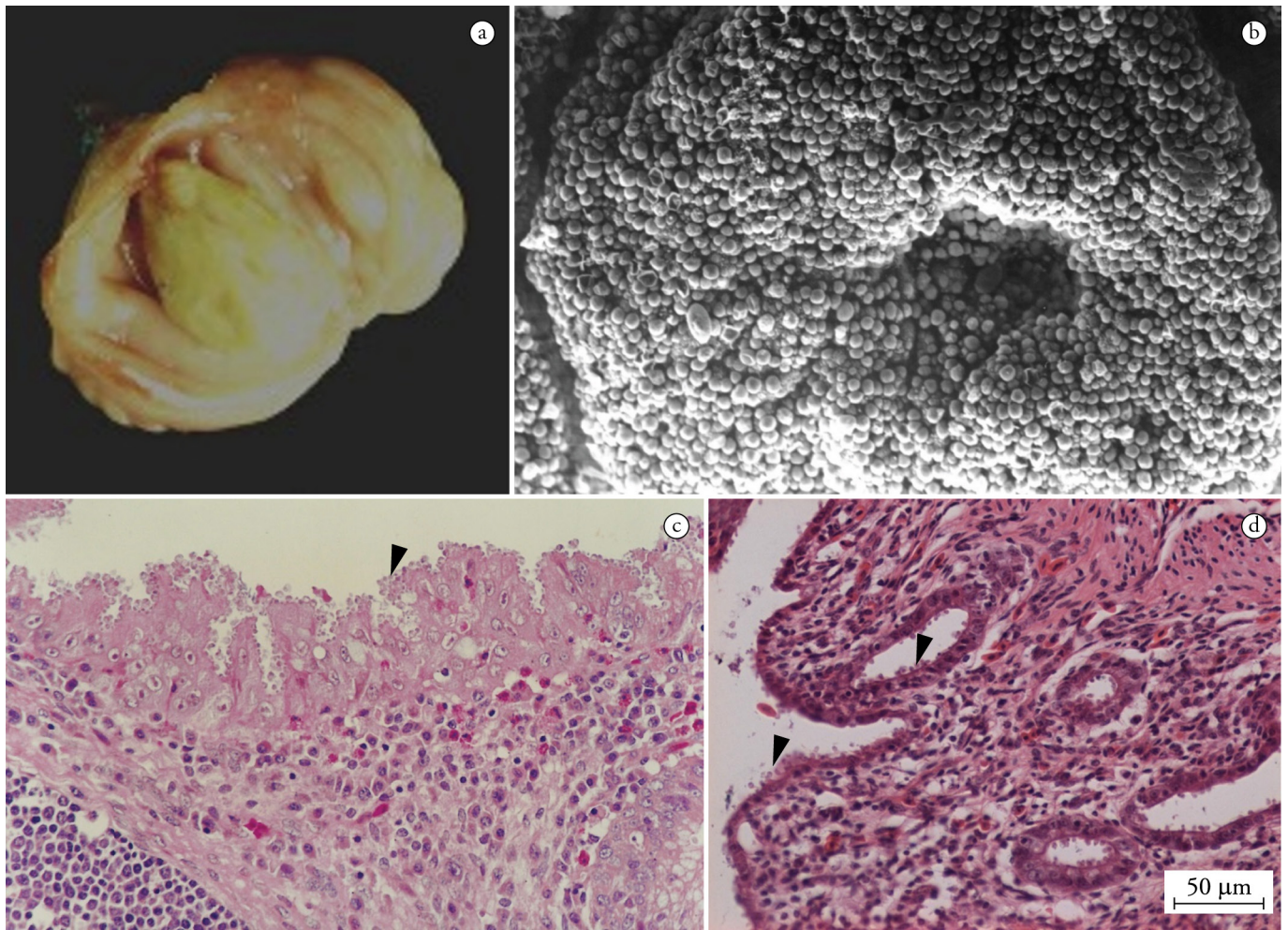


Figure 2. **a:** Caseous exudate filling the lumen of bursa of Fabricius of a chicken infected with *C. baileyi*. **b:** Scanning electron micrograph of bursa of Fabricius of a chicken infected with *C. baileyi*. Massive infection with parasite developmental stages covering the epithelial surface (700x). **c:** Light micrograph of chicken bursa of Fabricius. Developmental stages of *C. baileyi* adhered to the epithelial surface, epithelial hyperplasia and inflammatory cells infiltrating both submucosa and epithelium (H&E stain, 400x). **d:** Light micrograph of ostrich urodeum. Developmental stages of *Cryptosporidium* avian genotype II adhered to the epithelial surface and inflammatory cell infiltration in the submucosa (H&E stain, 400x).

Infection by Other Avian Genotypes of *Cryptosporidium*

Tissue tropism or the clinical importance of other genotypes of *Cryptosporidium* among birds has not been determined. Avian genotype I and avian genotype V show genetic similarity to *C. baileyi* and avian genotype II (ABE & MAKINO, 2010; MEIRELES et al., 2006; NG et al., 2006). Because species with greater genetic similarity present similar tissue tropism, as observed with *C. parvum* and *C. meleagridis*, with *C. baileyi* and avian genotype II and with *C. galli* and avian genotype III (XIAO et al., 2004; NG et al., 2006), it is likely that avian genotype I and avian genotype V colonize the final portion of the intestine, cloaca, bursa of Fabricius or respiratory system, and avian genotype IV, the proventriculus.

The hosts of the other avian genotypes described to date are as follows: avian genotype I: the canary (*Serinus canaria*) (NG et al., 2006; NAKAMURA et al., 2009) and the Indian peafowl (*Pavo cristatus*) (NAKAMURA et al., 2009); avian genotype IV: the Japanese white-eye (*Zosterops japonicus*) (NG et al., 2006); and avian genotype V: the cockatiel (*Nymphicus hollandicus*) (ABE & MAKINO, 2010; QI et al., 2011) and the blue-fronted parrot (*Amazona aestiva*) (NAKAMURA et al., 2014).

Diagnosis of Cryptosporidiosis Among Birds

Experience is a fundamental factor in diagnosing cryptosporidiosis because *Cryptosporidium* oocysts are small in comparison with other coccidians, do not present sporocysts, are difficult to

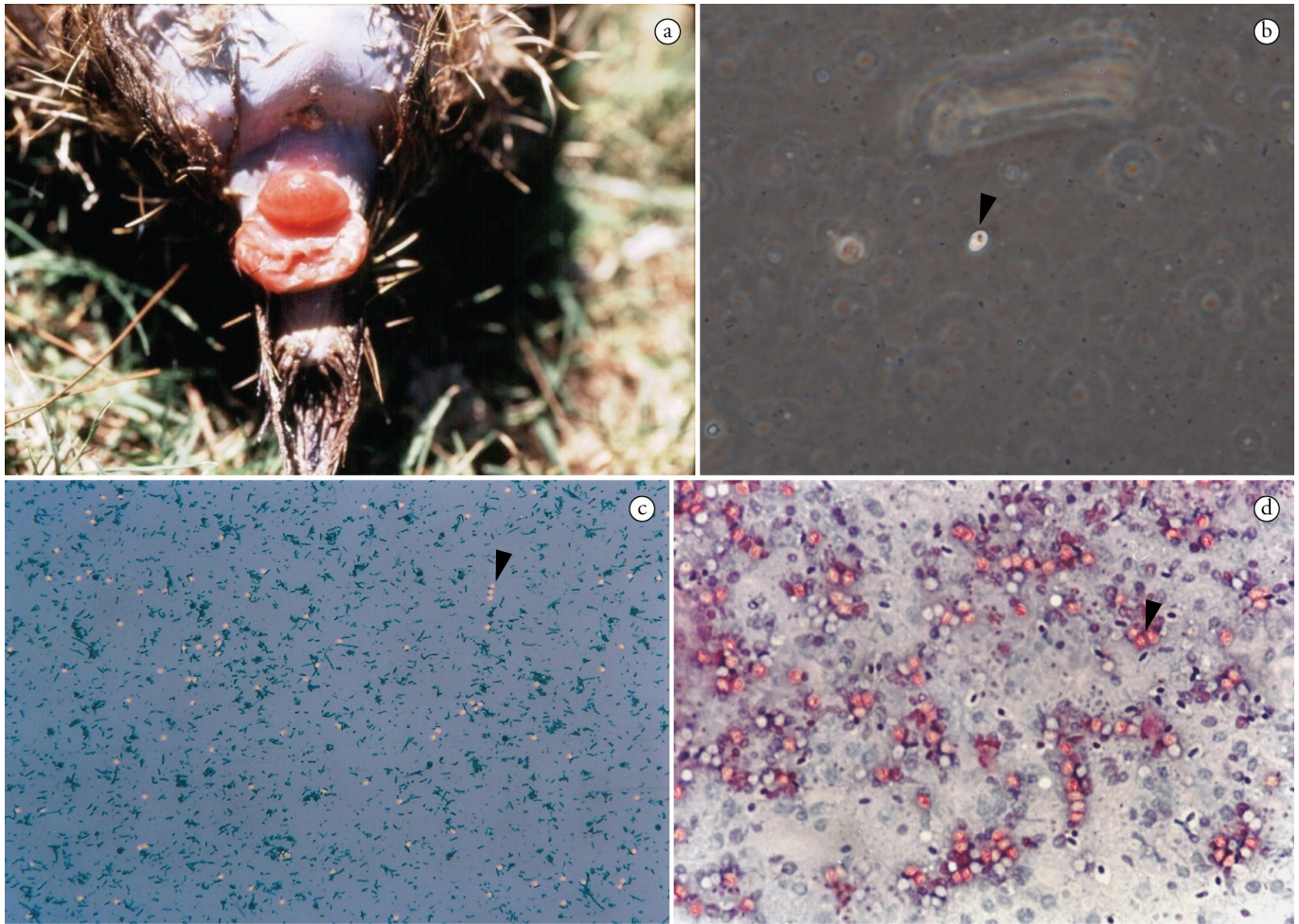


Figure 3. **a:** Cloacal prolapse in ostrich chick infected with *Cryptosporidium* avian genotype II. **b:** Single oocyst of *C. galli* (arrow). Fecal sample from a chronically infected adult canary processed using the Sheather's centrifugal flotation procedure (Phase contrast microscopy, 400x). **c:** Numerous oocysts of *Cryptosporidium* avian genotype II (arrow). Fecal sample from an ostrich chick processed using the ether centrifugal sedimentation procedure (Malachite green negative stain, 100x). **d:** Light micrograph of chicken bursa of Fabricius mucosal smear. Developmental stages of *C. baileyi* (arrow) (Safranin methylene blue stain, 200x).

observe, and are morphologically similar to fungi and yeast spores (CASEMORE, 1991). In samples with few oocysts in particular, care is needed to avoid false-positive results in fecal samples examined using the most common diagnostic methods, such as acid-fast staining or viewing oocysts under an optical microscope after concentration with saturated solutions of sugar, zinc sulfate or sodium chloride.

False-negative results are also common in samples with a low number of oocysts because of the low sensitivity of the staining techniques (JEX et al., 2008). In infections with *C. galli*, chronic shedding occurs, and few oocysts (Figure 3b) are observed per slide (ANTUNES et al., 2008). The amount of oocyst shedding and the patent period of infection with *C. baileyi* and *C. meleagridis* vary according to the age and species of the host (SRÉTER & VARGA, 2000).

The diagnostic methods using microscopy that are most used and least expensive involve screening for oocysts after centrifugal flotation in Sheather's solution, followed by phase

contrast microscopy (Figure 3b) or bright-field microscopy (CARDOZO et al., 2008; TEIXEIRA et al., 2011a) and any of the many staining techniques for fecal samples, including negative malachite green staining (Figure 3c) (ELLIOT et al., 1999) and acid-fast staining (HENRIKSEN & POHLENZ, 1981; ORTOLANI, 2000; CARDOZO et al., 2008). In morphometric studies, morphological and morphometric alterations in oocysts should be considered when fecal smears are subjected to staining techniques (MEIRELES & FIGUEIREDO, 1992; CARDOZO et al., 2005).

Several staining techniques are useful for screening of the evolutionary stages of *Cryptosporidium* in histological sections and in mucosal smears, including hematoxylin and eosin, safranin-methylene blue (Figure 3d) and acid-fast stains (Figure 4). Furthermore, *Cryptosporidium* DNA can be detected in tissue sections using fluorescent *in situ* hybridization (LATIMER et al., 1988; CHVALA et al., 2006; JEX et al., 2008).

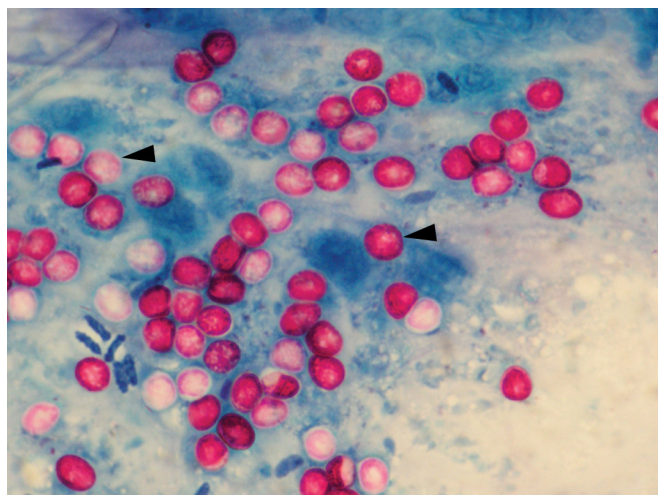


Figure 4. Light micrograph of lesser seed-finch proventriculus mucosal smear. Developmental stages of *C. galli* (arrows) (Kinyoun acid-fast stain, 1,000x).

Immunological methods for *Cryptosporidium* spp. diagnosis have been extensively reviewed (JEX et al., 2008; CHALMERS & KATZER, 2013). The detection of *Cryptosporidium* by capture enzyme-linked immunoassays (ELISA) or direct fluorescent antibody (DFA) assays using commercially available antibodies have been extensively adopted in fecal and environmental samples; as a rule, they present higher sensitivity and higher specificity than oocyst-staining techniques.

The antigens targeted by capture ELISA and DFA present cross-reactivity among the different species of *Cryptosporidium*, and therefore, does not allow species-specific diagnosis (GRACZYK et al., 1996; JEX et al., 2008; CHALMERS et al., 2011; TEIXEIRA et al., 2011b). Although both methods are commonly applied to detect *C. parvum* antigens (JEX et al., 2008), they may be useful for the diagnosis of avian cryptosporidiosis (RICHTER et al., 1994; GRACZYK et al., 1996; ROHELA et al., 2005; PAGÈS-MANTÉ et al., 2007).

Although the oocysts of some species present distinct morphology and morphometry, microscopic analysis does not allow species characterization because small variations exist in these parameters, and in many cases, the oocysts may be identical between different species or genotypes (RYAN, 2010). However, a presumptive diagnosis of gastric, intestinal or respiratory/bursal/cloacal cryptosporidiosis in birds can be accomplished by the presence of ellipsoidal oocysts measuring 7.5-8.5 × 6.0-6.4 μm; spherical, irregularly spherical or slightly elongated oocysts measuring 4.5-6.0 × 4.2-5.3 μm; or ovoid oocysts measuring 6.0-7.5 × 4.8-5.7 μm, respectively (CURRENT et al., 1986; LINDSAY et al., 1989; RYAN, 2010).

Molecular characterization of *Cryptosporidium* is performed by means of PCR, followed by either restriction fragment length polymorphism (RFLP) or sequencing of the amplified fragments. The gene most used for determining the species or genotype is 18S rRNA (RYAN et al., 2014). In comparison with the species of *Cryptosporidium* found in mammals, few sequences for the *Cryptosporidium* of avian species have been published in

GenBank. When better resolution is needed to identify genetically similar species or genotypes, the relevant sequences of avian *Cryptosporidium* that are available relate to actin gene, heat shock protein gene (HSP-70) and *Cryptosporidium* oocyst wall protein gene (COWP) (Table 1). The 60-kDa glycoprotein (GP60) gene is used for subtyping *C. meleagridis* in molecular epidemiology studies (STENSVOLD et al., 2014; WANG et al., 2014a).

The genetic similarity between avian genotype II and avian genotype V in the 18S rRNA gene is 99.9%. Only a substitution of G by A in positions 329 and 378 differentiates the sequences of avian genotype II (DQ290031) and avian genotype V (AB471646), respectively. Because of this genetic similarity and the possibility of intraspecies variations in the 18S rRNA gene, classification of these two avian genotypes is recommended only after at least one gene that presents greater interspecies polymorphism, such as the HSP-70 gene or the actin gene (ABE & MAKINO, 2010; NG et al., 2006; MEIRELES et al., 2006), has been analyzed.

Species-specific diagnosis using molecular biology techniques is also possible. Recently, Nakamura et al. (2014) developed a real-time PCR specifically for diagnosing *C. galli* and avian genotype III.

Treatment and Prophylaxis

Many drugs have been tested for the treatment of cryptosporidiosis, but the US Food and Drug Administration (FDA) has approved only nitazoxanide for use in humans (SMITH & CORCORAN, 2004; STRIEPEN, 2013). Although halofuginone has shown variable efficacy, an effective drug for the prophylaxis and treatment of animal cryptosporidiosis is still lacking (LINDSAY et al., 1987b; SRÉTER et al., 2000; SHAHIDUZZAMAN & DAUGSCHIES, 2012).

Cryptosporidium oocysts are resistant to environmental stress and to the disinfectants commonly used in avian facilities. The prevention and control of avian cryptosporidiosis must rely on rigorous measures related to nutritional and sanitary management to prevent exposure to oocysts and the prophylaxis of concomitant diseases that are commonly associated with avian cryptosporidiosis (SANTOS et al., 2005; SRÉTER & VARGA, 2000; SILVA et al., 2010; SHAHIDUZZAMAN & DAUGSCHIES, 2012).

Importance for Public Health

More than 90% of human *Cryptosporidium* infections are related to *C. hominis* or *C. parvum*, although there are sporadic reports of infections with other *Cryptosporidium* species or genotypes. Among the *Cryptosporidium* species and genotypes of avian hosts, only *C. meleagridis* has a wider host spectrum and is able to infect humans; in fact, it is the third most common cause of human cryptosporidiosis. In some countries, such as Peru and Thailand, *C. meleagridis* is responsible for 10-20% of human *Cryptosporidium* infections, with a frequency similar to that of infection by *C. parvum* (XIAO & FENG, 2008; CHALMERS & GILES, 2010; ELWIN et al., 2012; INSULANDER et al., 2013).

Silverlås et al. (2012) reported the possible zoonotic transmission of *C. meleagridis* in Sweden when samples with identical nucleotide

sequences for the 18S rRNA and HSP-70 genes were found in hens, broiler chickens and an infected person. Further studies using phylogenetic analysis of multiple *loci* have suggested that the *C. meleagridis* found in birds may be related to isolates from humans and that birds may constitute an infectious source of human infections by *C. meleagridis* (STENSVOLD et al., 2014; WANG et al., 2014a).

Epidemiological studies have reported the presence of *C. meleagridis* in domestic birds and environmental samples. In Algeria, a report showed a high prevalence of *C. meleagridis*: 34% (26/90) in chickens and 44% (25/57) in turkeys (BAROUDI et al., 2013). However, in China, a low prevalence was described for *C. meleagridis* among broiler chickens (0.52%; 2/385) (WANG et al., 2014b), laying hens (0.19%; 3/1542) (WANG et al., 2010) and quails (0.22%; 4/1818) (WANG et al., 2012). Li et al. (2012) found *C. meleagridis* in 24.4% (22/90) of the wastewater samples collected from four cities in China.

The oocysts of *C. parvum* are sporadically present in fecal samples of asymptomatic birds that are kept either as pets or in zoos. In most situations, the birds represent only a mechanical transporter of oocysts (NAKAMURA et al., 2009; QUAH et al., 2011). However, even if birds are rarely infected by the *Cryptosporidium* species that are associated with mammals, aquatic birds mechanically transport the oocysts of zoonotic species, such as *C. parvum* and *C. hominis*, and may participate in the epidemiological chain of human cryptosporidiosis by means of environmental contamination (GRACZYK et al., 1998; ZHOU et al., 2004; GRACZYK et al., 2008; PLUTZER & TOMOR, 2009).

Concluding Remarks

Among the three species and various genotypes of *Cryptosporidium* identified in birds, only partial information is available regarding their economic, clinical, pathological and epidemiological characteristics and their importance for public health. Most of this information concerns *C. baileyi*, *C. galli*, *C. meleagridis*, avian genotype II and avian genotype III. Birds are kept as pets, for ornamental purposes, in zoos, in wildlife conservation centers and for commercial poultry production. The importance of determining the various aspects of cryptosporidiosis as a zoonosis or as a disease with significance regarding the health of birds is undeniable.

Reports of clinical disease associated with the presence of *Cryptosporidium* spp. among birds are increasingly frequent. Cryptosporidiosis on commercial farms remains understudied, perhaps because it is a subclinical disease or because it presents clinical signs that are not pathognomonic. Moreover, cryptosporidiosis is not among the diseases that are routinely diagnosed in avian pathology laboratories.

Several aspects of avian cryptosporidiosis, particularly its pathogeny among domestic birds, were more frequently studied during the 1980s and 1990s. After this period, the focus of research on avian cryptosporidiosis was directed toward the detection and classification of species and genotypes of *Cryptosporidium* and their roles as zoonotic agents. New research related to natural or experimental infection by *Cryptosporidium* spp. among domestic and wild birds could elucidate factors that are still undefined, such

as the importance of this parasite as a primary infection agent and its interaction with other etiological agents of infections in the gastrointestinal tract, respiratory tract and bursa of Fabricius.

References

- Abbassi H, Coudert F, Dambrine G, Chérel Y, Naciri M. Effect of *Cryptosporidium baileyi* in specific pathogen free chickens vaccinated (CVI988/Rispens) and challenged with HPRS-16 strain of Marek's. *Avian Pathol* 2000; 29(6): 623-634. <http://dx.doi.org/10.1080/03079450020016887>. PMID:19184860.
- Abe N, Makino I. Multilocus genotypic analysis of *Cryptosporidium* isolates from cockatiels, Japan. *Parasitol Res* 2010; 106(6): 1491-1497. <http://dx.doi.org/10.1007/s00436-010-1810-5>. PMID:20339870.
- Akiyoshi DE, Dilo J, Pearson C, Chapman S, Tumwine J, Tzipori S. Characterization of *Cryptosporidium meleagridis* of human origin passaged through different host species. *Infect Immun* 2003; 71(4): 1828-1832. <http://dx.doi.org/10.1128/IAI.71.4.1828-1832.2003>. PMID:12654797.
- Allwright DM, Wessels J. *Cryptosporidium* species in ostriches. *Vet Rec* 1993; 133(1): 24. <http://dx.doi.org/10.1136/vr.133.1.24-a>. PMID:8362489.
- Antunes RG, Simões DC, Nakamura AA, Meireles MV. Natural infection with *Cryptosporidium galli* in canaries (*Serinus canaria*), in a cockatiel (*Nymphicus hollandicus*), and in lesser seed-finches (*Oryzoborus angolensis*) from Brazil. *Avian Dis* 2008; 52(4): 702-705. <http://dx.doi.org/10.1637/8356-051208-Case.1>. PMID:19166068.
- Baines D, Newborn D, Richardson M. Spread of *Cryptosporidium baileyi* in red grouse *Lagopus lagopus scoticus*. *Vet Rec* 2014; 175(6): 149. <http://dx.doi.org/10.1136/vr.102275>. PMID:24934399.
- Bamaiyi PH, Umoh JU, Abdu PA, Lawal IA. The prevalence of *Cryptosporidium* oocysts in Zaria, Nigeria. *Borneo J Resour Sci Tech* 2013; 2(2): 52-59.
- Baroudi D, Khelef D, Goucem R, Adjou KT, Adamu H, Zhang H, et al. Common occurrence of zoonotic pathogen *Cryptosporidium meleagridis* in broiler chickens and turkeys in Algeria. *Vet Parasitol* 2013; 196(3-4): 334-340. <http://dx.doi.org/10.1016/j.vetpar.2013.02.022>. PMID:23498647.
- Barta JR, Thompson RC. What is *Cryptosporidium*? Reappraising its biology and phylogenetic affinities. *Trends Parasitol* 2006; 22(10): 463-468. <http://dx.doi.org/10.1016/j.pt.2006.08.001>. PMID:16904941.
- Belton DJ, Powell IB. Cryptosporidiosis in lovebirds (*Agapornis* sp.). *N Z Vet J* 1987; 35(1-2): 15. <http://dx.doi.org/10.1080/00480169.1987.35364>. PMID:16031325.
- Bermudez AJ, Ley DH, Levy MG, Ficken MD, Guy JS, Gerig TM. Intestinal and bursal cryptosporidiosis in turkeys following inoculation with *Cryptosporidium* sp. isolated from commercial poults. *Avian Dis* 1988; 32(3): 445-450. <http://dx.doi.org/10.2307/1590910>. PMID:3196261.
- Bezuidenhout AJ, Penrith ML, Burger WP. Prolapse of the phallus and cloaca in the ostrich (*Struthio camelus*). *J S Afr Vet Assoc* 1993; 64(4): 156-158. PMID:8176694.
- Blagburn BL, Lindsay DS, Giambone JJ, Sundermann CA, Hoerr FJ. Experimental cryptosporidiosis in broiler chickens. *Poult Sci* 1987; 66(3): 442-449. <http://dx.doi.org/10.3382/ps.0660442>. PMID:3601855.
- Blagburn BL, Lindsay DS, Hoerr FJ, Atlas AL, Toivio-Kinnucan M. *Cryptosporidium* sp. infection in the proventriculus of an Australian diamond firetail finch (*Staganoplura bella*: Passeriformes, Estrildidae).

- Avian Dis* 1990; 34(4): 1027-1030. <http://dx.doi.org/10.2307/1591401>. PMID:2282009.
- Blagburn BL, Lindsay DS, Hoerr FJ, Davis JF, Giambrone JJ. Pathobiology of cryptosporidiosis (*C. baileyi*) in broiler chickens. *J Protozool* 1991; 38(6): 25S-28S. PMID:1667932.
- Bougiouklis PA, Weissenböck H, Wells A, Miller WA, Palmieri C, Shivaprasad HL. Otitis media associated with *Cryptosporidium baileyi* in a Saker falcon (*Falco cherrug*). *J Comp Pathol* 2013; 148(4): 419-423. <http://dx.doi.org/10.1016/j.jcpa.2012.09.005>. PMID:23123131.
- Bowman DD, Lucio-Forster A. Cryptosporidiosis and giardiasis in dogs and cats: veterinary and public health importance. *Exp Parasitol* 2010; 124(1): 121-127. <http://dx.doi.org/10.1016/j.exppara.2009.01.003>. PMID:19545532.
- Cardozo SV, Teixeira WL Fo, Lopes CWG. Avaliação das técnicas de rotina no diagnóstico de oocistos de *Cryptosporidium baileyi* em amostras de fezes de frangos de corte (*Gallus gallus domesticus*). *Rev Bras Parasitol Vet* 2008;17(S1 Suppl 1): 351-353. PMID:20059878.
- Cardozo SV, Teixeira WL Fo, Lopes CWG. Transmissão experimental de *Cryptosporidium baileyi* (Apicomplexa: cryptosporidiidae) isolado de frango de corte à codorna Japonesa (*Coturnix japonica*). *Rev Bras Parasitol Vet* 2005; 14(3): 119-124. PMID:16229756.
- Casemore DP. Laboratory methods for diagnosing cryptosporidiosis. *J Clin Pathol* 1991; 44(6): 445-451. <http://dx.doi.org/10.1136/jcp.44.6.445>. PMID:1712367.
- Cavalier-Smith T. Gregarine site-heterogeneous 18S rDNA trees, revision of gregarine higher classification, and the evolutionary diversification of Sporozoa. *Eur J Protistol* 2014; 50(5): 472-495. <http://dx.doi.org/10.1016/j.ejop.2014.07.002>. PMID:25238406.
- Chalmers RM, Campbell BM, Crouch N, Charlett A, Davies AP. Comparison of diagnostic sensitivity and specificity of seven *Cryptosporidium* assays used in the UK. *J Med Microbiol* 2011; 60(Pt 11): 1598-1604. <http://dx.doi.org/10.1099/jmm.0.034181-0>. PMID:21757501.
- Chalmers RM, Giles M. Zoonotic cryptosporidiosis in the UK - challenges for control. *J Appl Microbiol* 2010; 109(5): 1487-1497. <http://dx.doi.org/10.1111/j.1365-2672.2010.04764.x>. PMID:20497274.
- Chalmers RM, Katzer F. Looking for *Cryptosporidium*: the application of advances in detection and diagnosis. *Trends Parasitol* 2013; 29(5): 237-251. <http://dx.doi.org/10.1016/j.pt.2013.03.001>. PMID:23566713.
- Chvala S, Fragner K, Hackl R, Hess M, Weissenböck H. *Cryptosporidium* infection in domestic geese (*Anser anser f. domestica*) detected by in-situ hybridization. *J Comp Pathol* 2006; 134(2-3): 211-218. <http://dx.doi.org/10.1016/j.jcpa.2005.11.002>. PMID:16615936.
- Clubb S. What is your diagnosis? *J Avian Med Surg* 1997; 11(1): 41-42.
- Coldwell L, Caldow G, Holliman A, Mearns R, Errington H, Giles M, et al. *Cryptosporidium baileyi* in wild red grouse with 'bulgy eye'. *Vet Rec* 2012; 170(23): 603-604. <http://dx.doi.org/10.1136/vr.e3940>. PMID:22696475.
- Current WL, Upton SJ, Haynes TB. The life cycle of *Cryptosporidium baileyi* n. sp. (Apicomplexa, Cryptosporidiidae) infecting chickens. *J Protozool* 1986; 33(2): 289-296. <http://dx.doi.org/10.1111/j.1550-7408.1986.tb05608.x>. PMID:3735157.
- Darabus G, Olariu R. The homologous and interspecies transmission of *Cryptosporidium parvum* and *Cryptosporidium meleagridis*. *Pol J Vet Sci* 2003; 6(3): 225-228. PMID:14510055.
- Darabus G. Experimental studies of inter-and intraspecific transmission of *Cryptosporidium parvum* and *C. meleagridis*. *Rev Rom Med Vet* 1997; 7: 155-160.
- Dhillon AS, Thacker HL, Dietzel AV, Winterfield RW. Respiratory cryptosporidiosis in broiler chickens. *Avian Dis* 1981; 25(3): 747-751. <http://dx.doi.org/10.2307/1590007>. PMID:7316908.
- Eladl AH, Hamed HR, Khalil MR. Consequence of Cryptosporidiosis on the immune response of vaccinated broiler chickens against Newcastle disease and/or avian influenza. *Vet Res Commun* 2014; 38(3): 237-247. <http://dx.doi.org/10.1007/s11259-014-9610-5>. PMID:24993748.
- Elliot A, Morgan UM, Thompson RCA. Improved staining method for detecting *Cryptosporidium* oocysts in stools using malachite green. *J Gen Appl Microbiol* 1999; 45(3): 139-142. <http://dx.doi.org/10.2323/jgam.45.139>. PMID:12501386.
- Elwin K, Hadfield SJ, Robinson G, Chalmers RM. The epidemiology of sporadic human infections with unusual cryptosporidia detected during routine typing in England and Wales, 2000-2008. *Epidemiol Infect* 2012; 140(4): 673-683. <http://dx.doi.org/10.1017/S0950268811000860>. PMID:21733255.
- Fayer R. General biology. In: Fayer R, Xiao L, editors. *Cryptosporidium and Cryptosporidiosis*. Boca Raton: CRC; 2008. p. 1-42.
- Fayer R. Taxonomy and species delimitation in *Cryptosporidium*. *Exp Parasitol* 2010; 124(1): 90-97. <http://dx.doi.org/10.1016/j.exppara.2009.03.005>. PMID:19303009.
- Fletcher OJ, Munnell JF, Page RK. Cryptosporidiosis of the bursa of Fabricius of chickens. *Avian Dis* 1975; 19(3): 630-639. <http://dx.doi.org/10.2307/1589092>. PMID:1164328.
- Gharagozlou MJ, Dezfulian O, Rahbari S, Bokaie S, Jahanzad I, Razavi ANE. Intestinal cryptosporidiosis in turkeys in Iran. *J Vet Med A Physiol Pathol Clin Med* 2006; 53(6): 282-285. <http://dx.doi.org/10.1111/j.1439-0442.2006.00843.x>. PMID:16901269.
- Glisson JR, Brown TP, Brugh M, Page RK, Kleven SH, Davis RB. Sinusitis in turkeys associated with respiratory cryptosporidiosis. *Avian Dis* 1984; 28(3): 783-790. <http://dx.doi.org/10.2307/1590250>. PMID:6487198.
- Gomes RS, Huber F, da Silva S, do Bomfim TC. *Cryptosporidium* spp. parasitize exotic birds that are commercialized in markets, commercial aviaries, and pet shops. *Parasitol Res* 2012; 110(4): 1363-1370. <http://dx.doi.org/10.1007/s00436-011-2636-5>. PMID:21922240.
- Goodwin MA, Brown J, Resurreccion RS, Smith JA. Respiratory coccidiosis (*Cryptosporidium baileyi*) among northern Georgia broilers in one company. *Avian Dis* 1996; 40(3): 572-575. <http://dx.doi.org/10.2307/1592266>. PMID:8883786.
- Goodwin MA, Brown J. Intestinal cryptosporidiosis in chickens. *Avian Dis* 1989; 33(4): 770-777. <http://dx.doi.org/10.2307/1591159>. PMID:2619667.
- Goodwin MA, Krabill VA. Diarrhea associated with small-intestinal cryptosporidiosis in a budgerigar and in a cockatiel. *Avian Dis* 1989; 33(4): 829-833. <http://dx.doi.org/10.2307/1591170>. PMID:2619673.
- Goodwin MA, Steffens WL, Russell ID, Brown J. Diarrhea associated with intestinal Cryptosporidiosis in turkeys. *Avian Dis* 1988; 32(1): 63-67. <http://dx.doi.org/10.2307/1590949>. PMID:3382381.
- Goodwin MA. Cryptosporidiosis in birds-a review. *Avian Pathol* 1989; 18(3): 365-384. <http://dx.doi.org/10.1080/03079458908418612>. PMID:18679870.

- Goodwin MA. Small-intestinal cryptosporidiosis in a chicken. *Avian Dis* 1988; 32(4): 844-848. <http://dx.doi.org/10.2307/1591011>. PMID:3202780.
- Gorham SL, Mallinson ET, Synder DB, Odor EM. Cryptosporidia in the bursa of Fabricius—a correlation with mortality rates in broiler chickens. *Avian Pathol* 1987; 16(2): 205-211. <http://dx.doi.org/10.1080/03079458708436369>. PMID:18766608.
- Graczyk TK, Cranfield MR, Fayer R. Evaluation of commercial enzyme immunoassay (EIA) and immunofluorescent antibody (FA) test kits for detection of *Cryptosporidium* oocysts of species other than *Cryptosporidium parvum*. *Am J Trop Med Hyg* 1996; 54(3): 274-279. PMID:8600765.
- Graczyk TK, Fayer R, Trout JM, Lewis EJ, Farley CA, Sulaiman I, et al. *Giardia* sp. cysts and infectious *Cryptosporidium parvum* oocysts in the feces of migratory Canada geese (*Branta canadensis*). *Appl Environ Microbiol* 1998; 64(7): 2736-2738. PMID:9647860.
- Graczyk TK, Majewska AC, Schwab KJ. The role of birds in dissemination of human waterborne enteropathogens. *Trends Parasitol* 2008; 24(2): 55-59. <http://dx.doi.org/10.1016/j.pt.2007.10.007>. PMID:18165154.
- Guy JS, Levy MG, Ley DH, Barnes HJ, Gerig TM. Experimental reproduction of enteritis in bobwhite quail (*Colinus virginianus*) with *Cryptosporidium* and reovirus. *Avian Dis* 1987; 31(4): 713-722. <http://dx.doi.org/10.2307/1591021>. PMID:2831866.
- Guy JS, Levy MG, Ley DH, Barnes HJ, Gerig TM. Interaction of reovirus and *Cryptosporidium baileyi* in experimentally infected chickens. *Avian Dis* 1988; 32(3): 381-390. <http://dx.doi.org/10.2307/1590901>. PMID:2848481.
- Hao YX, Yang JM, He C, Liu Q, McAllister TA. Reduced serologic response to avian influenza vaccine in specific-pathogen-free chicks inoculated with *Cryptosporidium baileyi*. *Avian Dis* 2008; 52(4): 690-693. <http://dx.doi.org/10.1637/8370-052608-Reg.1>. PMID:19166065.
- Henriksen SA, Pohlenz JFL. Staining of cryptosporidia by a modified Ziehl-Neelsen technique. *Acta Vet Scand* 1981; 22(3-4): 594-596. PMID:6178277.
- Hoerr FJ, Current WL, Haynes TB. Fatal cryptosporidiosis in quail. *Avian Dis* 1986; 30(2): 421-425. <http://dx.doi.org/10.2307/1590550>. PMID:3729889.
- Hornok S, Heijmans JF, Békési L, Peek HW, Dobos-Kovács M, Drén CN, et al. Interaction of chicken anaemia virus and *Cryptosporidium baileyi* in experimentally infected chickens. *Vet Parasitol* 1998; 76(1-2): 43-55. [http://dx.doi.org/10.1016/S0304-4017\(97\)00046-0](http://dx.doi.org/10.1016/S0304-4017(97)00046-0). PMID:9653989.
- Huber F, da Silva S, Bomfim TCB, Teixeira KRS, Bello AR. Genotypic characterization and phylogenetic analysis of *Cryptosporidium* sp. from domestic animals in Brazil. *Vet Parasitol* 2007; 150(1-2): 65-74. <http://dx.doi.org/10.1016/j.vetpar.2007.08.018>. PMID:17905514.
- Insulander M, Silverlås C, Lebbad M, Karlsson L, Mattsson JG, Svenungsson B. Molecular epidemiology and clinical manifestations of human cryptosporidiosis in Sweden. *Epidemiol Infect* 2013; 141(5): 1009-1020. <http://dx.doi.org/10.1017/S0950268812001665>. PMID:22877562.
- Itakura C, Goryo M, Umemura T. Cryptosporidial infection in chickens. *Avian Pathol* 1984; 13(3): 487-499. <http://dx.doi.org/10.1080/03079458408418550>. PMID:18766863.
- Jardine JE, Verwoerd DJ. Pancreatic cryptosporidiosis in ostriches. *Avian Pathol* 1997; 26(3): 665-670. <http://dx.doi.org/10.1080/03079459708419243>. PMID:18483936.
- Jellison KL, Distel DL, Hemond HF, Schauer DB. Phylogenetic analysis of the hypervariable region of the 18S rRNA gene of *Cryptosporidium* oocysts in feces of Canada geese (*Branta canadensis*): evidence for five novel genotypes. *Appl Environ Microbiol* 2004; 70(1): 452-458. <http://dx.doi.org/10.1128/AEM.70.1.452-458.2004>. PMID:14711674.
- Jex AR, Smith HV, Monis PT, Campbell BE, Gasser RB. *Cryptosporidium* – biotechnological advances in the detection, diagnosis and analysis of genetic variation. *Biotechnol Adv* 2008; 26(4): 304-317. <http://dx.doi.org/10.1016/j.biotechadv.2008.02.003>. PMID:18430539.
- Kik MJL, van Asten AJAM, Lenstra JA, Kirpensteijn J. Cloaca prolapse and cystitis in green iguana (*Iguana iguana*) caused by a novel *Cryptosporidium* species. *Vet Parasitol* 2011; 175(1-2): 165-167. <http://dx.doi.org/10.1016/j.vetpar.2010.10.002>. PMID:21036480.
- Latimer KS, Goodwin MA, Davis MK. Rapid cytologic diagnosis of respiratory cryptosporidiosis in chickens. *Avian Dis* 1988; 32(4): 826-830. <http://dx.doi.org/10.2307/1591006>. PMID:2462413.
- Levy MG, Ley DH, Barnes HJ, Gerig TM, Corbett WT. Experimental cryptosporidiosis and infectious bursal disease virus infection of specific-pathogen-free chickens. *Avian Dis* 1988; 32(4): 803-811. <http://dx.doi.org/10.2307/1591002>. PMID:2849406.
- Ley DH, Moresco A, Frasca S Jr. Conjunctivitis, rhinitis, and sinusitis in cliff swallows (*Petrochelidon pyrrhonota*) found in association with *Mycoplasma sturni* infection and cryptosporidiosis. *Avian Pathol* 2012; 41(4): 395-401. <http://dx.doi.org/10.1080/03079457.2012.697624>. PMID:22834555.
- Li J, Lin X, Zhang L, Qi N, Liao S, Lv M, et al. Molecular characterization of *Cryptosporidium* spp. in domestic pigeons (*Columba livia domestica*) in Guangdong Province, Southern China. *Parasitol Res* 2015; 114(6): 2237-2241. <http://dx.doi.org/10.1007/s00436-015-4415-1>. PMID:25773186.
- Li N, Xiao L, Wang L, Zhao S, Zhao X, Duan L, et al. Molecular surveillance of *Cryptosporidium* spp., *Giardia duodenalis*, and *Enterocytozoon bieneusi* by genotyping and subtyping parasites in wastewater. *PLoS Negl Trop Dis* 2012; 6(9): e1809.
- Lindsay DS, Blagburn BL, Ernest JA. Experimental *Cryptosporidium parvum* infections in chickens. *J Parasitol* 1987a; 73(1): 242-244. <http://dx.doi.org/10.2307/3282381>. PMID:3572661.
- Lindsay DS, Blagburn BL, Hoerr FJ. Small intestinal cryptosporidiosis in cockatiels associated with *Cryptosporidium baileyi*-like oocysts. *Avian Dis* 1990; 34(3): 791-793. <http://dx.doi.org/10.2307/1591283>. PMID:2241709.
- Lindsay DS, Blagburn BL, Sundermann CA, Ernest JA. Chemoprophylaxis of cryptosporidiosis in chickens, using halofuginone, salinomycin, lasalocid, or monensin. *Am J Vet Res* 1987b; 48(3): 354-355. PMID:3565889.
- Lindsay DS, Blagburn BL, Sundermann CA. Morphometric comparison of the oocysts of *Cryptosporidium meleagridis* and *Cryptosporidium baileyi* from birds. *Proc Helminthol Soc Wash* 1989; 56(1): 91-92.
- Máca O, Pavlásek I. First finding of spontaneous infections with *Cryptosporidium baileyi* and *C. meleagridis* in the red-legged partridge *Alectoris rufa* from an aviary in the Czech Republic. *Vet Parasitol* 2015; 209(3-4): 164-168. <http://dx.doi.org/10.1016/j.vetpar.2015.03.003>. PMID:25814162.
- Makino I, Abe N, Reavill DR. *Cryptosporidium* avian genotype III as a possible causative agent of chronic vomiting in peach-faced lovebirds (*Agapornis roseicollis*). *Avian Dis* 2010; 54(3): 1102-1107. <http://dx.doi.org/10.1637/9227-123009-Case.1>. PMID:20945797.
- Mason RW, Hartley WJ. Respiratory cryptosporidiosis in a peacock chick. *Avian Dis* 1980; 24(3): 771-776. <http://dx.doi.org/10.2307/1589814>. PMID:7447841.

- Mason RW. Conjunctival cryptosporidiosis in a duck. *Avian Dis* 1986; 30(3): 598-600. <http://dx.doi.org/10.2307/1590428>. PMID:3767818.
- McEvoy JM, Giddings CW. *Cryptosporidium* in commercially produced turkeys on-farm and postslaughter. *Lett Appl Microbiol* 2009; 48(3): 302-306. <http://dx.doi.org/10.1111/j.1472-765X.2008.02516.x>. PMID:19187504.
- Meireles MV, Figueiredo PC. Isolamento e identificação do *Cryptosporidium baileyi* Current et al. 1986 (Apicomplexa:Cryptosporidiidae) em frangos de corte. *Rev Bras Parasitol Vet* 1992; 1(2): 125-130.
- Meireles MV, Paulillo AC, Costa AJ, Moraes FR, Ávila FA, Silva GS. Correlação entre *Toxoplasma gondii* e *Cryptosporidium baileyi* em frangos de corte experimentalmente infectados. *Rev Bras Parasitol Vet* 1995; 4(2): 105-112.
- Meireles MV, Paulillo AC, Silva GS, Costa AJ, Júnior LD, Machado RZ. Infecção experimental por *Cryptosporidium baileyi* em aves de corte: I – Aspectos clínicos, parasitológicos e zootécnicos. *Rev Bras Parasitol Vet* 1998a; 7(1): 11-14.
- Meireles MV, Paulillo AC, Silva GS, Costa AJ, Luvizotto MCR, Júnior LD, et al. Influência da infecção experimental com *Cryptosporidium baileyi* na resposta imune de frangos de corte vacinados contra a doença de Newcastle. *Rev Bras Cienci Vet* 1998b; 5(1): 15-19.
- Meireles MV, Paulillo AC, Silva GS, Luvizotto MCR, Costa AJ, Andreatti RL Fo. Experimental infection with *Cryptosporidium baileyi* in broilers raised on floor-pens. *Braz J Poult Sci* 1999; 1(1): 37-42.
- Meireles MV, Soares RM, Santos MM, Gennari SM. Biological studies and molecular characterization of a *Cryptosporidium* isolate from ostriches (*Struthio camelus*). *J Parasitol* 2006; 92(3): 623-626. [http://dx.doi.org/10.1645/0022-3395\(2006\)92\[623:BSAMCO\]2.0.CO;2](http://dx.doi.org/10.1645/0022-3395(2006)92[623:BSAMCO]2.0.CO;2). PMID:16884009.
- Molina-Lopez RA, Ramis A, Martín-Vazquez S, Gómez-Couso H, Ares-Mazás E, Cacciò SM, et al. *Cryptosporidium baileyi* infection associated with an outbreak of ocular and respiratory disease in otus owls (*Otus scops*) in a rehabilitation centre. *Avian Pathol* 2010; 39(3): 171-176. <http://dx.doi.org/10.1080/03079451003717589>. PMID:20544422.
- Morgan UM, Monis PT, Xiao L, Limor J, Sulaiman I, Raidal S, et al. Molecular and phylogenetic characterisation of *Cryptosporidium* from birds. *Int J Parasitol* 2001; 31(3): 289-296. [http://dx.doi.org/10.1016/S0020-7519\(00\)00164-8](http://dx.doi.org/10.1016/S0020-7519(00)00164-8). PMID:11226456.
- Morgan UM, Xiao L, Limor J, Gelis S, Raidal SR, Fayer R, et al. *Cryptosporidium meleagridis* in an Indian ring-necked parrot (*Psittacula krameri*). *Aust Vet J* 2000; 78(3): 182-183. <http://dx.doi.org/10.1111/j.1751-0813.2000.tb10589.x>. PMID:10860158.
- Murakami S, Miyama M, Ogawa A, Shimada J, Nakane T. Occurrence of conjunctivitis, sinusitis and upper region tracheitis in Japanese quail (*Coturnix coturnix japonica*), possibly caused by *Mycoplasma gallisepticum* accompanied by *Cryptosporidium* sp. infection. *Avian Pathol* 2002; 31(4): 363-370. <http://dx.doi.org/10.1080/030794502201633>. PMID:12396337.
- Naciri M, Mazzella O, Coudert F. Interactions cryptosporidies-virus sauvage ou vaccinal de la maladie de Marek chez le poulet. *Rec Méd Vét* 1989; 165(4): 383-387.
- Nakamura AA, Homem CG, Silva AMJ, Meireles MV. Diagnosis of gastric cryptosporidiosis in birds using a duplex real-time PCR assay. *Vet Parasitol* 2014; 205(1-2): 7-13. <http://dx.doi.org/10.1016/j.vetpar.2014.07.033>. PMID:25155280.
- Nakamura AA, Simões DC, Antunes RG, Silva DC, Meireles MV. Molecular characterization of *Cryptosporidium* spp. from fecal samples of birds kept in captivity in Brazil. *Vet Parasitol* 2009; 166(1-2): 47-51. <http://dx.doi.org/10.1016/j.vetpar.2009.07.033>. PMID:19683397.
- Nakamura K, Abe F. Respiratory (especially pulmonary) and urinary infections of *Cryptosporidium* in layer chickens. *Avian Pathol* 1988; 17(3): 703-711. <http://dx.doi.org/10.1080/03079458808436487>. PMID:18766726.
- Ng J, Pavlasek I, Ryan U. Identification of novel *Cryptosporidium* genotypes from avian hosts. *Appl Environ Microbiol* 2006; 72(12): 7548-7553. <http://dx.doi.org/10.1128/AEM.01352-06>. PMID:17028234.
- Nguyen ST, Fukuda Y, Tada C, Huynh VV, Nguyen DT, Nakai Y. Prevalence and molecular characterization of *Cryptosporidium* in ostriches (*Struthio camelus*) on a farm in central Vietnam. *Exp Parasitol* 2013; 133(1): 8-11. <http://dx.doi.org/10.1016/j.exppara.2012.10.010>. PMID:23142549.
- O'Donoghue PJ, Tham VL, de Saram WG, Paull KL, McDermott S. *Cryptosporidium* infections in birds and mammals and attempted cross-transmission studies. *Vet Parasitol* 1987; 26(1-2): 1-11. [http://dx.doi.org/10.1016/0304-4017\(87\)90071-9](http://dx.doi.org/10.1016/0304-4017(87)90071-9). PMID:2964117.
- Oliveira FCR, Ederli NB, Ederli BB, Albuquerque MC, Santos MD. [Occurrence of *Cryptosporidium* spp. oocysts (Apicomplexa, Cryptosporidiidae) in ostriches, *Struthio camelus* L., 1758 (Aves, Struthionidae) reared in North and Lowered Coastline regions of the state of Rio de Janeiro, Brazil]. *Rev Bras Parasitol Vet* 2008; 17(1 Suppl 1): 322-325. PMID:20059869.
- Ortolani EL. Standardization of the modified Ziehl-Neelsen technique to stain oocysts of *Cryptosporidium*. *Rev Bras Parasitol Vet* 2000; 9(1): 29-31.
- Özkul IA, Aydin Y. Small-intestinal cryptosporidiosis in a young pigeon. *Avian Pathol* 1994; 23(2): 369-372. <http://dx.doi.org/10.1080/03079459408419006>. PMID:18671103.
- Pagès-Manté A, Pagès-Bosch M, Majó-Masferrer N, Gómez-Couso H, Ares-Mazás E. An outbreak of disease associated with cryptosporidia on a red-legged partridge (*Alectoris rufa*) game farm. *Avian Pathol* 2007; 36(4): 275-278. <http://dx.doi.org/10.1080/03079450701439389>. PMID:17620172.
- Palković L, Maroušek V. The pathogenicity of *Cryptosporidium parvum* Tyzzer, 1912 and *C. baileyi* Current, Upton et Haynes, 1986 for chickens. *Folia Parasitol (Praha)* 1989; 36(3): 209-217. PMID:2583611.
- Pavlásek I. Cryptosporidia: Biology, diagnosis, host spectrum, specificity, and the environment. *Remed Klinicka Mikrobiol* 1999; 3: 290-301.
- Penrith ML, Bezuidenhout AJ, Burger WP, Putterill JF. Evidence for cryptosporidial infection as a cause of prolapse of the phallus and cloaca in ostrich chicks (*Struthio camelus*). *Onderstepoort J Vet Res* 1994; 61(4): 283-289. PMID:7501359.
- Penrith ML, Burger WPAA. A *Cryptosporidium* sp. in an ostrich. *J S Afr Vet Assoc* 1993; 64(2): 60-61. PMID:8410943.
- Plutzer J, Tomor B. The role of aquatic birds in the environmental dissemination of human pathogenic *Giardia duodenalis* cysts and *Cryptosporidium* oocysts in Hungary. *Parasitol Int* 2009; 58(3): 227-231. <http://dx.doi.org/10.1016/j.parint.2009.05.004>. PMID:19446039.
- Proctor SJ, Kemp RL. *Cryptosporidium anserinum* sp. n. (Sporozoa) in a domestic goose *Anser anser* L., from Iowa. *J Protozool* 1974; 21(5): 664-666. <http://dx.doi.org/10.1111/j.1550-7408.1974.tb03724.x>. PMID:4217367.
- Qi M, Huang L, Wang R, Xiao L, Xu L, Li J, et al. Natural infection of *Cryptosporidium muris* in ostriches (*Struthio camelus*). *Vet Parasitol* 2014; 205(3-4): 518-522. <http://dx.doi.org/10.1016/j.vetpar.2014.06.035>. PMID:25178556.

- Qi M, Wang R, Ning C, Li X, Zhang L, Jian F, et al. *Cryptosporidium* spp. in pet birds: genetic diversity and potential public health significance. *Exp Parasitol* 2011; 128(4): 336-340. <http://dx.doi.org/10.1016/j.exppara.2011.04.003>. PMID:21557938.
- Quah JX, Ambu S, Lim YAL, Mahdy MAK, Mak JW. Molecular identification of *Cryptosporidium parvum* from avian hosts. *Parasitology* 2011; 138(5): 573-577. <http://dx.doi.org/10.1017/S0031182010001691>. PMID:21232175.
- Radfar MH, Asl EN, Seghinsara HR, Dehaghi MM, Fathi S. Biodiversity and prevalence of parasites of domestic pigeons (*Columba livia domestica*) in a selected semiarid zone of South Khorasan, Iran. *Trop Anim Health Prod* 2012; 44(2): 225-229. <http://dx.doi.org/10.1007/s11250-011-0002-3>. PMID:22081317.
- Ramirez NE, Ward LA, Sreevatsan S. A review of the biology and epidemiology of cryptosporidiosis in humans and animals. *Microbes Infect* 2004; 6(8): 773-785. <http://dx.doi.org/10.1016/j.micinf.2004.02.021>. PMID:15207825.
- Randall CJ. Conjunctivitis in pheasants associated with cryptosporidial infection. *Vet Rec* 1986; 118(8): 211. <http://dx.doi.org/10.1136/vr.118.8.211>. PMID:3716166.
- Ravich ML, Reavill DR, Hess L, Childress AL, Wellehan JFX Jr. Gastrointestinal cryptosporidiosis in captive psittacine birds in the United States: a case review. *J Avian Med Surg* 2014; 28(4): 297-303. <http://dx.doi.org/10.1647/1082-6742-28.4.297>. PMID:25843467.
- Reboredo-Fernández A, Ares-Mazás E, Cacciò SM, Gómez-Couso H. Occurrence of *Giardia* and *Cryptosporidium* in wild birds in Galicia (Northwest Spain). *Parasitology* 2015; 142(7): 917-925. <http://dx.doi.org/10.1017/S0031182015000049>. PMID:25669618.
- Rhee JK, Kim HC, Lee SB, Yook SY. Immunosuppressive effect of *Cryptosporidium baileyi* infection on vaccination against Newcastle disease in chicks. *Korean J Parasitol* 1998a; 36(2): 121-125. <http://dx.doi.org/10.3347/kjp.1998.36.2.121>. PMID:9637829.
- Rhee JK, Yang HJ, Yook SY, Kim HC. Immunosuppressive effect of *Cryptosporidium baileyi* infection on vaccination against avian infectious bronchitis in chicks. *Korean J Parasitol* 1998b; 36(3): 203-206. <http://dx.doi.org/10.3347/kjp.1998.36.3.203>. PMID:9755592.
- Rhee JK, Yang HJ, Kim HC. Verification of immunosuppression in chicks caused by *Cryptosporidium baileyi* infection using Brucella abortus strain 1119-3. *Korean J Parasitol* 1998c; 36(4): 281-284. <http://dx.doi.org/10.3347/kjp.1998.36.4.281>. PMID:9868895.
- Richter D, Wiegand-Tripp G, Burkhardt E, Kaleta EF. Natural infections by *Cryptosporidium* sp. in farm-raised ducks and geese. *Avian Pathol* 1994; 23(2): 277-286. <http://dx.doi.org/10.1080/03079459408418995>. PMID:18671092.
- Ritter GD, Ley DH, Levy M, Guy J, Barnes HJ. Intestinal cryptosporidiosis and reovirus isolation from bobwhite quail (*Colinus virginianus*) with enteritis. *Avian Dis* 1986; 30(3): 603-608. <http://dx.doi.org/10.2307/1590430>. PMID:3021104.
- Rohela M, Lim YA, Jamaiah I, Khadijah PYY, Laang ST, Nazri MH, et al. Occurrence of *Cryptosporidium* oocysts in wrinkled hornbill and other birds in the Kuala Lumpur National Zoo. *Southeast Asian J Trop Med Public Health* 2005;36(S4 Suppl 4): 34-40. PMID:16438177.
- Ryan U, Fayer R, Xiao L. *Cryptosporidium* species in humans and animals: current understanding and research needs. *Parasitology* 2014; 141(13): 1667-1685. <http://dx.doi.org/10.1017/S0031182014001085>. PMID:25111501.
- Ryan U, Hijjawi N. New developments in *Cryptosporidium* research. *Int J Parasitol* 2015; 45(6): 367-373. <http://dx.doi.org/10.1016/j.ijpara.2015.01.009>. PMID:25769247.
- Ryan U, Xiao L, Read C, Zhou L, Lal AA, Pavlásek I. Identification of novel *Cryptosporidium* genotypes from the Czech Republic. *Appl Environ Microbiol* 2003b; 69(7): 4302-4307. <http://dx.doi.org/10.1128/AEM.69.7.4302-4307.2003>. PMID:12839819.
- Ryan U. *Cryptosporidium* in birds, fish and amphibians. *Exp Parasitol* 2010; 124(1): 113-120. <http://dx.doi.org/10.1016/j.exppara.2009.02.002>. PMID:19545515.
- Ryan UM, Xiao L, Read C, Sulaiman IM, Monis P, Lal AA, et al. A redescription of *Cryptosporidium galli* Pavlasek, 1999 (Apicomplexa: Cryptosporidiidae) from birds. *J Parasitol* 2003a; 89(4): 809-813. <http://dx.doi.org/10.1645/GE-74RI>. PMID:14533694.
- Santín M. Clinical and subclinical infections with *Cryptosporidium* in animals. *N Z Vet J* 2013; 61(1): 1-10. <http://dx.doi.org/10.1080/00480169.2012.731681>. PMID:23134088.
- Santos MMAB, Peiró JR, Meireles MV. *Cryptosporidium* infection in ostriches (*Struthio camelus*) in Brazil: clinical, morphological and molecular studies. *Braz J Poult Sci* 2005; 7(2): 113-117.
- Schulze C, Kämmerling J, Kutzer P, Engelhardt A, Richter B. *Cryptosporidium baileyi* - infection in Red-breasted Merganser (*Mergus serrator*) ducklings from a zoological garden. *Berl Munch Tierarztl Wochenschr* 2012; 125(9-10): 428-431. PMID:23045806.
- Scott TR. Our current understanding of humoral immunity of poultry. *Poult Sci* 2004; 83(4): 574-579. <http://dx.doi.org/10.1093/ps/83.4.574>. PMID:15109054.
- Sevá AP, Funada MR, Richtzenhain L, Guimarães MB, Souza SO, Allegratti L, et al. Genotyping of *Cryptosporidium* spp. from free-living wild birds from Brazil. *Vet Parasitol* 2011; 175(1-2): 27-32. <http://dx.doi.org/10.1016/j.vetpar.2010.09.031>. PMID:21035268.
- Shahiduzzaman M, Dausgschies A. Therapy and prevention of cryptosporidiosis in animals. *Vet Parasitol* 2012; 188(3-4): 203-214. <http://dx.doi.org/10.1016/j.vetpar.2012.03.052>. PMID:22521978.
- Silva DC, Homem CG, Nakamura AA, Teixeira WF, Perri SH, Meireles MV. Physical, epidemiological, and molecular evaluation of infection by *Cryptosporidium galli* in Passeriformes. *Parasitol Res* 2010; 107(2): 271-277. <http://dx.doi.org/10.1007/s00436-010-1858-2>. PMID:20407911.
- Silverlås C, Mattsson JG, Insulander M, Lebbad M. Zoonotic transmission of *Cryptosporidium meleagridis* on an organic Swedish farm. *Int J Parasitol* 2012; 42(11): 963-967. <http://dx.doi.org/10.1016/j.ijpara.2012.08.008>. PMID:23022616.
- Šlapeta J. Cryptosporidiosis and *Cryptosporidium* species in animals and humans: a thirty colour rainbow? *Int J Parasitol* 2013; 43(12-13): 957-970. <http://dx.doi.org/10.1016/j.ijpara.2013.07.005>. PMID:23973380.
- Slavin D. *Cryptosporidium meleagridis* (sp. nov.). *J Comp Pathol* 1955; 65(3): 262-266. [http://dx.doi.org/10.1016/S0368-1742\(55\)80025-2](http://dx.doi.org/10.1016/S0368-1742(55)80025-2). PMID:13242675.
- Smith HV, Cacciò SM, Cook N, Nichols RAB, Tait A. *Cryptosporidium* and *Giardia* as foodborne zoonoses. *Vet Parasitol* 2007; 149(1-2): 29-40. <http://dx.doi.org/10.1016/j.vetpar.2007.07.015>. PMID:17728067.
- Smith HV, Corcoran GD. New drugs and treatment for cryptosporidiosis. *Curr Opin Infect Dis* 2004; 17(6): 557-564. <http://dx.doi.org/10.1097/00001432-200412000-00008>. PMID:15640710.

- Snyder DB, Current WL, Russek-Cohen E, Gorham SL, Mallinson ET, Marquardt WW, et al. Serologic incidence of *Cryptosporidium* in Delmarva broiler flocks. *Poult Sci* 1988; 67(5): 730-735. <http://dx.doi.org/10.3382/ps.0670730>. PMID:3405949.
- Sréter T, Kovács G, Silva AJ, Pieniazek NJ, Széll Z, Dobos-Kovács M, et al. Morphologic, host specificity, and molecular characterization of a Hungarian *Cryptosporidium meleagridis* isolate. *Appl Environ Microbiol* 2000; 66(2): 735-738. <http://dx.doi.org/10.1128/AEM.66.2.735-738.2000>. PMID:10653744.
- Sréter T, Varga I. Cryptosporidiosis in birds - a review. *Vet Parasitol* 2000; 87(4): 261-279. [http://dx.doi.org/10.1016/S0304-4017\(99\)00178-8](http://dx.doi.org/10.1016/S0304-4017(99)00178-8). PMID:10669097.
- Stensvold CR, Beser J, Axén C, Lebbad M. High applicability of a novel method for gp60-based subtyping of *Cryptosporidium meleagridis*. *J Clin Microbiol* 2014; 52(7): 2311-2319. <http://dx.doi.org/10.1128/JCM.00598-14>. PMID:24740082.
- Striepen B. Parasitic infections: time to tackle cryptosporidiosis. *Nature* 2013; 503(7475): 189-191. <http://dx.doi.org/10.1038/503189a>. PMID:24236315.
- Tarwid JN, Cawthorn RJ, Riddell C. Cryptosporidiosis in the respiratory tract of turkeys in Saskatchewan. *Avian Dis* 1985; 29(2): 528-532. <http://dx.doi.org/10.2307/1590516>. PMID:4026742.
- Teixeira WFP, Coelho WMD, Nunes CM, Meireles MV. Detection of *Cryptosporidium parvum* oocysts in calf fecal samples by direct immunofluorescence assay. *Rev Bras Parasitol Vet* 2011b; 20(4): 269-273. <http://dx.doi.org/10.1590/S1984-29612011000400003>. PMID:22166379.
- Teixeira WFP, Coelho WMD, Soutello RVG, Oliveira FP, Homem CG, Nunes CM, et al. Diagnóstico de criptosporidiose em amostras fecais de bezerros por imunofluorescência direta e microscopia de contraste de fase. *Cienc Rural* 2011a; 41(6): 1057-1062. <http://dx.doi.org/10.1590/S0103-84782011005000077>.
- Tham VL, Kniesberg S, Dixon BR. Cryptosporidiosis in quails. *Avian Pathol* 1982; 11(4): 619-626. <http://dx.doi.org/10.1080/03079458208436138>. PMID:18770229.
- Tyzzer EE. Coccidiosis in gallinaceous birds. *Am J Epidemiol* 1929; 10(2): 269-383.
- Valigurová A, Jirků M, Koudela B, Gelnar M, Modrý D, Šlapeta J. Cryptosporidia: epicellular parasites embraced by the host cell membrane. *Int J Parasitol* 2008; 38(8-9): 913-922. <http://dx.doi.org/10.1016/j.ijpara.2007.11.003>. PMID:18158154.
- van Zeeland YRA, Schoemaker NJ, Kik MJL, van der Giessen JWB. Upper respiratory tract infection caused by *Cryptosporidium baileyi* in three mixed-bred falcons (*Falco rusticolus* x *Falco cherrug*). *Avian Dis* 2008; 52(2): 357-363. <http://dx.doi.org/10.1637/8121-100207-Case.1>. PMID:18646471.
- Wages DP, Ficken MD. Cryptosporidiosis and turkey viral hepatitis in turkeys. *Avian Dis* 1989; 33(1): 191-194. <http://dx.doi.org/10.2307/1591088>. PMID:2930401.
- Wang L, Xue X, Li J, Zhou Q, Yu Y, Du A. Cryptosporidiosis in broiler chickens in Zhejiang Province, China: molecular characterization of oocysts detected in fecal samples. *Parasite* 2014b; 21: 36. <http://dx.doi.org/10.1051/parasite/2014035>. PMID:25075975.
- Wang R, Jian F, Sun Y, Hu Q, Zhu J, Wang F, et al. Large-scale survey of *Cryptosporidium* spp. in chickens and Pekin ducks (*Anas platyrhynchos*) in Henan, China: prevalence and molecular characterization. *Avian Pathol* 2010; 39(6): 447-451. <http://dx.doi.org/10.1080/03079457.2010.518314>. PMID:21154053.
- Wang R, Qi M, Jingjing Z, Sun D, Ning C, Zhao J, et al. Prevalence of *Cryptosporidium baileyi* in ostriches (*Struthio camelus*) in Zhengzhou, China. *Vet Parasitol* 2011; 175(1-2): 151-154. <http://dx.doi.org/10.1016/j.vetpar.2010.10.005>. PMID:21030152.
- Wang R, Wang F, Zhao J, Qi M, Ning C, Zhang L, et al. *Cryptosporidium* spp. in quails (*Coturnix coturnix japonica*) in Henan, China: molecular characterization and public health significance. *Vet Parasitol* 2012; 187(3-4): 534-537. <http://dx.doi.org/10.1016/j.vetpar.2012.02.002>. PMID:22377447.
- Wang Y, Yang W, Cama V, Wang L, Cabrera L, Ortega Y, et al. Population genetics of *Cryptosporidium meleagridis* in humans and birds: evidence for cross-species transmission. *Int J Parasitol* 2014a; 44(8): 515-521. <http://dx.doi.org/10.1016/j.ijpara.2014.03.003>. PMID:24727090.
- Woodmansee DB, Pavlásek I, Pohlenz JFL, Moon HW. Subclinical cryptosporidiosis of turkeys in Iowa. *J Parasitol* 1988; 74(5): 898-900. <http://dx.doi.org/10.2307/3282279>. PMID:3418465.
- Xiao L, Fayer R, Ryan U, Upton SJ. *Cryptosporidium* taxonomy: recent advances and implications for public health. *Clin Microbiol Rev* 2004; 17(1): 72-97. <http://dx.doi.org/10.1128/CMR.17.1.72-97.2004>. PMID:14726456.
- Xiao L, Fayer R. Molecular characterisation of species and genotypes of *Cryptosporidium* and *Giardia* and assessment of zoonotic transmission. *Int J Parasitol* 2008; 38(11): 1239-1255. <http://dx.doi.org/10.1016/j.ijpara.2008.03.006>. PMID:18479685.
- Xiao L, Feng Y. Zoonotic cryptosporidiosis. *FEMS Immunol Med Microbiol* 2008; 52(3): 309-323. <http://dx.doi.org/10.1111/j.1574-695X.2008.00377.x>. PMID:18205803.
- Zhou L, Kassa H, Tischler ML, Xiao L. Host-adapted *Cryptosporidium* spp. in Canada geese (*Branta canadensis*). *Appl Environ Microbiol* 2004; 70(7): 4211-4215. <http://dx.doi.org/10.1128/AEM.70.7.4211-4215.2004>. PMID:15240303.
- Zylan K, Bailey T, Smith HV, Silvanose C, Kinne J, Schuster RK, et al. An outbreak of cryptosporidiosis in a collection of Stone curlews (*Burhinus oedicnemus*) in Dubai. *Avian Pathol* 2008; 37(5): 521-526. <http://dx.doi.org/10.1080/03079450802357019>. PMID:18798028.