

Kudoa spp. (Myxozoa, Multivalvulida) parasitizing fish caught in Aracaju, Sergipe, Brazil

Kudoa spp. (Myxozoa, Multivalvulida) parasitando peixes capturados em Aracaju, Sergipe, Brasil

Jorge Costa Eiras¹; Rodrigo Yudi Fujimoto²; Rubens Riscala Madi³; Veronica de Lourdes Sierpe Jeraldo⁴; Cláudia Moura de Melo⁴; Jônatas dos Santos de Souza⁵; José Antonio Picanço Diniz⁶; Daniel Guerreiro Diniz^{7*}

¹ Departamento de Biologia, Faculdade de Ciências, Universidade do Porto – UP, Porto, Portugal; CIIMAR, Centro Interdisciplinar de Investigação Marinha e Ambiental, Porto, Portugal

² Embrapa Tabuleiros Costeiros, Aracaju, SE, Brasil

³ Laboratório de Biologia Tropical, Instituto de Tecnologia e Pesquisa – ITP, Aracaju, SE, Brasil

⁴ Laboratório de Doenças Infecciosas e Parasitárias, Instituto de Tecnologia e Pesquisa – ITP, Aracaju, SE, Brasil

⁵ Programa de Pós-graduação em Saúde e Ambiente, Universidade Tiradentes – UNIT, Aracaju, SE, Brasil

⁶ Seção de Microscopia Eletrônica, Instituto Evandro Chagas – IEC, Belém, PA, Brasil

⁷ Laboratório de Investigações em Neurodegeneração e Infecção, Instituto de Ciências Biológicas, Hospital Universitário João de Barros Barreto, Universidade Federal do Pará – UFPA, Belém, PA, Brasil

Received August 3, 2016

Accepted August 31, 2016

Abstract

This study reports on *Kudoa* spp. (Myxozoa, Multivalvulida) from the fish species *Lutjanus analis*, *Bagre marinus*, *Aspistor luniscutis* and *Lutjanus jocu*, which were caught in Aracaju, state of Sergipe, Brazil. The parasites formed oval plasmodia around the esophagus of *L. analis*, and elongated plasmodia inside the skeletal muscle of *B. marinus*, *A. luniscutis* and *L. jocu*. Host myoliquefaction was not observed in all the cases studied. The current study provides a morphological and morphometric description of each parasite as well as a comparison with all the species described worldwide. Lack of molecular data impaired specific identification of the parasites. The importance of these parasites is discussed and the need for further studies on infections in Brazilian fish is emphasized because of the high economic impact of some *Kudoa* species which cause liquefaction in hosts' muscles and render these fish unsuitable for consumption.

Keywords: *Kudoa*, Myxosporea, parasites, marine fish, Brazil.

Resumo

Este estudo relata *Kudoa* spp. (Myxozoa, Multivalvulida) de espécies de peixes *Lutjanus analis*, *Bagre marinus*, *Aspistor luniscutis* e *Lutjanus jocu* que foram capturados na costa litorânea de Aracaju, Estado de Sergipe, Brasil. Os parasitas formavam plasmódios ovais rodeando o esôfago em *L. analis*, enquanto que nas espécies *B. marinus*, *A. luniscutis* e *L. jocu* formavam plasmódios alongados no interior das fibras musculares. Fenômenos de liquefação do músculo do hospedeiro não foram observados. O presente estudo proporciona uma descrição morfológica e morfométrica de cada parasita, sendo feita uma comparação com todas as espécies conhecidas em todo mundo. A inexistência de dados moleculares prejudica a identificação específica dos parasitas. A importância destes parasitas é discutida e a necessidade de mais estudos relacionados a infecções em peixes brasileiros é enfatizada por causa do alto impacto econômico de algumas espécies de *Kudoa* que causam liquefação nos músculos dos hospedeiros e tornam estes peixes impróprios para consumo.

Palavras-chave: *Kudoa*, Myxosporea, parasitas, peixes marinhos, Brasil.

*Corresponding author: Daniel Guerreiro Diniz. Laboratório de Investigações em Neurodegeneração e Infecção, Instituto de Ciências Biológicas, Hospital Universitário João de Barros Barreto, Universidade Federal do Pará – UFPA, Rua dos Mundurucus, 4487, Guamá, CEP 66073-005, Belém, PA, Brasil.
e-mail: danielguerreirodiniz@gmail.com

Introduction

Kudoa spp. are multivalvulid myxozoans that infect fish living in marine and brackish water and, rarely, in freshwater. So far, about 100 different nominal species have been described (EIRAS et al., 2014a; KRISTMUNDSSON & FREEMAN 2014; MANSOUR et al., 2014, 2015) and they present wide geographical distribution. However, the number of species described in South America is surprisingly low, given the high diversity of potential hosts on both the Atlantic and Pacific coasts. There are only a few records of these parasites in Brazil: *Kudoa aequidens* in *Aequidens plagiozonatus* (CASAL et al., 2008), *K. sciaenae* in *Stellifer minor* (OLIVA et al., 1992), *K. orbicularis* in *Chaetobranchopsis orbicularis* (AZEVEDO et al., 2016), and *Kudoa* sp. in *Mugil liza* (EIRAS et al., 2016), *Trichiurus lepturus* (ANDRADA et al., 2005); *Mugil platanus* (KNOFF & SERRA-FREIRE, 1993) *Scomberomorus brasiliensis* (EIRAS et al., 2014a), *Odontesthes bonariensis*, and *Micropogonias furnieri* (EIRAS et al., 2016). Most of these parasites are histozoic and place themselves within the fish's skeletal muscles, thus forming a sort of elongated plasmodium (for species list see MORAN et al., 1999; LOM & DYKOVÁ, 2006; EIRAS et al., 2014b). A relatively large number of species place themselves in other organs.

From an economic point of view, these parasites are extremely important. It is well known that some species cause myoliquefaction after the host's death, and the infected fish becomes unsuitable for consumption. This is particularly important when myoliquefaction affects farmed fish, since it can lead to unmarketable fish. Moreover, myoliquefaction can cause adverse effects in the canning industry (GILMAN & EIRAS, 1998). Myoliquefaction, among other effects, has been described in fish infected with *K. camarguensis* (PAMPOULIE et al., 1999), *K. lateolabracis* (YOKOYAMA et al., 2004), *K. megacapsula* (YOKOYAMA & ITOH, 2005), *K. thyrsites* (YOKOYAMA et al., 2004) and *K. peruvianus* (SALAS, 1972). In addition, the sometimes conspicuous cysts within the fish's muscles lead to rejection of these fish in the market.

In view of the limited knowledge of these parasites in fish along the Brazilian coast, it was studied the infection by *Kudoa* spp. at different locations on the Brazilian coast. The current paper reports on occurrences of these parasites in several fish species caught in Aracaju, state of Sergipe, Brazil.

Materials and Methods

Specimens of several fish species (Table 1) were purchased from fishermen in Aracaju, state of Sergipe, Brazil. In addition to the specimens reported in Table 1, 66 specimens (not measured) of *Lutjanus analis* and nine of *Lutjanus jocu* were also assessed. The specimens were taken to the laboratory and carefully dissected. All of their organs were thoroughly inspected to check for the presence of *Kudoa*. The species' possible myoliquefactive action was assessed by visually inspecting the muscle to evaluate the integrity of the muscle fibers, as well as by palpating the fish to detect muscle softening.

Table 1. Fish species examined for the presence of *Kudoa* spp.: common name and total length (cm) of the specimens, from Aracaju, Brazil.

Species	Common name	Total length	Number of fish
<i>Aspistor luniscutis</i> (Valenciennes, 1840)	Bagre	33.0	1
<i>Bagre marinus</i> (Mitchill, 1815)	Bagre-Bandeira	25.9	1
<i>Calamus pennatula</i> (Guichenot, 1868)	Peixe-Pena	30.0	1
<i>Caranx bartholomaei</i> (Cuvier, 1833)	Xaréu	40.0	1
<i>Cephalopholis fulva</i> (Linnaeus, 1758)	Piraúna	29.0-35.5	2
<i>Conodon nobilis</i> (Linnaeus, 1758)	Roncador	22.0	1
<i>Diapterus rhombeus</i> (Cuvier, 1829)	Carapeba	18.5	1
<i>Haemulon plumieri</i> (Lacépède, 1801)	Roncador-branco	32.0	1
<i>Katsuwonus pelamis</i> (Linnaeus, 1758)	Bonito Barriga Listrada	57.0	1
<i>Larimus breviceps</i> (Cuvier, 1830)	Oveva	19.5	1
<i>Lutjanus analis</i> (Cuvier, 1828)	Caranho-vermelho	23.0	1
<i>Lutjanus jocu</i> (Bloch & Schneider, 1801)	Dentão	23.4	1
<i>Nebriis microps</i> (Cuvier, 1830)	Corvina	16.5	1
<i>Polydactylus virginicus</i> (Linnaeus, 1758)	Barbudo	17.0	1
<i>Sphyrna barracuda</i> (Edwards, 1771)	Barracuda	50.5	1

Twenty-five fresh spores of the parasites were measured as specified by Lom & Arthur (1989). The samples were fixed for 1 h at room temperature in a solution containing 2.5% glutaraldehyde (Electron Microscopy Sciences (EMS), Fort Washington, PA, USA) in 0.1 M cacodylate buffer (Sigma) at pH 7.2, for scanning electron microscopy. They were post-fixed for 1 h in a solution containing 1% OsO₄ in 0.1 M cacodylate buffer at pH 7.2 and then rinsed, dehydrated in ethanol (Merck, Brazil) and dried using the critical point method in an Emitech K850 apparatus (Emitech, Kent, England). The samples were then assembled on stubs with double sided carbon tape (EMS), metalized with a thin layer of approximately 20 nm of gold (Emitech) using an Emitech K550 (Emitech, Kent, England) and observed using a 1450VP LEO scanning electron microscope.

Results

Only four fish species (one specimen of each species examined) were infected by *Kudoa* sp.: *Lutjanus analis*, *Lutjanus jocu*, *Bagre marinus* and *Aspistor luniscutis*.

Lutjanus analis (Cuvier, 1828), common name
Carancho-Vermelho

The parasite formed hundreds of whitish elongated oval plasmodia with rounded extremities, 1.38 (1.10-1.44) mm long and 0.61 (0.46-0.63) mm wide, which surrounded the esophagus wall and were placed under the serous membrane (Figure 1A, B). They were mature and contained thousands of spores at the same developmental stage.

The spores (Figure 1C, D) were stellate in apical view and presented four equal radiating shell valves with smoothly curved margins, but they did not present projections or extensions. The four polar capsules were slightly piriform, elongated and equally sized (sometimes one of the capsules was a little shorter than the others), with a pointed anterior extremity. The spores were 7.8 (7-9) μm wide and 6.2 (6-7) μm thick in apical view, and 4.7 (4-5) μm long in lateral view. The polar capsules were 3.2 (3-4) μm long and 1.4 (1-1.5) μm wide.

Bagre marinus (Mitchill, 1815), common name
Bagre-Bandeira

The parasites formed small plasmodia (Figure 2A), which contained only mature spores, inside the skeletal muscle fibers. The plasmodia had round or tapering extremities and were 9.8-17.1 mm long and had a maximum width of 0.98 mm.

The spores (Figure 2B) were rounded and stellate in apical view, with four equal radiating shell valves without projections or extensions. The polar capsules were rounded (slightly elliptical in lateral view) and had the same size. The spores were 8.2 (7-10) μm wide and 6.4 (6-8) μm thick in apical view, and 6.2 (6-7) μm long in lateral view. The polar capsules presented a diameter of 2.4 (2-3) μm .

Aspistor luniscutis (Valenciennes, 1840), common
name *Bagre*

The parasites formed tapered plasmodia at both extremities inside the muscle cells and measured 18.5-26.9 mm long and 1.5-2.0 mm thick.

The spores were quadrate and stellate in apical view, with small indentations that corresponded to the four shell valves. These valves were of the same size and shape and had no projections or extensions (Figure 3). The polar capsules were often a little different in size, such that two of them were larger and two smaller. The bigger ones were piriform and the smaller capsules were slightly piriform and mostly rounded. The spores were 8.3 (7.0-9.0) μm wide and 6.3 (6.0-6.5) μm thick in apical view, and 6.1 (6-7) μm long in lateral view. The larger polar capsules were 2.4 (2.2-2.5) μm long and 1.3 (1-1.5) μm thick. The smaller ones were 1.8 μm long and 1.0 μm thick.




Figure 1. *Kudoa* sp. parasite of *Lutjanus analis*. (A) Plasmodia on the wall of esophagus; (B) Plasmodium observed via scanning electron microscopy; (C) Spore observed in apical/side view via scanning electron microscopy; (D) Spores in apical view observed via optical microscopy. Bars: (A) 1 cm; (B) 5 μm ; (C) 100 μm ; (D) 10 μm .

The number of coils in the polar filament was not visible by means of optical microscopy on any of the observed spores. Any of the host specimens presented myoliquefaction symptoms for approximately 15 h after the host's death.

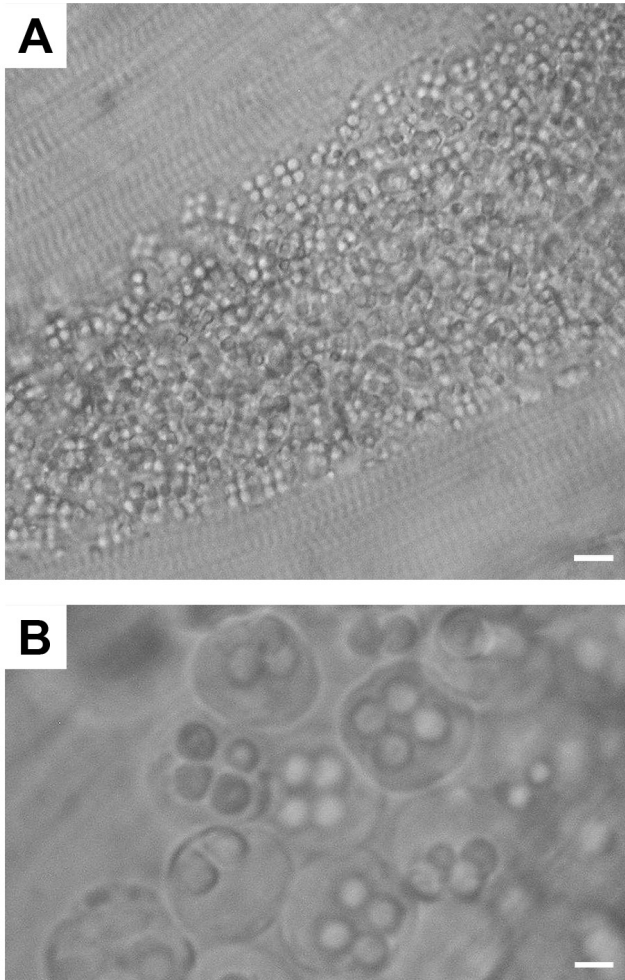


Figure 2. *Kudoa* sp. parasite of *Bagre marinus*. (A) Detail of the plasmodium inside the muscle fiber; (B) Spores observed in apical view. Bars: (A) 20 μ m; (B) 10 μ m.

Lutjanus jocu (Bloch & Schneider, 1801), common name *Dentão*

One fish specimen was infected, and its parasites formed thin and elongated plasmodia inside the muscle fibers. They measured 41.7-44.1 mm long and 0.24 mm wide. The plasmodia contained spores at different developmental stages, and there were smaller quantities of mature spores. An accident in the laboratory impaired collection of more data on these parasites.

Discussion

To establish the identity of the present specimens, they were compared with all the species of *Kudoa* described so far, and therefore including all the species described from hosts in Brazil and other South American countries. About 100 nominal *Kudoa* species have been described worldwide. In addition to species that are found within the muscle fibers of fish, four species infect the gills; two, the ovaries; one, the intestinal mesentery; one, the kidneys; one, the connective tissues; nine, the nervous system; one, the intestine submucosa; one, the integument; one, the wall of the esophagus and mesenteries; three, the gall bladder; five, the heart; two, the intestine; and one species was found throughout the body (EIRAS et al., 2014b). They have been described infecting different hosts, including two species related to *L. analis*: *Lutjanus lemniscatus* (*Kudoa lemniscati* MILLER & ADLARD, 2012) in Australia, and *Lutjanus erythropterus* (*Kudoa lutjanus* WANG et al., 2005) in Taiwan.

Kudoa lemniscati in *L. lemniscatus* cannot be matched with our material since it has 7-8 polar capsules (MILLER & ADLARD, 2012). This feature is enough to immediately distinguish the two species without further considerations. *Kudoa lutjanus* in *L. erythropterus* is found throughout the body, including the brain, eyes, muscles, swim-bladder, etc. *Kudoa lemniscati* forms plasmodia that are much smaller than those in our material (0.003 to 0.65 mm in diameter) and causes liquefaction in the host's muscle (WANG et al., 2005). Therefore, it does not match our specimens.

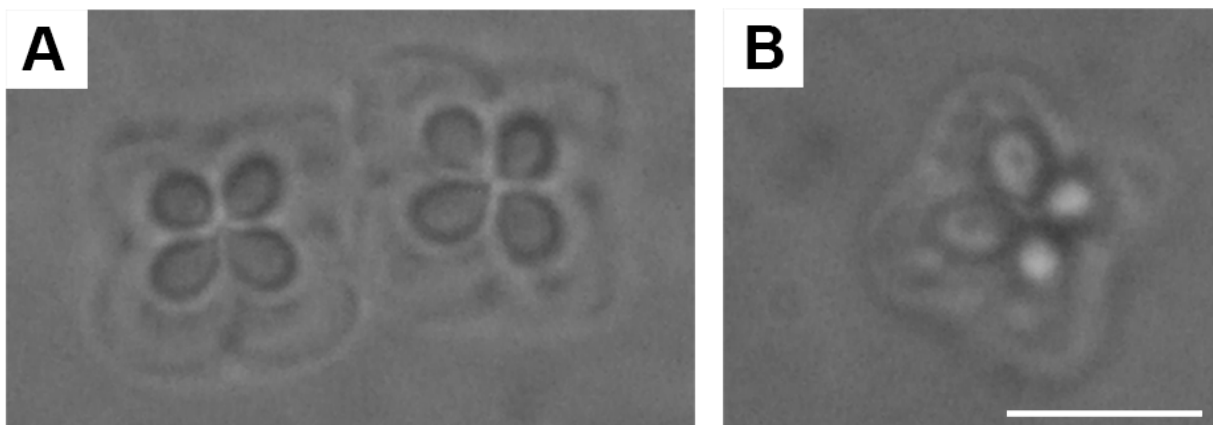


Figure 3. *Kudoa* sp. parasite of *Aspistor luniscutis*. Spores observed in apical view. Bar: (A, B) 5 μ m.

The comparisons between present material and all the other species in extra-muscular locations showed that they do not match any of the descriptions, despite some similarities relating to hosts and parasite location within the host. *Kudoa diana*e Dyková, et al. 2002, was more similar to our specimens and has been found infecting *Spherooides annulatus* in Mexico (DYKOVÁ et al., 2002). This species is also located on the wall of the esophagus. However, additionally, it has been found in the mesenteries (location which was not seen in our material) and presents the following spore dimensions: 5 (4.5-5.5) μm long, 6 (5.5-6.5) μm wide, 6 (5.5-6.5) μm thick, and polar capsule dimension of 2.0 μm \times 1.5 μm . These dimensions are smaller than those of our specimens. Furthermore, the shell valves thicken in the slightly protruding apical part of the spores. Therefore, the two forms cannot be considered to be identical. Comparison between the species that infect the host's muscle tissue did not reveal any similarity with the material studied here.

The other two species were compared with *Kudoa* spp. infecting the host's muscle tissue.

In the case of parasites infecting *B. marinus*, the most similar species concerning general dimensions were *K. grammatorcyni* Adlard, Bryant, Whipps and Kent, 2005 (ADLARD et al., 2005), *K. leiostomi* Dyková, Lom and Overstreet, 1994 (DYKOVÁ et al., 1994), *K. musculoliquefaciens* Matsumoto, 1954 (synonym: *Chloromyxum musculoliquefaciens* Egusa, 1986) and *K. trachuri* Matsukane, Sato, Tanaka, Kamata and Sugita-Konichi, 2011 (MATSUKANE et al., 2011). In the case of *K. grammatorcyni*, the six polar capsules that it presents immediately separate the two forms. *Kudoa leiostomi* presents some similarities with the form that we observed in the current study but its dimensions are a little bigger and so are its polar capsules. *Kudoa musculoliquefaciens* is probably the species which mostly resembles our material: the length and width of the spores are practically the same, whereas the thickness is greater in *K. musculoliquefaciens*. However, it has smaller polar capsules, and causes liquefaction in the host's muscle, features that are very different from those of the form infecting *B. marinus*. Finally, *K. trachuri* has dimensions that are somewhat similar to those of our material (6.1 \times 7.7 \times 5.8) but the plasmodia are oval and much smaller (0.5-1.6 \times 0.3-1.1), and its polar capsules are bigger, which differentiates the two forms.

Regarding the parasites in *A. luniscutis*, *Kudoa caudata* Kovaleva and Gayevskaya, 1983, was the most similar species (quoted from EIRAS et al., 2014b). This species has been seen to infect *Scomber japonicus*. However, it is thicker (6.6 μm) and causes myoliquefaction in the host, and thus it cannot match the form that infects *A. luniscutis*. Comparison with the *Kudoa* spp. that infects host tissues other than muscles showed that our material is different from all of them.

Based on the observed features, it seems that the forms described in the current study are different from those described so far. However, our observations just deal with morphological and morphometric features. Molecular studies were not performed and, thus, ultimate identification at species levels was not possible.

Studies on *Kudoa* spp. that infect fish along the Brazilian coast are very scarce. Only four species have been described and there were seven hosts infected by unidentified *Kudoa* species, as already mentioned in this paper's introduction. A comparison between the

forms described in this paper and the Brazilian species shows that they do not match. Because of the lack of research on this group, and the strong diversity of potential hosts, we believe that consistent studies on the presence of these parasites have the potential to reveal numerous undescribed species. Furthermore, we consider such studies to be important, since some species are able to cause myoliquefaction in the host's muscle tissues, thus making the host unsuitable for consumption. This subject is particularly important for the fish farming industry. High economic losses caused by *Kudoa* spp. infection in farmed fish have been reported for several host fish species (ALVAREZ-PELLITERO & SITJÁ-BOBODILLA, 1993; KRISTMUNDSSON & FREEMAN, 2014; MORAN et al., 1999; WHITAKER & KENT, 1991).

Acknowledgements

The participation of J.C. Eiras on this research was supported by the European Regional Development Fund (ERDF) through the COMPETE - Operational Competitiveness Programme and national funds through FCT - Foundation for Science and Technology, under the project "PEst-C/MAR/LA0015/2011".

References

- Adlard RD, Bryant MS, Whipps CM, Kent ML. Multivalvulid myxozoans from eastern Australia: three new species of *Kudoa* from scombrid and labrid fishes of the Great Barrier Reef, Queensland, Australia. *J Parasitol* 2005; 91(5): 1138-1142. PMID:16419761. <http://dx.doi.org/10.1645/GE-368R.1>.
- Alvarez-Pellitero P, Sitjá-Bobodilla A. Pathology of Myxosporea in marine fish culture. *Dis Aquat Organ* 1993; 17: 229-238. <http://dx.doi.org/10.3354/dao017229>.
- Andrada CG, Tortelly R, Nogueira PP, Andrade CL, Lima FC. Infecção por *Kudoa* Meglitsch, 1947 (Myxozoa: Multivalvulida) em musculatura esquelética de espada *Trichiurus lepturus* L. (Teleostei: Trichiuridae). *Parasitol Latinoam* 2005; 60(3-4): 150-153. <http://dx.doi.org/10.4067/S0717-77122005000200008>.
- Azevedo C, Rocha S, Matos E, Oliveira E, Matos P, Al-Quraishy S, et al. Ultrastructural and phylogenetic description of *Kudoa orbicularis* n. sp. (Myxosporea: Multivalvulida): a parasite infecting the muscle of the fish *Chaetobranchopsis orbicularis* (Teleostei: Cichlidae) in the Amazon Region. *J Eukaryot Microbiol* 2016; 63(1): 27-36. PMID:26095978. <http://dx.doi.org/10.1111/jeu.12244>.
- Casal G, Matos E, Matos P, Azevedo C. Ultrastructural description of a new myxosporean parasite *Kudoa aequidens* sp. n. (Myxozoa, Myxosporea), found in the sub-opercular musculature of *Aequidens plagiazonatus* (Teleostei) from the Amazon River. *Acta Protozool* 2008; 47(2): 135-141.
- Dyková I, Avila EJJ, Fiala I. *Kudoa diana*e sp. n. (Myxosporea: Multivalvulida), a new parasite of bullseye puffer, *Spherooides annulatus* (Tetraodontiformes: Tetraodontidae). *Folia Parasitol (Praha)* 2002; 49(1): 17-23. PMID:11993546. <http://dx.doi.org/10.14411/fp.2002.006>.
- Dyková I, Lom J, Overstreet RM. Myxosporean parasites of the genus *Kudoa* Meglitsch, 1947 from some Gulf of Mexico fishes: description of two new species and notes on their ultrastructure. *Eur J Protistol* 1994; 30(3): 316-323.

- Eiras JC, Lima JTAX, Cruz CF, Saraiva A. A note on the infection of *Scomberomorus brasiliensis* (Osteichthyes, Scombridae) by *Kudoa* sp. (Myxozoa: Multivalvulida). *Braz J Biol* 2014a;74(3 Suppl 1): 164-166. PMID:25627380. <http://dx.doi.org/10.1590/1519-6984.23712>.
- Eiras JC, Saraiva A, Cruz C. Synopsis of the species of *Kudoa* Meglitsch, 1947 (Myxozoa: Myxosporea: Multivalvulida). *Syst Parasitol* 2014b; 87(2): 153-180. PMID:24474038. <http://dx.doi.org/10.1007/s11230-013-9461-4>.
- Eiras JC, Pereira J Jr, Saraiva A, Cruz CF. Observations on the infection by *Kudoa* spp. (Myxozoa, Multivalvulida) in fishes caught off Rio Grande do Sul State, Brazil. *Acta Sci Biol Sci* 2016; 38(1): 99-103. <http://dx.doi.org/10.4025/actasciobiolsci.v38i1.30492>.
- Gilman MM, Eiras JC. *Kudoa* sp. (Myxosporea: Multivalvulida) infecting *Sardina pilchardus* (Walb., 1792) off the Portuguese coast. *Res Rev Parasitol* 1998; 58(2): 135-137.
- Knoff M, Serra-Freire NM. Protozoários parasitos de *Mugil platanus* Günther, 1880 do litoral do Estado do Rio de Janeiro, Brasil. *Rev Bras Parasitol Vet* 1993; 2(1): 25-28.
- Kristmundsson Á, Freeman MA. Negative effects of *Kudoa islandica* n. sp. (Myxosporea: Kudoidae) on aquaculture and wild fisheries in Iceland. *Int J Parasitol Parasites Wildl* 2014; 3(2): 135-146. PMID:25161912. <http://dx.doi.org/10.1016/j.ijppaw.2014.06.001>.
- Lom J, Arthur JR. A guideline for the preparation of species descriptions in Myxosporea. *J Fish Dis* 1989; 12(2): 151-156. <http://dx.doi.org/10.1111/j.1365-2761.1989.tb00287.x>.
- Lom J, Dyková I. Myxozoan genera: definition and notes on taxonomy, life cycle, terminology and pathogenic species. *Folia Parasitol (Praha)* 2006; 53(1): 1-36. PMID:16696428. <http://dx.doi.org/10.14411/fp.2006.001>.
- Mansour L, Harrath AH, Abdel-Baki A-AS, Al-Quraishy SS, Al Omar SY. *Kudoa saudiensis* sp. n. (Myxosporea: Multivalvulida) infecting oocytes of the Indian mackerel *Rastrelliger kanagurta* (Perciformes: Scombridae). *Folia Parasitol (Praha)* 2015; 62: 1-10. PMID:25960554. <http://dx.doi.org/10.14411/fp.2015.010>.
- Mansour L, Harrath AH, Abd-Elkader OH, Alwasel S, Abdel-Baki AA, Al Omar SY. Structural and molecular characterization of *Kudoa quraishii* n. sp. from the trunk muscle of the Indian mackerel *Rastrelliger kanagurta* (Perciformes, Scombridae) in Saudi Arabia coasts. *Parasitol Res* 2014; 113(4): 1361-1370. PMID:24488108. <http://dx.doi.org/10.1007/s00436-014-3775-2>.
- Matsukane Y, Sato H, Tanaka S, Kamata Y, Sugita-Konishi Y. *Kudoa iwatai* and two novel *Kudoa* spp., *K. trachuri* n. sp. and *K. thunni* n. sp. (Myxosporea: Multivalvulida), from daily consumed marine fish in western Japan. *Parasitol Res* 2011; 108(4): 913-926. PMID:21053015. <http://dx.doi.org/10.1007/s00436-010-2133-2>.
- Miller TL, Adlard RD. Brain infecting kudoids of Australia's coral reefs, including a description of *Kudoa lemniscati* n. sp. (Myxosporea: Kudoidae) from *Lutjanus lemniscatus* (Perciformes: Lutjanidae) off Ningaloo Reef, Western Australia. *Parasitol Int* 2012; 61(2): 331-342. PMID:22260905. <http://dx.doi.org/10.1016/j.parint.2012.01.002>.
- Moran JDW, Whitaker DJ, Kent ML. A review of the myxosporean genus *Kudoa* Meglitsch, 1947, and its impact on the international aquaculture industry and commercial fisheries. *Aquaculture* 1999; 17(1-2): 163-196. [http://dx.doi.org/10.1016/S0044-8486\(98\)00437-2](http://dx.doi.org/10.1016/S0044-8486(98)00437-2).
- Oliva M, Luque JL, Teran L, Llican L. *Kudoa sciaenae* (Myxozoa: Multivalvulidae) cysts distribution in the somatic muscles of *Stellifer minor* (Tschudi, 1844) (Pisces: Sciaenidae). *Mem Inst Oswaldo Cruz* 1992; 87(1): 33-35. <http://dx.doi.org/10.1590/S0074-02761992000100006>.
- Pampoulie C, Marques A, Rosecchi E, Crivelli AJ, Bouchereau JL. A new myxosporean parasite, *Kudoa camarguensis* n. sp., recorded on two goby species (Teleostei: Pisces) in the Rhône delta (Mediterranean Sea, France). *J Eukaryot Microbiol* 1999; 46(3): 304-310. <http://dx.doi.org/10.1111/j.1550-7408.1999.tb05129.x>.
- Salas EM. Investigación parasitológica de la merluza (*Merluccius gayii peruanus*). Instituto del Mar de Peru. *Informe* 1972; 40(8): 5-13.
- Wang PC, Huang JP, Tsai MA, Cheng SY, Tsai SS, Chen SD, et al. Systemic infection of *Kudoa lutjanus* n. sp. (Myxozoa: Myxosporea) in red snapper *Lutjanus erythropterus* from Taiwan. *Dis Aquat Organ* 2005; 67(1-2): 115-124. PMID:16385817. <http://dx.doi.org/10.3354/dao067115>.
- Whitaker DJ, Kent ML. Myxosporean *Kudoa thyrssites*: a cause of soft flesh in farm-reared Atlantic salmon. *J Aquat Anim Health* 1991; 3(4): 291-294. [http://dx.doi.org/10.1577/1548-8667\(1991\)003<0291:MK TACO>2.3.CO;2](http://dx.doi.org/10.1577/1548-8667(1991)003<0291:MK TACO>2.3.CO;2).
- Yokoyama H, Itoh N. Two multivalvulid myxozoans causing postmortem myoliquefaction: *Kudoa megacapsula* n. sp. from red barracuda (*Sphyræna pinguis*) and *Kudoa thyrssites* from splendid alfonso (*Beryx splendens*). *J Parasitol* 2005; 91(5): 1132-1137. PMID:16419760. <http://dx.doi.org/10.1645/GE-548R.1>.
- Yokoyama H, Whipps CM, Kent ML, Mizuno K, Kawakami H. *Kudoa thyrssites* from Japanese flounder and *Kudoa lateolabracis* n. sp. from Chinese sea bass: causative myxozoans of post-mortem myoliquefaction. *Fish Pathol* 2004; 39(2): 79-85. <http://dx.doi.org/10.3147/jfsfp.39.79>.