

Morphological diagnosis of *Setaria labiatopapillosa* in domestic bovids from Marajó Island, Brazil

Diagnóstico morfológico de *Setaria labiatopapillosa* em bovinos domésticos da Ilha do Marajó, Brasil

Rogério Antonio Ribeiro Rodrigues¹ ; David Marcial Fernandez Conga¹ ; Jeannie Nascimento dos Santos² ; Evonildo Costa Gonçalves³ ; Raul Henrique da Silva Pinheiro⁴ ; Elane Guerreiro Giese^{1,5*} 

¹ Programa de Pós-graduação em Saúde e Produção Animal na Amazônia, Instituto da Saúde e Produção Animal, Universidade Federal Rural da Amazônia – UFRA, Belém, PA, Brasil

² Laboratório de Biologia Celular e Helmintologia “Profa Dra Reinalda Marisa Lanfredi”, Instituto de Ciências Biológicas, Universidade Federal do Pará - UFPA, Belém, PA, Brasil

³ Laboratório de Tecnologia Biomolecular, Instituto de Ciências Biológicas, Universidade Federal do Pará - UFPA, Belém, PA, Brasil

⁴ Programa de Pós-graduação em Sociedade, Natureza e Desenvolvimento, Instituto de Biodiversidade e Florestas, Universidade Federal do Oeste do Pará – UFOPA, Santarém, PA, Brasil

⁵ Laboratório de Histologia e Embriologia Animal, Instituto da Saúde e Produção Animal, Universidade Federal Rural da Amazônia – UFRA, Belém, PA, Brasil

How to cite: Rodrigues RAR, Conga DMF, Santos JN, Gonçalves EC, Pinheiro RHS, Giese EG. Morphological diagnosis of *Setaria labiatopapillosa* in domestic bovids from Marajó Island, Brazil. *Braz J Vet Parasitol* 2021; 30(3): e004321. <https://doi.org/10.1590/S1984-29612021055>

Abstract

The genus *Setaria* is known worldwide for parasiting wild and domestic mammals, with 43 species registered, of which five occur in the American continent. The objective of this study was to characterize the occurrence, morphology and morphometry of *S. labiatopapillosa* in *B. taurus* and *B. bubalis* in Marajó Island, Brazil. Carcass inspections of 420 cattle were carried out in two slaughterhouses in Pará. The nematodes were found on the white and serous viscera of the small intestine, being cleaned and discussed for analysis by light microscopy and scanning electron microscopy. The morphological and morphometric characteristics are compatible with *S. labiatopapillosa* parasitizing both species, with a prevalence of 25% (*B. bubalis*) and 24% (*B. taurus*). Information obtained by scanning electron microscopy was added to the description of the species, in addition to expanding the distribution of this parasite in the national territory.

Keywords: Nematoda, Onchocercidae, parasite, Bovidae, Amazon.

Resumo

O gênero *Setaria* é mundialmente conhecido parasitando mamíferos selvagens e domésticos, sendo registradas 43 espécies, das quais cinco ocorrem no continente americano. Este estudo objetivou caracterizar a ocorrência, morfologia e morfometria de *S. labiatopapillosa* em *B. taurus* e *B. bubalis* na Ilha de Marajó, Brasil. Foram realizadas inspeções de carcaça de 420 bovinos em dois abatedouros no Pará. Os nematódeos foram encontrados sobre as vísceras brancas e serosa do intestino delgado, sendo limpos e conversados para análise por microscopia de luz e microscopia eletrônica de varredura. As características morfológicas e morfométricas são compatíveis com *S. labiatopapillosa* parasitando ambas as espécies, com prevalência de 25% (*B. bubalis*) e 24% (*B. taurus*). Informações obtidas por microscopia eletrônica de varredura foram adicionadas à descrição da espécie, além de ampliar a distribuição desse parasito no território nacional.

Palavras-chave: Nematoda, Onchocercidae, parasito, Bovidae, Amazônia.

Received March 14, 2021. Accepted May 24, 2021.

*Corresponding author: lheaufra@gmail.com



This is an Open Access article distributed under the terms of the Creative Commons Attribution License, which permits unrestricted use, distribution, and reproduction in any medium, provided the original work is properly cited.

Introduction

There are 43 species of *Setaria* distributed worldwide (Anderson, 2000), parasitizing the abdominal cavity of domestic and wild animals (Kim et al., 2010; Gomez-Puerta & Mayor, 2017; Mrifag et al., 2021). The most common species in bovids are *Setaria digitata*, *Setaria cervi*, *Setaria tundra*, *Setaria bidentata*, *Setaria yehi*, *Setaria marshalli* and *Setaria labiatopapillosa* (Desset, 1966; Becklund & Walker, 1969; Rhee et al., 1994), the latter being the focus of the present study.

In the American continent the following species have been recorded: *Setaria equina* parasite of *Equus caballus*, *E. asinus*, *E. asinus*; *Setaria yehi* parasites cervid (*Odocoileus hemionus* and *O. virginianus*); *Setaria digitata* and *Setaria labiatopapillosa* parasites of large domestic and wild ruminants (*Antilocapra americana*, *Bison bison*, *Alces alces*, *Bos taurus* and *Bubalus bubalis*) (Becklund & Walker, 1969). In Brazil, up until the sixties, *Setaria bidentata* had been recorded parasitizing *Mazama rufus* (syn. *Cervus rufus*) (Yeh, 1959) and *M. americana* (Rego, 1960).

Nematodes of this genus are not pathogenic (Gomez-Puerta & Mayor, 2017), but there have been reports of injuries to the central nervous system of its hosts related to infection by *Setaria* in ruminants caused by erratic microfilary migrations (Soulsby, 1982). Among the rare zoonotic cases, there is a reported occurrence of *Setaria* sp. parasitizing the ocular conjunctiva of human beings, in Cluj-Napoca, Romania, which represents a potential danger to human health (Țălu et al., 2012).

Despite the zoonotic potential, the occurrence of *Setaria* sp. is neglected in domestic ruminant breeding in Brazil, especially in rural areas where the presence of vectors is more frequent. The objective of this study is to characterize the occurrence, morphology and morphometry of *S. labiatopapillosa* in *B. taurus* and *B. bubalis* in Marajó Island, Brazil.

Materials and Methods

During the period from August 2017 to May 2019, nematodes were collected from the serosa of the duodenum and the free abdominal cavity and from intestine of 244 *Bubalus bubalis* and 176 *Bos taurus* slaughtered at the official municipal slaughterhouse in Soure (00°43'00"S; 48°31'24"W) on Marajó Island, Pará State, in the eastern Brazilian Amazon. Nematodes were fixed in AFA solution (93 parts 70% ethyl alcohol, 5 parts formaldehyde, and 2 parts glacial acetic acid). For morphological and morphometric analysis, the nematodes were dehydrated in an ethanol series, clarified with Aman's Lactophenol (20%) and observed using a light microscope, and LEICA DM2500 camera with an imaging capture system according to method described by Pinheiro et al. (2019). Measurements are given in micrometers unless otherwise noted and are presented as the mean followed by the range (minimum and maximum values) in parentheses. Taxonomic classification of nematodes was in accordance with Vicente et al. (1997) and Anderson (2000).

For scanning electron microscopy, 6 nematodes were washed in phosphate-buffered saline (pH 7.0), post-fixed in 1% osmium tetroxide, dehydrated to the critical point of CO₂, metalized with gold-palladium, and analyzed with a scanning electron microscope (VEGA 3/TESCAN) at the Laboratório de Microscopia Eletrônica de Varredura, Instituto da Saúde e Produção Animal, Universidade Federal Rural da Amazônia - UFRA, state of Pará, Brazil. The ecological indexes of parasitism were used according to Bush et al. (1997) and Bautista-Hernández et al. (2015).

Specimens were deposited in the Coleção de Invertebrados of the Museu Paraense Emílio Goeldi (acronym MPEG), Belém, Pará, Brazil: from 10 females and 5 males of *Bubalus bubalis* (Vouchers number MPEG 00264 to MPEG 00266 respectively) and 10 females and 5 males of *Bos taurus* (Vouchers number MPEG 00265 to MPEG 00267 respectively). This work obtained a release for the scientific collection provided by the Comitê de Ética em Uso de Animais of Universidade Federal Rural da Amazônia (CEUA/ UFRA) (license number 066/2017).

Results

A total of 136 nematodes were recovered from cattle and buffalo showing a prevalence of 24% and 25% and mean intensity of 1.37 and 1.1 respectively. All nematodes were measured and morphologically characterized (Figure 1a-h). The morphological and morphometric characteristics of the nematodes recovered from *B. bubalis* and *B. taurus* are presented below and in Table 1.

The specimens were long and thin with the cephalic and caudal ends tapering more than the rest of the body. In the anterior region, a small oral capsule and elliptical oral opening were observed 2 bifurcated cephalic elevations,

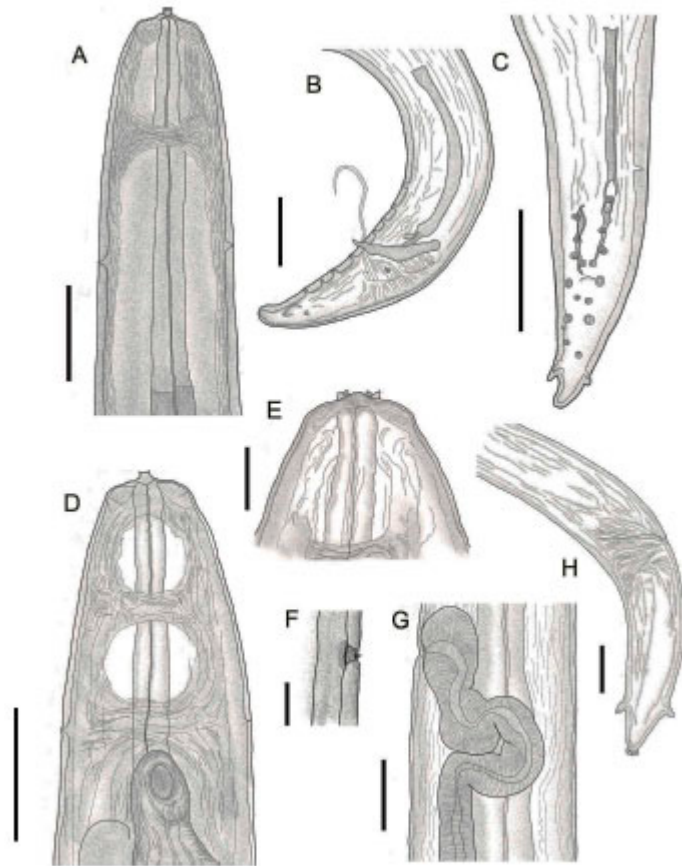


Figure 1. Morphology of *Setaria labiatopapillosa*: (a) cefalic end, lateral view with details in ring nerve, deirids and muscular esophagus. Bar= 200µm; Male: (b) posterior end, lateral view with details in spicules, caudal papillae and cloaca. Ba r= 100µm; (c) posterior end, ventral view with details in spicules, caudal papillae and cloaca. Ba r= 100µm; Female: (d) cefalic end, lateral view with details in ring nerve, deirids and vulvar aperture. Bar = 300µm. (e) cephalic end, ventral view. Bar = 100µm. (f) details of deirid. Bar = 100µm. (g) lateral view with details of vulvar aperture and vagina. Bar = 200µm. (h) posterior end with details of lappets and anal aperture. Bar = 100µm.

Table 1. Comparative measurements of *Setaria* parasites of Bovidae.

Morphometric characterization	<i>S. labiatopapillosa</i>				<i>S. labiatopapillosa</i>		<i>S. digitata</i>		<i>S. bidentata</i>	
	Male	Female	Male	Female	Male	Female	Male	Female	Male	Female
Host	<i>Bubalus bubalis</i>		<i>Bos taurus</i>		<i>Bos indicus and Bos taurus</i>		<i>Bos indicus and Bos taurus</i>		<i>Mazama americana</i>	
Locality	Brazil				China, Malayan, India and Africa		Colombo		Peru	
Total Length (mm)	32-35	39-60	34-36	39-65	40-51	60-94	35-46	65-75	31.8-38	51.1-78.8
Width	263-276	300-423	215-232	143-760	380-450	600-900	300-500	700-900	267-323	486-612
Head elevations	16-33	13-46	41.6-56.6	27-54	-	-	-	-	-	-
Oral capsule	16-33	10-53	17-33	10-50	-	-	-	-	-	-
Nerve ring	253-273	133-316	110-167	112-317	250-280	250-290	200-300	200-300	141-218	109-208
Esophagus (mm)	7.3-8.3	8-10	7-8	5.4-8.7	-	-	-	-	2.5-3.6	3.3-4.1
Muscular esophagus	650-786	203-850	650-786.6	203-853	600-800	600-850	500-600	600-700	382-449	267-529
Glandular esophagus	7.3-8.3	7.4-9.9	7.28-8.28	7.2-9.7	7.0-9.5	7.3-10.4	5.5-6.5	5.5-6.5	-	-
Deirids	303-483	240-556	303-483	240-557	500-530	430-630	-	240-560	269-407	381-520
Vulva (mm)	-	0.45-0.78	-	0.45-0.75	-	0.45-0.80	-	0.5-0.6	-	0.203-0.399
Longer spicule	300-358	-	300-358	-	120-160	-	300-360	-	223-305	-
Small spicule	92-158	-	97-160	-	-	-	90-160	-	110-154	-
Lateral appendages	-	130-300	-	133-290	-	90-130	-	50-110	-	-
Tail	-	108-405	-	107-415	170-200	440-600	-	400-500	-	338-468
Numbers of specimens	5	10	5	10	-	-	8	6	8	10
Reference	In this study				Yeh (1959)		Railliet & Henry (1911)		Gomez Puerta & Mayor (2017)	

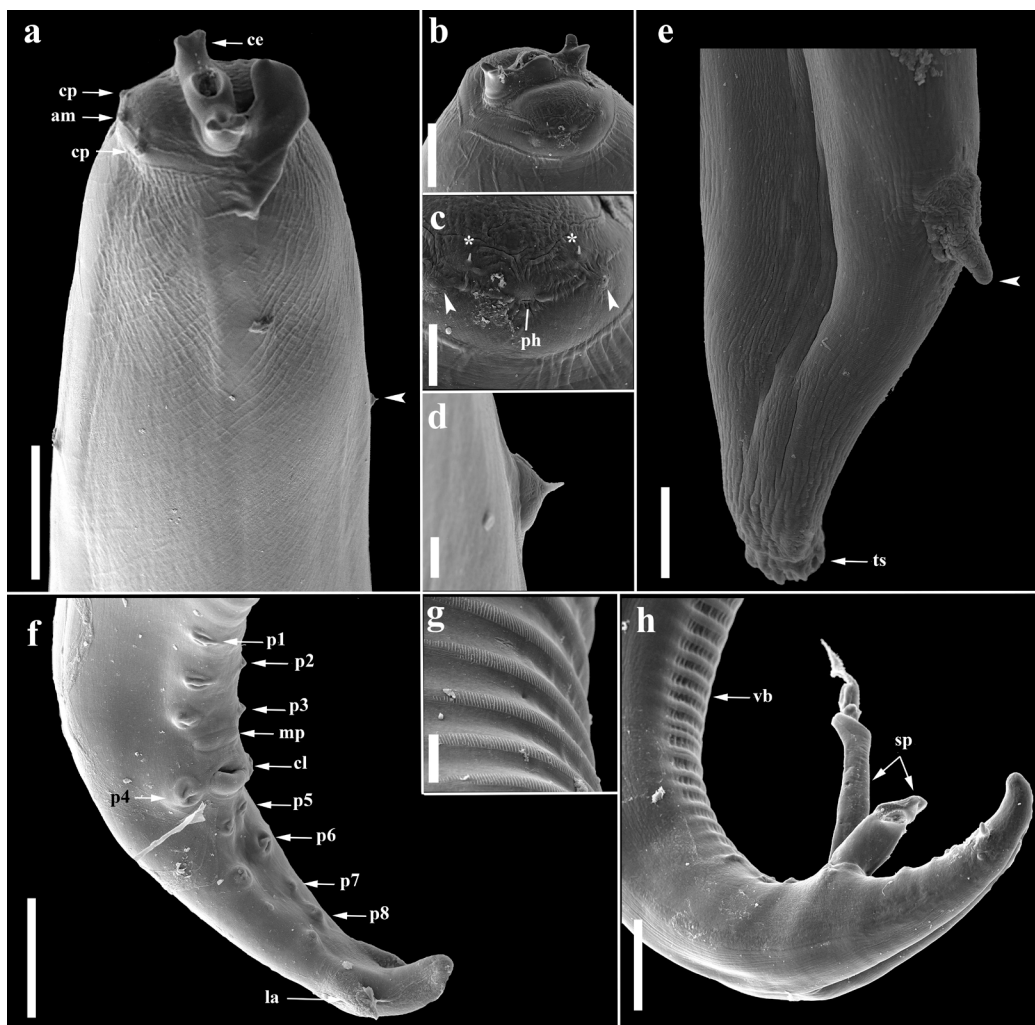


Figure 2. Scanning electron micrographs of *Setaria labiatopapillosa*: **(a)** cephalic region showing evidence cephalic elevations (ce), common papillae (cp), amphidial papillae (am) and conical deirids (arrowhead). Bar= 100µm; **(b)** details of cephalic elevations. Bar= 20µm; **(c)** details of ciliated papillae (*), common papillae (arrowhead), amphidium (ph). Bar= 20µm; **(d)** conical deirids. Bar= 5µm; **(e)** posterior portion of the female evidence lateral appendages (arrowhead), tail tip (ts). Bar= 20µm; **(f)** posterior region of the male evidence 3 pairs of precloacal papillae (p1-p3), median papillae (mp), 1 pair of adcloacal papillae (p4), cloaca (cl), 4 pairs of postcloacal papillae (p5-p8), lateral appendix (la). Bar= 50µm; **(g)** details of ventral bands on the males. Bar= 10µm; **(h)** view of ventral bands (vb) and spicules (sp). Bar= 50µm.

2 pairs of ciliated papillae, 2 pairs of simple papillae, 2 amphidial papillae (Figure 2a-c). Conical deirids (Figure 2d) and nerve ring at the height of the muscular esophagus. In females, the vulva was located at the level of the deirids, and in the posterior region the lateral appendages and the tapered tail were visualized, ending in a rougher region that resembled spines (Figure 2e). In the posterior region of the males, 3 pairs of precloacal papillae, one median papilla, one pair of adcloacal papillae and another 4 pairs of postcloacal papillae, and pair of lateral appendages, uneven spicules, ventral bands (Figure 2f-g and 2h).

Morphological and morphometric characterization of nematodes recovered from *Bubalus bubalis*

Male (based on 5 specimens)

Total length 34 (32-35) mm. Width at height of the esophagus/ intestine junction 269 (263-276). Oral capsule 26 (16-33). Head elevations 30 (16-33). Deirids and nerve ring 392 (303-483) and 263 (253-273), respectively. Esophagus 7.8 (7.3-8.3) mm. Muscular esophagus 714 (650-786) × 78 (63-93); Glandular esophagus 8.0 (7.3-8.3) mm × 0.2 (0.1-0.2) mm. Cloacal papillae distributed in: 3 pairs of precloacal papillae, 1 median papilla, 1 pair of adcloacal papillae and 4 pairs of postcloacal papillae and 1 pair of side phasmids, located between the last pair of

postcloacal papillae and the lateral appendages. Spicules unequal, morphologically similar and sclerotized spicules: small spicule 135 (92–158) and longer spicule 321 (300–358).

Female (based on 10 specimens – Female gravid)

Total length 53 (39–60) mm. Width at height of the esophagus/ intestine junction 363 (300–423). Oral capsule 36 (10–53). Head elevations 30 (13–46). Deirids and nerve ring 375 (240–556) and 255 (133–316), respectively. Vulva 0.64 (0.45–0.78) mm. Esophagus 9 (8–10) mm. Muscular esophagus 627 (203–850) × 92 (53–163). Glandular esophagus 8 (7.4–9.9) mm × 0.24 (0.11–0.41) mm. Distance from the lateral appendages to the tail 78 (50–108), lateral appendages 220 (130–300), conical tail 243 (108–405).

Morphological and morphometric characterization of nematodes recovered from *Bos taurus*

Male (based on 5 specimens)

Total length 35 (34–36) mm. Width height of the esophagus/ intestine junction 211 (215–232). Oral capsule 27 (17–33). Head elevations 53 (42–57). Deirids and nerve ring 392 (303–483) and 140 (110–167), respectively. Esophagus 8 (7–8) mm. Muscular esophagus 714 (650–787) × 78 (63–93). Glandular esophagus 7.8 (7.3–8.3) mm × 0.2 (0.1–0.2) mm. Cloacal papillae distributed: 3 pairs of precloacal papillae, 1 median papillae, 1 pair of adcloacal papillae and 4 pairs of postcloacal papillae, 1 pair of lateral phasmids, located between the last pair of postcloacal papillae and the side appendages. Unequal spicules, morphologically similar and sclerotized: small spicule 135 (97–160) and longer spicule 323 (300–358).

Female (Based on 10 specimens – Female gravid)

Total length 54 (39–65) mm. Width at height of the esophagus/intestine junction 393 (143–760). Oral capsule 31 (10–50). Head elevations 45.5 (22.6–54). Deirids and nerve ring 375 (240–557) and 244 (112–317) respectively. Vulva 0.64 (0.45–0.75) mm. Esophagus 6.4 (5.4–8.7) mm. Muscular esophagus 647 (203–853) × 92 (53–163). Glandular esophagus 8.0 (7.2–9.7) mm × 0.1 (0.1–0.2) mm. Distance from the lateral appendages to the tail 80 (50–119), lateral appendages 210 (133–330) conical tail 230 (107–415).

Discussion

The specimens analyzed in the present work belong to the genus *Setaria* parasites of the abdominal cavity the serous layers of the small intestines of the host buffaloes and cattle, reported by Nakano et al. (2007) in Japan, Watermeyer et al. (2013), in South Africa, Gomez-Puerta & Mayor, 2017 in Peru, Shin et al. (2017) in South Korea and Mrifag et al. (2021) in Morocco.

With the scanning electron microscopy, it was possible to view in the previous elliptical oral opening, 1 pair of bifurcated head elevations, 2 pairs of ciliated cephalic papillae, 2 pairs of cephalic papillae without eyelashes and a papilla over amphids and deirids of conic shape. These findings are compatible with those in Mrifag et al. (2021) since they are specific characteristics of the species *Setaria labiatopapillosa*. However, they differ from the findings of Watermeyer et al. (2013) who studied *Setaria* parasites of *Redunca arundinum* in South Africa and they did not observe ciliated papillae. Another relevant feature for differentiating species of *Setaria* is related to the shape of the deirids, as reported of Desset (1966).

Watermeyer et al. (2013) report bifid deirids in the species *Setaria graberi* in *Redunca arundinum*, while in present study the deirids are conical in form. In this sense, the findings in the present study are similar to those of Desset (1966), who found conical deirids for the species *Setaria bidentata* and *Setaria digitata*. This was also corroborated by Rhee et al. (1994) for *Setaria digitata*, and for Becklund & Walker (1969) for the species *Setaria labiatopapillosa* since they also have conical deirids.

In the posterior region, the tails of males and females showed two lateral cuticular appendages, corroborating the results of Mrifag et al. (2021), when they reported the occurrence of *Setaria labiatopapillosa* in cattle in Morocco. The final portion had a conical shape and in females, spike-like structures typical of females of the genus *Setaria* were observed, which is similar to the findings of several other authors (Desset, 1966; Becklund & Walker, 1969; Rhee et al., 1994; Kim et al., 2010; Singh et al., 2015; Mrifag et al., 2021).

The quantity and distribution of sexual papillae varies according to the species. Desset (1966) reports 3 pairs of precloacal papillae, 3 medium papillae and 4 pairs of postcloacal papillae in the species *Setaria cornuta*. Rhee et al. (1994) showed 3 pairs of precloacal papillae in the species *Setaria digitata*, 1 pair of adcloacal papillae and 3 pairs of postcloacal papillae, diverging from the results of the present study.

The male specimens showed 17 cloacal papillae: 3 pairs of precloacal papillae, 1 medium papilla, 1 pair of adcloacal papillae, and 4 pairs of postcloacal papillae; characteristic of the species *Setaria labiatopapillosa*, observed by Becklund & Walker (1969). Watermeyer et al. (2013) report the presence of 4 pairs of precloacal papillae, one median papilla and 6 pairs of postcloacal papillae for the species *Setaria graberi*, diverging from what was observed in the present study.

That said, this is the first report of *Setaria labiatopapillosa* in the northern region in Brazil, thus constituting a new geographical record for the occurrence of the species of the present study, bovine abdominal cavity parasites in the Amazon.

Conclusions

After morphological and morphometric analyses *Setaria labiatopapillosa* was found to occur parasitizing *Bos taurus* and *Bubalus bubalis* on the island of Marajó, Pará, Brazil.

Acknowledgements

The authors are grateful the Laboratório de Microscopia Eletrônica de Varredura, ISPA, UFRA for the use of the scanning electron microscope. This study is part of the dissertation of Rogério Antonio Ribeiro Rodrigues, developed for the Programa de Pós-Graduação Saúde e Produção Animal na Amazônia, Instituto da Saúde e Produção Animal, Universidade Federal Rural da Amazônia (UFRA). This study was financed in part by the Coordenação de Aperfeiçoamento de Pessoal de Nível Superior (CAPES – BRASIL) - Finance Code 001 and Project Pró-Amazônia: Biodiversidade e Sustentabilidade (Edital N° 047/ 2012 – Ministério da Educação do Brasil). Raul Henrique da Silva Pinheiro was supported by a research fellowship from the “Programa de Pós-Graduação em Sociedade, Natureza e Desenvolvimento (PPGSND), Universidade Federal do Oeste do Pará – UFOPA/ CAPES/ BRASIL) – Finance Code 001”. Elane Giese thanks CNPq for the research productivity scholarship.

References

- Anderson RC. The Superfamily Filarioidea. In: Anderson RC. Nematode parasites of vertebrates: their development and transmission. 2nd ed. New York: CABI Publishing; 2000. p. 467-529. <http://dx.doi.org/10.1079/9780851994215.0000>.
- Bautista-Hernández CE, Monks S, Pulido-Flores G, Miranda R. A new species of *Paracreptotrema* (Digenea, Plagiorchiiformes, Allocreadiidae) infecting two species of poeciliids in Río Malila of the Río Pánuco basin, Hidalgo, México, with a key to the species of the genus. *ZooKeys* 2015; (482): 55-66. <http://dx.doi.org/10.3897/zookeys.482.8144>. PMID:25709530.
- Becklund WW, Walker ML. Taxonomy, hosts, and geographic distribution of the *Setaria* (Nematoda: Filarioidea) in the United States and Canada. *J Parasitol* 1969; 55(2): 359-368. <http://dx.doi.org/10.2307/3277411>. PMID:5778814.
- Bush AO, Lafferty KD, Lotz JM, Shostak AW. Parasitology meets ecology on its own terms: margolis et al. revisited. *J Parasitol* 1997; 83(4): 575-583. <http://dx.doi.org/10.2307/3284227>. PMID:9267395.
- Desset MC. Contribution à la systématique des Filaires du genre *Setaria*; valeur des diérides. *Mém Mus Natl Hist Nat Sér A, Zool* 1966;39(2):257-88. [online]. [cited 2021 Mar 14]. Available from: <https://biostor.org/reference/249230>
- Gomez-Puerta LA, Mayor P. Congenital filariasis caused by *Setaria bidentata* (Nematoda: Filarioidea) in the red brocket deer (*Mazama americana*). *J Parasitol* 2017; 103(1): 123-126. <http://dx.doi.org/10.1645/16-86>. PMID:27788338.
- Kim NS, Kim HC, Sim C, Ji JR, Kim NS, Park BK. Congenital infection with *Setaria digitata* and *Setaria marshalli* in the thoracic cavity of a Korean calf: a case report. *Vet Med* 2010; 55(6): 275-280. <http://dx.doi.org/10.17221/2987-VETMED>.
- Mrifag R, Lemrabott MA, El Kharrim KE, Belghyti D, Basco LK. *Setaria labiatopapillosa* (Filarioidea, Nematoda) in Moroccan cattle: atypical localization and morphological characterization of females and microfilariae by light and scanning electron microscopy. *Parasitol Res* 2021; 120(3): 911-918. <http://dx.doi.org/10.1007/s00436-020-06966-z>. PMID:33188488.

- Nakano H, Tozuka M, Ikadai H, Ishida H, Goto R, Kudo N, et al. Morphological survey of Bovine *Setaria* in the Abdominal Cavities of Cattle in Aomori and Kumamoto Prefectures, Japan. *J Vet Med Sci* 2007; 69(4): 413-415. <http://dx.doi.org/10.1292/jvms.69.413>. PMID:17485931.
- Pinheiro RHS, Furtado AP, Santos JN, Giese EG. *Contracecaecum* larvae: morphological and morphometric retrospective analysis, biogeography and zoonotic risk in the amazon. *Rev Bras Parasitol Vet* 2019; 28(1): 12-32. <http://dx.doi.org/10.1590/s1984-29612019002>. PMID:30892463.
- Rego AA. Redescrção de *Artionema bidentata* (Molin, 1858) comb. n. (Nematoda, Filarioidea). *Mem Inst Oswaldo Cruz* 1960; 58(2): 149-159. <http://dx.doi.org/10.1590/S0074-02761960000200002>. PMID:13740380.
- Rhee JK, Choi EY, Park BK, Jang BG. Application of scanning electron microscopy in assessing the prevalence of some *Setaria* species in Korean cattle. *Korean J Parasitol* 1994; 32(1): 1-6. <http://dx.doi.org/10.3347/kjp.1994.32.1.1>. PMID:8167102.
- Shin J, Ahn K-S, Jeong H-S, Kim B-S, Choi E, Shin S-S. First blindness cases of horses infected with *Setaria digitata* (Nematoda: Filarioidea) in the Republic of Korea. *Korean J Parasitol* 2017; 55(6): 667-671. <http://dx.doi.org/10.3347/kjp.2017.55.6.667>. PMID:29320823.
- Singh H, Singh N, Singh ND, Jyoti, Rath SS. Occurrence of *Setaria labiatopapillosa* in peritoneal cavity of a crossbred cattle. *J Parasit Dis* 2015; 39(2): 152-154. <http://dx.doi.org/10.1007/s12639-013-0308-3>. PMID:26063990.
- Soulsby EJL. *Helminths, arthropodes & protozoa of domesticated animals*. 7th ed. London: Baillière Tindall and Cassel; 1982.
- Țălu S, Ștefănuț A, Mihalca A, Coroiu Z. Subconjunctival infestation with *Setaria*. *Helmintologia* 2012; 49(2): 119-121. <http://dx.doi.org/10.2478/s11687-012-0024-z>.
- Vicente JJ, Rodrigues HO, Gomes DC, Pinto RM. Nematóides do Brasil. Parte V: nematóides de mamíferos. *Rev Bras Zool* 1997; 14(Suppl 1): 1-452. <http://dx.doi.org/10.1590/S0101-81751997000500001>.
- Watermeyer R, Putterill JF, Boomker J, Kuzmin Y, Junker K. Redescription of *Setaria graberi* Shoho in Troncy, Graber & Thal, 1976 (Nematoda: Filarioidea) based on specimens from *Redunca arundinum* (Bovidae) in South Africa. *Parasite* 2013; 20: 43. <http://dx.doi.org/10.1051/parasite/2013042>. PMID:24165230.
- Yeh LS. A revision of the nematode genus *Setaria* Viborg, 1795, its host-parasite relationship, speciation and evolution. *J Helminthol* 1959; 33(1): 1-98. <http://dx.doi.org/10.1017/S0022149X00003709>. PMID:13664929.