

D- α -tocopherol reduces renal damage in hypertensive rats

Thaís Maria da Fonseca Pletiskaitz, Guiomar Nascimento Gomes*

Department of Physiology, Federal University of São Paulo

This study investigated the beneficial effects of D- α -tocopherol supplementation in protecting against the renal morphological and functional changes caused by hypertension. Spontaneously hypertensive (SHR) and normotensive control (WKY) rats received D- α -tocopherol (80 mg/kg by gavage) or vehicle (mineral oil) every other day for 60 days, from the age of 2 months. After this treatment period, all animals were assessed for renal morphological and functional parameters. The glomerular hypertrophy, increased interlobular wall thickness and enlarged renal vascular resistance found in SHR were reduced by D- α -tocopherol treatment. Sodium and volume retention observed in SHR were also decreased by D- α -tocopherol treatment. Moreover, D- α -tocopherol supplementation significantly reduced arterial pressure in SHR but not in WKY. D- α -tocopherol also reduced the excretion of thiobarbituric acid-reactive substances (TBARS), a marker of oxidative stress, in SHR. These results suggest that D- α -tocopherol supplementation can reduce kidney damage induced by hypertension.

Uniterms: Hypertension. Renal injury. Glomerular enlargement. Vascular hypertrophy. D- α -tocopherol.

O presente estudo avaliou os efeitos benéficos da suplementação com D- α -tocopherol sobre as alterações morfológicas e funcionais renais causadas pela hipertensão arterial. A partir de dois meses de idade, ratos espontaneamente hipertensos (SHR) e controles normotensos (WKY) receberam D- α -tocoferol (80 mg/kg por gavagem) ou veículo (óleo mineral) em dias alternados, por 60 dias. Após este período foram avaliados os parâmetros morfofuncionais dos rins. Os animais SHR apresentaram: hipertrofia glomerular, aumento da espessura da parede das artérias interlobulares e elevação da resistência vascular renal. Estas alterações foram menores nos animais SHR suplementados com D- α -tocoferol. A retenção de sódio e de volume encontrada nos SHR também foi reduzida com o tratamento com D- α -tocoferol. Além disso, a suplementação com D- α -tocoferol reduziu significativamente a pressão arterial em SHR, mas não em WKY. Houve, também, redução da excreção de ácido tiobarbitúrico (TBARS), um marcador de estresse oxidativo, nos animais SHR tratados com D- α -tocoferol. Os resultados sugerem que suplementação com D- α -tocoferol é capaz de reduzir importantes alterações renais causadas pela hipertensão arterial.

Unitermos: Hipertensão arterial. Lesão renal. Aumento glomerular. Hipertrofia vascular. D- α -tocoferol.

INTRODUCTION

Besides representing a significant cardiovascular risk factor and major contributor to renal damage, hypertension alone is a serious public-health problem worldwide (Kearney *et al.*, 2005). Increased systemic blood pressure can be transmitted to the glomeruli leading to progressive renal injury which, in turn, can aggravate systemic hypertension (Fogo, 2000; Marcantoni *et al.*, 2000).

Intravascular volume expansion due to increased

sympathetic tone and/or angiotensin production, decreased activity of vasorelaxants such as nitric oxide (NO) and increased activity of vasoconstrictors such as endothelin, also participate in the development of hypertension (Luke, 1999; Razzaque *et al.*, 2003; Pechanova, 2010).

Over the last two decades, oxidative stress has been shown to play an important role in the pathogenesis of hypertension. Reactive oxygen species (ROS) are thought to act through several mechanisms to mediate vascular changes. ROS can directly affect endothelial and vascular smooth muscle cells, resulting in structural and functional damage, can scavenge or inactivate endothelium relaxing factors such as NO and prostacyclin and may also stimulate the production of peroxynitrite, a potent constrictor

*Correspondence: G. N. Gomes. Department of Physiology, Universidade Federal de São Paulo. Rua Botucatu 862 - 5º andar, 04023-900 - São Paulo - S.P., Brazil. Telephone: +55-11-55764511. Fax number: +55-11-55759165. E-mail address: guiomar.gomes@unifesp.br

and lipid-oxidizing radical (Rubo *et al.*, 1995; Abe *et al.*, 1998; Cohen, Tong, 2010). In the kidney, ROS imbalance is associated to glomerular and tubular dysfunction as well as sodium retention (Nistala *et al.*, 2008).

Diminished antioxidant capacity in essential hypertensive patients (Russo *et al.*, 1998; Pedro-Botet *et al.*, 2000; Rodrigo *et al.*, 2008) appears to be related to decreased concentrations of glutathione dismutase and superoxide dismutase (Pedro-Botet *et al.*, 2000). Supplementation with D- α -Tocopherol, the most active form of vitamin E, has been shown to improve the action of catalase, superoxide dismutase and glutathione dismutase (Lin *et al.*, 2005; Lexis *et al.*, 2006), resulting in reduced oxidative stress.

Considering the effect of D- α -tocopherol on antioxidant enzymes, and that hypertension and increased exposure to ROS can lead to renal dysfunction, the present study investigated whether D- α -tocopherol treatment can reduce the alterations of glomerular and renal vascular morphology observed in SHR and in renal function parameters.

MATERIAL AND METHODS

Animals and experimental treatments

Two-month-old male spontaneously hypertensive (SHR) and control Wistar-Kyoto (WKY) rats were obtained from the Center for Development of Experimental Models for Medicine and Biology (CEDEME - Federal University of São Paulo). The animals were kept in a temperature-controlled room under a 12:12 h light/dark cycle and were housed in individual cages with free access to water and food.

Half of the SHR and control animals received D- α -tocopherol every other day for 60 days (80 mg/kg by gavage, dissolved in mineral oil). The remaining animals received vehicle alone (mineral oil - 100 μ L). Blood pressure was measured using the tail-cuff method every 2 weeks during drug treatment. The experimental protocol was approved by the Research Ethics Committee of the Federal University of São Paulo.

Renal function studies

Animals were anaesthetized with sodium thiopental (30 mg/kg) and placed on a heated bench to maintain body temperature at 37 °C. Tracheotomy was followed by insertion of polyethylene catheters into the jugular vein for infusions and into the carotid artery for blood sampling. A catheter was inserted into the animal's bladder to obtain

urine samples. After the surgical procedures, a 1-hour stabilization period was allowed, followed by 3 collection periods. Animals were primed with 1 mL of saline containing inulin (90 mg/kg) and sodium para-aminohippurate (PAH, 6.5 mg/kg), then treated with continuous infusion of a saline solution containing inulin (15 mg/mL) and PAH (4 mg/mL) at 0.08 mL/min. Glomerular filtration rate (GFR) and renal plasma flow (RPF) were calculated from plasma and urine inulin and PAH concentrations, which were measured by colorimetry as previously described (Gomes *et al.*, 2005). Na⁺ and K⁺ in blood and urine were measured using ion-selective electrodes (Ciba-Corning 614 Na/K analyzer). Acid excretion was estimated based on excretion of titratable acidity (AT) and ammonium excretion (NH₄⁺), whereas AT was measured by microtitration, and NH₄⁺ by colorimetry (Gomes *et al.*, 2005).

Renal blood flow was calculated as renal plasma flow divided by 1-hematocrit. Resistance to blood flow through renal circulation was calculated as arterial blood pressure divided by renal blood flow.

Morphologic and morphometric analysis

Both kidneys were rapidly dissected, cleaned of connective tissue, weighed, and fixed in Bouin's fluid for 24h. Each kidney was cut in half longitudinally and embedded in wax. Sections (5 μ m thick) were cut from the region near the hilus and stained with Masson Trichrome. The wall thickness of the interlobar arteries was measured in Verhoeff-stained sections. Glomerular area was measured using the image analysis program Image-Pro Plus (Media Cybernetics). Images were acquired with a Sony video camera mounted on a Leica DMLA microscope. Twenty different fields in each slide were analyzed. Each image had an area of 285,000 μ m². Interlobular arteries were measured in ten different fields from each slide. Wall thickness was measured at 4 points at each vessel.

Measurement of hematocrit

Arterial blood samples (100 μ L) were collected in glass micro-hematocrit capillary tubes and centrifuged for 15 min at 4000 rpm to determine the concentration of red blood cells.

Estimation of oxidative stress

Measurement of thiobarbituric acid-reactive substances (TBARS) in urine samples

TBARS levels were measured by a spectrophotometric assay that quantifies a chromogen produced by

the reaction of thiobarbituric acid with malondialdehyde, using a commercial kit (OXItek TBARS Assay Kit, Zep-toMetrix Corporation, Buffalo, NY - USA).

Evaluation of 8-hydroxy-2'-deoxyguanosine (8-OHdG) in renal tissue

The expression of 8-OHdG, a marker of oxidative DNA damage, was analyzed in renal tissue by immunohistochemistry. Kidney sections were incubated overnight at 4 °C with anti-8-OHdG (Jaica, Japan) at a dilution of 1:50. The reaction product was detected with a streptavidin peroxidase complex (Dako LSAB System HRP, DAKO Corporation, Carpinteria, CA, USA). Oxidative DNA damage was assessed using a Leica DMLB microscope at a magnification of 400x, in which each studied field had an area of 70,500 μm^2 . The intensity of staining was determined using the image analysis program ImageJ 1.42q (National Institutes of Health, USA) and is expressed as pixels.

Statistical analysis

Statistical analysis was performed by one-way analysis of variance (ANOVA), followed by the Bonferroni test. Statistical significance was defined as $P \leq 0.05$. Results are reported as mean \pm SEM.

RESULTS

Body weight was higher in hypertensive rats than in normotensive controls (313 ± 9 vs. 277 ± 7 g). Hypertensive rats also had larger kidneys (1.40 ± 0.03 vs. 1.18 ± 0.03 g), but relative kidney weight was similar in both hypertensive and control rats. D- α -tocopherol did not affect final body weight or relative kidney weight.

D- α -tocopherol reduced blood pressure values in SHR. The reduction observed was around 23 mm Hg in

SHR treated with D- α -tocopherol for 45 days compared to untreated SHR ($p < 0.001$). D- α -tocopherol did not significantly alter blood pressure in normotensive control rats (Figure 1).

GFR was reduced in SHR compared to normotensive controls (Table 1). D- α -tocopherol increased GFR in SHR to levels similar to those seen in normotensive controls, suggesting that D- α -tocopherol has a beneficial effect on renal function. Urine flow, sodium excretion, and potassium excretion were all reduced in SHR compared with normotensive controls (Table 1). D- α -tocopherol treatment increased each of these parameters in SHR, but had little effect in normotensive controls.

Excreted amount of ammonium and titratable acidity were significantly increased in SHR but these parameters

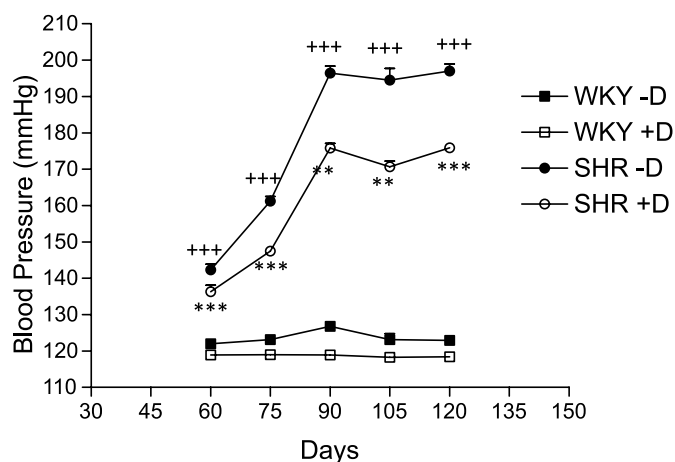


FIGURE 1 - Effect of D- α -tocopherol on blood pressure in SHR and control rats. Error bars indicate SEM. *** $p < 0.001$ compared to SHR without D- α -Tocopherol and +++ $p < 0.001$ compared to WKY without D- α -Tocopherol. (ANOVA followed by the Bonferroni test). Squares = WKY, circles = SHR, open symbols = without D- α -tocopherol, closed symbols = with D- α -tocopherol.

TABLE I - Effect of D- α -Tocopherol (D) on renal function in SHR and control rats

	normotensive (WKY)		hypertensive (SHR)	
	-D	+D	-D	+D
GFR (mL/min/kg)	7.04 \pm 0.15 (28/7)	7.16 \pm 0.16 (28/7)	5.56 \pm 0.11+++ (28/7)	6.70 \pm 0.16*** (28/7)
RPF (mL/min/kg)	21.66 \pm 0.73 (28/7)	26.05 \pm 0.80+++ (28/7)	19.71 \pm 0.66 (28/7)	22.93 \pm 0.53** (28/7)
V (mL/min/kg)	0.17 \pm 0.01 (28/7)	0.17 \pm 0.01 (28/7)	0.13 \pm 0.01 Θ (28/7)	0.17 \pm 0.01* (28/7)
FF (%)	33.98 \pm 1.84 (28/7)	28.31 \pm 1.19 Θ (28/7)	29.06 \pm 1.16 (28/7)	29.03 \pm 0.84 (28/7)
EA _{Na} ⁺ (mEq/min/kg)	11.69 \pm 0.79 (20/5)	12.24 \pm 0.59 (28/7)	5.74 \pm 0.43+++ (20/5)	10.20 \pm 1.42* (28/7)
EA _K ⁺ (mEq/min/kg)	8.75 \pm 0.43 (20/5)	9.47 \pm 0.39 (28/7)	6.20 \pm 0.36+++ (20/5)	7.78 \pm 0.28* (28/7)

GFR = glomerular filtration rate, RPF = renal plasma flow, FF = filtration fraction, V = urine flow, EA_{Na}⁺ = excreted amount of sodium, EA_K⁺ = excreted amount of potassium. Data is shown as mean \pm SEM. Values between parentheses represent the number of measurements/number of animals. * $p < 0.05$, ** $p < 0.01$, and *** $p < 0.001$ vs SHR-D and +++ $p < 0.001$ vs WKY-D.

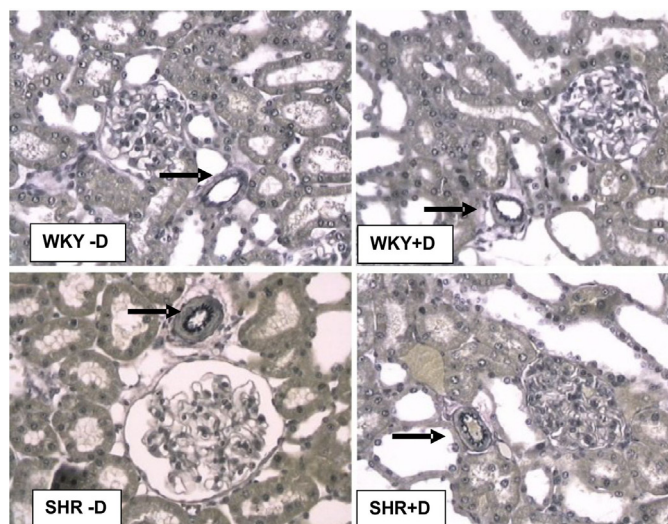
TABLE II - Effect of D- α -Tocopherol (D) on hematocrit, renal vascular resistance (RVR), and interlobular artery wall thickness (IAWT) in SHR and control rats

	normotensive (WKY)		hypertensive (SHR)	
	-D	+D	-D	+D
Hematocrit (%)	47.20 \pm 0.76 (8/2)	47.08 \pm 0.16 (16/4)	48.50 \pm 0.57 (8/2)	48.20 \pm 0.90 (16/4)
RVR (mmHg/mL/min)	3.03 \pm 0.14 (8/4)	2.67 \pm 0.12 (16/4)	5.61 \pm 0.24+++ (8/2)	3.94 \pm 0.16*** (16/4)
IAWT (μ)	11.01 \pm 0.28 (280/4)	10.87 \pm 0.21 (280/7)	16.24 \pm 0.37+++ (280/7)	12.50 \pm 0.28*** (280/7)

Data is shown as mean \pm SEM. Values between parentheses represent the number of measurements/number of animals. *** $p < 0.001$ compared to SHR without D- α -Tocopherol and +++ $p < 0.001$ compared to WKY without D- α -Tocopherol. (ANOVA followed by the Bonferroni test).

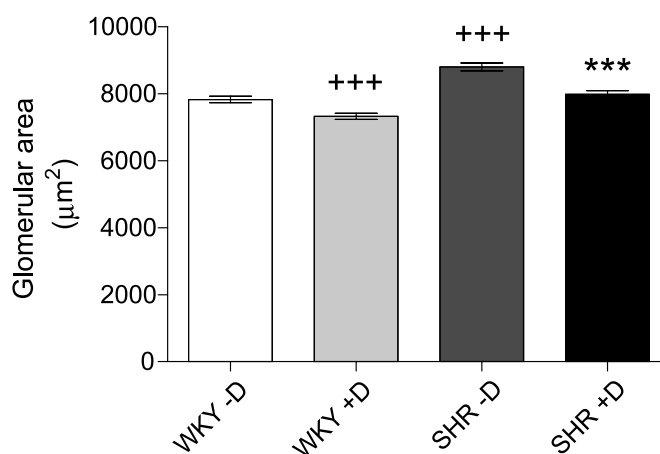
were similar in both treated SHR and control animals (NH_4^+ $\mu\text{mol}/\text{min}/\text{kg}$; WKY: 2.5 \pm 0.1; WKY+D: 2.2 \pm 0.1; SHR: 3.4 \pm 0.2; SHR+D: 2.7 \pm 0.1) (AT $\mu\text{mol}/\text{min}/\text{kg}$; WKY: 2.6 \pm 0.1; WKY+D: 1.8 \pm 0.1; SHR: 3.1 \pm 0.2; SHR+D: 2.8 \pm 0.1).

Wall thickness of the interlobular artery and resistance of the renal vascular bed were significantly increased in SHR compared to normotensive controls (Figure 2 and Table 2). In SHR, D- α -tocopherol reduced both interlobular artery wall thickness and renal vascular resistance, but in normotensive controls the drug had no effect.

**FIGURE 2** - Effect of D- α -tocopherol on thickness of interlobular artery wall (arrow) in SHR and control rats. Representative Verhoeff-stained sections are shown. Magnification: 200x.

SHR had significantly larger glomeruli than normotensive controls (Figure 3). D- α -tocopherol reduced glomerular area in both SHR and normotensive controls.

Treatment with D- α -tocopherol significantly reduced urinary excretion of thiobarbituric acid-reactive substances (TBARS, nmol/mL; SHR: 37.2 \pm 2.1(6); SHR

**FIGURE 3** - Effect of D- α -tocopherol on glomerular area. Error bars indicate SEM. *** $p < 0.001$ compared to SHR without D- α -Tocopherol, and +++ $p < 0.001$ compared to WKY without D- α -Tocopherol. (ANOVA followed by the Bonferroni test).

plus D- α -tocopherol: 28.0 \pm 17 (6)), a marker of oxidative stress, and also diminished the presence of 8-OHdG in renal tissue (Figure 4).

DISCUSSION

Renal hemodynamic studies performed in SHR have indicated that increased renal vascular resistance is present in young animals before the development of hypertension, suggesting this alteration could be a causative factor for the progression of hypertension (Skov, Mulvany, 2004). The afferent arterioles have been implicated as the predominant site of increased renal resistance in SHR (Ito *et al.*, 1992; Skov, Mulvany, 2004) but other studies have indicated that increased intrarenal resistance is spread throughout the segmental vasculature (Lowenstein *et al.*, 1970; Hsu *et al.*, 1982).

In the present study, we observed an increase in renal vascular resistance and interlobar artery wall thickness in

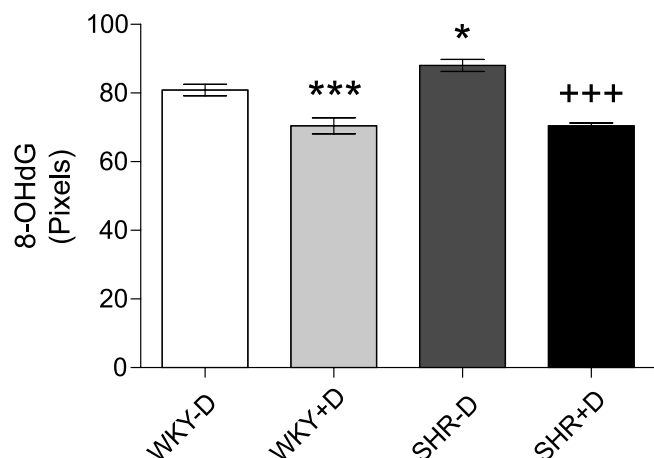


FIGURE 4 - Quantification of 8-OHdG in renal tissue. Error bars indicate SEM. * $p < 0.05$, *** $p < 0.001$ compared to WKY-D, and +++ $p < 0.001$ compared to SHR-D. (ANOVA followed by the Bonferroni test).

SHR compared to normotensive controls, confirming the results shown by Kett *et al.* (1995) and reinforcing the notion that vascular changes are not restricted to the afferent arteriole. Moreover, we also observed that D- α -tocopherol treatment, from a young age, prevented increase in interlobar artery wall thickness and renal vascular resistance in SHR. Another important morphological change that occurred in SHR was glomerular hypertrophy. This alteration could be related to increased blood pressure transmitted to glomerular capillaries as demonstrated by Ofstad and Iversen (2005), and/or could be a consequence of increased postglomerular vascular resistance. Treatment with D- α -tocopherol also prevented glomerular hypertrophy in SHR.

Functional studies have demonstrated that treatment with angiotensin converting enzyme (ACE) inhibitors reduces renal vascular resistance and increases both renal blood flow and GFR in SHR (Harrap *et al.*, 1986; Numabe *et al.*, 1994). However, SHR do not have augmented levels of renin or angiotensin II (ANG II) (Chatziantoniou, Arendshorst, 1991), thus the effectiveness of this treatment appears to be due to increased responsiveness of renal vasculature to the constrictor effect of ANG II in SHR (Vyas, Jackson, 1995; Dukacz *et al.*, 2001; Kobori *et al.*, 2007).

Increased production of superoxide (O_2^-) has been demonstrated in several experimental models of hypertension, including hypertension induced by partial nephrectomy, salt-sensitive hypertension, and SHR (Adler, Huang, 2004). Increased O_2^- is associated with changes in nitric oxide synthase enzyme (NOS) expression (Welch, Wilcox, 2001), inactivation of nitric oxide (Hermann *et al.*, 2006), and generation of peroxynitrite and isoprostanes (Cohen, Tong, 2010). ANG II can also increase ROS production

via AT1 receptors that activate intracellular mediators, stimulating superoxide production through the NAD(P)H oxidase system (Plumb *et al.*, 2005).

In this study, SHR treated with D- α -Tocopherol showed a reduction in blood pressure together with reduced urinary TBARS excretion, suggesting that the reduction in blood pressure occurs as consequence of reduced oxidative stress. These results are in agreement with data from Newaz and Nawal (1998) showing reduction of lipid peroxides in plasma and blood vessels and enhancement of total antioxidants, in parallel to reduced blood pressure, in SHR supplemented with D- α -Tocopherol. Thus, it is possible that D-alpha-Tocopherol, by improving the action of antioxidant enzymes (Lin *et al.*, 2005; Lexis *et al.*, 2006), reduces ROS and restores NO levels to within normal range, resulting in vasodilatation and reduced blood pressure. In the kidney, effects of ANG II and other vasoconstrictors are modulated by NO (Herman *et al.*, 2006; Patzak, Persson, 2007). Increasing oxidative stress by reducing NO availability can exacerbate the renal vasculature response to vasoconstrictors. Hence, chronic use of D- α -Tocopherol can enhance antioxidant enzymes, resulting in vasodilatation of afferent and/or efferent arterioles, decreased pre and/or post-glomerular resistances, and reduced changes observed in renal morphology of SHR such as glomerular and vascular hypertrophy. It is known that glomerular hypertrophy is related to the development of glomerulosclerosis (Fogo, 2000) where the prevention of this alteration can contribute toward preventing the development of kidney disease.

Increased renal vascular resistance is also related to the reduced levels of RPF and GFR found in SHR. Treatment with D- α -Tocopherol appears to improve renal hemodynamics in SHR since it significantly increased RPF and GFR levels. These results suggest that the renal morphological and functional changes observed in SHR could be due, at least in part, to vasoconstriction caused by increased oxidative stress. However, other mechanisms may also contribute to the increased renal vascular resistance in SHR, including structural alterations (Anderson *et al.*, 2000), pressure-induced vasoconstriction (Ito *et al.*, 1992), increased renal sympathetic nerve activity (Korner *et al.*, 1993), or renal hypersensitivity to vasoconstrictor agents such as angiotensin II (Vyas, Jackson 1995).

In the present study, we observed reduced levels of sodium excretion in SHR. It is possible that this reduction was due to increased proximal sodium reabsorption considering that potassium excretion was not increased in SHR. Renal sodium retention is thought to be one of the genetic causes of hypertension in SHR (Morduchowicz *et al.*, 1989; Boer *et al.*, 2005). Moreover, increased Na^+

H⁺ exchange has been reported in proximal tubule cells of young SHR (Morduchowicz *et al.*, 1989). This effect appears to be due to increased activity of transporters rather than to an increased number of transporters since transporter mRNA abundance was found to be normal (Hayash *et al.*, 1997; Kobayashi *et al.*, 2004).

In SHR treated with D- α -tocopherol, sodium excretion was similar to that seen in normotensive controls. D- α -tocopherol also restored the reduced urine flow observed in SHR to the levels seen in control animals. It is possible that vascular changes alter interstitial hydrostatic pressure contributing to sodium and volume excretion in SHR. Alternatively, the decrease in oxidative stress could lead to a reduction in renal sympathetic nerve activity, known to be elevated in SHR (Korner *et al.*, 1993; Boer *et al.*, 2005), causing natriuresis and diuresis.

We observed that acid excretion evaluated by urinary concentration of NH₄⁺ and titratable acid, was significantly higher in SHR than in normotensive controls. These urinary changes are consistent with the increased activity of the Na⁺/H⁺ exchanger in the proximal tubule in SHR reported previously (Hayashi *et al.*, 1997). Treatment with D- α -tocopherol reverted these changes. The use of α -tocopherol in hemodialysis patients was also shown to reduce serum urate concentration, probably as a result of its inhibitory effect on xantine oxidase. This effect can result in ROS reduction given that, besides urate formation, the enzyme also produces ROS (Eleftheriadis *et al.*, 2010).

CONCLUSIONS

Taken together, these results suggest that D- α -tocopherol supplementation is able to protect, at least in part, against the harmful effects of hypertension on renal function. In fact, glomerular hypertrophy and thickening of the interlobular artery wall were prevented by D- α -tocopherol administration; glomerular filtration rate, acid excretion and sodium excretion, significantly changed in SHR, were restored to values similar to control levels in SHR treated with D- α -Tocopherol. These results indicate that D- α -tocopherol may be useful for preventing the progression of renal injury caused by hypertension.

REFERENCES

- ABE, J.I.; BERK, B.C. Reactive oxygen species as mediators of signal transduction in cardiovascular disease. *Trends Cardiovasc. Med.*, v.8, p.59-64, 1998.
- ADLER, S.; HUANG, H. Oxidant stress in kidneys of spontaneously hypertensive rats involves both oxidase overexpression and loss of extracellular superoxide dismutase. *Am. J. Physiol. Renal. Physiol.*, v.287, p.F907-F913, 2004.
- ANDERSON, W.P.; KETT, M.M.; STEVENSON, K.M.; EDGLEY, A.J.; DENTON, K.M.; FITZGERALD, S.M. Renovascular hypertension: structural changes in the renal vasculature. *Hypertension*, v.36, p.648-652, 2000.
- BOER, P.A.; MORELLI, J.M.; FIGUEIREDO, J.F.; GONTIJO, J.A.R. Early altered renal sodium handling determined by lithium clearance in spontaneously hypertensive rats (SHR): Role of renal nerves. *Life Sci.*, v.76, p.1805-1815, 2005.
- CHATZIANTONIOU, C.; ARENDSHORST, W.J. Angiotensin and thromboxane in genetically hypertensive rats: Renal blood flow and receptor studies. *Am. J. Physiol.*, v.261, p.F238-F247, 1991.
- COEHN, R.A.; TONG, X.Y. Vascular oxidative stress: the common link in hypertensive and diabetic vascular disease. *J. Cardiovasc. Pharmacol.*, v.55, p.308-316, 2010.
- DUKACZ, S.A.; FENG, M.G.; YANG, L.F.; LEE, R.M.; KLINE, R.L. Abnormal renal medullary response to angiotensin II in SHR is corrected by long-term enalapril treatment. *Am. J. Physiol. (Regul Integr Comp Physiol)*, v.280, p.1076-1084, 2001.
- FOGO, A.B. Glomerular hypertension, abnormal glomerular growth, and progression of renal diseases. *Kidney Int.*, v.75, p.S15-S21, 2000.
- GOMES, G.N.; BARBOSA, F.T.; RADAELI, R.F.; CAVANAL, M.F.; MELLO AIRES, M.; ZALADEK GIL, F. Effect of D- α -tocopherol on tubular nephron acidification by rats with induced diabetes mellitus. *Braz. J. Med. Biol. Res.*, v.38, p.1043-1051, 2005.
- HARRAP, S.B.; NICOLACI, J.A.; DOYLE, A.E. Persistent effect on blood pressure and renal haemodynamics following chronic angiotensin converting enzyme inhibition with perindopril. *Clin. Exp. Pharmacol. Physiol.*, v.13, p.753-765, 1986.
- HAYASHI, M.; YOSHIDA, T.; MONKAWA, T.; YAMAJI, Y.; SATO, S.; SARUTA, T. Na⁺/H⁺-exchanger 3 activity and its gene in the spontaneously hypertensive rat kidney. *J. Hypertens.*, v.15, p.43-48, 1997.

- HERMANN, M.; FLAMMER, A.; LUSCHER, T.F. Nitric oxide in hypertension. *J. Clin. Hypertens.*, v.8, p.17-29, 2006.
- HSU, C.H.; SLAVICEK, J.H.; KURTZ, T.W. Segmental renal vascular resistance in the spontaneously hypertensive rat. *Am. J. Physiol.*, v.242 p.H961-H966, 1982.
- ITO, S.; JUNCOS, L.A.; CARRETERO, A.O. Pressure-induced constriction of the afferent arteriole of spontaneously hypertensive rats. *Hypertension*, v.19, p.164-167, 1992.
- KEARNEY, P.M.; WHELTON, M.; REYNOLDS, K.; MUNTNER, P.; WHELTON, P.K.; HE, J. Global burden of hypertension: analysis of worldwide data. *Lancet*, v.365, p.217-223, 2005.
- KETT, M.M.; ALCORN, D.; BERTRAM, J.F.; ANDERSON, W.P. Enalapril does not prevent renal arterial hypertrophy in spontaneously hypertensive rat. *Hypertension*, v.25 p.335-342, 1995.
- KOBAYASHI, K.; MONKAWA, T.; HAYASHI, M. SARUTA, T. Expression of the Na⁺/H exchanger regulatory protein family in genetically hypertensive rats. *J. Hypertens.*, v.22, p.1723-1730, 2004.
- KOBORI, H.; NANGAKU, M.; NAVAR, L.G.; NISHIYAMA, A. The intrarenal renin-angiotensin system: from physiology to the pathobiology of hypertension and kidney disease. *Pharmacol. Rev.*, v.59, p.251-287, 2007.
- KORNER, P.; BOBIK, A.; ODDIE, C.; FRIBERG, P. Sympathoadrenal system is critical for structural changes in genetic hypertension. *Hypertension*, v.22, p.243-252, 1993.
- LEXIS, L.A.; FASSETT, R.G.; COOMBES, J.S. Alpha-tocopherol and alpha-lipoic acid enhance the erythrocyte antioxidant defence in cyclosporine A-treated rats. *Basic Clin. Pharmacol. Toxicol.*, v.98, p.68-73, 2006.
- LIN, Y.F.; TSAI, H.L.; LEE, Y.C.; CHANG, S.J. Maternal vitamin E supplementation affects the antioxidant capability and oxidative status of hatching chicks. *J. Nutr.*, v.135, p.2457-2461, 2005.
- LOWENSTEIN, J.; BERANBAUM, E.R.; CHASIS, H.; BALDWIN, D.S. Intrarenal pressure and exaggerated natriuresis in essential hypertension. *Clin. Sci.*, v.38, p.359-374, 1970.
- LUKE, R.G. Hypertensive nephrosclerosis: pathogenesis and prevalence. Essential hypertension is an important cause of end-stage renal disease. *Nephrol. Dial Transplant.*, v.14, p.2271-2278, 1999.
- MARCANTONI, C.; JAFAR, T.H.; OLDRIZZI, L.; LEVEY, A.S.; MASCHIO, G. The role of systemic hypertension in the progression of nondiabetic renal disease. *Kidney Int.*, v.75, p.S44-S48, 2000.
- MoRDUCHOWICZ, G.A.; SHEIKH-HAMAD, D.; JO, O.D.; NORD, E.P.; LEE, D.B.; YANAGAWA, N. Increased Na⁺/H⁺ antiport activity in the renal brush border membrane of SHR. *Kidney Int.*, v.36, p.576-581, 1989.
- NEWAZ, M.A.; NAWAL, N.N. Effect of alpha-tocopherol on lipid peroxidation and total antioxidant status in spontaneously hypertensive rats. *Am. J. Hypertens.*, v.11, p.1480-1485, 1998.
- NISTALA, R.; WHALEY-CONNELL, A.; SOWERS, J.R. Redox Control of renal function and hypertension. *Antioxid. Redox Signal.*, v.10, p.2047-2089, 2008.
- NUMABE, A.; KOMATSU, K.; FROHLICH, E.D. Effects of ANG-converting enzyme and alpha 1-adrenoceptor inhibition on intrarenal hemodynamics in SHR. *Am. J. Physiol.*, v.266, p.R1437-R1442, 1994.
- OFSTAD, J.; IVERSEN, B.M. Glomerular and tubular damage in normotensive and hypertensive rats. *Am. J. Physiol. Renal Physiol.*, v.288, p. F665-F672, 2005.
- PATZAK, A.; PERSSON, A.E. Angiotensin II-nitric oxide interaction in the kidney. *Curr. Opin. Nephrol. Hypertens.*, v.16, p.46-51, 2007.
- PECHANOVA, O. Contribution of central nervous system to hypertension: role of angiotensin II and nitric oxide. *Act. Nerv. Super Rediviva*, v.52 p.223-227, 2010.
- PEDRO-BOTET, J.; COVAS, M.I.; MARTÍN, S.; RUBIÉS-PRAT, J. Decreased endogenous antioxidant enzymatic status in essential hypertension. *J. Hum. Hypertens.*, v.14, p.343-345, 2000.
- PLUMB, R.D.; EL-SHERBEENY, N.A.; DIXON, L.J.; HUGHES, S.M.; DEVINE, A.B.; LEAHEY, W.J.; McVEIGH, G.E. NAD(P)H-dependent superoxide production in platelets: The role of angiotensin II and protein kinase C. *Clin. Biochem.*, v.38, p.607-613, 2005.

- RAZZAQUE, M.S.; AZOUZ, A.; SHINAGAWA, T.; TAGUCHI, T. Factors regulation the progression of hypertensive nephrosclerosis. *Contrib. Nephrol.*, v.39, p.173-186, 2003.
- RODRIGO, R.; PRAT, H.; PASSALACQUA, W.; ARAYA, J.; BÄCHLER, J.P. Decrease in oxidative stress through supplementation of vitamins C and E is associated with a reduction in blood pressure in patients with essential hypertension. *Clin. Sci.*, v.114, p.625-634, 2008.
- RUBBO, H.; TARPEY, M.; FREEMAN, B.A. Nitric oxide and reactive oxygen species in vascular injury. *Biochem. Soc. Symp.*, v.61, p.33-45, 1995.
- RUSSO, C.; OLIVIERI, O.; GIRELLI, D. Antioxidant status and lipid peroxidation in patients with essential hypertension. *J. Hypertens.*, v.16, p.1267-1271, 1998.
- SKOV, K.; MULVANY, M.J. Structure of renal afferent arterioles in the pathogenesis of hypertension. *Acta Physiol. Scand.*, v.181, p.397-405, 2004.
- VYAS, S.J.; JACKSON, E.K. Angiotensin II: enhanced renal responsiveness in young genetically hypertensive rats. *J. Pharmacol. Exp. Ther.*, v.273, p.768-777, 1995.
- WELCH, W.J.; WILCOX, C.S. AT1 receptor antagonist combats oxidative stress and restores nitric oxide signaling in the SHR. *Kidney Int.*, v.59, p.1257-1263, 2001.

Received for publication on 26th August 2011

Accepted for publication on 05th April 2012