

# Alveolar corticotomies in orthodontics: Indications and effects on tooth movement

Dauro Douglas Oliveira\*, Bruno Franco de Oliveira\*\*, Rodrigo Villamarim Soares\*\*\*

## Abstract

**Introduction:** The systematic search for increased efficiency in orthodontic treatment is shared by several areas of orthodontics. Performing alveolar corticotomies shortly before the application of orthodontic forces has been suggested as a method to enhance tooth movement and, consequently, orthodontic treatment as a whole. **Objective:** This article reviews the historical perspective of this therapeutic approach, presents and illustrates with clinical cases its main indications and finally discusses the biological reasons underlying its use.

**Keywords:** Alveolar corticotomies. Orthodontic tooth movement. Accelerated orthodontics. Orthodontic treatment.

## INTRODUCTION

When are you taking off my braces? This is probably the question most often addressed to orthodontists in their daily practice. Which orthodontic patient is not enthusiastic about the possibility of reducing their treatment time? Given this constant demand for shorter treatments, orthodontists from around the world have increasingly sought ways to boost orthodontic treatment efficiency.

The search for this efficiency, i.e., new approaches to shorten treatment time without foregoing optimal results, has become a primary goal of all areas of orthodontics. Low friction and self-ligating bracket systems, robot preformed

archwires, rapid canine retraction and alveolar corticotomies are examples of approaches that aim to reduce the time required by orthodontic therapy. Since the promise of a faster treatment holds considerable commercial appeal, orthodontists are faced with a major challenge: To critically sift through the available options by distinguishing genuine breakthroughs in alternative treatment approaches from others more financially oriented and not committed to improving service quality for our patients.

Professionals intent on performing alveolar corticotomies to enhance orthodontic treatment are bound to be confronted by this challenge. Reintroduced in the late 20<sup>th</sup> century, this

\* Coordinator, MSc Program in Orthodontics, PUC Minas. PhD in Orthodontics, Federal University of Rio de Janeiro (UFRJ). MSc in Orthodontics, Marquette University – Milwaukee, WI, USA.

\*\* MSc in Dental Prosthesis, PUC Minas.

\*\*\* Coordinator, MSc Program in Periodontics, PUC Minas. PhD in Oral Biology, Boston University - Boston, MA, USA.

alternative treatment has aroused much curiosity and controversy, fueled, in part, at least by the promotional and commercial interest of the professionals who put it back into the orthodontic scenery. Despite some initial resistance, some researchers saw potential in the clinical reports and began to investigate the effects of corticotomies with a more scientific perspective. Currently there are at least ten centers and research groups studying this topic in countries like South Korea, the U.S., Japan and Brazil.<sup>1</sup>

The upshot of this steady academic trend is reflected in the recent increase in the number of alveolar corticotomy articles published in prestigious scientific journals. Another example of this growing interest can be illustrated by an event that took place in the last Meeting of the American Association of Orthodontists, held in Washington in May 2010: The highest award for research in orthodontics in the United States and Canada (the Milo Hellman Award) was bestowed on a study that assessed the mechanism and morphological changes in alveolar bone following alveolar corticotomies<sup>2</sup>.

Based on scientific publications and clinical experience, we aim to explain important aspects that should be taken into consideration in using alveolar corticotomies as an aid to orthodontic treatment. We also propose to discuss the historical perspective of this therapeutic approach,

indications for its clinical use, biological foundations for its use as well as its limitations and risks. We therefore hope to contribute to disseminate information on this topic, which will inform the decision-making process of those professionals desiring to use this procedure in their clinical activities.

### WHAT ARE ALVEOLAR CORTICOTOMIES AND WHAT IS THE HISTORICAL PERSPECTIVE OF THEIR USE IN ORTHODONTICS?

Alveolar corticotomies (ACS) are defined as a surgical intervention limited to the cortical portion of the alveolar bone. Whereas in osteotomies both cortical and trabecular bone material is removed in considerable quantities, in ACS the incision must pierce the cortical layer, and at the same time, penetrate into the bone marrow only minimally (Fig 1).<sup>3</sup> During the last decade, the performance of ACS was again suggested as a means to enhance orthodontic treatment.<sup>4,5,6</sup>

Attempts to shorten the time needed for tooth movement can be divided into three categories: (1) local administration of chemicals, (2) physical or mechanical stimulation of the alveolar bone, such as the use of direct electrical current or magnets, and (3) surgery, including dental distraction and alveolar corticotomies.<sup>7</sup> The first reports on surgical approaches to correct poorly positioned teeth are assigned to L. C.

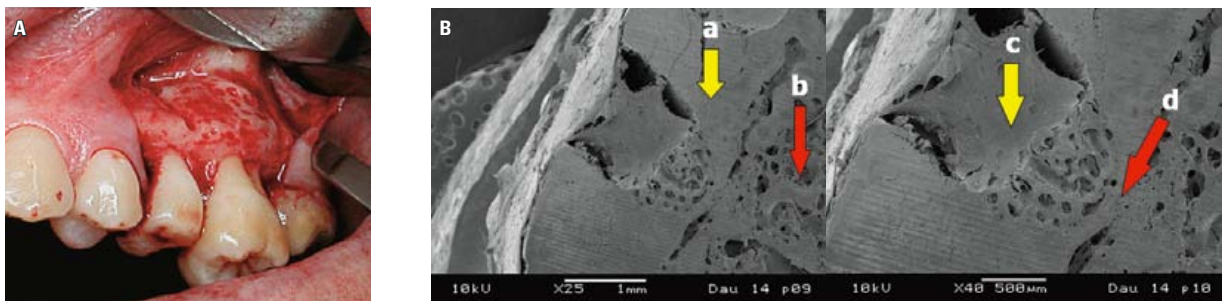


FIGURE 1 - **A)** Clinical aspect of alveolar corticotomy. **B)** Scanning electron microscopy (SEM) image showing the depth reached by the bur in the alveolar bone of dogs, where: **a)** cortical bone, **b)** trabecular bone, **c)** surgical injury being filled by young cortical bone, **d)** bur perforation as far as the limit between cortical and trabecular bone (Source: adapted from Oliveira<sup>3</sup>).

Brian, in 1892, and G. Cunningham, in 1893.<sup>8</sup> The former reported such cases at the Meeting of the American Dental Society of Europe and the latter presented the possibility of immediate correction of irregular teeth during the Dental Conference in Chicago that year.

Some fifty-odd years later, in 1959, Köle<sup>9</sup> used a combination of interradicular corticotomies and supra-apical osteotomies to speed up tooth movement. This treatment approach never gained widespread acceptance, probably due to the association of horizontal subapical osteotomies, which posed considerable risks to the periodontium and tooth pulp vitality.<sup>10</sup> Furthermore, the use of removable orthodontic appliances provided poor control of tooth movement, which inevitably compromised orthodontic treatment outcome. In 1975, Dük-er<sup>11</sup> performed the first animal study replicating the technique described by Köle.<sup>9</sup> A few years later, subapical osteotomies were replaced by cuts limited to the cortical portion of the alveolar bone. Hence the first description of a surgical attempt to enhance orthodontic treatment using only corticotomies, thereby reducing the risks inherent in the previous approach. Furthermore, the use of fixed orthodontic appliances increased the control and efficiency afforded by this therapeutic combination.<sup>12</sup>

Nevertheless, the use of ACS as an aid to orthodontic therapy remained limited. Since 2001, however, there have been renewed attempts at popularizing this therapeutic approach. A modified, more localized surgical technique proved very effective in helping to intrude supra-extruded molars with magnets.<sup>13</sup> In addition, another variant—which expands the technique and combines it with lyophilized bone grafts—was presented as a means to accelerate and significantly shorten conventional orthodontic treatment time.<sup>4</sup>

As the Wilcko brothers—an orthodontist and a periodontist—reported<sup>4</sup> a 1/2 to 1/3 reduction

in traditional orthodontic treatment time, their publications and conference presentations aroused intense curiosity, mainly because they were based solely on case reports. In this context, many clinical orthodontists and researchers began to study into this subject in order to gain an in-depth understanding of how alveolar corticotomies affect orthodontic movement.

### WHEN ARE CORTICOTOMIES INDICATED IN ORTHODONTICS?

After the first reports by the Wilcko brothers,<sup>4</sup> a wide array of combined ACS-orthodontic treatment techniques have been described in the literature. Reports can be found that describe the successful use of ACS in the enhanced correction of severe bimaxillary protrusion,<sup>14</sup> closure of complex skeletal open bites,<sup>15</sup> facilitated molar intrusion with removable appliances,<sup>16</sup> intrusion and molar uprighting combining ACS and mini-implants,<sup>6</sup> and optimization of treatment of patients with cleft lip and palate,<sup>17</sup> among others. The indications for the use of ACS in orthodontics have been grouped into three main categories: (1) to accelerate corrective orthodontic treatment, as a whole, (2) to facilitate the implementation of mechanically challenging orthodontic movements, and (3) to enhance the correction of moderate to severe skeletal malocclusions.

### Accelerating corrective orthodontic treatment

Conventional orthodontic movement is a biological process characterized by sequential reaction of the periodontal tissue and alveolar bone adjacent to the mechanical forces produced by an orthodontic appliance.<sup>18</sup> Variables such as force system properties, turnover features of the periodontal ligament, and bone metabolism levels, play important roles in determining the type and amount of tooth movement to be achieved. The ability to speed up

orthodontic movement and decrease total treatment time was particularly highlighted by the Wilcko brothers in 2001,<sup>4</sup> as explained in more detail in 2009.<sup>19</sup>

The technique described by these authors was named Accelerated Osteogenic Orthodontics (AOO)<sup>4</sup> and subsequently renamed Periodontally Accelerated Osteogenic Orthodontics (PAOO).<sup>19</sup> This approach combines multiple alveolar corticotomies, often extended from molar to molar. Grooves are cut in the cortical bone, both on the buccal and lingual surfaces, in one or both arches, followed by placement of lyophilized bone grafts before repositioning and suturing the gingival flap.

Fixed orthodontic appliances should be installed approximately one week before surgery. Corticotomies should then be performed around the teeth to stimulate the process of bone regeneration. The authors suggest that the bone grafts are aimed at increasing alveolar volume so that even if very large expansions were implemented to resolve severe crowding, the roots would still have sufficient support. Some cases were presented whereby tooth movement occurred two to three times faster than would have been achieved with orthodontics alone.<sup>4,19</sup>

It should be commented that the presented cases showed significant dental expansion both in the transverse and anteroposterior direction. After the opening of the gingival flap, a larger than expected amount of fenestration and dehiscence was noted. Since the tooth movement was "buccal to the alveolar bone," grafts of lyophilized material would minimize the risks associated with such movement.<sup>4,19</sup>

We have had no experience with the use of multiple corticotomies in orthodontic treatment and consider that, in our view, orthodontic treatment acceleration does not justify or outweigh the risks and invasiveness of the procedure. We also suspect that such substantial

anteroposterior and transverse expansion might jeopardize facial aesthetics and stability of the results. It is important, however, to recognize the historical importance of the approach by briefly describing it. Regardless of when ACS should or should not be indicated, it is undeniable that the results reported by Wilcko et al<sup>4,19</sup> aroused our curiosity about other clinical situations where alveolar corticotomies could be applied. The ability to (a) facilitate alveolar bone response in complex dental movements, or (b) take advantage of a surgical procedure that was already originally part of the treatment plan, are examples of conditions where we believe ACS could be useful, as will be illustrated as follows.

#### **Facilitating complex orthodontic movements**

Given the fact that the efficiency of orthodontic tooth movement depends on adequate control of the forces delivered to the teeth and on how the alveolar bone responds to the mechanical stimuli generated by these forces, before considering the possibility of stimulating the alveolar bone through corticotomies, we must define what forces will be used and how unwanted reaction forces will be controlled. Managing the side effects of any orthodontic mechanics is often the most challenging aspect of treatment. Proper assessment of such side effects is therefore essential to improve efficiency. Moreover, it is undeniable that the introduction of temporary skeletal anchorage devices (TADs) represented a dramatic step forward in the control of complex orthodontic movements.

However, the use of mini-implants and mini-plates is not always possible, be it for anatomical or financial reasons. This may be the best window of opportunity for the use of alveolar corticotomies in orthodontics, i.e., when TADs cannot be used, or even when these devices can be combined with ACS. The clinical examples presented below illustrate these ACS indications.

### Intrusion of posterior teeth

In growing patients, upper molar intrusion due to restricted vertical growth of the maxillary alveolar process is quite feasible with the use of extraoral appliances, provided that patients are compliant. Moreover, the actual intrusion of supra-extruded molars in adult patients is one of the most challenging dental movements in orthodontics. Skeletal anchorage devices are the first choice for these cases. However, clinical situations are sometimes encountered in which the unique anatomical features of a given patient preclude the placement of mini-implants in an ideal site, where pure intrusive forces could be applied.<sup>16</sup> Furthermore, although mini-plates are a great alternative for tooth intrusion, many patients reject them owing to cost issues and the need for an additional surgery for their removal.<sup>20</sup> Under these conditions corticotomies can be viewed as an attractive alternative.

### Corticotomies combined with skeletal anchorage devices

A 37-year-old female patient wished to improve her chewing function, compromised by the early loss of teeth 36 and 37 and consequent

excessive extrusion of the teeth 26 and 27 (Fig 2). The patient turned down a suggestion to fix the problem prosthetically, which would involve root canal treatment, lengthening of clinical crowns and full crowns on the extruded teeth. After the patient had been informed of the advantages, disadvantages and risks involved in the orthodontic-prosthetic approach, encompassing intrusion of upper molars and lower implant-supported prostheses, this option was chosen.

Due to the proximity of the roots, the mini-implants could not be placed in a site that would be ideal for the delivery of direct intrusive forces. On the same day that the skeletal anchorage devices were installed, the left upper third molar was extracted and alveolar corticotomies were performed around the roots of the teeth to be intruded (Fig 3). One week after performance of the ACS, cast metal bars were attached to mini-implants placed in the mesial region of tooth 25 and in the distal region of tooth 27. Then, 150 g of intrusive forces were delivered using nickel-titanium springs tied to these bars. Approximately four months into treatment, the maxillary molars were re-leveled with the adjacent teeth and dental implants were installed in place of teeth 36 and 37 (Fig 4).

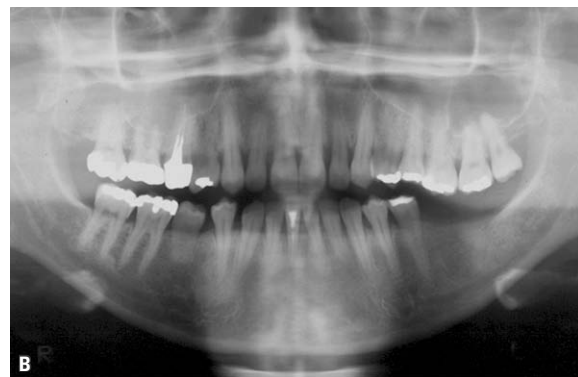
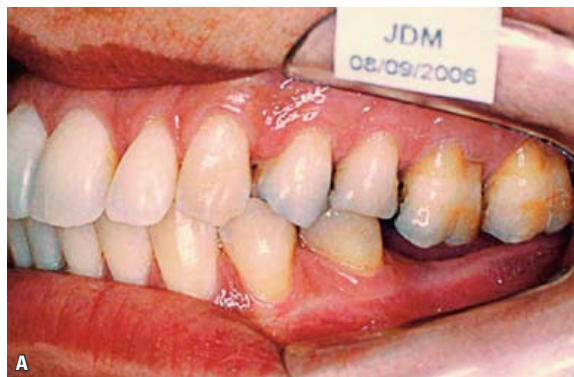
FIGURE 2 - Pre-orthodontic treatment images. **A)** Intraoral photograph showing severe extrusion of teeth 26 and 27. **B)** Panoramic radiograph disclosing an uneven upper occlusal plane and the presence of tooth 28.



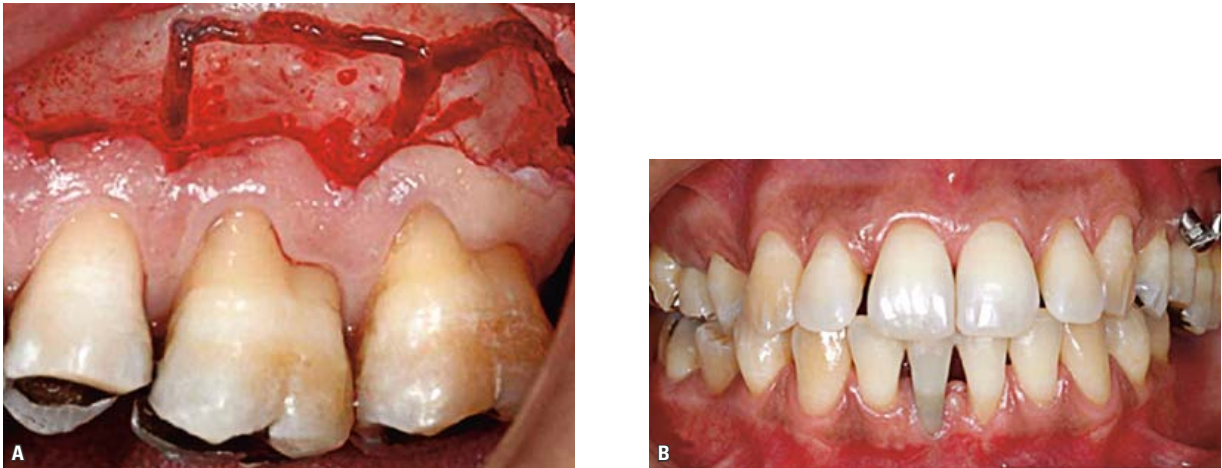


FIGURE 3 - Transoperative photographs. **A)** Corticotomies circumscribing the roots of the teeth to be intruded. **B)** Buccal mini-implants to support the cast metal bars.

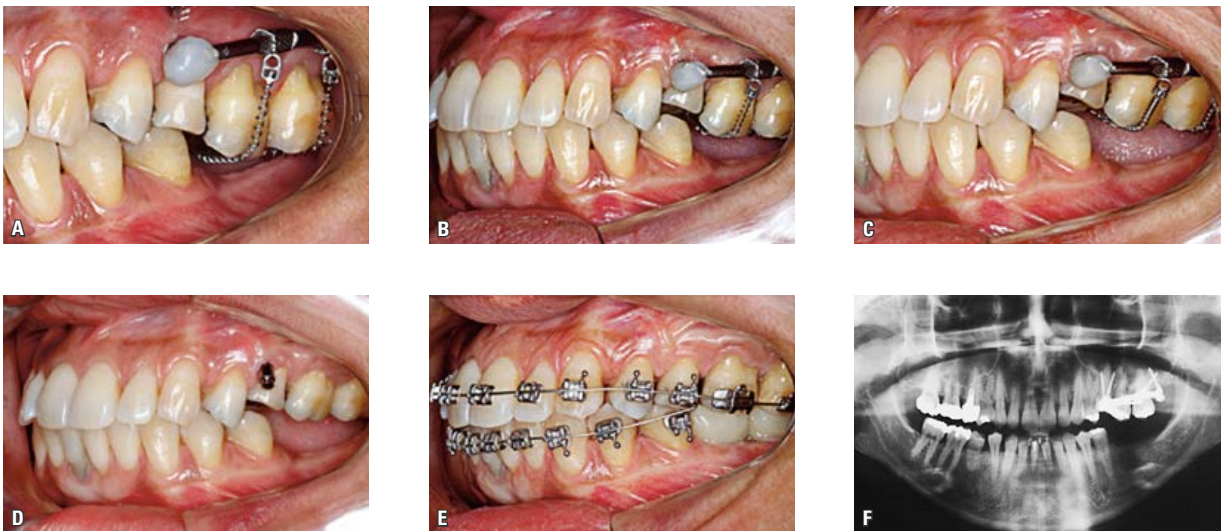


FIGURE 4 - Intrusion progress. **A)** Starting intrusive force application seven days post-corticotomies. **B)** Two months after the start of intrusion mechanics. **C)** Four months into treatment. **D)** Five months after performance of ACS, when the cast metal bars were removed. **E)** Patient with osseointegrated implant-supported provisional restorations replacing teeth 36 and 37, lost prematurely. **F)** Panoramic radiograph showing the levelling of the upper occlusal plane.

#### Corticotomies to enhance extraoral forces

Another female patient with impaired speech and mastication functions sought orthodontic treatment. She was 42 years old and had lost the mandibular premolars and second molars prematurely, which led to significant extrusion

of teeth 15, 16 and 17 (Fig 5). When she was referred to the Orthodontic Clinic at PUC Minas University, her name was on the waiting list for maxillofacial surgery, followed by subapical surgery and immediate intrusion of the bone block with her extruded teeth. She was interested in

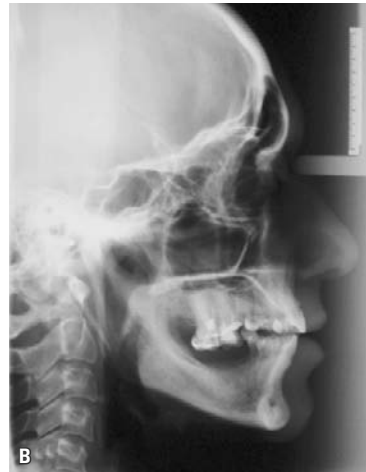
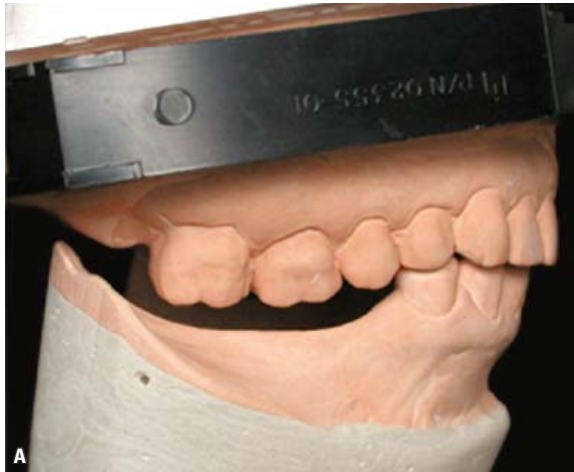
FIGURE 5 - Pretreatment images: **A)** Plaster models photograph showing severe extrusion of teeth 15, 16 and 17. **B)** Lateral cephalometric radiograph disclosing an uneven upper occlusal plane.

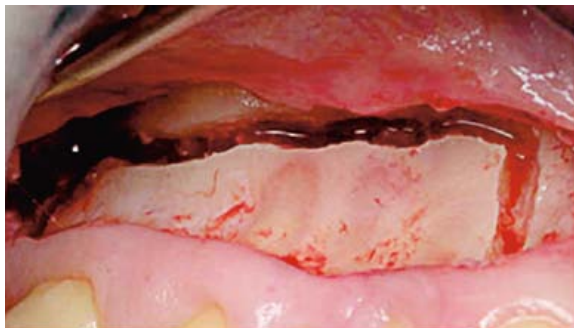


FIGURE 6 - Transoperative photograph illustrating alveolar corticotomies.

finding an alternative solution to her problem that would rule out the need for orthognathic surgery, which had been previously proposed.

The use of mini-plates or mini-implants was rejected by the patient for financial reasons. Aware of the difficulties entailed in intruding the molars of adults using extraoral forces and willing to comply with treatment, the patient opted for leveling of the upper occlusal plane with alveolar corticotomies to potentiate the effects of the headgear. One week after the ACS (Fig 6),

segmented orthodontic appliances were placed on the teeth to be intruded and intrusive forces began to be applied. In the fourth month of treatment, a lower partial removable denture was installed to add some occlusal force to the force system already in motion. Approximately seven months later the upper occlusal plane was leveled and osseointegrated implants had already been placed in the mandible (Fig 7).

#### Corticotomies and fixed orthodontic appliances

Although the intrusion approaches described above were successful, both had limitations. In the first case, mini-implants were needed and in the second, success would not have been achieved were it not for the patient's absolute compliance. Since we all know that finding patients who are willing to use headgear is increasingly difficult, especially among adults, the search for other alternatives that rely less on patient compliance is in order. The intrusion of extruded molars with fixed orthodontic appliances using straight archwires has always been regarded as inappropriate due to its extrusive effect on adjacent teeth.<sup>13,15,16</sup> Could it be that a decrease in alveolar bone density around alveolar

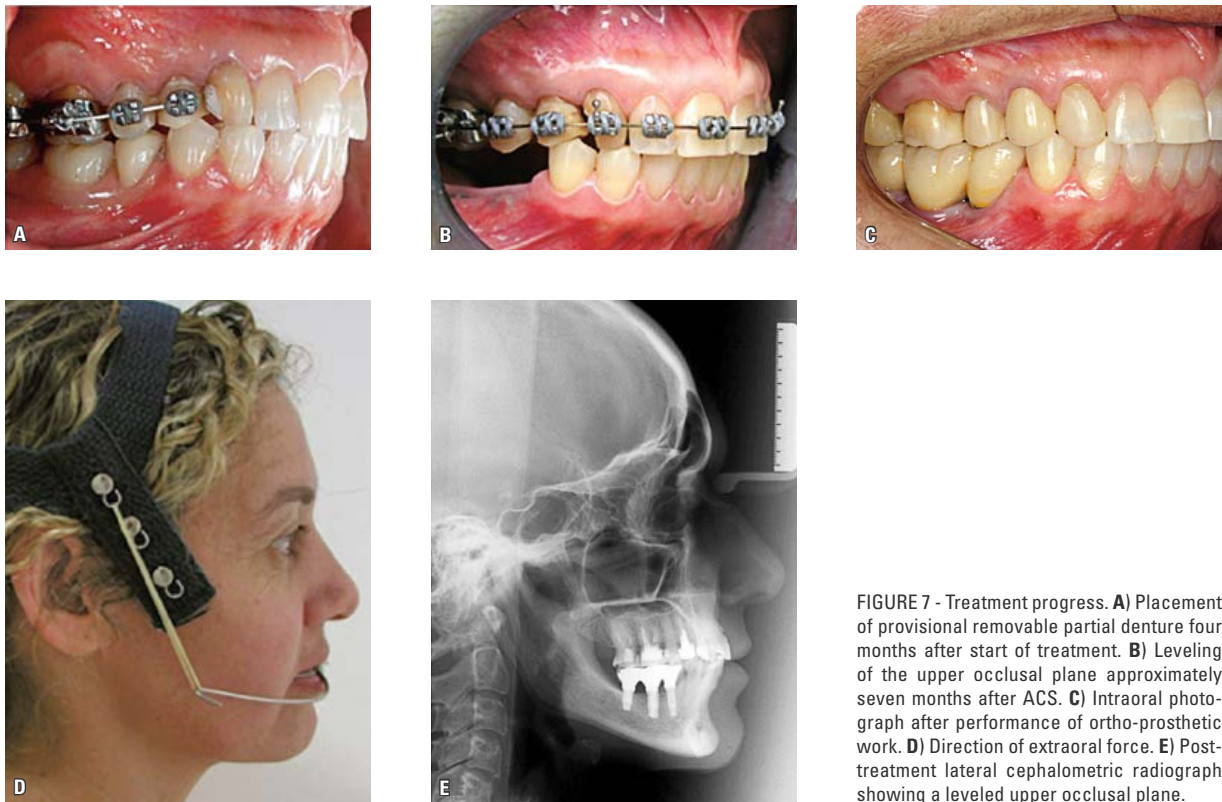


FIGURE 7 - Treatment progress. **A)** Placement of provisional removable partial denture four months after start of treatment. **B)** Leveling of the upper occlusal plane approximately seven months after ACS. **C)** Intraoral photograph after performance of ortho-prosthetic work. **D)** Direction of extraoral force. **E)** Post-treatment lateral cephalometric radiograph showing a leveled upper occlusal plane.

corticotomy sites would facilitate the intrusion of extruded teeth, thereby minimizing the extrusion of adjacent teeth used for anchorage? The case shown here suggests that this alternative might eventually deserve more attention.

A 21-year-old patient was referred for pre-prosthetic orthodontic evaluation. The prosthodontist was primarily concerned with an excessive extrusion of first molars, especially on the left side (Fig 8, A). Due to the patient's refusal to use skeletal anchorage devices, or even removable appliances specially designed for intrusion of upper molars, we suggested a combination of alveolar corticotomies and fixed orthodontic appliances with small but important adjustments to streamline the procedure. The patient was informed of all potential risks and signed a consent form authorizing the treatment.

Prior to the ACS, we prepared the upper arch orthodontically. After bonding the fixed appliances, the mechanical routine of alignment and leveling was conducted until archwire progress reached a 0.21 x 0.025-in stainless steel archwire, always bypassing the tooth to be intruded (Fig 8, B). We performed alveolar corticotomy around tooth 26 according to the protocol described above<sup>16</sup> (Fig 9). A week after the ACS, a 0.017 x 0.025-in nickel-titanium archwire segment was inserted into the auxiliary slots of the second premolar and second molar tubes. Five weeks after the onset of force application, the archwire segment was replaced by another superelastic archwire size 0.018 x 0.025-in, which remained in place until the end of the intrusion, 2.5 months later (Fig 8, C). Adequate intrusion was confirmed



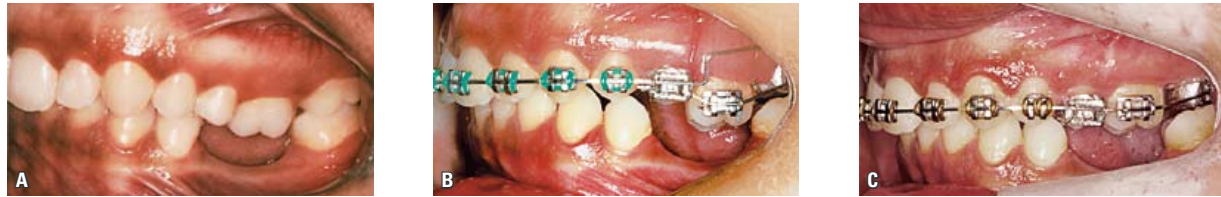

FIGURE 8 - Intraoral photographs illustrating the progress of the intrusion of tooth 16. **A)** Pretreatment. **B)** One week post-corticotomies and start of intrusive force application. **C)** Four months after ACS, leveling nearly complete.

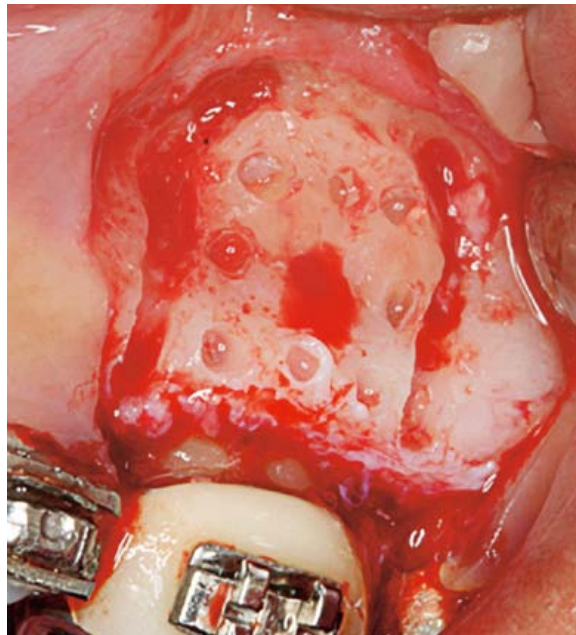


FIGURE 9 - Operative photograph showing corticotomies on the buccal surface of the tooth to be intruded.

both clinically and cephalometrically with no unwanted side effects on adjacent teeth.

Although the results demonstrate a successful treatment using this technique, they must be approached with caution. We should be aware that this posterior tooth intrusion method had not yet been reported in the literature. Souza<sup>21</sup> evaluated periodontal, orthodontic and endodontic parameters of molars intruded using the technique illustrated above. None of the periodontal measures worsened during treatment.

Intrusion was satisfactorily performed without relevant side effects and no significant changes were found in the pulps of the teeth. Detailed results of this study were sent for evaluation and publication in relevant scientific journals.

#### Enhancing the correction of skeletal malocclusions

This is a widely reported indication when discussing the potential indications of ACS. It is also an option that can help to decrease the invasiveness of this approach, for example, by replacing orthognathic surgery to correct anterior open bite. Originally reported by Chung et al,<sup>22</sup> this was the first corticotomy indication to be investigated in a clinical study. Akay et al<sup>15</sup> evaluated the efficiency of ACS associated with buccal miniplates and palatal mini-implants for correction of anterior open bite in patients aged between 15 and 25 years. The authors reported a mean decrease of 4.64 mm in overbite within approximately 12 weeks, concluding that corticotomies combined with skeletal anchorage would be a viable alternative in cases where patients reject orthognathic surgery for correction of anterior open bite. The case described below illustrates this indication for ACS without the aid of skeletal anchorage.

A 33-year-old female patient was referred for orthodontic treatment to improve both function and aesthetics. She presented with severe anterior open bite and early loss of first molars, making the ortho-surgical approach the treatment of choice (Fig 10). Repair using

orthognathic surgery was rejected for financial reasons and the alternative treatment plan was implemented. At first, this approach consisted of posterior alveolar corticotomies in the maxilla, palatal expander with occlusal coverage and oblique headgear (Fig 11). After the open bite

showed some improvement, fixed orthodontic appliances were installed to upright the lower mesio-inclined teeth and the right mandibular lateral incisor was extracted to adjust the anterior occlusal relationship. The patient's occlusal conditions were improved (Fig 12).

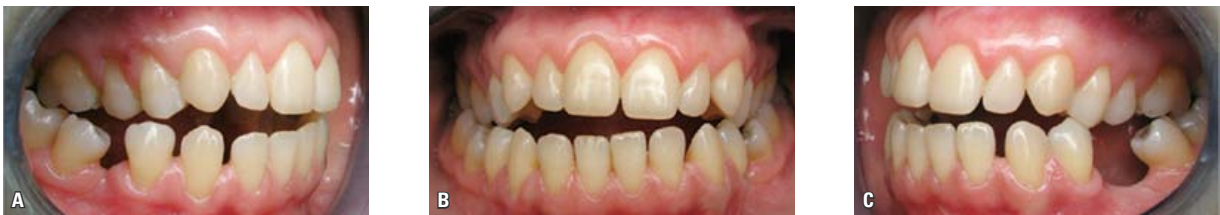

FIGURE 10 - Pretreatment intraoral photographs.

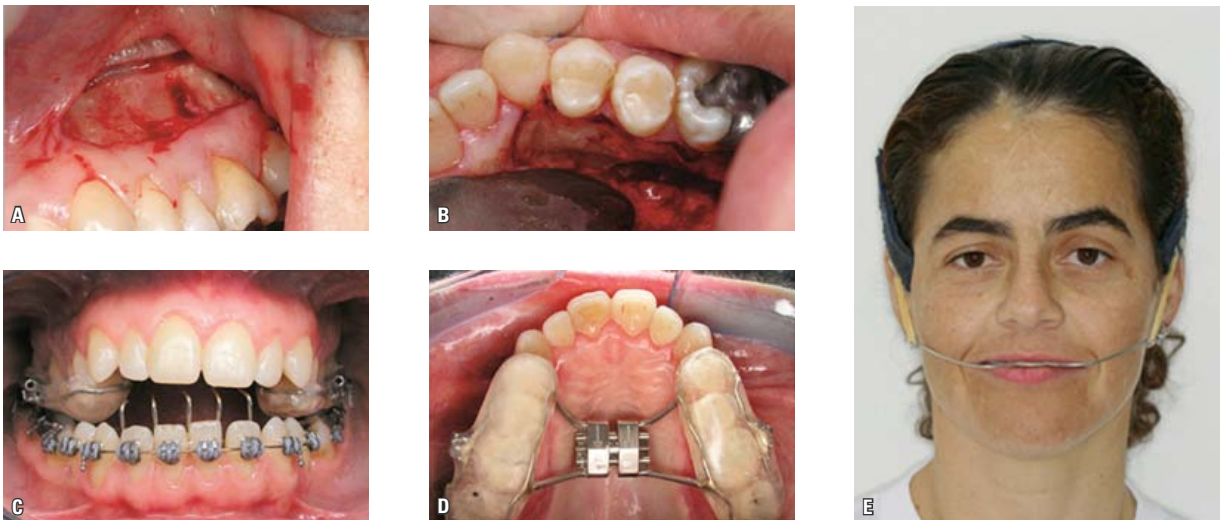


FIGURE 11 - Implementing combination of ACS and orthodontics. **A)** Buccal corticotomy. **B)** Palatal corticotomy. **C, D)** Placement of palatal expander with occlusal coverage and spurs. **E)** Extraoral forces.

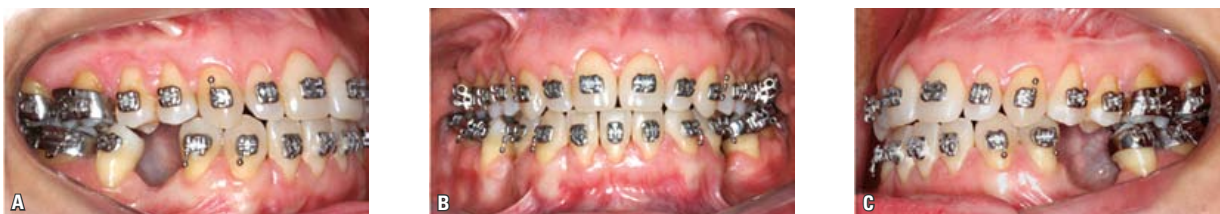

FIGURE 12 - Progress intraoral photographs showing open bite closure and finishing treatment stage.

## WHY DO ALVEOLAR CORTICOTOMIES ENHANCE ORTHODONTIC TREATMENT?

To be considered effective, orthodontic treatment must meet the goals established during planning within the shortest possible time without compromising the quality and stability of the results and, finally, preserving the long-term health of periodontal tissues. Optimal tooth movement requires the combination of well planned orthodontic forces<sup>23</sup> and an alveolar bone that offers less resistance to movement, i.e., less dense and with increased bone metabolism.<sup>24</sup> Different force systems geared to improving the various types of tooth movements have been described in the literature.<sup>25</sup> However, it is unclear how best to create a biological environment which facilitates effective orthodontic movement.

When alveolar bone metabolism is increased, orthodontic movement is accelerated.<sup>24</sup> Effective tooth movement enhancement has been demonstrated in laboratory studies with animals after the administration of certain drugs,<sup>26</sup> or by changing the optimal levels of hormones involved in regulating bone metabolism.<sup>27</sup> Such methods, however, are not yet available for clinical application in humans.

Since the first reports about the combination of corticotomies and orthodontic movement, it was believed that ACS delineated bone blocks which were linked together only by bone marrow, which would be more easily moved by the forces delivered by the orthodontic appliance.<sup>9</sup> It was suggested that due to the surgical cut, the greater resistance to tooth movement offered by the cortical bone would be reduced and, consequently, orthodontic movement would be increased.<sup>12</sup>

It was reported that the increased efficiency of orthodontic treatment was not due to greater ease in moving the blocks limited by bone corticotomies but rather by increased bone turnover in response to surgical trauma.<sup>4</sup> This

change in bone physiology would result in a localized decrease in trabecular bone density, which in turn, would offer less resistance to tooth movement.<sup>19</sup> Although providing satisfactory clinical results in reduced time periods, both studies afforded only indirect scientific explanations for these results.

In particular, the formulation of this latter theory to explain the effects of alveolar corticotomies was based on the physiological responses that occur during the bone healing process. After any trauma to bone tissue, remodeling, which is commonly found in the bone tissue structure, is greatly increased to accelerate the repair process and, consequently, functional recovery.<sup>28</sup> Soon after suffering structural damage, bone tissue goes through a biological stage called Regional Acceleratory Phenomenon, characterized by increased metabolism and decreased density, both transient and localized.

Recent animal studies have helped to broaden our understanding of what happens to the alveolar bone after an ACS. Oliveira<sup>3</sup> noted that in dogs both localized and transient alveolar bone density appeared to be lower. The largest decreases in bone density were recorded immediately, and 7 days, after surgery. Measurements taken 14 and 28 days post-surgery showed gradual recovery, albeit partial, of pre-operative bone density. When surgical trauma was limited to the cortical bone, it caused significant changes in the structure of the trabecular bone near the surgical site and a decrease in both volume and density. There was an increase in trabecular bone size, reduced connection between these structures and a decline in trabecular bone density. These results are consistent with the characteristics of the Regional Acceleratory Phenomenon observed in long bone healing and thus suggest that this phenomenon is also present in alveolar bone following the performance of ACS.

A second trial of the same study showed a

significant increase both in speed and amount of orthodontic movement, when it was performed in combination with localized alveolar corticotomies. The amount of mesial movement of the teeth used for anchorage was lower when alveolar corticotomies were performed around the tooth to be distalized. In another study on the effects of ACS in dogs, Mostafa et al<sup>7</sup> reported similar results. The amount of orthodontic movement was twice as large as had been achieved without the surgery. Histologically, bone remodeling was more active and extensive following corticotomies, which also suggests that the movement can be enhanced by an increase in bone metabolism resulting from the regional acceleratory phenomenon.

Lee et al<sup>29</sup> and Sebaoun et al<sup>30</sup> reported systemic and histological evidence supporting the theory that enhancement of tooth movement after ACS is due to an increase in the phenomenon of demineralization and remineralization observed in bone turnover. Results reported for rats showed a threefold increase in anabolic and catabolic processes up to 21 days after

performance of ACS, showing that the effects on trabecular bone were both intensive and extensive.<sup>30</sup> Finally, images obtained with a micro CT scanner confirmed that the alveolar bone adjacent to the ACS behaved quite differently from the bone located adjacent to areas that had undergone osteotomy.<sup>29</sup>

#### **WHAT ARE THE POSSIBLE CONTRAINDICATIONS AND LIMITATIONS OF USING ACS?**

Despite an increasing number of reports on the use of alveolar corticotomies as an aid to orthodontic treatment, few studies have reported setbacks when employing this combined treatment. Recently, however, Wilcko et al<sup>19</sup> gave an objective account of scenarios where the use of ACS-orthodontics should be avoided, i.e., (1) patients showing any sign of active periodontal disease, (2) individuals with inadequately treated endodontic problems, (3) patients making prolonged use of corticosteroids, (4) persons who are taking any medications that slow down bone metabolism, such as bisphosphonates and NSAIDs.



## CONCLUSIONS

Interest in the use of alveolar corticotomies as an adjunct to orthodontic treatment is growing thanks to a deeper understanding of its effects and more solid evidence-based research.

The biological stimulus generated by corticotomies is reflected in the structure of trabecular bone, which provides an opportunity to enhance certain orthodontic movements.

Although corticotomies are primarily indicated to shorten orthodontic treatment time, we believe that the more rational indications for ACS are for cases where either skeletal anchorage devices cannot be used, or both (ACS and

anchorage devices) can be used in combination.

As well as shedding more light on how to use ACS in orthodontics, further studies should encourage the search for new and exciting, and hopefully, less invasive procedures.

## ACKNOWLEDGEMENTS

We wish to thank Dr. Telma Martins de Araujo, Head Professor of Orthodontics at the Federal University of Bahia (UFBA) for the invitation and opportunity to publish these case reports.

We are also grateful to our colleague, Dr. Maria Lucia Haueisen, for her help in preparing some of the illustrations.

## REFERENCES

1. Wang L, Lee W, Lei DL, Liu YP, Yamashita DD, Yen SL. Tissue responses in corticotomy- and osteotomy-assisted tooth movements in rats: histology and immunostaining. Discussion. *Am J Orthod Dentofacial Orthop*. 2009 Dec;136(6):770-1.
2. Baloul SS. Mechanism of action and morphological changes in the alveolar bone in response to selective alveolar decortication facilitated tooth movement. [abstract]. In: 110<sup>th</sup> AAO Annual Session - Passion for Excellence; 2010 Apr 30 – May 4; Washington, DC: American Association of Orthodontists; 2010. p. 6. [cited 2010 June 12]. Available from: [http://www.aomembers.org/mtgs/upload/AS10\\_Book\\_Abstracts-I.pdf](http://www.aomembers.org/mtgs/upload/AS10_Book_Abstracts-I.pdf).
3. Oliveira DD. Efeitos da corticotomia alveolar na estrutura óssea e na movimentação ortodôntica. (tese) Rio de Janeiro (RJ): Universidade Federal do Rio de Janeiro; 2006.
4. Wilcko WM, Wilcko T, Bouquot JE, Ferguson DJ. Rapid orthodontics with alveolar reshaping: two case reports of decrowding. *Int J Periodontics Restorative Dent*. 2001 Feb;21(1):9-19.
5. Oliveira DD, Bolognese AM, Souza MMG. Corticotomias seletivas no osso alveolar para auxiliar a movimentação ortodôntica. *Rev Clin Ortod Dental Press*. 2007 jun-jul;6(3):66-72.
6. Kim SH, Kook YA, Jeong DM, Lee W, Chung KR, Nelson G. Clinical application of accelerated osteogenic orthodontics and partially osseointegrated mini-implants for minor tooth movement. *Am J Dentofacial Orthop*. 2009 Sep;136(9):431-9.
7. Mostafa YA, Mohamed Salah Fayed M, Mehanni S, ElBokle NN, Heider AM. Comparison of corticotomy-facilitated vs standard tooth-movement techniques in dogs with miniscrews as anchorage units. *Am J Orthod Dentofacial Orthop*. 2009 Oct;136(4):570-7.
8. Merrill RG, Pedersen GW. Interdental osteotomy for immediate repositioning of dental-osseous elements. *J Oral Surg*. 1976 Feb;34(2):118-25.
9. Köle H. Surgical operations on the alveolar ridge to correct occlusal abnormalities. *Oral Surg Oral Med Oral Path*. 1959 May;12(5):515-29.
10. Bell W, Levy B. Revascularization and bone healing after maxillary corticotomies. *J Oral Surg*. 1972 Sep;30(9):640-8.
11. Düker J. Experimental animal research into segmented alveolar movement after corticotomy. *J Maxillofac Surg*. 1975 Jun;3(2):81-4.
12. Generson RM, Porter JM, Zell A, Stratigos GT. Combined surgical and orthodontic management of anterior open bite using corticotomy. *J Oral Surg*. 1978 Mar;36(3):216-9.
13. Hwang H, Lee K. Intrusion of overerupted molars by corticotomy and magnets. *Am J Orthod Dentofacial Orthop*. 2001 Feb;120(2):209-16.
14. Lino S, Sakoda S, Miyawaki S. An adult bimaxillary protrusion treated with corticotomy-facilitated orthodontics and titanium miniplates. *Angle Orthod*. 2006 Nov;76(6):1074-82.
15. Akay MC, Aras A, Günbay T, Akyalçın S, Koyuncue BO. Enhanced effect of combined treatment with corticotomy and skeletal anchorage in open bite correction. *J Oral Maxillofac Surg*. 2009 Mar;67(3):563-9.

16. Oliveira DD, Oliveira BF, Araújo Brito HH, Souza MM, Medeiros PJ. Selective alveolar corticotomy to intrude overerupted molars. *Am J Orthod Dentofacial Orthop.* 2008 Jun;133(6):902-8.
17. Yen SLK, Yamashita DD, Kim TH, Baek HS, Gross J. Closure of an unusually large palatal fistula in a cleft patient by bony transport and corticotomy-assisted expansion. *J Oral Maxillofac Surg.* 2003 Nov;61(11):1346-50.
18. Krishnan V, Davidovitch A. Cellular, molecular, and tissue-level reactions to orthodontic force. *Am J Orthod Dentofacial Orthop.* 2006 Apr;129(4):469-75.
19. Wilcko MT, Wilcko MW, Pulver JJ, Bissada NF, Bouquot JE. Accelerated osteogenic orthodontics technique: a 1-stage surgically facilitated rapid orthodontic technique with alveolar augmentation. *J Oral Maxillofac Surg.* 2009 Oct;67(10):2149-59.
20. Faber J, Morum TFA, Leal S, Berto PM, Carvalho CKS. Miniplacas permitem tratamento eficiente e eficaz da mordida aberta anterior. *Rev Dental Press Ortod Ortop Facial.* 2008 set-out;13(5):144-57.
21. Souza MLAH. Corticotomia alveolar seletiva no mecanismo de intrusão dos primeiros molares superiores. Análise dos parâmetros clínicos e periodontais. [dissertação]. Belo Horizonte (MG): Pontifícia Universidade Católica de Minas Gerais; 2009.
22. Chung KR, Oh MY, Ko SJ. Corticotomy-assisted orthodontics. *J Clin Orthod.* 2001 May;35(5):331-9.
23. Melsen B, Agerbaek N, Markenstam G. Intrusion of incisors in adult patients with marginal bone loss. *Am J Orthod.* 1989 Sep;96(3):232-41.
24. Verna C, Dalstra M, Melsen B. The rate and type of orthodontic tooth movement is influenced by bone turnover in a rat model. *Eur J Orthod.* 2000 Aug;22(4):343-52.
25. Pilon JJ, Kuijpers-Jagtman AM, Maltha JC. Magnitude of orthodontic force and rate of bodily tooth movement, an experimental study in beagle dogs. *Am J Orthod Dentofacial Orthop.* 1995 Jul;107(1):16-23.
26. Hashimoto F, Kobayashi Y, Matak S, Kobayashi K, Kato Y, Sakai H. Administration of osteocalcin accelerates orthodontic tooth movement induced by a closed coil spring in rats. *Eur J Orthod.* 2001 Oct;23(5):535-45.
27. Yamashiro T, Takano-Yamamoto T. Influences of ovariectomy on experimental tooth movement in the rat. *J Dent Res.* 2001 Sep;80(9):1858-61.
28. Frost HM. The biology of fracture healing: An overview for clinicians. Part I. *Clin Orthop Rel Res.* 1989 Nov;248(11):283-93.
29. Lee W, Karapetyan G, Moats R, Yamashita DD, Moon HB, Ferguson DJ, et al. Corticotomy-osteotomy-assisted tooth movement microCTs differ. *J Dent Res.* 2008 Sep;87(9):861-7.
30. Sebaoun JD, Kantarci A, Turner JW, Carvalho RS, Van Dyke TE, Fergusson DJ. Modeling of trabecular bone and lamina dura following selective alveolar decortication in rats. *J Periodontol.* 2008 Sep;79(9):1679-88.

Submitted: May 2010  
Revised and accepted: June 2010

#### Contact address

Dauro Douglas Oliveira  
Programa de Mestrado em Odontologia – PUC Minas  
Av. Dom José Gaspar, 500 – Prédio 46 – Bairro Coração Eucarístico  
CEP: 30.535-610 – Belo Horizonte / MG  
Email: daurooliveira@hotmail.com