

# Skeletal displacements following mandibular advancement surgery: 3D quantitative assessment

Alexandre Trindade Simões da Motta\*, Felipe de Assis Ribeiro Carvalho\*\*, Lúcia Helena Soares Cevidanes\*\*\*, Marco Antonio de Oliveira Almeida\*\*\*\*

## Abstract

**Objective:** To evaluate changes in the position and remodeling of the mandibular rami, condyles and chin with mandibular advancement surgery through the superimposition of 3D Cone-Beam Computed Tomography (CBCT) models. **Methods:** This prospective observational study used pre-surgery and post-surgery CBCT scans of 27 subjects presenting skeletal Class II with normal or horizontal growth pattern. An automatic technique of cranial base superimposition was used to assess positional and/or remodeling changes in anatomic regions of interest. Displacements were visually displayed and quantified by 3D color maps. Descriptive statistics consisted of mean values, standard deviations and minimum/maximum displacements. Changes greater than 2 mm were considered clinically relevant, and a categorization was done. Positive and negative displacements showed each region directional tendency. To test if displacements in anatomic regions were associated with each other, Pearson correlation coefficients were used under a 95% significance level. **Results:** The chin moved anterior-inferiorly  $6.81 \pm 3.2$  mm on average and the inferior portion of the rami moved laterally (left:  $2.97 \pm 2.71$  mm; right:  $2.34 \pm 2.35$  mm). Other anatomic regions showed  $<2$  mm mean displacements, but with evident individual variability. Significant statistical correlations were positive and moderate. The condyles, posterior border and superior portion of the rami showed a bilateral correlation, and the superior and inferior portion of the rami an ipsilateral correlation. **Conclusion:** This 3D method allowed clear visualization and quantification of surgery outcomes, with an anterior-inferior chin displacement and a lateral movement on the inferior portion of the rami, but with considerable individual variability in all the evaluated anatomic regions.

**Keywords:** Cone-Beam Computed Tomography. Image processing, Computer-assisted. Surgery, computer-assisted. Computer simulation. Orthodontics. Surgery, oral.

\* PhD, MSc and Specialist in Orthodontics (UERJ). PhD Scholarship CAPES 382705-4 at University of North Carolina at Chapel Hill (UNC). Professor, Department of Orthodontics, Fluminense Federal University (UFF), Niterói, Brazil.

\*\* MSc and Specialist in Orthodontics (UERJ). Specialist in Oral Radiology (ABORJ). PhD student in Orthodontics (UERJ) and Visiting Scholar (UNC).

\*\*\* PhD in Oral Biology (UNC). Assistant Professor, Department of Orthodontics, University of North Carolina at Chapel Hill.

\*\*\*\* Post-doctorate in Orthodontics (UNC). Head Professor, Department of Orthodontics, State University of Rio de Janeiro, Brazil.

## INTRODUCTION

Bilateral sagittal split ramus osteotomy (BSSO) is frequently performed in cases of mandibular advancement surgery. Despite its popularity, post-surgical instability due to displacement of the condyle from its seated position in the glenoid fossa in the three planes of space (ie, sagittal, vertical, and transverse) remains an area of concern.<sup>1</sup>

A post-surgical superior and posterior displacement of the condyle can happen with surgery, and it has been described to be correlated to the amount of mandibular advancement.<sup>2-5</sup> The association of condylar displacement and treatment relapse has been described,<sup>5,6</sup> and the control of the proximal segment was considered to be the most important aspect in the stability of this surgical modality.<sup>7</sup>

Assessment of surgical treatment outcomes using Cone-Beam Computed Tomography (CBCT) has the potential to unravel the interactions between the dental, skeletal and soft tissue components that contribute to treatment response.<sup>8</sup> The use of 3-dimensional (3D) superimposition tools allows the identification and quantification of bone displacement and remodeling.<sup>9,10</sup>

Previous studies<sup>9,11-14</sup> have used the 3D virtual models superimposition technique to assess post-surgical outcomes and stability in Class III patients, but the post-surgical outcomes of Class II correction have not been evaluated by this method.

The purpose of the present study was to tri-dimensionally assess surgical displacements of the condyles, rami (superior, inferior and posterior) and chin after mandibular advancement, testing directional correlation between them.

## METHODS

For this prospective observational study, twenty-seven patients (9 males and 18 females; mean age 30.04±13.08 years) who were submitted to orthognathic surgery at the UNC Memorial Hospital, with an attending resident from the

Department of Oral and Maxillofacial Surgery, were recruited. All patients underwent orthodontic treatment and had mandibular advancement surgery by means of a bilateral sagittal split osteotomy (BSSO). Nine of them also had genioplasty as an adjunctive procedure. CBCT scans were taken before surgery and after surgery at splint removal with the NewTom 3G (Aperio Services LLC, Sarasota, FL, 34236). Two of those patients had at least 1 scan done with the NewTom 9000 (Aperio Services LLC, Sarasota, FL) which has a smaller field of view (FOV), therefore, the chin was not included.

All patients had skeletal discrepancies severe enough to justify an orthognathic surgery. Patients with anterior open bite were excluded, so that the entire sample presented a skeletal Class II with normal or horizontal growth pattern. Lip-palatal fissures, problems resulting from trauma or degenerative conditions like rheumatoid arthritis were also excluded. Informed consent was obtained from all subjects. All patients agreed in having CBCTs in different phases of treatment as it was described in the experimental protocol approved by UNC ethical committee.

The imaging protocol involved a 36-second head CBCT scanning with a field of view of 230 x 230 mm. All CT scans were acquired with the patient in centric occlusion. The 3D models were constructed from CBCT images with a voxel dimension of 0.5x0.5x0.5 mm. Image segmentation of the anatomic structures of interest and the 3D graphic rendering were done by using the ITK-SNAP<sup>15</sup> open-source software (<http://www.itk-snap.org/>). Virtual models corresponding to the cranial bases (Fig 1); condyles (right and left); posterior rami (right and left); superior rami (right and left); inferior rami (right and left) and chin were built (Fig 2).

The pre-surgery and post-surgery models were registered based on the cranial base, since this structure is not altered by surgery. A fully automated voxel-wise rigid registration method was

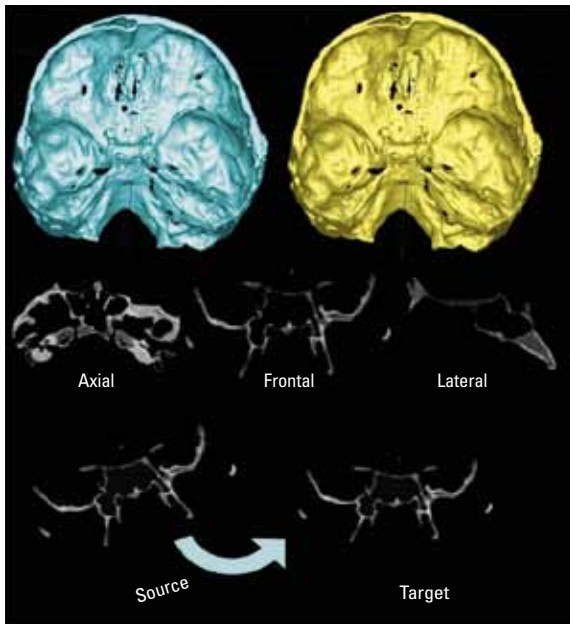


FIGURE 1 - Registration of CBCTs generated 3D virtual models using the cranial base surface through a fully automated voxel-wise method. Pre-surgery cranial base was used as a reference (source) for the post-surgery one (target) which were relocated along with the virtual maxillary and mandibular models.




FIGURE 2 - Anatomic regions of interest: (1) Right condyle; (2) Left condyle; (3) Right posterior ramus; (4) Left posterior ramus (5) Right superior ramus; (6) Left superior ramus; (7) Right inferior ramus; (8) Left inferior ramus and (9) Chin.

used through the IMAGINE free software (developed by NIH and modified at UNC, <http://www.ia.unc.edu/dev/download/imagen/index.htm>).<sup>9</sup> The software compares both images using the intensity of gray scale for each voxel of the region, so that the pre-surgical cranial base was used as reference for the superimposition of post-surgery models (Fig 1).

Following the registration step, all the re-oriented virtual models, originally saved in a .GIPL format were converted to a SGL open inven-

tor format (IV) by the free software VOL2SURF (<http://www.cc.nih.gov/cip/software.html>), allowing the quantitative evaluation of greatest displacements using the CMF application software (Maurice Müller Institute, Bern, Switzerland).<sup>16</sup>

The previously proposed color maps method<sup>17</sup> was used to generate the closest-point distances between the surfaces. The CMF software calculates thousands of color-coded surface distances in millimeters between before and after-treatment 3D models by using surface triangles at two different time points, so that the difference between the two surfaces at any location can be quantified. The isoline (contour line) tool was recently included in the method and considered a technique improvement, since it is used to quantitatively measure the greatest displacement (mm) for the specific anatomic regions of interest (Fig 3).

The quantitative changes were visualized using color maps, which can be used to indicate inward (blue) or outward (red) displacement between superimposed structures. An absence of change is indicated by the green color code. For example, in mandibular advancement surgery, the forward chin displacement would be shown in a red color code; in mandibular set-back surgery the chin surfaces would be shown in a blue color code.

Semi-transparency constitutes another method used in this study for visualization of the location and direction of skeletal displacements, with one of the models in an opaque view superimposed to another in a partially transparent view. This method for quantitative change exhibition at multiple locations has been validated and used since 2005.<sup>9</sup>

Positive values indicated an anterior-inferior displacement of the chin while negative values indicated a posterior-superior displacement. For the condyles, positive values represented a posterior-superior displacement and negative values indicated anterior-inferior movements. For the rami posterior borders, positive values represented posterior displacements and negative values indicated anterior displacements.

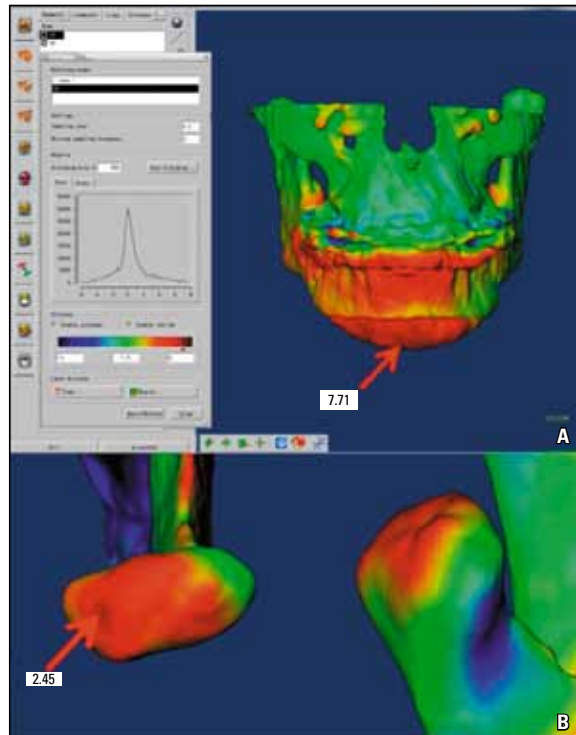


FIGURE 3 - The ISOLINE tool allowed the identification of the greatest displacement of a specific anatomic region. **A)** Example of a 7.71 mm chin advancement between pre-surgery and after splint removal (surgical outcomes). **B)** Right condyle displaced 2.45 mm posterior-superiorly after surgery.

The lateral portions of the mandibular rami were divided in two parts (superior and inferior) aiming to identify the complex torque or medial/lateral movement of this region. This way, positive values represented a lateral displacement of the rami, and negative values showed a medial displacement. When both portions of the ramus showed displacements in opposite directions, it indicated a torque movement of this anatomic region.

To assess surgical outcomes, the largest displacements between pre-surgery/post-surgery (splint-removal) were computed for all anatomic regions of interest.

To check the reproducibility of greatest displacements' measurements done by the isolines, 10 randomly selected superimpositions were measured twice, at a 2-week interval and

compared through intraclass correlation coefficient ( $P < 0.001$ ). The agreement between the measurements was high for all anatomic regions: chin ( $r=0.98$ ); condyles ( $r=0.92$ ); posterior borders ( $r=0.97$ ); superior rami ( $r=0.97$ ) and inferior rami ( $r=0.95$ ).

Descriptive statistics consisting of mean values, standard deviations and minimum/maximum displacements were done. Since changes greater than 2 mm can be considered clinically relevant, a categorization shows the number of patients that had displacements greater than 2 mm, between 2 mm and -2 mm and smaller than -2 mm, along with the mean values, standard deviations, and minimum and maximum values for each group. Descriptive statistics was divided in positive and negative displacements according to each region directional tendency.

To test if displacements in anatomic regions were associated with each other, i.e., if changes at the condyles and/or ramus were associated with changes at the chin, the Pearson correlation coefficients were used under 95% significance level.

## RESULTS

Mean displacements of all the evaluated anatomic regions showed that the chin and the inferior portion of the rami presented changes greater than 2 mm, which are considered clinically relevant. The chin moved anterior-inferiorly  $6.81 \pm 3.2$  mm on average and the inferior portion of the rami moved laterally  $2.97 \pm 2.71$  mm on the left side and  $2.34 \pm 2.35$  mm on the right side (Table 1 and Fig 4).

All the other anatomic regions showed mean displacements smaller than 2 mm, but the individual variability was evident, with the maximum displacements ranging outside the 2 mm limit (Table 1 and Fig 5).

Condylar maximum displacements, for example, ranged between -3.7 mm and +3.2 mm. Figure 6 shows a patient who underwent a condyle displacement of +3.2 mm.

Considering changes greater than 2 mm as being clinically relevant, it is possible to quantify the number of anatomic regions that displaced significantly. As one should expect, the chin had a displacement greater than 2 mm with surgery in all the patients (n=25). Looking at the posterior border of the rami (right and left, n=54), 8 had displacements smaller than -2 mm and 6 greater than 2 mm. For the condyles (right and left, n=54) 2 showed displacements smaller than -2 mm and 11 greater than 2 mm (Table 2).

The superior portion of the rami (right and left, n=54) underwent displacements smaller than -2 mm in 3 patients and greater than 2 mm in 15. After the chin, the inferior portion of the rami was the region with the most relevant changes, showing displacements smaller than -2 mm in 3 cases and greater than 2 mm in 35 (right and left, n=54) (Table 2).

Correlations of displacements between the evaluated anatomic regions by means of a Pearson correlation coefficient showed that all the significant statistical correlations were positive and moderate (Table 3). The chin anterior displacement was correlated with the lateral movement of the superior portion of the right ramus ( $r=0.46, p=0.02$ ).

TABLE 1 - Descriptive statistics of surgical displacements.

Region	Pre-surgery /Post-surgery			
	Number of patients	Mean (mm)	SD (mm)	Min / Max (mm)
Chin	25	6.81	3.20	2.5/15.8
Posterior ramus (left)	27	0.08	2.32	-3.2/6.1
Posterior ramus(right)	27	-0.09	1.84	-2.8/4.1
Condyle (left)	27	0.98	1.46	-3.7/3.2
Condyle (right)	27	0.81	1.40	-2.4/2.9
Superior ramus (right)	27	0.62	1.94	-2.9/3.5
Inferior ramus (right)	27	2.34	2.35	-3.0/5.8
Superior ramus (left)	27	1.57	1.92	-1.9/5.7
Inferior ramus (left)	27	2.97	2.71	-2.5/7.0

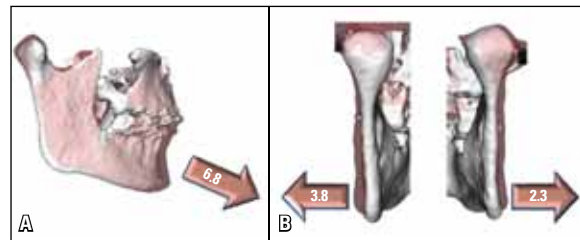


FIGURE 4 - A) Semi-transparent visualization showing a 6.8 mm mean mandibular advancement measured at the chin. B) Proximal segment lateral displacement after mandibular advancement surgery. The sagittal osteotomy probably acted like a wedge and the condyles as a fulcrum, causing the inferior rami to be the anatomic region with the greatest mean displacement after the chin.

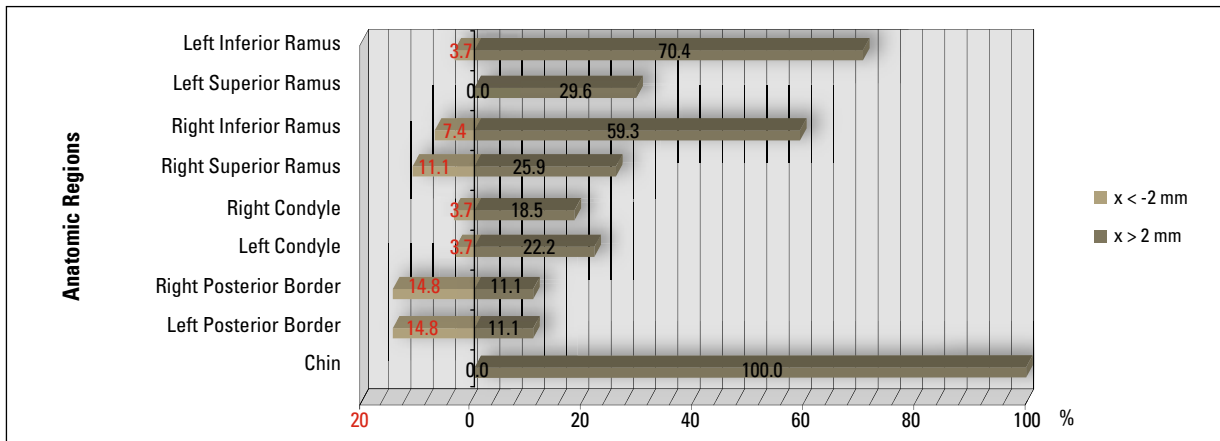


FIGURE 5 - Clinically relevant displacements for each anatomic region. Percentage of patients with changes > 2 mm and < -2 mm.

TABLE 2 - Descriptive statistics of surgical displacements: number of patients showing displacements greater than 2 mm, between 2 mm and -2mm and smaller than -2 mm, along with the mean values, standard deviations, and minimum/maximum values for each group.

PRE-SURGERY / SPLINT REMOVAL					
Chin (n=25)					
	N	Mean	SD	Min	Max
$x < -2$	0	-	-	-	-
$-2 \leq x \leq 2$	0	-	-	-	-
$x > 2$	25	6.81	3.20	2.50	15.80
Left Posterior Border (n=27)					
	N	Mean	SD	Min	Max
$x < -2$	4	-3.00	0.22	-3.20	-2.70
$-2 \leq x \leq 2$	20	-0.05	1.15	-2.00	1.60
$x > 2$	3	5.03	1.29	3.60	6.10
Right Posterior Border (n=27)					
	N	Mean	SD	Min	Max
$x < -2$	4	-2.40	0.32	-2.80	-2.10
$-2 \leq x \leq 2$	20	-0.13	1.27	-2.00	1.40
$x > 2$	3	3.23	1.03	2.10	4.10
Left Condyle (n=27)					
	N	Mean	SD	Min	Max
$x < -2$	1	-3.70	-	-3.70	-3.70
$-2 \leq x \leq 2$	20	0.78	1.00	-1.40	1.90
$x > 2$	6	2.45	0.40	2.10	3.20
Right Condyle (n=27)					
	N	Mean	SD	Min	Max
$x < -2$	1	-2.40	-	-2.40	-2.40
$-2 \leq x \leq 2$	21	0.56	1.10	-1.80	1.80
$x > 2$	5	2.50	0.26	2.20	2.90
Right Superior Ramus (n=27)					
	N	Mean	SD	Min	Max
$x < -2$	3	-2.57	0.31	-2.90	-2.30
$-2 \leq x \leq 2$	17	0.26	1.35	-1.90	2.00
$x > 2$	7	2.86	0.34	2.60	3.50
Right Inferior Ramus (n=27)					
	N	Mean	SD	Min	Max
$x < -2$	2	-2.65	0.49	-3.00	-2.30
$-2 \leq x \leq 2$	9	0.70	1.38	-1.80	2.00
$x > 2$	16	3.89	1.01	2.60	5.80
Left Superior Ramus (n=27)					
	N	Mean	SD	Min	Max
$x < -2$	0	-	-	-	-
$-2 \leq x \leq 2$	19	0.65	1.40	-1.90	2.00
$x > 2$	8	3.76	0.97	3.00	5.70
Left Inferior Ramus (n=27)					
	N	Mean	SD	Min	Max
$x < -2$	1	-2.50	-	-2.50	-2.50
$-2 \leq x \leq 2$	7	-0.30	1.44	-1.30	1.90
$x > 2$	19	4.46	1.33	2.30	7.00

The posterior movement of the left and right ramus posterior border showed correlation ( $r=0.69$ ,  $p<0.0001$ ). The posterior movement of the left ramus posterior border also correlated to the superior portion of the ramus on the same side ( $r=0.42$ ,  $p<0.03$ ).

Posterior-superior displacements of the condyles were correlated between left and right

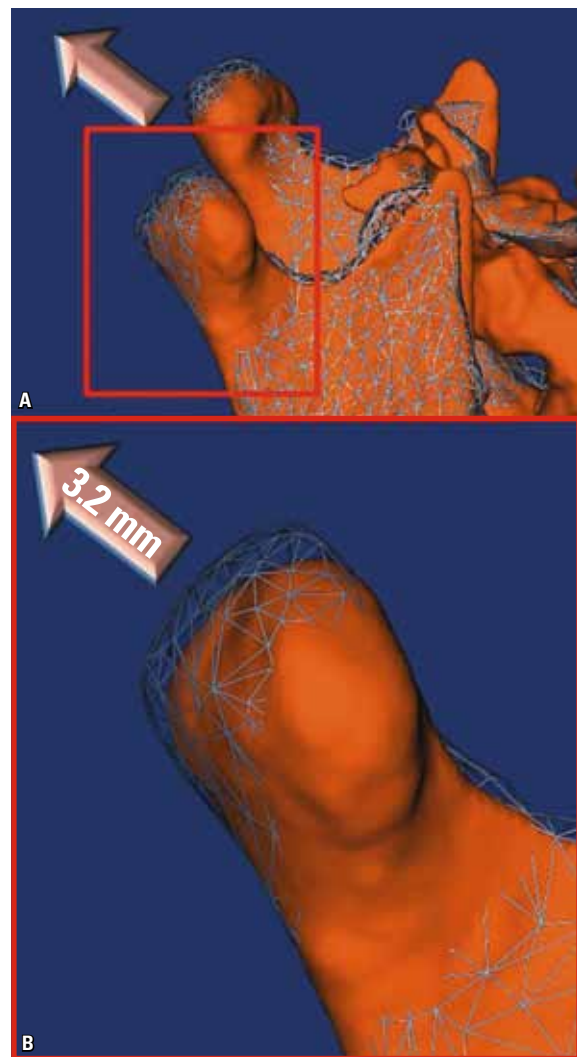


FIGURE 6 - **A)** Mesh-transparencies visualization showing a condyle displacement of 3.2 mm after surgery. **B)** Close-up view of the displaced condyle.

TABLE 3 - Pearson correlation coefficients for the surgical displacements between all anatomical regions. The upper right part of the table shows r values and the lower part p values. Statistically significant values are in bold.

	Chin	Left Post. Border	Right Post. Border	Left Condyle	Right Condyle	Right Sup. Ramus	Right Inf. Ramus	Left Sup. Ramus	Left Inf. Ramus
Chin		-0.26	-0.18	-0.34	-0.28	<b>0.46</b>	0.22	0.08	0.09
Left Post. Border	0.21		<b>0.69</b>	-0.06	-0.07	-0.05	0.12	<b>0.42</b>	0.22
Right Post. Border	0.40	<b>&lt;.0001</b>		-0.14	0.18	-0.12	0.06	0.12	0.24
Left Condyle	0.10	0.75	0.49		<b>0.66</b>	-0.33	-0.14	-0.21	-0.31
Right Condyle	0.17	0.73	0.37	<b>0.00</b>		-0.22	0.04	-0.30	-0.21
Right Sup. Ramus	<b>0.02</b>	0.79	0.56	0.10	0.28		<b>0.58</b>	<b>0.46</b>	0.09
Right Inf. Ramus	0.30	0.56	0.76	0.49	0.86	<b>0.00</b>		0.21	-0.18
Left Sup. Ramus	0.71	<b>0.03</b>	0.56	0.30	0.14	<b>0.01</b>	0.30		<b>0.66</b>
Left Inf. Ramus	0.67	0.27	0.24	0.11	0.28	0.65	0.36	<b>0.00</b>	

( $r=0.66$ ,  $p=0.0002$ ). The superior portions of the rami were also correlated between sides ( $r=0.46$ ,  $p=0.0148$ ).

On both sides, the superior and inferior portion of the ramus were correlated, showing a lateral movement tendency (right:  $r=0.58$ ,  $p=0.0016$ ; left:  $r=0.66$ ,  $p=0.0002$ ).

## DISCUSSION

In conventional cephalometrics, the cranial base often is used for superimpositions because it shows minimal changes after neural growth is completed. In 3D image analysis, registration can be based on choice of stable surfaces or landmarks. While landmark location in 2D is hampered by identification of hard and soft tissues on x-rays due to the superimposition of multiple structures, locating 3D landmarks on complex curving structures is significantly more difficult.<sup>19</sup> There are no suitable operational definitions for craniofacial landmarks in the three

planes of space (coronal, sagittal, and axial). In the context of facial changes, superimposition should not rely on landmark identification nor on best-fit techniques on structures that may have changed between image acquisitions.<sup>18</sup>

The major strength of the superimposition method used in this study is that registration does not depend on the precision of the 3D surface models. The cranial base models are only used to mask anatomic structures that do not change with growth and treatment. The registration procedure actually compares voxel by voxel of gray level CBCTs images, containing only the cranial base, and calculates the rotation and translation parameters between the two time-point images.

Regional superimposition in the cranial base does not completely define the movement of the mandible relative to the maxilla<sup>9,10,20-23</sup>. Previous studies<sup>20,22,24-26</sup> revealed that relative displacement of mandibular and maxillary skeletal and

dental components is critical because the resulting information may differ from conclusions formulated from the cranial base superimposition.

Although a 3D superimposition study presents additional information when compared to traditional cephalometric methods, analysis of the 3D morphology poses methodological challenges. Current methods, including methods used in commercially available software (Geomagic Studio, Geomagic U.S. Corp, Research Triangle Park, NC, 27709 and Vultus, 3dMD, Atlanta, GA, 30339), calculate the closest point between two surfaces. However, the closest point is not necessarily the corresponding point in both surfaces.

The quantification utilizing isolines in this study determined the absolute maximum change in the anatomic region, where positive or negative values based on operator observation aided the assessment of the direction of displacement. For example, positive values at the chin indicate an anterior-inferior displacement, but it's not possible to distinguish how anterior and how inferior the displacement is. A method that quantifies vectorial displacements is being developed at UNC, which will be able to analyze shape correspondence between two structures, and in the future will improve directional evaluation. Another issue is that differences between the surfaces are not only a result of displacement as this method suggests, there may occur a remodeling process too.

It has been advocated in the literature<sup>27</sup> that a precise repositioning of the condyles during surgery would ensure stability of the surgical results and reduce temporomandibular joint noxious effects. It might improve postoperative masticatory function, but the extent of condylar change that is compatible with normal function post-surgically is still unknown. In this study, mild mean condylar displacements with surgery (left  $0.98 \pm 1.46$  mm and right  $0.81 \pm 1.40$  mm) were observed, but some patients experienced an important condylar displacement up to 3.7 mm anterior-inferiorly and 3.2 mm posterior-superiorly.

The use of devices for preserving the preoperative position of the mandibular condyle during bilateral sagittal split osteotomy has been proposed, but it was concluded that there is no scientific evidence to support its routine use in orthognathic surgery, which makes the condylar positioning a critical procedure to be handled.<sup>28</sup>

With the increased use of rigid fixation, there has been a decrease in the amount of relapse but an increase in the amount of force transmitted to the condyles. Gradual advancement of the mandible by distraction osteogenesis slowly overcomes the soft-tissue envelope and may decrease the amount of force exerted on the condyles. Using an animal model to measure the magnitude of pressure associated with immediate versus gradual mandibular advancement, it was found that the superior joint space fluid pressures increased and remained elevated over a 5-week period after immediate advancement, contrasting with the results of gradually advancement of the mandible where the pressures were elevated but returned to near baseline prior to the activation the following day. Based on these findings, the authors could conclude that it is likely that gradual advancement of the mandible by distraction osteogenesis produces less force and causes less condylar resorption than large mandibular advancement stabilized with rigid fixation, but further studies are needed to compare methods for mandibular advancement.<sup>29</sup>

This study found that the inferior portion of the rami was the region with the most relevant displacements after the chin, showing displacements smaller than -2 mm in just 3 rami of a total of 54 and greater than 2 mm in 35 (right and left). The average lateral displacement was  $2.97 \pm 2.71$  mm on the left side and  $2.34 \pm 2.35$  mm on the right side. These results agree with another study<sup>1</sup> that found an increased transverse intergonion distance with a mean of 5.0 mm in 44 of 45 patients after



BSSO using miniplates for fixation. The sum of mean displacements for right and left sides of the inferior portion of the rami was 5.28 mm in the present study, very close to the results of the study cited above<sup>1</sup> even with the different measurement methods.

Besides the chin and the inferior portion of the rami, all the other anatomic regions showed mean displacements smaller than 2 mm, but with the maximum displacements ranging beyond the clinical acceptable limit. Relevant displacements of distal and proximal mandibular segments and surgically induced posterior condylar displacement seem to be important surgical risk factors for postoperative condylar resorption. Although these displacements are hard to predict during surgery, it might be an area of concern especially for those patients who are at a high risk of condylar resorption.<sup>30</sup>

## CONCLUSIONS

Superimposition of 3-dimensional (3D) virtual surface models allowed clear visualization and quantification of outcomes of mandibular advancement surgery.

On average, mandibular advancement surgery resulted in clinically significant (greater than 2 mm) anterior-inferior chin displacement as well as lateral movement on the inferior portion of the rami. On the other hand, a considerable individual variability was observed for all the evaluated anatomic regions, with changes ranging beyond the clinically acceptable limit.

Bilateral changes were significantly correlated for condyles, posterior border and superior portion of the rami, and ipsilateral displacements correlation occurred between superior and inferior portion of the rami, showing a lateral movement tendency.

## REFERENCES

- Becktor JP, Rebellato J, Sollenius O, Vedtofte P, Isaksson S. Transverse displacement of the proximal segment after bilateral sagittal osteotomy: a comparison of lag screw fixation versus miniplates with monocortical screw technique. *J Oral Maxillofac Surg.* 2008 Jan;66(1):104-11.
- Rebellato J, Lindauer SJ, Sheats RD, Isaacson RJ. Condylar positional changes after mandibular advancement surgery with rigid internal fixation. *Am J Orthod Dentofacial Orthop.* 1999 Jul;116(1):93-100.
- Van Sickels JE, Larsen AJ, Thrash WJ. Relapse after rigid fixation of mandibular advancement. *J Oral Maxillofac Surg.* 1986 Sep;44(9):698-702.
- Alder ME, Deahl ST, Matteson SR, Van Sickels JE, Tiner BD, Rugh JD. Short-term changes of condylar position after sagittal split osteotomy for mandibular advancement. *Oral Surg Oral Med Oral Pathol Oral Radiol Endod.* 1999 Feb;87(2):159-65.
- Gassmann CJ, Van Sickels JE, Thrash WJ. Causes, location, and timing of relapse following rigid fixation after mandibular advancement. *J Oral Maxillofac Surg.* 1990 May;48(5):450-4.
- Van Sickels JE, Larsen AJ, Thrash WJ. A retrospective study of relapse in rigidly fixated sagittal split osteotomies: contributing factors. *Am J Orthod Dentofacial Orthop.* 1988 May;93(5):413-8.
- Schendel SA, Epker BN. Results after mandibular advancement surgery: an analysis of 87 cases. *J Oral Surg.* 1980 Apr;38(4):265-82.
- Bastir M, Rosas A, O'Higgins P. Craniofacial levels and the morphological maturation of the human skull. *J Anat.* 2006 Nov;209(5):637-54.
- Cevidanes LH, Bailey LJ, Tucker GR Jr, Styner MA, Mol A, Phillips CL, et al. Superimposition of 3D cone-beam CT models of orthognathic surgery patients. *Dentomaxillofac Radiol.* 2005 Nov;34(6):369-75.
- Cevidanes LH, Franco AA, Gerig G, Proffit WR, Slice DE, Enlow DH, et al. Assessment of mandibular growth and response to orthopedic treatment with 3-dimensional magnetic resonance images. *Am J Orthod Dentofacial Orthop.* 2005 Jul;128(1):16-26.
- Cevidanes LH, Bailey LJ, Tucker SF, Styner MA, Mol A, Phillips CL, et al. Three-dimensional cone-beam computed tomography for assessment of mandibular changes after orthognathic surgery. *Am J Orthod Dentofacial Orthop.* 2007 Jan;131(1):44-50.
- Cevidanes LH, Oliveira A, Phillips C, Motta AT, Styner M, Tyndall D. Three dimensional short-term mandibular displacements following class III surgery. *J Dent Res.* 2007;(Spec Iss A):1827.
- Grauer D, Cevidanes LHS, Phillips C, Mol A, Styner M, Proffit W. Assessment of maxillary surgery outcomes one year post-surgery. *J Dent Res.* 2006;(Spec Iss A):0813.
- Lee B, Cevidanes LHS, Phillips C, Mol A, Styner M, Proffit W. 3D assessment of mandibular changes one year after orthognathic surgery. *J Dent Res.* 2006;(Spec Iss A):1610.
- Yushkevich PA, Piven J, Hazlett HC, Smith RG, Ho S, Gee JC, et al. User guided 3D active contour segmentation of anatomical structures: significantly improved efficiency and reliability. *Neuroimage.* 2006 Jul 1;31(3):1116-28.
- Chapuis J, Schramm A, Pappas I, Hallermann W, Schwenzer-Zimmerer K, Langlotz F, et al. A new system for computer-aided preoperative planning and intraoperative navigation during corrective jaw surgery. *IEEE Trans Inf Technol Biomed.* 2007 May;11(3):274-87.
- Gerig G, Jomier M, Chakos M. Valmet: a new validation tool for assessing and improving 3D object segmentation. *Med Image Comput Comput Assist Interv Int Conf.* 2001;2208:516-28.
- Bookstein F, Schäfer K, Prossinger H, Seidler H, Fieder M, Stringer C, et al. Comparing frontal cranial profiles in archaic and modern homo by morphometric analysis. *Anat Rec.* 1999 Dec 15;257(6):217-24.
- Bookstein FL. *Morphometric tools for landmark data.* 1<sup>st</sup> ed. Cambridge: Cambridge University Press; 1991.
- Baumrind S, Ben-Bassat Y, Bravo LA, Curry S, Korn EL. Partitioning the components of maxillary tooth displacement by the comparison of data from three cephalometric superimpositions. *Angle Orthod.* 1996;66(2):111-24.
- Efstratiadis S, Baumrind S, Shofer F, Jacobsson-Hunt U, Laster L, Ghafari J. Evaluation of Class II treatment by cephalometric regional superimpositions versus conventional measurements. *Am J Orthod Dentofacial Orthop.* 2005 Nov;128(5):607-18.
- Ghafari J, Baumrind S, Efstratiadis SS. Misinterpreting growth and treatment outcome from serial cephalographs. *Clin Orthod Res.* 1998 Nov;1(2):102-6.
- Cevidanes LH, Styner MA, Proffit WR. Image analysis and superimposition of 3-dimensional cone-beam computed tomography models. *Am J Orthod Dentofacial Orthop.* 2006 May;129(5):611-8.
- Björk A, Skieller V. Normal and abnormal growth of the mandible. A synthesis of longitudinal cephalometric implant studies over a period of 25 years. *Eur J Orthod.* 1983 Feb;5(1):1-46.
- Halazonetis DJ. Computer-assisted cephalometric analysis. *Am J Orthod Dentofacial Orthop.* 1994 May;105(5):517-21.
- Johnston LE Jr. Balancing the books on orthodontic treatment: an integrated analysis of change. *Br J Orthod.* 1996 May;23(2):93-102.
- Harris MD, Van Sickels JE, Alder M. Factors influencing condylar position after the bilateral sagittal split osteotomy fixed with bicortical screws. *J Oral Maxillofac Surg.* 1999 Jun;57(6):650-4.
- Costa F, Robiony M, Toro C, Sembronio S, Polini F, Politi M. Condylar positioning devices for orthognathic surgery: a literature review. *Oral Surg Oral Med Oral Pathol Oral Radiol Endod.* 2008 Aug;106(2):179-90.
- Herford AS, Hoffman R, Demirdji S, Boyne PJ, Caruso JM, Leggitt VL, et al. A comparison of synovial fluid pressure after immediate versus gradual mandibular advancement in the miniature pig. *J Oral Maxillofac Surg.* 2005 Jun;63(6):775-85.
- Hwang SJ, Haers PE, Seifert B, Sailer HF. Surgical risk factors for condylar resorption after orthognathic surgery. *Oral Surg Oral Med Oral Pathol Oral Radiol Endod.* 2000 May;89(5):542-52.

Submitted: January 2010  
Revised and accepted: July 2010

**Contact address**

Alexandre Trindade Motta  
Av. das Américas, 3500 – Bloco 7/sala 220  
CEP: 22.640-102 – Barra da Tijuca - Rio de Janeiro / RJ, Brazil  
E-mail: alemotta@rjnet.com.br