

Assessment of condylar growth by skeletal scintigraphy in patients with posterior functional crossbite

Pepita Sampaio Cardoso Sekito*, Myrela Cardoso Costa**, Edson Boasquevisque***, Jonas Capelli Junior****

Abstract

Objectives: This study evaluates the condylar growth activity in 10 patients with functional posterior crossbite before and after correction, using the mandibular bone skeletal scintigraphy. **Methods:** Patients received endovenous injection of radioactive contrast (Technesium-99m labeling, sodium methylene diphosphate). After two hours, planar scintigraphic images were taken by means of a Gamma camera. Lateral images of the closed mouth, showing the right and left condyles, were used. An image of the 4th lumbar vertebra was also used as reference. **Results:** Statistically significant differences were not found in the uptake rate values, on both sides when pre-treatment and post-treatment periods were analyzed separately and also when pre-treatment and post-treatment periods were analyzed in the same side. No differences were found in the condylar growth activity, in patients with functional posterior crossbite.

Keywords: Functional posterior crossbite. Condilar growth. Skeletal scintigraphy.

INTRODUCTION

In dentistry and particularly orthodontics, the understanding of growth and craniofacial development, have always been of extreme importance due to the direct influence on diagnosis and prediction of treatment. As the knowledge of these events improves, it is also possible to im-

prove treatment planning because most attempts to prevent, intercept and correct malocclusions take place during growth.¹⁻⁵

The dynamic growth assessment by means of conventional methods is quite limited, as this is based, either on the growth that occurred in the past (serial observation and serial cephalograms)

* MD, Assistant Professor – Orthodontics, Dental School, Estácio de Sá University.

** MD, PhD Student, School of Dentistry, State University of Rio de Janeiro

*** PhD, Assistant Professor – School of Medical Sciences, State University of Rio de Janeiro.

**** PhD, Associate Professor in Orthodontics School of Dentistry, State University of Rio de Janeiro.

or due to the craniofacial assessment based on general skeletal maturation (hand and wrist radiographs and vertebra maturation). Thus, a dynamic method to specifically assess craniofacial growth, such as skeletal scintigraphy would enhance diagnosis and treatment planning, especially in cases of craniofacial deformities or mandibular alterations.^{6,7,8}

Skeletal scintigraphy is an imaging method that has the sensitivity to reflect skeletal metabolic activity.⁹ It involves the administration of a bone-seeking radiopharmaceutical preparation, which is then absorbed by the blood flow. Bone formation and remodeling can thus be observed through this technique as osteogenesis is detected by means of bone scans carried out with a gamma camera.^{6,7,8}

The radioisotope used, ^{99m}Tc, is coupled to phosphates and phosphonates which are incorporated to the bone matrix, where bone formation and resorption take place. Thus, bone scintigraphy is considered an efficient technique that can be indicated for the assessment of dynamic craniofacial growth, with only one exam.^{6,7,8} Because of its ability to detect functional change, a bone scan can be informative before visible structural changes occur on radiographs.^{9,10}

Functional posterior crossbite is a lateral deviation of the mandible due to occlusal interference. Authors report that, in children with this malocclusion, the condyles on the crossbite side are positioned relatively more superiorly and posteriorly in the glenoid fossa than those on the non-crossbite side.¹¹ In such cases the neuromuscular activity is altered, thus, a skeletal remodeling of the temporomandibular joint can occur over time, generating asymmetries in the condylar and mandibular growth, which will result in true dentofacial asymmetries in adult stage. Several studies, using radiographs, report that when this malocclusion is corrected, and the functional deviation eliminated, condyles will take a symmetric position, which will allow a more harmonic mandibular growth.^{12,13,14}

The aim of this study was to evaluate the condylar growth activity in patients with functional posterior crossbite, through mandibular skeletal scintigraphy.

MATERIAL AND METHODS

Ten patients were selected (mean age 9yr±4mo) presenting posterior functional crossbite and chosen to be treated in the Orthodontic Clinic at the State University of Rio de Janeiro. Specific criteria were: Crossbite should involve, at least, two teeth, including the first permanent molar plus a deciduous molar, and a midline deviation of 1 mm or more in the intercuspatal position. The patient should not have midline deviation in centric relation and, when requested to occlude, should present occlusal interferences that cause lateral deviation of the mandible. Consent was obtained and this study was previously submitted and authorized by the ethical committee of the State University of Rio de Janeiro.

A removable Porter appliance (W arch) was used for crossbite correction. Activations were carried out with a six-week interval, and continued until the overcorrection of the crossbite. Once the overcorrection had been achieved, the appliance remained passive for a six-week retention period.¹⁴ Mandibular skeletal scintigraphy examination was carried out before treatment and then repeated after the retention period (mean, 5.1 months).

To perform mandibular skeletal scintigraphy, patients were sent to the Nuclear Medicine Service of the State University of Rio de Janeiro Hospital, where a radioactive contrast was injected intravenously (cubital vein), using the Technesium-99m Radionucleid composite, labeling methylene diphosphonate sodium (Tc 99m – MDP), in saline solution (0.9%). Dose used was 300 microcuries (300μCi) for each kilogram.^{7,8}

After two-hours, the patients were positioned in front of the Gamma camera (Siemens™ E-CAN model), with a wide range of vision using

a parallel hole collimator for low energy and high resolution. Static (planar) projections of the head were taken, considering the lateral direction (right and left) with closed mouth, having 400.000 counts per image. An image of the lumbo-sacral spine was also taken using the same technique. Hyperextension of the neck was carried out on the lateral shots, to increase space between the cervical spine and the mandible region and help the observation of the condyles.^{7,8}

Images were processed on the ICON/Siemens system. Regions of Interest (ROIs) were selected in the right and left projections of the condyles and in the 4th lumbar vertebra (Fig 1). Considering the selected regions, mean counts per pixel were calculated on each one of the ROIs. Uptake ratio between counts of each condyle and the fourth vertebra was calculated as follows: UR (uptake ratio) is equal to mandible ROIs count divided by 4th lumbar vertebra ROIs count. The fourth lumbar vertebra uptake was used as a control and reference for the other selected areas, as it had an even skeletal uptake, compensating possible errors resulting from skeletal overposition of the condylar regions.^{7,8}

Before final results were obtained, the same evaluator, trained for the method, carried out the ROIs markings on all projections. Exams were evaluated three times and intra-observer error was 6.5%.

Pre-treatment and post-treatment UR values were compared for the same side and each side UR value (crossbite and non-crossbite sides) was

also compared for the same period. Wilcoxon test was used to verify the differences. Significance would be accepted for a level of 5%.

RESULTS

No statistically significant differences were found in the condylar growth activity, on both sides when pre-treatment and post-treatment periods were analyzed separately and also, when pre-treatment and post-treatment periods were analyzed in the same side (Tables 1 and 2).

In Figures 2 and 3, it can be observed that the dispersion found was greater in the pre-treatment than in the post-treatment period. This suggests that the UR values of the altered and non-altered sides presented closer values in the post-treatment period.

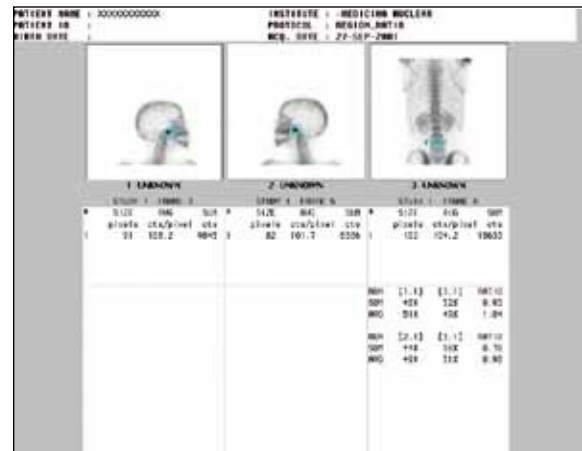

FIGURE 1 - Patient with functional posterior crossbite (scintigraphy images processing): lateral images X fourth lumbar vertebra image, with selected regions of interest (ROIs) and calculated ratio of uptake (RU).

TABLE 1 - Uptake ratios (UR) comparisons between the condylar sides treated.

	Altered side Pre-treatment	Altered side Post-treatment	Non-altered side Pre-treatment	Non-altered side Post-treatment
Mean	1.152	1.035	1.169	1.023
SD	0.144	0.238	0.152	0.242
p	0.575		0.475	

(Wilcoxon test for significance level of 5%).

TABLE 2 - Uptake ratios (UR) comparisons between treatment periods.

	Altered side Pre-treatment	Non-altered side Pre-treatment	Altered side Post-treatment	Non-altered side Post-treatment
Mean	1.152	1.169	1.035	1.023
SD	0.144	0.152	0.238	0.242
p	0.574		0.540	

(Wilcoxon test for significance level of 5%).

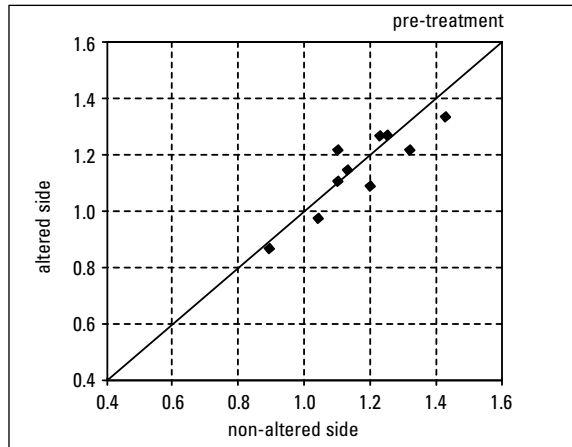


FIGURE 2 - Dispersion between the uptake ratios (UR) of the altered and non-altered condylar sides in the pre-treatment in the lateral scintigraphy projections.

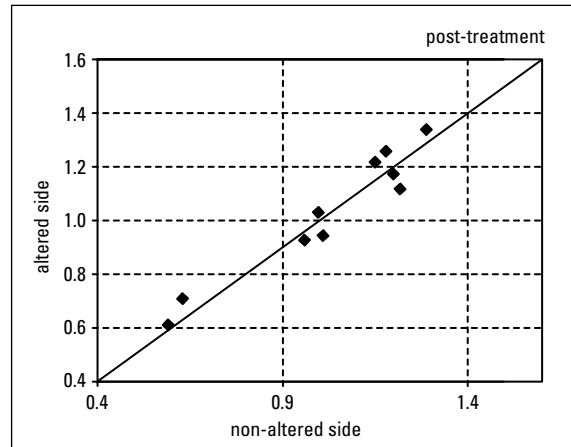


FIGURE 3 - Dispersion between the uptake ratios (UR) of the altered and non-altered condylar sides, in the post-treatment, in the lateral scintigraphy projections.

DISCUSSION

There are evidences that condylar position in patients presenting functional posterior crossbite may appear altered.¹⁰ Previous studies have found that the condyle, on the crossbite side, became higher and posteriorly positioned in the glenoid fossa,¹¹⁻¹⁶ while the condyle on the non-crossbite side would present a more anterior and lower position.^{12,14} When the condyles presented such excentric position, some altered neuromuscular activity might exist in these patients. This may cause asymmetries in the condylar development, as well as in mandibular growth.¹²⁻¹⁷

It has been observed in some studies that once malocclusion has been corrected, the functional deviation is usually eliminated. Thus, condyles that were mal-positioned before treatment can take a more symmetrical bilateral position, which, as a consequence, may allow for a more harmonic condylar and mandibular growth.^{12,13,14} In the present study, even though no statistical differences were observed, the

tendency for a greater uptake of the altered condylar side, in the pre-treatment, may suggest agreement with the previously referred studies on condylar positioning.^{12,13,14} Due to the altered condylar position, these authors suggest an increased condylar skeletal uptake on the altered condylar side, before crossbite correction.

Interestingly, the results of the present study may also raise some questions about the condylar growth changes. As we could not find statistically significant differences between crossbite and non-crossbite sides using a very sensitive technique, the altered positioning of the condyles may not actually lead to significant changes in condylar growth but some TMJ soft tissue adaptations and remodeling of the glenoid fossa.

It is also important to consider that maybe changes do not occur immediately after crossbite correction, and that possibly a retention period greater than six weeks is necessary to observe significant differences.

On the other hand, as both sides of the mandible work on a correlated function basis, an altered

growth condition, on one side, may generate considerable effects in the function and growth of the opposite, biasing the results.⁶ Further studies with a longer retention period and larger sample, may enhance the knowledge about this important clinical issue.

The similar post-treatment condylar uptake values, suggested, in agreement to previous studies, that concentric position of the condyles may represent a more balanced growth and development of such condyles, when the functional posterior crossbite is corrected.¹¹⁻¹⁴

The dispersion analysis for condylar uptake suggests that in the pre-treatment (Fig 2) period the UR values presented a greater difference between the crossbite and non-crossbite sides than in the post-treatment (Fig 3), where smaller dispersion suggests closer UR values between the two condylar sides.¹¹⁻¹⁴

Although no statistically significant difference was found in the present study, a decrease tendency in the condylar uptake was observed, on both sides, after the crossbite correction.

Some studies suggest that the condylar position becomes more concentric after the crossbite correction.^{11,12,13} According to those authors, the altered condylar side may have more growth stimulus due to the condylar displacement, caused by the malocclusion. Once this stimulus

is eliminated, by the treatment and a greater concentricity of the condylar position is obtained, a smaller or more balanced condylar growth can be achieved.^{11,12,13}

Variation in the uptake values in the post-treatment period might suggest that patients respond differently to the treatment, although they keep the same tendency. Different reactions to crossbite correction have been also cited, according to their characteristics (number of patients, individual characteristics, re-assessment period) and the nature of treatment (appliance design, period of treatment).^{16,17}

This study introduces an important mechanism of evaluation of the influence of orthodontic treatment upon growth during crossbite correction. Further researches will be able to clarify the questions raised as they become more specific in their analysis strategies. In this way, resources for the skeletal scintigraphy examination could be used to optimize diagnostic routine in clinical orthodontics.

CONCLUSION

No statistically significant differences were observed in the condylar growth activity in individuals with functional posterior crossbite, when ipsilateral and contralateral sides are compared before and after treatment.

REFERENCES

1. Grave KC, Brown T. Skeletal ossification and adolescent growth spurt. *Am J Orthod Dentofacial Orthop.* 1976 Jul;69(6):611-9.
2. Green LJ. The interrelationships among height, weight, and chronological, dental and skeletal ages. *Angle Orthod.* 1961 Jun;31(3):189-93.
3. Hägg U, Taranger J. Maturation indicators and the puberal growth spurt. *Am J Orthod.* 1982 Oct;82(4):299-309.
4. Moore RN, Moyer BA, DuBois LM. Skeletal maturation and craniofacial growth. *Am J Orthod Dentofacial Orthop.* 1990 Jul;98(1):33-40.
5. Gomes AS, Lima EM. Mandibular growth during adolescence. *Angle Orthod.* 2006 Sep;76(5):786-90.
6. Cisneros GJ, Kaban LB. Computerized skeletal scintigraphy for assessment of mandibular asymmetry. *J Oral Maxillofac Surg.* 1984 Aug;42(8):513-20.
7. Kaban LB, Cisneros GJ, Heyman S, Treves S. Assessment of mandibular growth by skeletal scintigraphy. *J Oral Maxillofac Surg.* 1982 Jan;40(1):18-22.
8. Kaban LB, Treves ST, Progrell MA, Hattner RS. Skeletal scintigraphy for assessment of mandibular growth and asymmetry. In: *Pediatric Nuclear Medicine.* 2nd ed. New York: Springer Verlag; 1995. p. 316-27.
9. Güner DD, Oztürk Y, Sayman HB. Evaluation of the effects of functional orthopaedic treatment on temporomandibular joints with single-photon emission computerized tomography. *Eur J Orthod.* 2003 Feb;25(1):9-12.
10. Baydas B, Yavuz I, Uslu H, Dagsuyu IM, Ceylan I. Nonsurgical rapid maxillary expansion effects on craniofacial structures in young adult females. *Angle Orthod.* 2006 Sep;76(5):759-67.
11. Andrade Ada S, Gameiro GH, Derossi M, Gavião MB. Posterior crossbite and functional changes – a systematic review. *Angle Orthod.* 2009 Mar;79(2):380-6.
12. Hesse KL, Artun J, Joondeph DR, Kennedy DB. Changes in condylar position and occlusion associated with maxillary expansion for correction of functional unilateral posterior crossbite. *Am J Orthod Dentofacial Orthop.* 1997 Apr;111(4):410-8.
13. Myers DR, Barenie JT, Bell RA, Williamson EH. Condylar position in children with functional posterior crossbites: before and after crossbite correction. *Pediatr Dent.* 1980 Sep;2(3):190-4.
14. Pinto AS, Buschang PH, Throckmorton GS, Chen P. Morphological and positional asymmetries of young children with functional unilateral posterior crossbite. *Am J Orthod Dentofacial Orthop.* 2001 Nov;120(5):513-20.
15. Paulsen HU, Rabøl A, Sørensen SS. Bone scintigraphy of human temporomandibular joints during Herbst treatment: a case report. *Eur J Orthod.* 1998 Aug;20(4):369-74.
16. Bell RA, LeCompte EJ. The effects of maxillary expansion using a quad-helix appliance during the deciduous and mixed dentitions. *Am J Orthod.* 1981 Feb;79(2):152-61.
17. Erdiñç AE, Ugur T, Erbay E. A comparison of different treatment techniques for posterior crossbite in the mixed dentition. *Am J Orthod Dentofacial Orthop.* 1999 Sep;116(3):287-300.

Submitted: June 2010
Revised and accepted: August 2010

Contact address

Myrela Cardoso Costa
Av. Professor Magalhães Neto, 1450 – 309
CEP: 41.810-012 – Salvador/BA, Brazil
E-mail: myrelacardoso@yahoo.com.br