

Use of orthodontic records in human identification*

Rhonan Ferreira da Silva**, Patrícia Chaves***, Luiz Renato Paranhos****, Marcos Augusto Lenza*****, Eduardo Daruge Júnior*****

Abstract

Objective: This study describes a forensic case of incinerated remains that were identified using information found in his orthodontic records. **Method:** Incinerated remains of a man were found inside a car. After forensic crime scene investigation and postmortem and radiographic exams in the Forensic Department, forensic experts found that the victim had a fixed orthodontic appliance, supernumerary teeth in all quadrants, partially erupted third molars and amalgam restorations in some surfaces of several teeth. As the individual's soft tissues were substantially destroyed, identification using fingerprints was not the ideal choice. After orthodontic records were handed in by the family, his clinical chart, radiographs, intra- and extraoral photographs and impressions were analyzed, and these data were compared with previously collected information. **Results and Conclusions:** Forensic dentistry examination revealed 20 concordant points in specimen examination and orthodontic records, which enabled the establishment of a positive correlation between the cadaver under examination and the missing person and eliminated the need for further analyses (DNA tests) to identify the victim.

Keywords: Forensic anthropology. Forensic dentistry. Orthodontics.

INTRODUCTION

Orthodontics is the specialization whose purpose is the prevention, supervision and guidance of the development of the masticatory system, the correction of dentofacial structures, including the conditions that require tooth movement for their treatment, and the establishment of esthetic harmony of the maxillary and mandibular structures of the face.

Because of the complexity of cases and the considerable time spent working with orthodontic patients, orthodontists produce several dental records, fundamental for the planning and performance of this type of treatment. These records usually include dental charts, which may be defined as the comprehensive document that contains all data about patient identification and history, answers to

* Study conducted as part of the requisites to obtain the degree of Specialist in Orthodontics of the School of Dentistry of the Federal University of Goiás (FO-UFG).

** MSc in Forensic Dentistry, School of Dentistry of Piracicaba, Campinas University (FOP-UNICAMP), Brazil. Professor, Forensic Dentistry, Paulista University, State of Goiás (UNIP-GO), Brazil. Criminal Examiner, Forensic Police Department, Goiás, Brazil.

*** MSc in Comprehensive Dental Clinic and Restorative Dentistry, FOP-UNICAMP, Brazil. Professor, Comprehensive Care, UNIP-GO, Brazil. Specialist Degree in Orthodontics, School of Dentistry, Federal University of Goiás (FO-UFG), Brazil.

**** PhD, Buccodental Biology - FOP/UNICAMP/Piracicaba. Head Professor, Graduate Dentistry Program, Orthodontics, UMESP/São Bernardo do Campo.

***** PhD in Orthodontics, University of Nebraska, USA. Head Professor, Orthodontics, FO-UFG, Brazil.

***** Professor, PhD in Forensic Dentistry, FOP-UNICAMP, Brazil.

a health questionnaire, findings of general physical examinations and extra- and intraoral exams, treatment plan chosen and authorized by the patient and treatment outcomes. Patient records are also used as a file to store complementary tests required by the orthodontic treatment, such as radiographs, plaster impressions, photographs, tracings, and other specific documents.

In Brazil, dentists are required to adequately store and keep all dental documents produced during the treatment of their patients, as established in Paragraph 5 of the Brazilian Code of Ethics in Dentistry. The storage of dental records enables the orthodontist to follow the clinical development of treatments under way and those already completed at any time. In Forensic Dentistry, the importance of these stored materials is associated with both issues of professional defense, in cases of lawsuits against dentists,⁸ and the identification of skeletonized, putrefied or incinerated cadavers.^{11,12}

Considering the responsibility of orthodontists in the practice of their profession and the richness of information found in orthodontic records, this study describes a forensic case of an individual whose remains were incinerated and whose identity was positively established using information from a panoramic radiograph and intraoral photographs taken due to an orthodontic treatment.

CASE REPORT

In August 2006, the incinerated remains of a man were found inside a car. After the forensic crime scene investigation, remains were taken to the Forensic Department of the region for routine postmortem examination, such as the determination of cause of death, identification of instrument or means of death and, if possible, establishment of the victim's identity.

The friability of remaining hard tissues, exacerbated by incineration, led us to resect the mandible and maxilla so that the characteristics of the dental arches could be better evaluated. Although

care was taken during postmortem examination, part of the structures in the anterior mandible did not resist tissue manipulation and partially lost their integrity. Postmortem and radiographic examination of these specimens revealed the presence of several dental events of great forensic importance, such as the use of a fixed orthodontic appliance (Fig 1), supernumerary teeth in the four quadrants, partially erupted third molars and amalgam restorations in several tooth surfaces (Figs 2 and 3).

Concurrent to the examination of remains, police investigations advanced and found information about the probable victim, who had anthropological characteristics compatible with those found in the cadaver under study. As soft tissues were severely destroyed, identification according to fingerprints was not the ideal choice. Therefore, relatives of this missing person were asked to search for any type of medical or dental records or photographs that might support identification.

The result of their search brought the information that the missing individual was undergoing orthodontic treatment, and all clinical records were requested. The records handed in for examination were a clinical chart, a panoramic radiograph (Fig 4), a lateral radiograph, 05 intraoral photographs (Fig 5), 03 extraoral photographs, a request for the extraction of supernumerary teeth,



FIGURE 1 - Incinerated anterior teeth with missing brackets, lost with buccal enamel, and orthodontic wire.

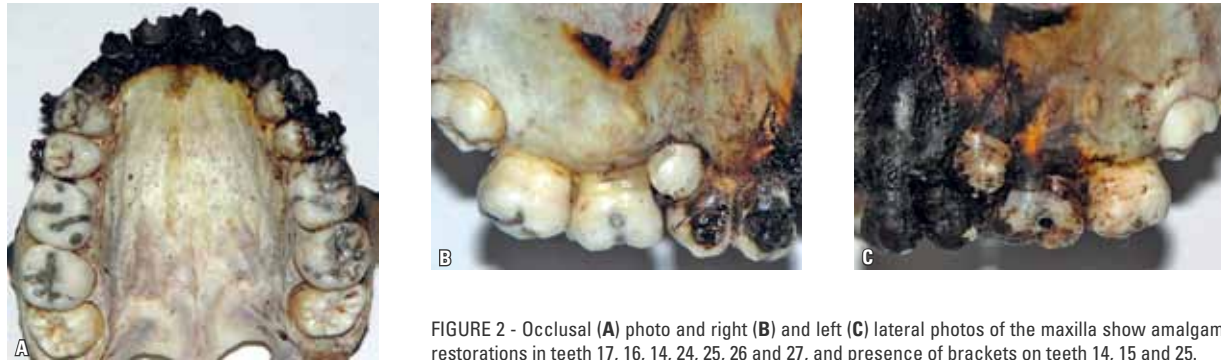


FIGURE 2 - Occlusal (A) photo and right (B) and left (C) lateral photos of the maxilla show amalgam restorations in teeth 17, 16, 14, 24, 25, 26 and 27, and presence of brackets on teeth 14, 15 and 25.

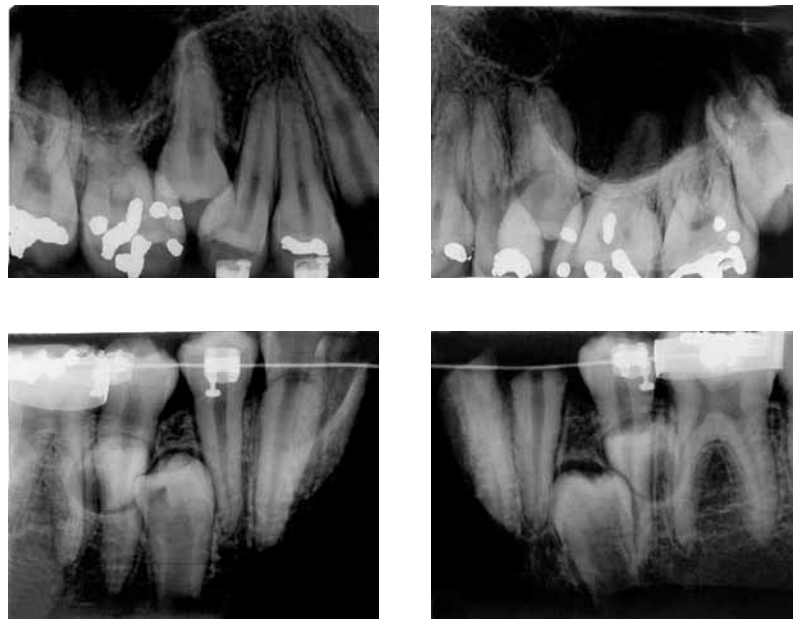


FIGURE 3 - Postmortem radiographs show supernumerary teeth in maxillary and mandibular arches, as well as brackets and bands in mandibular molars.

a radiographic interpretation report and a pair of plaster impressions. The date of these documents was of 2005. All dental information and characteristics in the orthodontic records were grouped in a single dental diagram.

DISCUSSION

Forensic literature has several case reports of incinerated, skeletonized or decomposing remains that were identified by analysis of dental characteristics,^{5,6} a technique that may be associ-

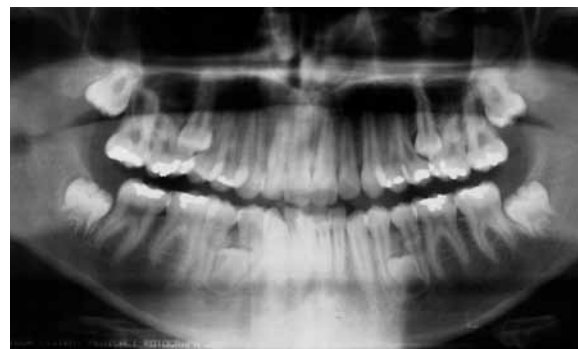

FIGURE 4 - Panoramic radiograph used in orthodontic treatment (2005).

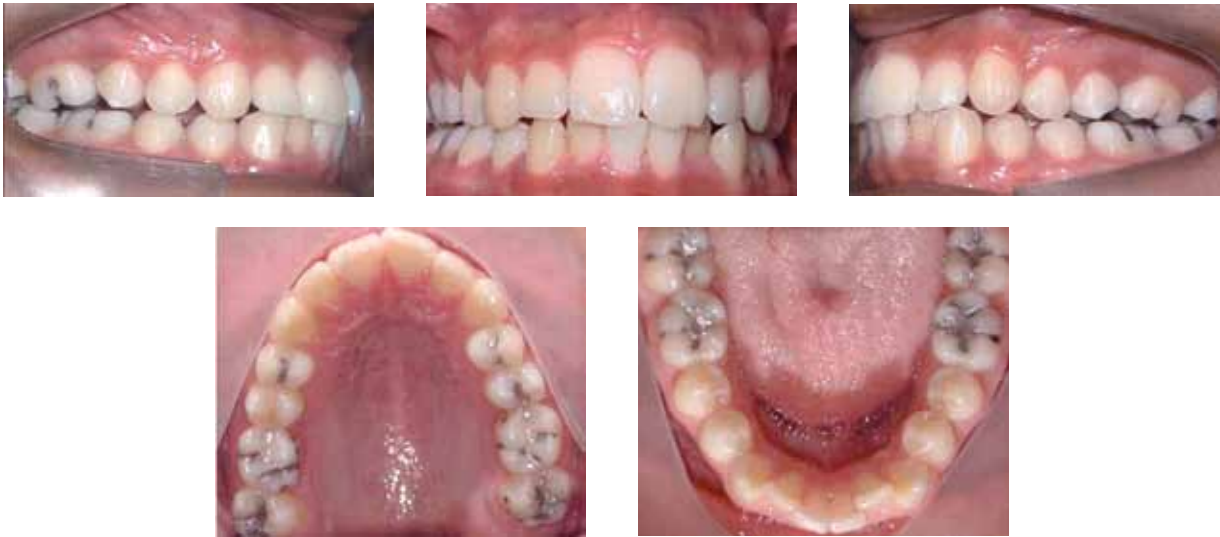

FIGURE 5 - Intraoral photographs taken for orthodontic treatment (2005).

ated with other human identification methods.² The good results obtained with the use of this technique may be assigned to the considerable resistance to fire of teeth and dental materials,⁷ as well as to the information found in documents produced during dental care, such as dental charts, radiographs and photographs.

Forensic dental identification may be classified as a comparative method to determine an individual's identity. For didactic purposes, it may be divided into three phases: (1) exam of the cadaver's dental arches; (2) exam of dental records; (3) and forensic dental comparisons.⁹ In the first phase, all the particular characteristics found in the cadaver's dental arches are recorded and associated with present or missing teeth, restorations (surfaces and materials), prosthesis, endodontic treatments, pathologies, anomalies, and other features. During the exam of dental records, experts collect all data about treatments performed or planned that were recorded by the dentist in the dental charts, associated with the information produced by complementary tests, such as radiographs, photographs and impressions. During the last phase, the data obtained in the first two phases are compared using the same reference points (surface,

tooth, quadrant) and a qualitative and quantitative analysis of the particular dental characteristics (Fig 6).

In the case described here, forensic dentistry comparisons revealed that a total of 20 relevant comparison points were identified, associated with the presence of supernumerary teeth between teeth # 15/16, 25/26, 34/35 and 44/45 (Teeth are described using the FDI numbering system), in addition to shape and site of amalgam restorations in most of the posterior teeth. These concordant comparative points showed a positive correlation between the cadaver under examination and the identity of the missing person and eliminated the need to perform other exams (DNA tests) to establish the victim's identity. Genetic testing provides extremely reliable results, but falls short of the usefulness of forensic dental examinations when cost, time and structure necessary to use the technique are taken into consideration.¹⁰

Positive identification was possible after we obtained the missing person's orthodontic treatment documentation. The panoramic radiograph and the photographs used in orthodontic planning were obtained by using correct techniques

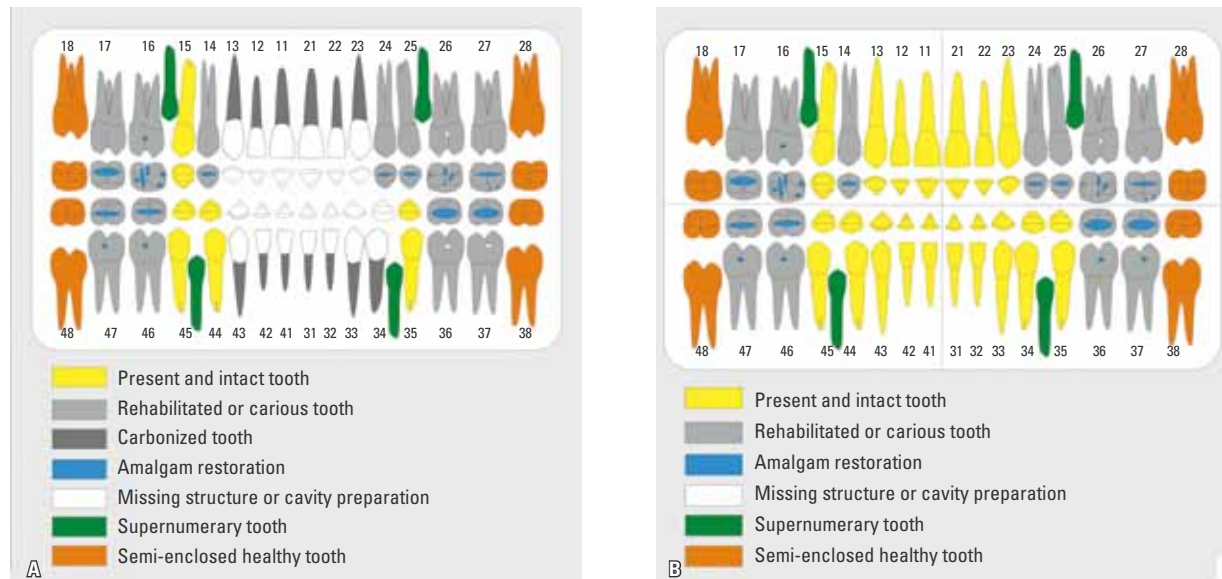


FIGURE 6 - Dental diagram built according to postmortem and radiographic examination of remains (A), and dental diagram with data collected from orthodontic records (B).

and had no distortions or poor sharpness, which made it possible to evaluate qualitative features. This is the reason why no minimum number of points should be established for the positive identification of an individual using the forensic dental technique, because the number of concordant points may vary according to each case.¹

CONCLUSION

Dentists should be aware of the importance of accurately completing dental charts and producing and storing data and material that are part of a patient's dental documentation because, in addition to their clinical importance, these records may produce relevant information to courts.

REFERENCES

1. Acharya AB, Taylor JA. Are a minimum number of concordant matches needed to establish identity in forensic odontology? *J Forensic Odontostomatol.* 2003 Jun;21(1):6-13.
2. Bilge Y, Kedici PS, Alakoç YD, Ulküer KU, Ilkyaz YY. The identification of a dismembered human body: a multidisciplinary approach. *Forensic Sci Int.* 2003 Nov 26;137(2-3):141-6.
3. Conselho Federal de Odontologia (Brasil). Código de ética odontológica: aprovado pela resolução CFO nº 42. Rio de Janeiro. 2003. [Acesso em: 2006 nov 6]. Disponível em: <<http://www.cfo.org.br>>.
4. Conselho Federal de Odontologia (Brasil). Consolidação das normas para procedimentos nos conselhos de Odontologia: aprovada pela resolução CFO nº 63. Rio de Janeiro, 2005. [Acesso em: 2006 nov 6]. Disponível em: <<http://www.cfo.org.br>>.
5. Goodman NR, Himmelberger LK. Identifying skeletal remains found in a sewer. *J Am Dent Assoc.* 2002 Nov;133(11):1508-13.
6. Marks MK, Bennett JL, Wilson OL. Digital video image capture in establishing positive identification. *J Forensic Sci.* 1997 May;42(3):492-5.
7. Muller M, Berytrand MF, Quatrehomme G, Bolla M, Rocca JP. Macroscopic and microscopic aspects of incinerated teeth. *J Forensic Odontostomatol.* 1998 Jun;16(1):1-7.
8. Ramos DIA, Daruge Júnior E, Daruge E, Antunes FCM, Meléndez BVC, Francesquín JL, et al. Transposición dental y sus implicaciones éticas y legales. *Rev ADM.* 2005 sept-oct;62(5):185-90.
9. Rothwell BR. Principles of dental identification. *Dent Clin North Am.* 2001 Apr;45(2):253-70.
10. Silva RF, Pereira SDR, Daruge E, Daruge Júnior E, Francesquini JL. A confiabilidade do exame odontolegal na identificação humana. *Robrac.* 2004;13(35):46-50.
11. Silva RF, Cruz BVM, Daruge Júnior E, Daruge E, Francesquini JL. La importancia de la documentación odontológica en la identificación humana. *Acta Odontol Venez.* 2005 ago;43(2):67-74.
12. Silva RF, Pereira SDR, Mendes SDS, Marinho DEA, Daruge Júnior E. Radiografias odontológicas: fonte de informação para a identificação humana. *Odontologia Clínic Científ.* 2006; 5(3):239-42.
13. Silva RF, Prado MM, Barbieri AA, Daruge Júnior E. Utilização de registros odontológicos para identificação humana. *RSBO.* 2009;6(1):95-9.

Submitted: April 2007

Revised and accepted: February 2009

Contact address

Rhonan Ferreira da Silva
 Avenida Arumã Qd. 186 Lt. 06, Parque Amazônia
 CEP: 74.835-320 - Goiânia / GO, Brazil
 E-mail: rhonanfs@terra.com.br