



Checklist of esthetic features to consider in diagnosing and treating excessive gingival display (gummy smile)

Máyra Reis Seixas*, Roberto Amarante Costa-Pinto**, Telma Martins de Araújo***

Abstract

Introduction: Excessive gingival display on smiling is one of the problems that negatively affect smile esthetics and is, in most cases, related to several etiologic factors that act in concert. A systematic evaluation of some aspects of the smile and the position of the lips at rest can facilitate the correct assessment of these patients. **Objective:** To present a checklist of dentolabial features and illustrate how the use of this record-keeping method during orthodontic diagnosis can help decision making in treating the gummy smile, which usually requires knowledge of orthodontics and other medical and dental specialties.

Keywords: Orthodontics. Esthetics. Smile.

INTRODUCTION

Whenever patients are able to clearly view their own gummy smile (GS) this condition becomes an important esthetic complaint during orthodontic anamnesis. Although it appears fairly frequently in private offices, very few studies in the literature address GS, its diagnosis and treatment as a central topic. Treating the smile is a challenging task for orthodontists. One historical reason for this fact is that in the 20th century, particularly in the 1950s and 1960s, orthodontic diagnosis and treatment were based on cephalometry and, therefore, esthetic concepts

were defined primarily based on a profile view of the patient. Nevertheless, in their orthodontic records orthodontists continued to focus on the use of plaster models, which provide but a static record of occlusion, neglecting the dynamic analysis of speech and smile, as well as the evaluation of morphological and functional characteristics of the lips. Since the act of smiling is a dynamic process, the beauty of a smile depends not only on correct dental and skeletal positioning, but also on the anatomy and function of the lip muscles, over which orthodontists must recognize that they exercise little or no control.

* MSc in Orthodontics, Rio de Janeiro Federal University (UFRJ). Collaborating Faculty Member, Specialization Program in Orthodontics, Bahia Federal University (UFBA). Diplomate of the Brazilian Board of Orthodontics and Facial Orthopedics.

** MSc in Orthodontics, Rio de Janeiro Federal University (UFRJ). Professor of Orthodontics (EBMSP). Collaborating Faculty Member, Specialization Program in Orthodontics, Bahia Federal University (UFBA).

*** MSc and PhD in Orthodontics, Rio de Janeiro Federal University (UFRJ). Head Professor and Coordinator, Prof. José Édimo Soares Martins Center of Orthodontics (UFBA). President, Brazilian Board of Orthodontics and Facial Orthopedics.

GUMMY SMILE (GS)

Most dental professionals believe that during smiling the upper lip should position itself at the gingival margin of the maxillary central incisors.^{1,2,3} However, it is known that displaying a certain amount of gingiva is esthetically acceptable and in many cases imparts a youthful appearance.^{4,5,6}

Although there are several parameters in the literature that define GS (amount in millimeters of gingival display on smiling), what seems most likely to arouse orthodontists' interest are the beliefs held by the general public concerning what is, or is not esthetically acceptable. Research conducted by Kokich Jr et al⁷ found that a smile is considered unesthetic—by both clinicians and lay people—when gingival exposure reaches 4 mm. For orthodontists, who tend to be more demanding, 2 mm gingival exposure on smiling is enough to compromise smile harmony (Fig 1).

Smile height is influenced by sex and age. There is evidence that women display higher smiles than men^{8,9} and that dentogingival exposure decreases with age.⁸ This information has

clinical relevance since GS self-corrects to a certain extent over time, especially in men.¹⁰

Its etiology is related to several factors, such as: Vertical maxillary excess, upper dentoalveolar protrusion, extrusion and/or altered passive eruption of anterosuperior teeth and hyperactivity of upper lip levator muscles. In most cases, however, some or all of these factors are correlated. Orthodontists seem to be the professionals most qualified to critically assess the weight of each of these factors, among which hyperactivity of the upper lip levator muscles is the least studied and hitherto understood.

DIAGNOSIS

Despite the etiologic factors involved in the gummy smile, some issues should be necessarily considered during clinical evaluation. Systematic recording of (a) interlabial distance at rest, (b) exposure of upper incisors during rest and speech, (c) smile arc, (d) width/length ratio of maxillary incisors and (e) morphofunctional characteristics of the upper lip by means of a checklist (Fig 2). All these records can be very

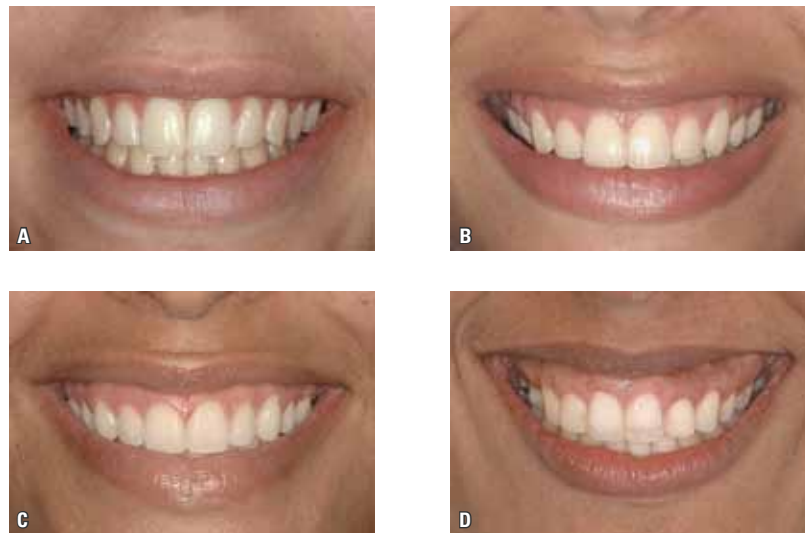

FIGURE 1 - Different degrees of gingival display on smiling: **A)** 0 mm; **B)** 1 mm; **C)** 2 mm and **D)** 4 mm.




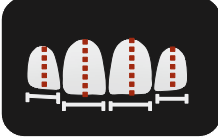

Interlabial Distance at rest	Exposure of upper incisors at rest	Smile arc	W/L ratio of maxillary incisors	Morphofunctional features of upper lip
				
1-3 mm <input type="checkbox"/>	<1 mm <input type="checkbox"/>	Pleasant <input type="checkbox"/>	<65% <input type="checkbox"/>	Short <input type="checkbox"/>
>3 mm <input type="checkbox"/>	1-4.5 mm <input type="checkbox"/>	Flat <input type="checkbox"/>	75-80% <input type="checkbox"/>	Thin <input type="checkbox"/>
	>4.5 mm <input type="checkbox"/>	Reverse <input type="checkbox"/>	>85% <input type="checkbox"/>	Hypermobility <input type="checkbox"/>

FIGURE 2 - Suggested checklist with five items for assessing dentolabial characteristics (download available at www.dentalpress.com.br/journal).

useful in the diagnostic stage. By including these data in the orthodontic consultation file one ensures that information key to the treatment plan are not forgotten or overlooked.

1. Interlabial distance at rest

When entering this information, it is crucial that orthodontists include in the initial orthodontic records a photograph showing the patient's lips at rest. Phonetic assessments based on video footage can also prove useful.

There is no direct relationship between GS and amount of interlabial space at rest.¹¹ Contrary to a long-standing belief, patients with normal upper lip length and reduced interlabial space can present with excessive gingival display on smiling. When interlabial space at rest is normal (1-3 mm), GS is considered to have a predominantly muscular origin (Figs 3 A, B and C). Usually, the main cause of increased interlabial space is dentoskeletal disharmony (vertical maxillary excess and/or protrusion of upper incisors), which may or may not be associated with anatomical and/or functional changes in the upper lip (Figs 4 A, B and C).^{11,13} Diagnosing GS's muscular etiology is crucial for immediately recognizing the limitations of orthodontic treatment and seeking help

from other specialties such as, for example, esthetic medicine. Moreover, a correct diagnosis can decrease the risk that GS correction may interfere with other favorable esthetic features of the smile. This fact lends support to the paradigm of contemporary orthodontics, which consists in identifying the positive esthetic features of the smile to ensure that such features are not affected by treatment of dentofacial problems.¹⁴

2. Upper incisor exposure during rest and speech

It is known that when the lips are at rest the amount of exposure of the upper incisors is approximately 2 to 4.5 mm in women and 1 to 3 mm in men (Fig 5). This characteristic is directly related to the youthful appearance of the smile and it is expected to decline throughout life (given the lengthening of the upper lip that results from the process of tissue maturation and aging).^{10,11,12}

To keep a record of this condition, one can use a standard lateral cephalometric radiograph of the lips at rest and measure the distance in millimeters between the incisal edge of the maxillary central incisor and the lower contour of the upper lip (Fig 6). Phonetic assessments during clinical examination are also important. Patients should

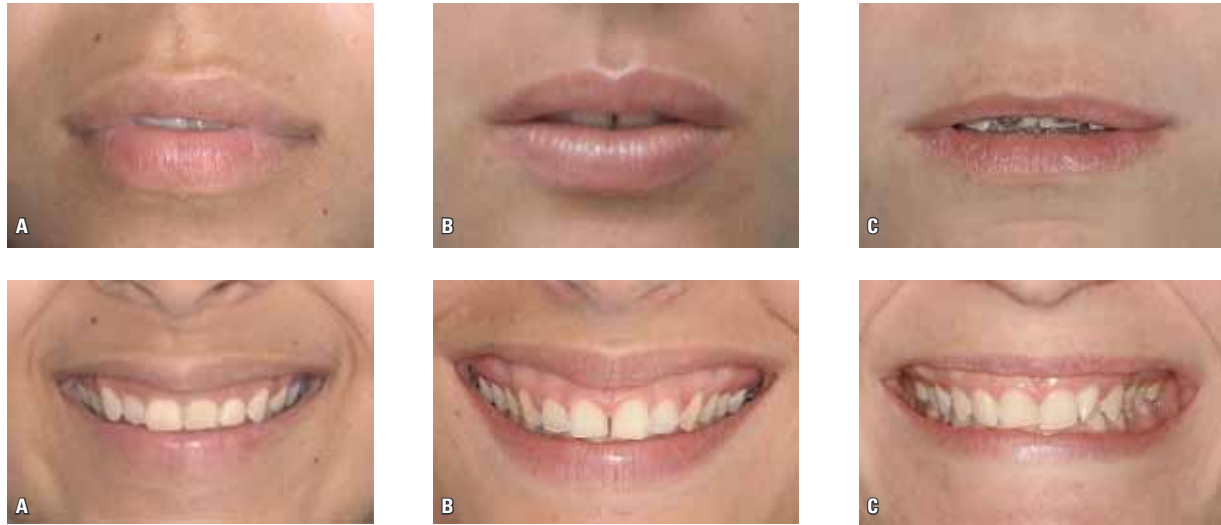

FIGURE 3 - Patients with interlabial space between 1 and 3 mm, normal exposure of upper incisors at rest and gummy smile. In this situation, intrusion of upper incisors to reduce gingival display on smiling is contraindicated.

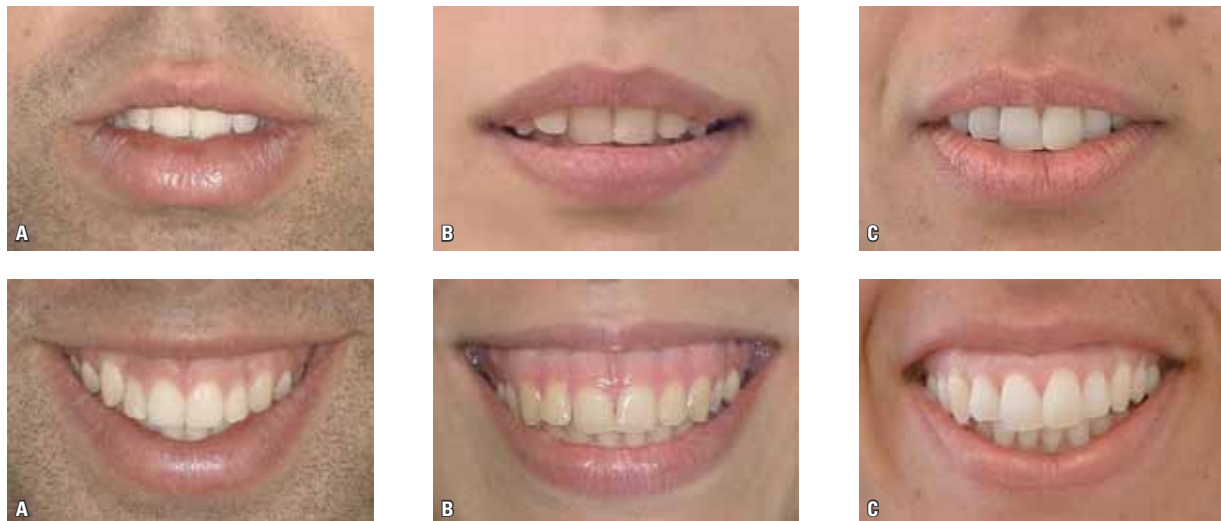

FIGURE 4 - Patients with interlabial space >3 mm, increased exposure of upper incisors at rest and gummy smile. In this situation, orthodontic intrusion and/or ortho-surgery of upper incisors is needed to reduce gingival display on smiling.

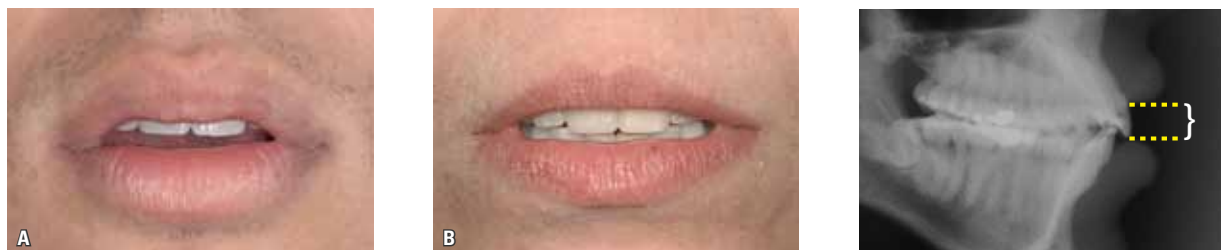

FIGURE 5 - Amount of upper incisor exposure at rest in men (A) is usually smaller than in women (B).

FIGURE 6 - Amount of upper incisor exposure in lateral cephalometric radiograph.

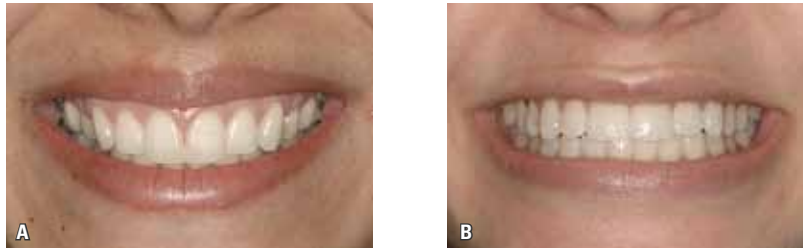

FIGURE 7 - **A)** Smile arc parallel to curvature formed by the lower lip during smile, giving it a young look. **B)** Flat smile arc due to excessive labial inclination of maxillary teeth.

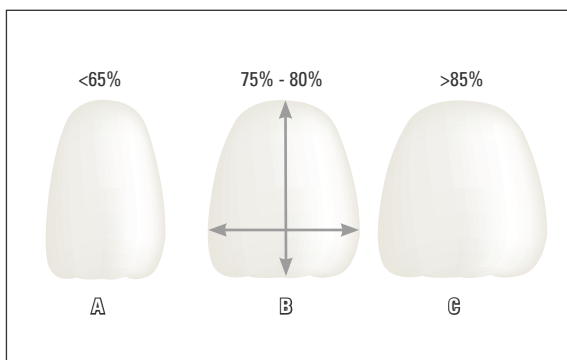


FIGURE 8 - Upper central incisors with different proportions, indicating that teeth are: **A)** Narrow and long, **B)** Proportional, **C)** Short and square.

be instructed to articulate phrases formed by phonemes that induce greater incisor exposure⁸ such as the following sentence (in Brazilian Portuguese): “Tia Ema torce pelo time do Corinthians,” followed by a broad, spontaneous smile, as exemplified at www.dentalpress.com.br/journal.

The following factors are related to increased exposure of the upper incisors at rest: Upper incisor extrusion, dolichocephalic facial pattern, vertical maxillary excess and a short upper lip. When treatment planning involves maxillary impaction and/or intrusion of anterosuperior teeth, the magnitude of dentoskeletal change should not be based on the amount of gingival display one wishes to decrease, but rather on the degree of incisor exposure (at rest) that one wishes to maintain. Patients whose esthetics can benefit from upper incisor intrusion do not usually pose a significant

challenge to the orthodontic or surgical planning of GS correction (Figs 3 A, B and C). On the other hand, patients who exhibit adequate incisor exposure during rest and speech require more careful planning (Figs 4 A, B and C).^{11,14}

3. Smile arc

The term smile arc is defined as the curvature formed by the incisal edges of anterosuperior teeth. To be considered an esthetic and youthful smile, this curvature must be parallel to the superior margin of the lower lip (Fig 7A).¹⁵ Women’s smiles feature a sharper curvature, whilst in men the curvature appears more flat. In individuals with brachycephalic facial pattern, the smile arc is flatter than in meso- and dolichocephalic individuals.¹¹

In some patients with GS maxillary incisor intrusion can be performed. However, failure to assess the smile arc can result in inappropriate flattening of its curvature, rendering it less attractive.^{16,17}

4. Width/length ratio of maxillary incisors

Cosmetic dentistry provides pertinent information regarding tooth proportions and morphology. According to some authors, it is of paramount importance that smile proportions conform to the face.^{17,18,19} The ratio known as “gold standard” determines that the width of the maxillary incisors should be approximately 80% of its length (Fig 8), with acceptable variations between 65% and 85%, whereas for upper lateral incisors that same ratio should be around 70%.^{17,18,19}

A high width/length ratio (W/L) is often found in squared teeth, while lower ratios are associated with a more elongated appearance. Prosthetic dentistry concepts determine that the proportions and morphology of upper central incisor crowns should be in harmony with the patient's facial pattern.^{12,18,19}

In subjects with GS, it is important to assess whether the crowns of anterior teeth appear very short. If this is the case, the next step is to establish the reason for such shortness, which may occur primarily for two reasons:

A) Reduction in height of the incisal edges of upper teeth by friction and/or fracture

In these cases, as incisors extrude so do their periodontal attachment and support. This process, called "compensatory tooth extrusion,"²⁰ may be responsible for excessive gingival display during smile. On periodontal probing, these teeth show normal gingival sulcus depth, and treatment can be accomplished through periodontal surgery with

prosthetic rehabilitation, or orthodontics associated with restorative dentistry.

- Clinical crown lengthening surgery with osteotomy

In view of the fact that this procedure induces exposure of the root surface and requires additional restorative treatment, it should be thoroughly discussed with the patient (Fig 9). Moreover, due to the tapering of tooth roots, prosthetic crowns will tend to acquire a more triangular shape, making it hard to achieve satisfactory interproximal esthetics. The emergence of "black spaces" after surgery is not uncommon. The advantage of this approach includes shorter treatment time and no need for fixed orthodontic appliances. On the downside, there is a decrease in crown/root ratio, loss of bone support and need for prosthetic restoration of the teeth involved.^{12,18,19,20}

- Orthodontic intrusion and subsequent restoration of tooth proportions using restorative dentistry procedures (Fig 10).¹⁷

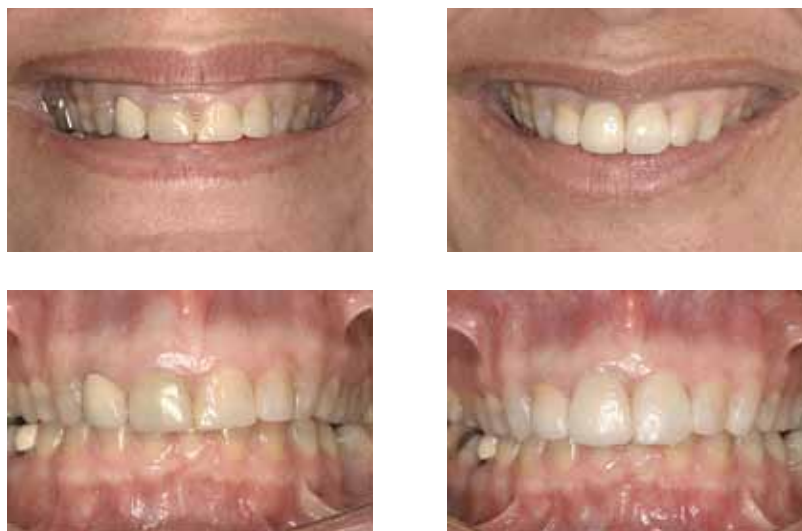

FIGURE 9 - Case of compensatory tooth extrusion whose chief complaint was small size of maxillary central incisors. At patient's request, surgical lengthening of clinical crowns of teeth 11 and 21 was performed and new porcelain crowns fabricated.

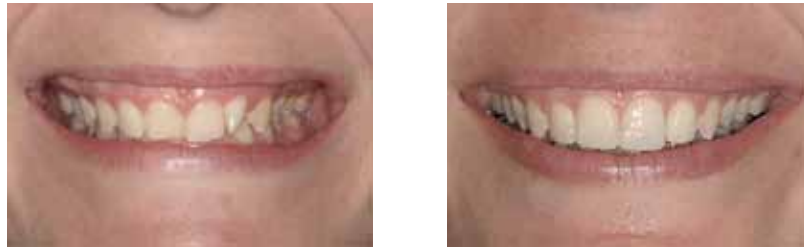

FIGURE 10 - Compensatory dental extrusion of teeth 11 and 21, treated with orthodontic intrusion and provisional restoration of incisal thirds with composite.

B) Gingival overgrowth

The etiologic factors behind gingival overgrowth are diverse, ranging from tissue hypertrophy due to infection and/or medication, to altered passive eruption.^{20,21} The process of tooth eruption is deemed completed when teeth reach the occlusal plane and go into function. The soft tissues follow this trend and ultimately the gingival margin migrates apically almost as far as the cemento-enamel junction (CEJ). This whole process is called passive eruption. When, for reasons hitherto unknown, the gingiva fails to migrate to its expected position, this condition is named altered passive eruption. If, on periodontal probing, these teeth exhibit increased values of gingival sulcus depth, such situation constitutes a clear indication that the patient should be referred to a periodontist to treat his/her gummy smile (Fig 11).^{20,21} Normally, the lengthening of incisor crowns is accomplished by removing excess gingival tissue

overlying the cervical enamel. When the distance between alveolar bone crest and CEJ is less than 1 mm (insufficient for adaptation of connective tissue attachment), osteotomy is necessary to establish accurate biological distances.²¹

5. Morphofunctional characteristics of the upper lip

The lips play a pivotal role in facial expression, especially in the act of smiling, whose variations are related to the morphofunctional features of the lip, such as: Length, thickness and insertion, direction and contraction of various lip-related muscle fibers.²²

As regards length, the average value for men's upper lip is 24 mm and for women, 20 mm.²³ It may seem that individuals with a short upper lip display more gingiva when smiling, but lip length is probably not directly related to a gummy smile.¹¹ Severe vertical maxillary excess cases, for example,

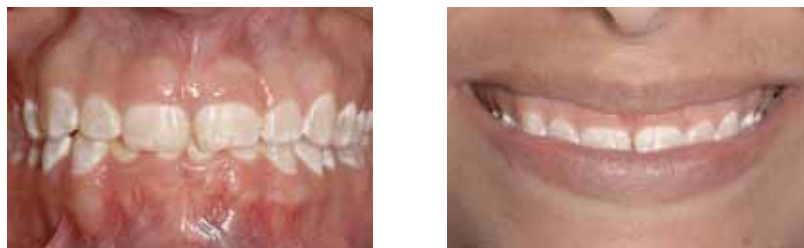

FIGURE 11 - Case of altered passive eruption with short upper incisors and gummy smile.

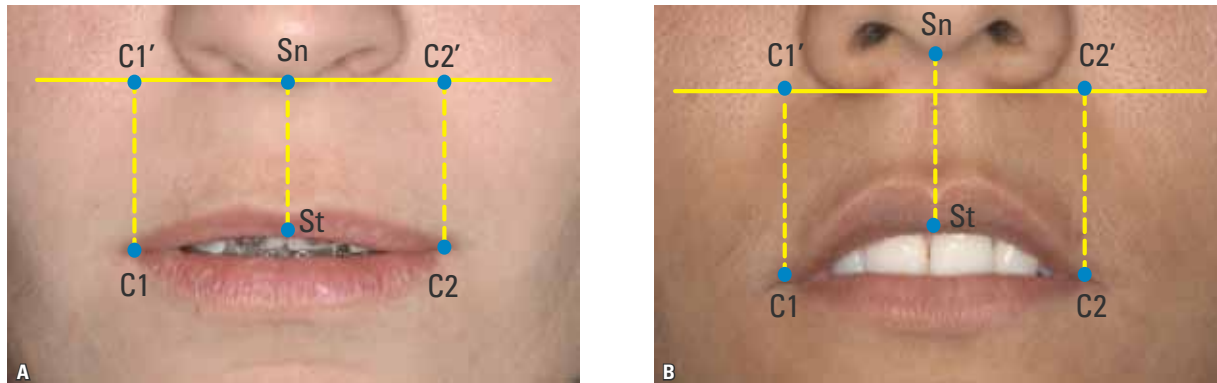


FIGURE 12 - Measurement of upper lip length: **A)** Long upper lip, **B)** short upper lip.

may have an upper lip of normal size or even quite long, which complicates GS correction, as lip length allows little or no incisor intrusion whatsoever.^{11,14}

To assess upper lip length one needs to measure the height of the philtrum and labial commissures. Philtrum height is reflected in the distance between the subnasale (Sn) and Stomion (St) points of the upper lip. In turn, commissure height is obtained by measuring perpendicularly the distance between these structures (C1 and C2) and their projections (C1' and C2') in a horizontal line that joins the two wing bases (Fig 12).

The linear values of these measures are not as important as the relationship between the length of the philtrum and commissures. In children and adolescents, philtrum height is slightly lower than commissure height and this difference can be explained by differential maturation of the lips during growth. Normally, when this happens in adults it causes increased exposure of the incisors during rest and speech (Fig 12B).¹⁴

Thin lips are also known to exhibit greater strain and responsiveness both to dentoalveolar changes and to the contractile pattern of the muscles.^{9,23}

Upper lip mobility, which results from the action of specific muscles, seems to be the main feature to consider in evaluating the soft tissues

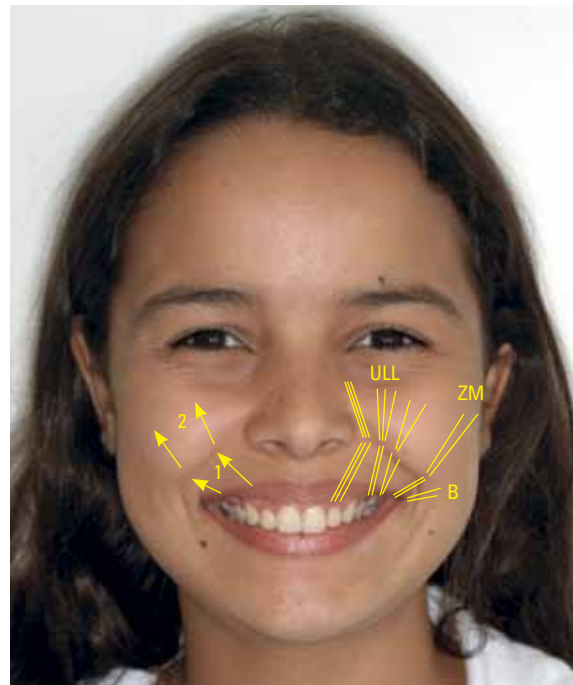


FIGURE 13 - Facial muscles involved in smile dynamics: Upper lip levators (ULL), zygomatic major (ZM) upper fibers of buccinator muscle (B). Stages of a smile: Voluntary smile (1); spontaneous smile (2).

involved in smiling.²⁴⁻²⁸ In addition to the muscle that surrounds the lips internally (orbicularis oris), several other muscle groups influence upper lip movement, i.e.: Levator muscle of upper lip, levator muscle of upper lip and nose wing,

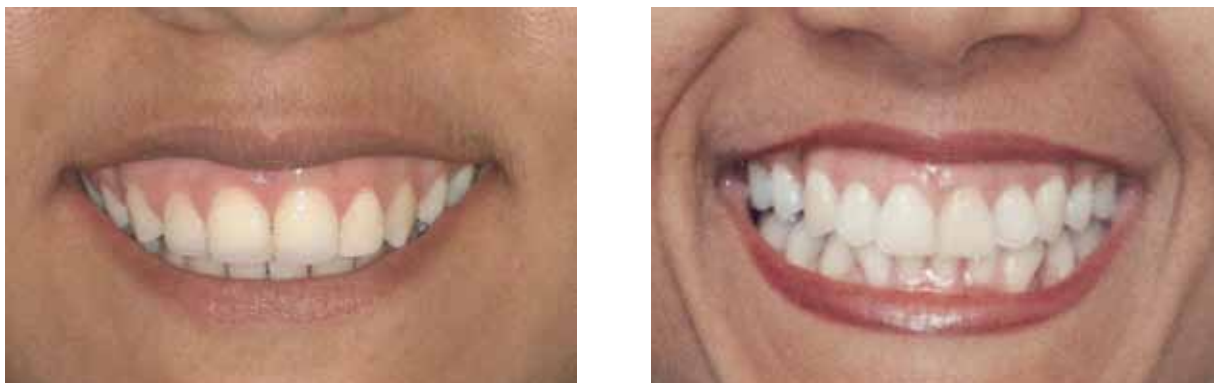

FIGURE 14 - Patients with thin and hyperactive lips are subject to greater gingival display on smiling.

levator muscle of the corner of the mouth, zygomatic major, zygomatic minor, depressor of the nasal septum (Fig 13).¹¹

Smile takes shape in two stages: In the first (voluntary smile) the upper lip is elevated towards the nasolabial sulcus by contraction of the levator muscles, which originate from this sulcus and are inserted into the lips. The medial bundles elevate the lip in the region of the anterior teeth, and the lateral bundles in the region of the posterior teeth until they meet with resistance from the adipose tissue in the cheeks. The second stage (spontaneous smile) starts with a higher elevation of both the lips and the nasolabial sulcus through the agency of three muscle groups: The upper lip levator, which originates from the infraorbital region, the zygomatic major muscle and the superior fibers of the buccinator muscle (Fig 13).^{11,22}

According to the classification of Rubin,²² there are three types of smile: (a) The so-called “Mona Lisa” smile, whereby the labial commissures are displaced upwards through the action of the zygomatic major muscle; (b) the “canine smile,” when the upper lip is elevated in uniform fashion; and finally (c) the “complex smile,” when the upper lip behaves like the “canine smile” and the lower lip moves inferiorly exposing the lower incisors.

Studies show that the upper lip muscles of individuals with GS are considerably more efficient than those with a normal level of gingival display.^{11,24-28}

In GS patients with normal facial proportions, lip length within average limits, marginal gingiva located near the CEJ and normal width-length ratio, etiology may be associated with hyperactivity of the muscles that move the upper lip during smile. A non-hyperactive lip moves approximately 6 mm to 8 mm from a resting position to a broad smile. On the other hand, a hyperactive upper lip moves a distance 1.5 to 2 times greater (Fig 14).²³ For these cases, some cosmetic procedures are available which have been studied in patients with facial paralysis since 1973.²⁷ Among these, silicone implantation at the bottom of the vestibule at the base of the anterior nasal spine, infiltration of botulinum A toxin and resective procedures in the muscles responsible for upper lip mobility produce satisfactory esthetic results.²⁴⁻²⁷

Cost-effectiveness, considering the durability, safety and low morbidity of these procedures, must be analyzed by orthodontists before this approach is safely and more often suggested to patients.

USING THE CHECKLIST

Clinical Case 1

The patient, a 13-year-old girl, reported as chief complaint the reduced size of her maxillary incisors and presented with the following characteristics: Facial thirds with balanced proportions, slightly convex profile, mild mandibular retrusion, competent lip seal, moderate GS, Angle Class I malocclusion with slight extrusion of upper incisors and excessive overbite (Fig 15).

Checklist assessment (Fig 16) revealed interlabial space, exposure of upper incisors at rest and normal morphofunctional upper lip, as well as appropriate smile arc curvature. A low width/length ratio of maxillary incisors was the only

feature assessed as unfavorable. (Fig 17). Initial periodontal probing of these teeth showed increased values of gingival sulcus depth, suggesting a state of altered passive eruption.

Orthodontic treatment was performed without extraction and, after further probing during the finishing phase, gingivectomy was indicated across the entire anterosuperior region (Fig 18). This procedure achieved a better width/length ratio of maxillary incisors and reduced gingival display (Figs 19 and 20). The patient's smile benefited from increased aesthetics and improved dental proportions, preserving incisor exposure at rest and a pleasant smile arc curvature (Figs 20 and 21).

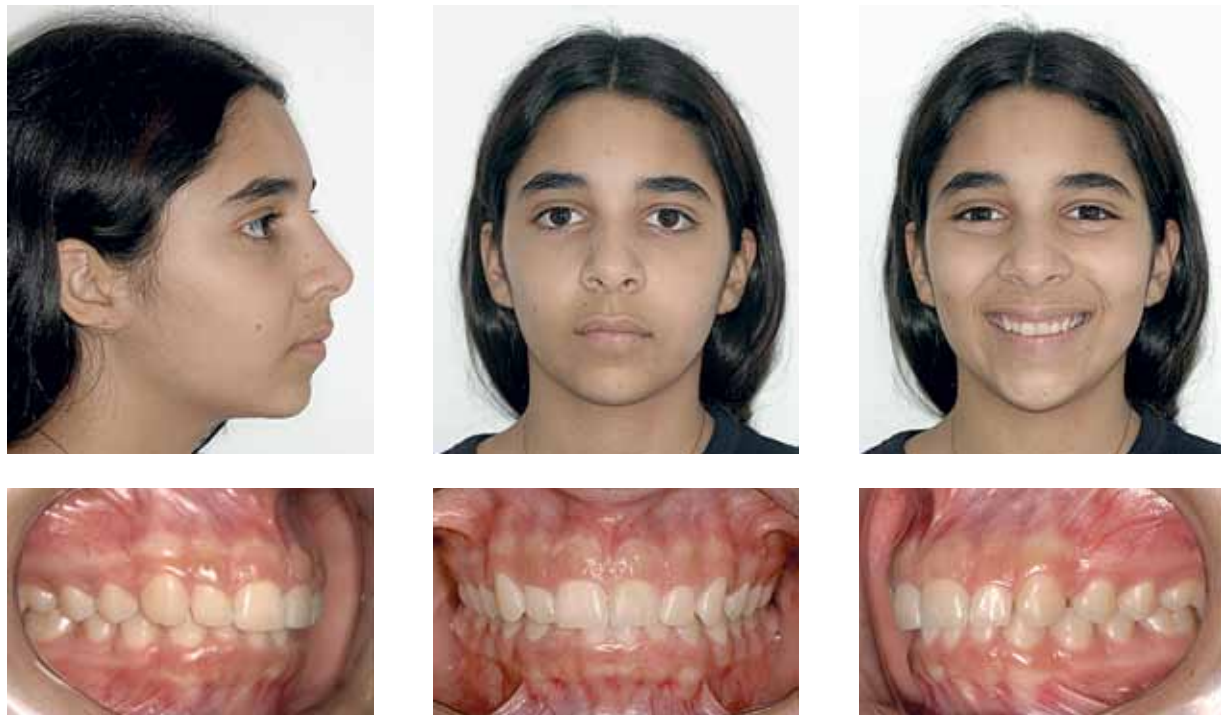

FIGURE 15 - Clinical case 1 – Initial facial and dental aspects.

Interlabial Distance at rest	Exposure of upper incisors at rest	Smile arc	W/L ratio of maxillary incisors	Morphofunctional features of upper lip
1-3 mm <input checked="" type="checkbox"/>	<1 mm <input type="checkbox"/>	Pleasant <input checked="" type="checkbox"/>	<65% <input type="checkbox"/>	Short <input type="checkbox"/>
>3 mm <input type="checkbox"/>	1-4.5 mm <input checked="" type="checkbox"/>	Flat <input type="checkbox"/>	75-80% <input type="checkbox"/>	Thin <input type="checkbox"/>
	>4.5 mm <input type="checkbox"/>	Reverse <input type="checkbox"/>	>85% <input checked="" type="checkbox"/>	Hypermobility <input type="checkbox"/>

FIGURE 16 - Clinical case 1 checklist.

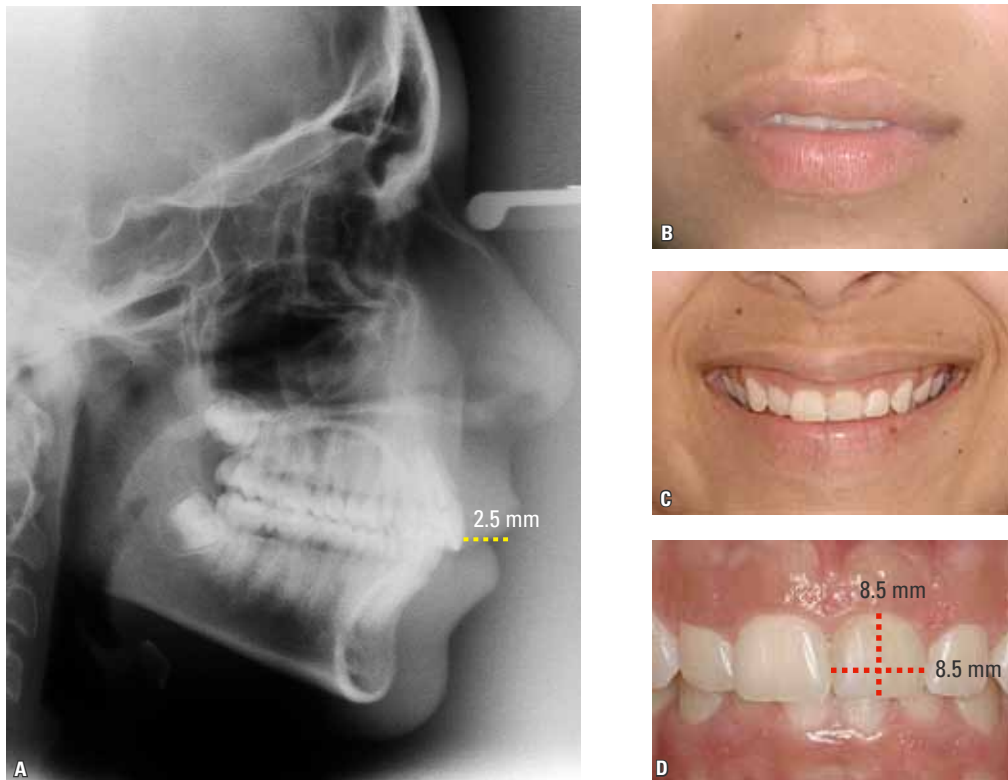


FIGURE 17 - Checklist features evaluated: **A)** Exposure of upper incisors at rest; **B)** interlabial distance at rest and morphological characteristics of upper lip; **C)** smile arc and functional characteristics of upper lip; **D)** Width/Length ratio of upper incisors.

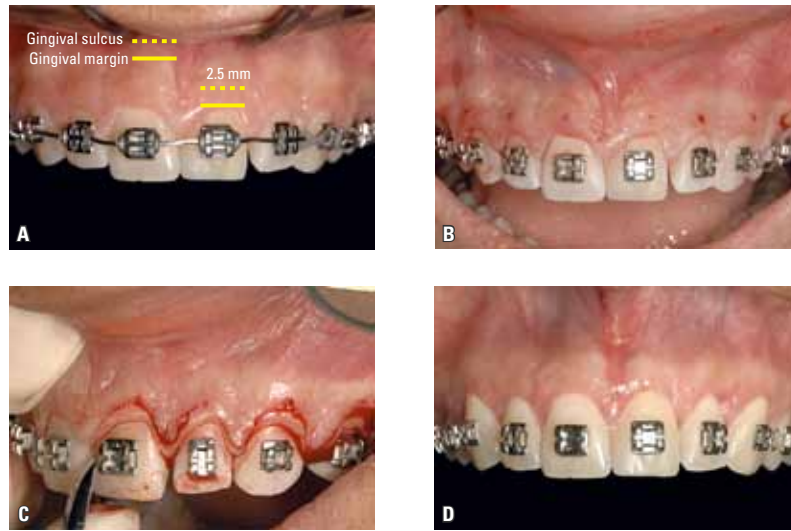


FIGURE 18 - **A** and **B**) Results of periodontal probing during finishing phase of treatment. **C**) Gingivectomy performed in upper arch. **D**) Gingival appearance one week after surgery.

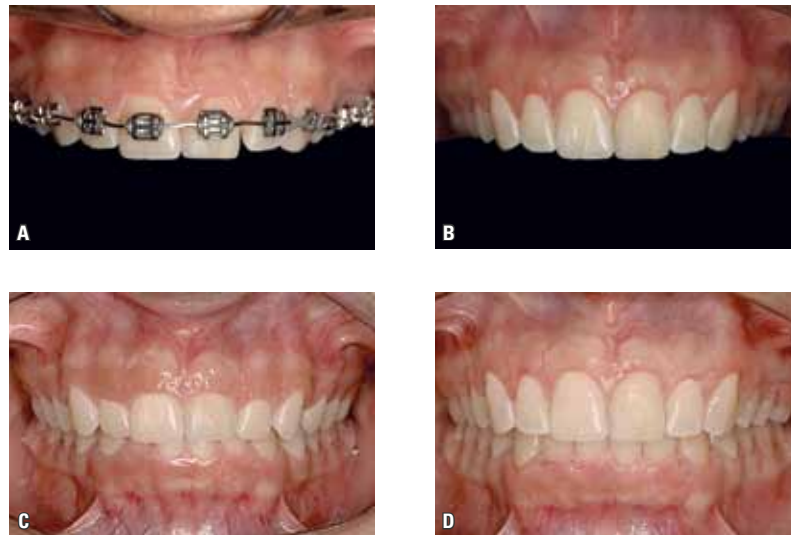


FIGURE 19 - **A** and **B**) Improved width/length ratio of anteriors teeth in close up view. **C** and **D**) Impact of gingivectomy on esthetic appearance of occlusion.

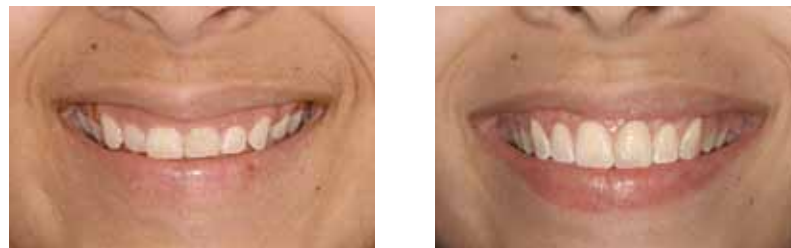

FIGURE 20 - Initial and final close up photos of smile, showing removal of maxillary gingival excess.



FIGURE 21 - Change in smile aesthetics between initial and final phases of treatment.

Clinical Case 2

The patient, an 18-year-old girl, reported as chief complaint the reduced size of her maxillary incisors and excessive maxillary gingival display, presenting with the following characteristics: Facial thirds with balanced proportions, straight profile, GS, Angle Class I malocclusion

with extrusion of maxillary incisors and excessive overbite (Fig 22).

Checklist assessment (Fig 23) revealed normal interlabial space and upper incisor exposure at rest as well as pleasant looking smile arc. The low width/length ratio of maxillary incisors and hypermobility of the upper lip on smiling were

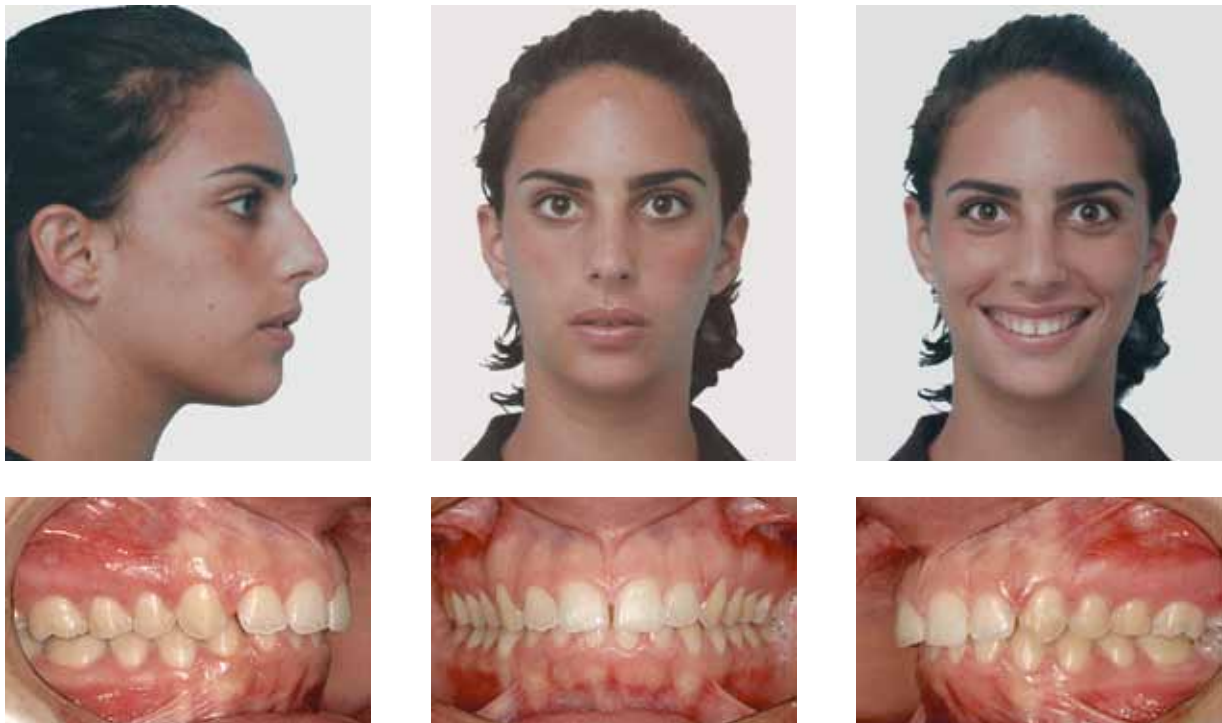

FIGURE 22 - Clinical case 2 – Initial facial and dental aspects.




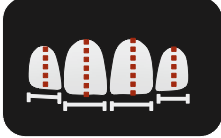

Interlabial Distance at rest	Exposure of upper incisors at rest	Smile arc	W/L ratio of maxillary incisors	Morphofunctional features of upper lip
				
1-3 mm <input checked="" type="checkbox"/>	<1 mm <input type="checkbox"/>	Pleasant <input checked="" type="checkbox"/>	<65% <input type="checkbox"/>	Short <input type="checkbox"/>
>3 mm <input type="checkbox"/>	1-4.5 mm <input checked="" type="checkbox"/>	Flat <input type="checkbox"/>	75-80% <input type="checkbox"/>	Thin <input type="checkbox"/>
	>4.5 mm <input type="checkbox"/>	Reverse <input type="checkbox"/>	>85% <input checked="" type="checkbox"/>	Hypermobility <input checked="" type="checkbox"/>

FIGURE 23 - Clinical case 2 checklist.

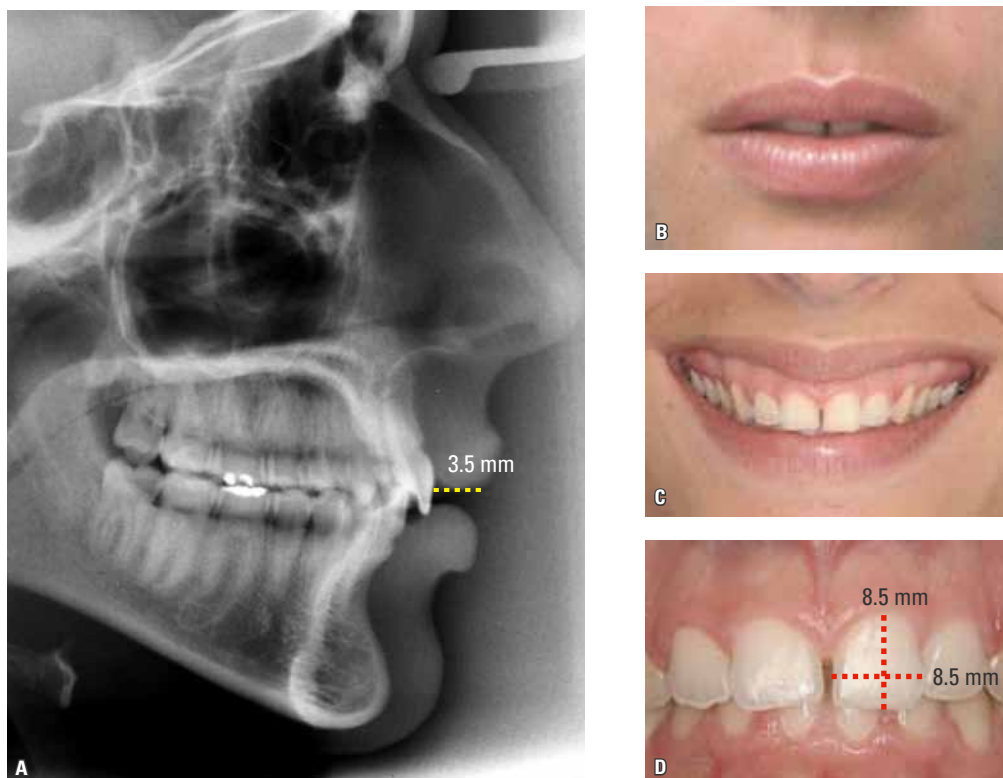


FIGURE 24 - Checklist features evaluated: **A)** Exposure of upper incisors at rest; **B)** interlabial distance at rest and morphological characteristics of upper lip; **C)** smile arc and functional characteristics of upper lip; **D)** Width/Length ratio of upper incisors.

regarded as negative features (Fig 24).

Initial periodontal probing showed increased values of gingival sulcus depth, suggesting a state of altered passive eruption associated with upper lip hypermobility. These two factors contributed substantially to increased gingival exposure in

the anterior and posterior regions of the smile.

Corrective orthodontic treatment was performed without extractions. In the final phase, after further periodontal probing, gingivectomy was performed to eliminate gingival pseudopockets present throughout the anterosu-

perior region (Fig 25). Composite restorations on the incisal edges of teeth 12, 11, 21 and 22 helped smoothen the incisal profile, which combined with an adequate width/length ratio of maxillary incisors to improve smile esthet-

ics (Fig 26). Despite a certain degree of gingival display still present due to hypermobility of the upper lip, the esthetic outcome of the treatment was rated as satisfactory by the patient (Figs 27 and 28).

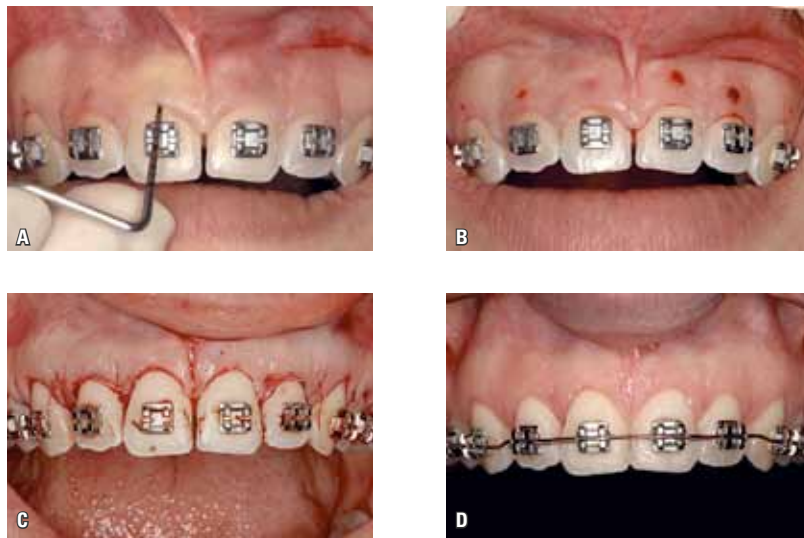


FIGURE 25 - **A** and **B**) Periodontal probing during finishing phase of treatment. **C**) Gingivectomy performed in upper arch. **D**) Gingival appearance one week after surgery.

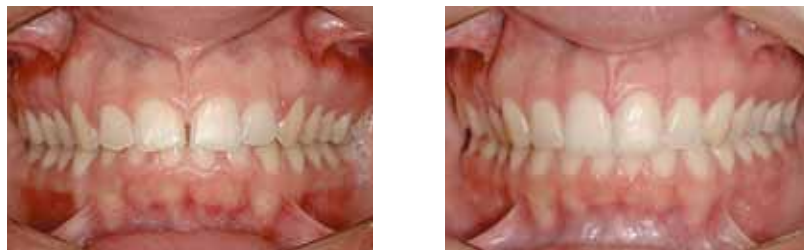

FIGURE 26 - Impact of gingivectomy on width/length ratio of anteriorsuperior teeth and on esthetic appearance of occlusion. Provisional composite restorations were performed to smoothen upper incisal silhouette.

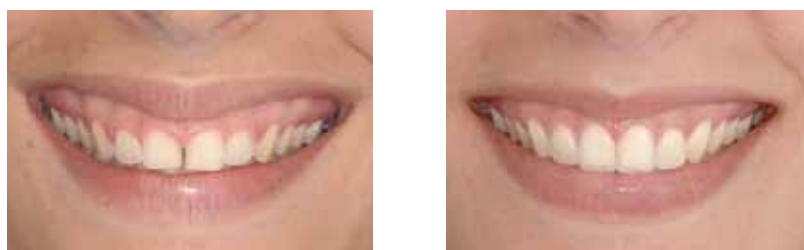

FIGURE 27 - Initial and final photos of smile, showing removal of maxillary gingival excess.



FIGURE 28 - Change in smile esthetics between initial and final phases of treatment.

Clinical Case 3

The patient, a 21-year-old woman, reported as chief complaint dental crowding and excessive upper gingival display, and exhibited the following characteristics: Facial thirds with balanced proportions, slightly concave profile, competent

lip seal, GS, Angle Class I malocclusion, excessive overbite, extrusion and lingual inclination of maxillary central incisors (Fig 29).

Checklist assessment (Fig 30) revealed normal interlabial space and pleasant smile arc. Normal exposure of the upper central incisors at rest, low

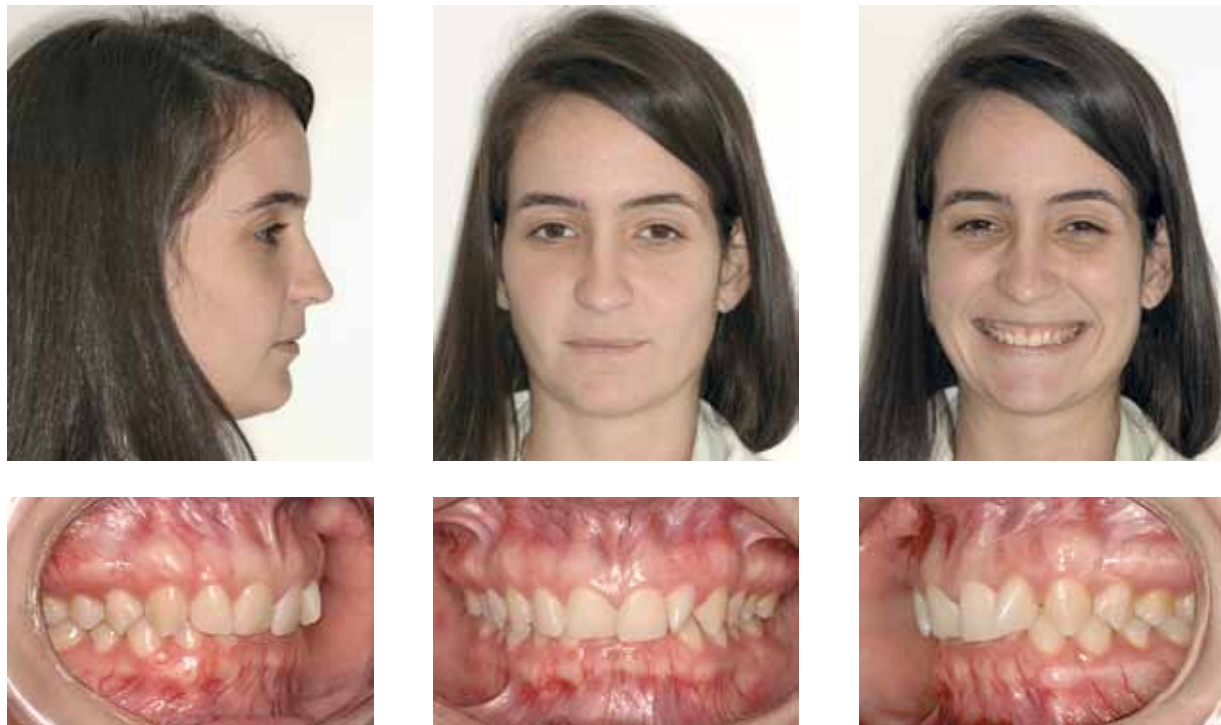

FIGURE 29 - Clinical case 3 – Initial facial and dental aspects.




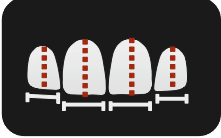

Interlabial Distance at rest	Exposure of upper incisors at rest	Smile arc	W/L ratio of maxillary incisors	Morphofunctional features of upper lip
				
1-3 mm <input checked="" type="checkbox"/>	<1 mm <input type="checkbox"/>	Pleasant <input checked="" type="checkbox"/>	<65% <input type="checkbox"/>	Short <input type="checkbox"/>
>3 mm <input type="checkbox"/>	1-4.5 mm <input checked="" type="checkbox"/>	Flat <input type="checkbox"/>	75-80% <input type="checkbox"/>	Thin <input checked="" type="checkbox"/>
	>4.5 mm <input type="checkbox"/>	Reverse <input type="checkbox"/>	>85% <input checked="" type="checkbox"/>	Hypermobility <input checked="" type="checkbox"/>

FIGURE 30 - Clinical case 3 checklist.

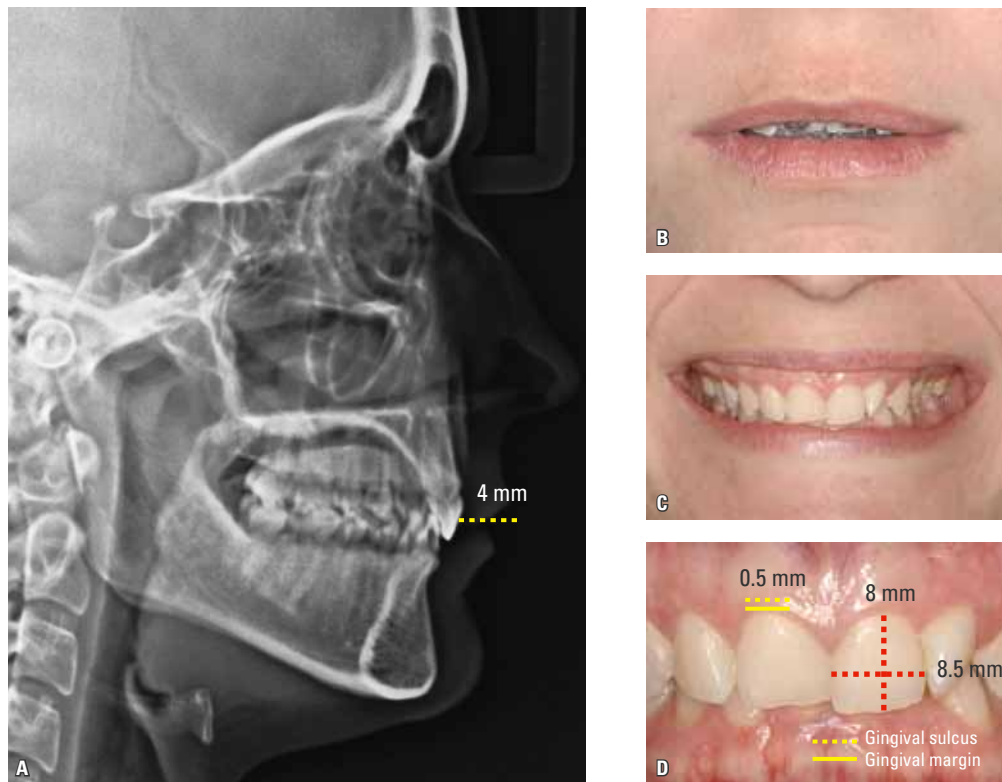


FIGURE 31 - Checklist features evaluated: **A)** Exposure of upper incisors at rest; **B)** interlabial distance at rest and morphological characteristics of upper lip; **C)** smile arc and functional characteristics of upper lip; **D)** Width/Length ratio of upper incisors, whose probing depth appeared normal.

length/width ratio of these teeth and upper lip hypermobility were considered as unfavorable features. Initial periodontal probing disclosed normal gingival sulcus depth. Incisal edge wear of maxil-

lary central incisors was observed, which led to a diagnosis of compensatory tooth extrusion (Fig 31).

Total corrective orthodontic treatment was performed without extractions, with intrusion

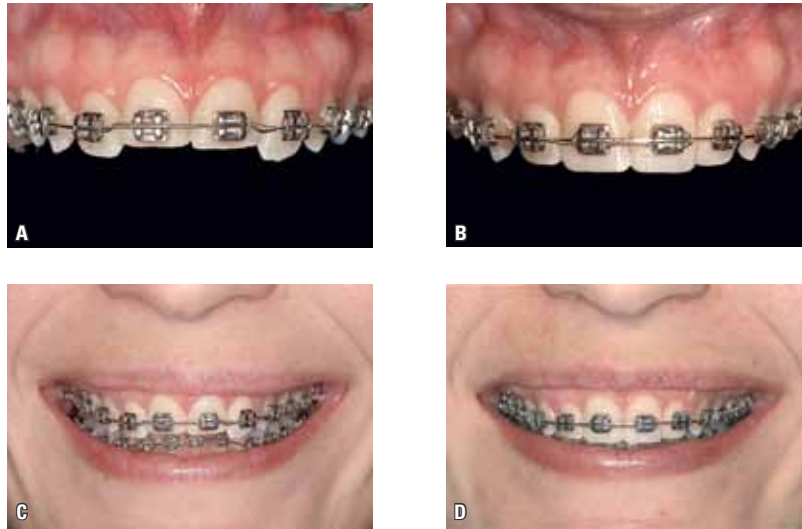


FIGURE 32 - **A and C)** Orthodontic intrusion of maxillary central incisors. **B and D)** Provisional restoration of incisal third of units 11 and 21 and ameloplasty to smoothen incisal edge height of teeth 12 and 22.

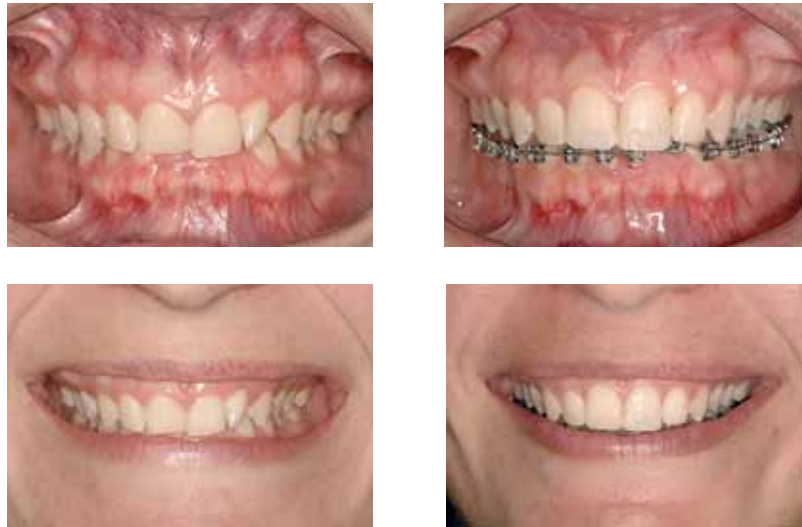

FIGURE 33 - Width/Length ratio of maxillary central incisors restored, providing dominance and prominence to these teeth and decreased maxillary gingival excess on smiling.

and correction of upper central incisor lingual inclination. After leveling the upper arch, the incisal edges of teeth 12 and 22 were smoothened through ameloplasty and units 11 and 21 were restored temporarily with composite (Fig 32).

This approach improved the width/length ratio and preserved upper incisor exposure at rest. Some small gingival exposure still remained due to lip hypermobility but not enough to compromise final smile esthetics (Figs 33 and 34).



FIGURE 34 - Change in smile esthetics between initial, intermediate and final phases of treatment.

Clinical Case 4

The patient, a 36-year-old woman, reported as chief complaint the presence of spaces in the first premolar region and showed the following characteristics: Facial thirds with balanced proportions, slightly convex profile, adequate lip seal, GS, Angle Class I

malocclusion, residual spaces resulting from first premolar extractions, extruded and lingually inclined upper incisors and excessive overbite (Fig 35).

Checklist assessment (Fig 36) revealed: Interlabial space and increased exposure of upper incisors at rest, pleasant smile arc (with pronounced

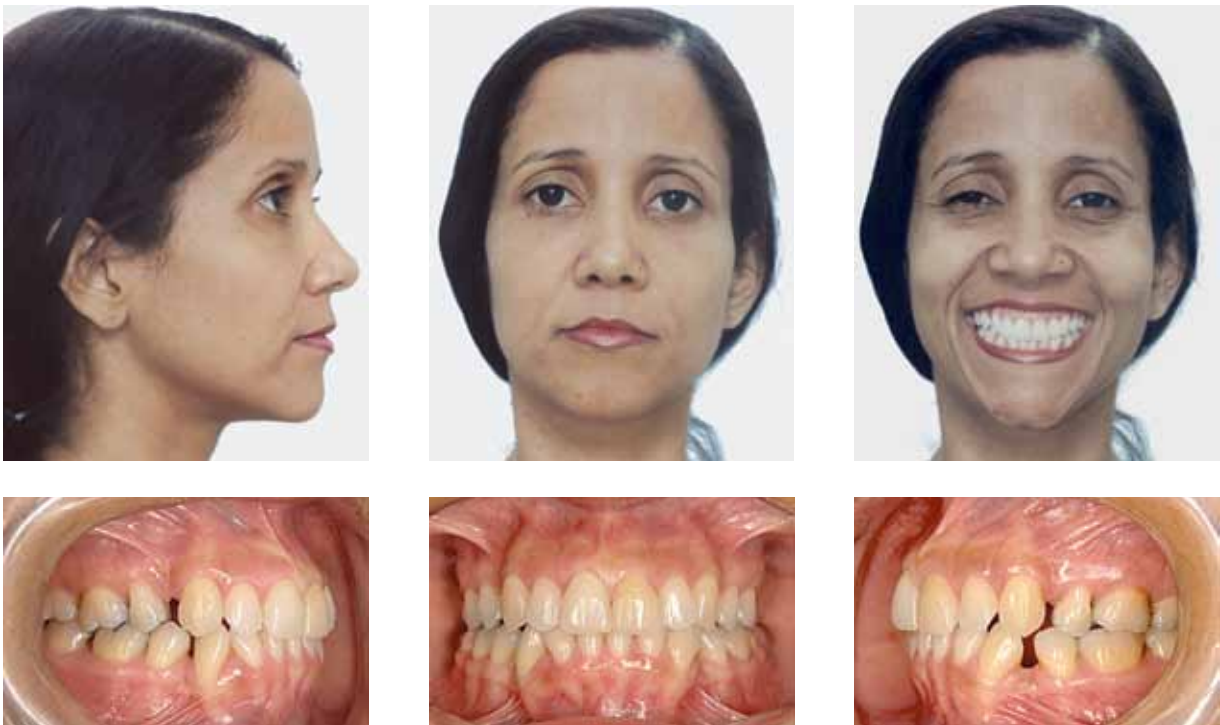

FIGURE 35 - Clinical case 4 – Initial facial and dental aspects.

Interlabial Distance at rest	Exposure of upper incisors at rest	Smile arc	W/L ratio of maxillary incisors	Morphofunctional features of upper lip
1-3 mm <input type="checkbox"/>	<1 mm <input type="checkbox"/>	Pleasant <input checked="" type="checkbox"/>	<65% <input type="checkbox"/>	Short <input checked="" type="checkbox"/>
>3 mm <input checked="" type="checkbox"/>	1-4.5 mm <input type="checkbox"/>	Flat <input type="checkbox"/>	75-80% <input checked="" type="checkbox"/>	Thin <input checked="" type="checkbox"/>
	>4.5 mm <input checked="" type="checkbox"/>	Reverse <input type="checkbox"/>	>85% <input type="checkbox"/>	Hypermobility <input checked="" type="checkbox"/>

FIGURE 36 - Clinical case 4 checklist.

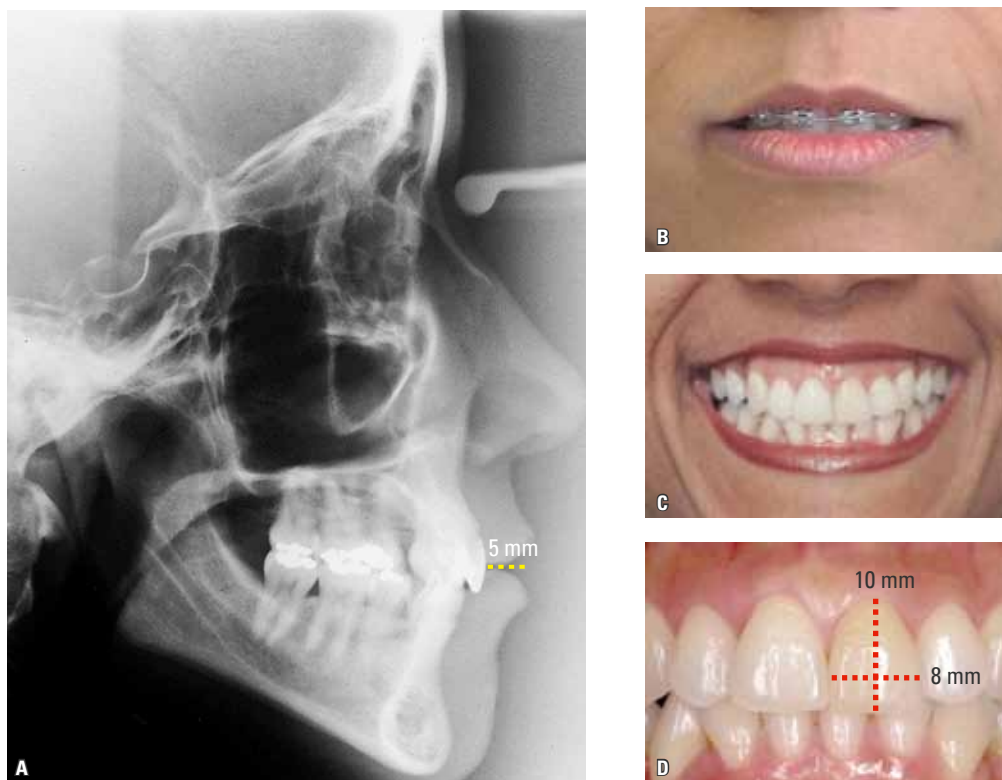


FIGURE 37 - Checklist features evaluated: **A)** Exposure of upper incisors at rest; **B)** interlabial distance at rest and morphological characteristics of upper lip; **C)** smile arc and functional characteristics of upper lip; **D)** Width/Length ratio of upper incisors.

curvature) and a short and thin upper lip with hypermobility. Upper incisor length/width ratio was satisfactory (Fig 37).

Dental alignment and leveling, correction of axial inclination of the incisors, canines and second premolars and space closure with retraction

of anterior teeth were performed during orthodontic treatment (Figs 38 and 39, and Table 1). Although part of the checklist points to the possibility of intrusion of the upper teeth, any attempt to correct excessive gingival display by this means could cause undesirable flattening of the smile arc.

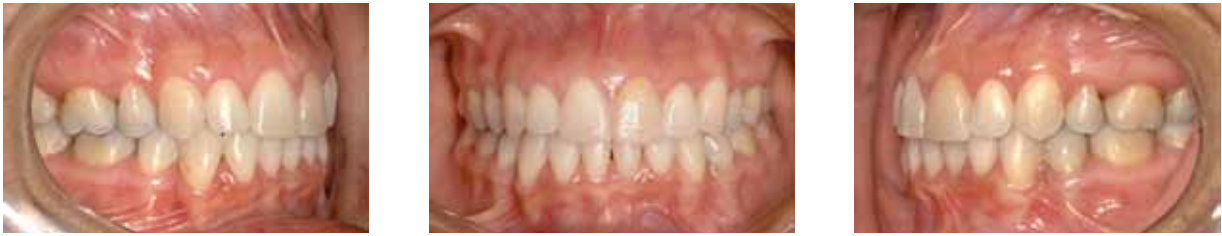

FIGURE 38 - Front and side views of final occlusion, showing provisional restorations of incisal edges of maxillary central incisors.

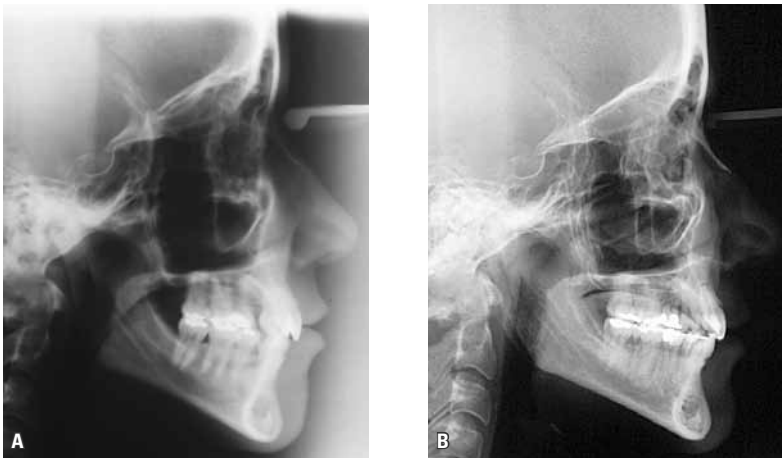


FIGURE 39 - Comparison between initial (A) and final (B) cephalometric radiographs, showing dental changes due to treatment.

TABLE 1 - Comparison of initial and final cephalometric measurements (case #4).

	Initial	Final
SNA	78°	78°
SNB	76°	76°
ANB	2°	2°
GoGn-SN	39°	39°
IMPA	80°	95°
1-NA	21°	18°
1-NB	15°	32°
1-NA	5 mm	5 mm
1-NB	5 mm	4 mm
Ls - S Line	0 mm	-2 mm
Li - S Line	1 mm	-0.5 mm

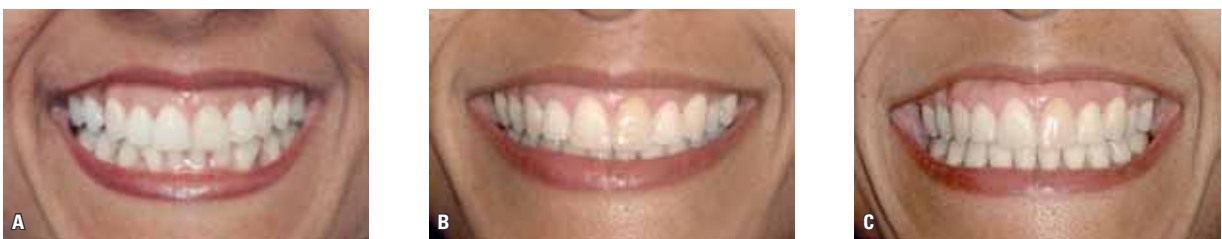

FIGURE 40 - A) Complex smile with high lip mobility. B) Voluntary smile after treatment. C) Maintenance of gingival display during spontaneous smile after treatment.

Therefore, leveling of upper teeth demanded special care. The morphofunctional characteristics of the upper lip—thin, short and with hypermobility—produced a complex smile and posed a major obstacle to the orthodontic treatment of excessive gingival display.

The upper incisal silhouette was restored through cosmetic dental remodeling. Ameloplasty

of the incisal edges of teeth 12 and 22 was performed and, additionally, composite was provisionally added to the incisal edges of teeth 11 and 21.

Despite improved smile esthetics in terms of dental position, gingival display was virtually maintained to ensure that the orthodontic approach would be consistent with the contemporary treatment paradigm (Figs 40 and 41).

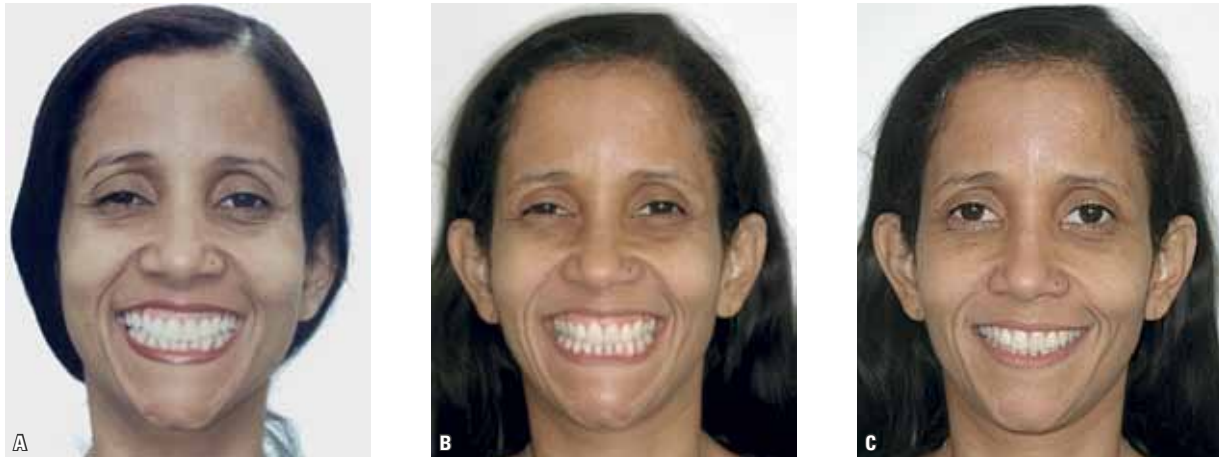

FIGURE 41 - **A)** Initial smile. **B)** and **C)** Spontaneous smile and voluntary smile, respectively, after treatment.

Clinical Case 5

The patient, a 25-year-old woman, reported as chief complaint dentoalveolar bimaxillary protrusion and incompetent lip seal, and exhibited the following characteristics: Increased lower face, convex profile, incompetent lip seal,

GS, Angle Class I malocclusion and pronounced dentoalveolar bimaxillary protrusion (Fig 42).

Checklist assessment (Fig 43) revealed significant changes in some features: There were significantly increased interlabial space and upper incisor exposure at rest, a short upper lip

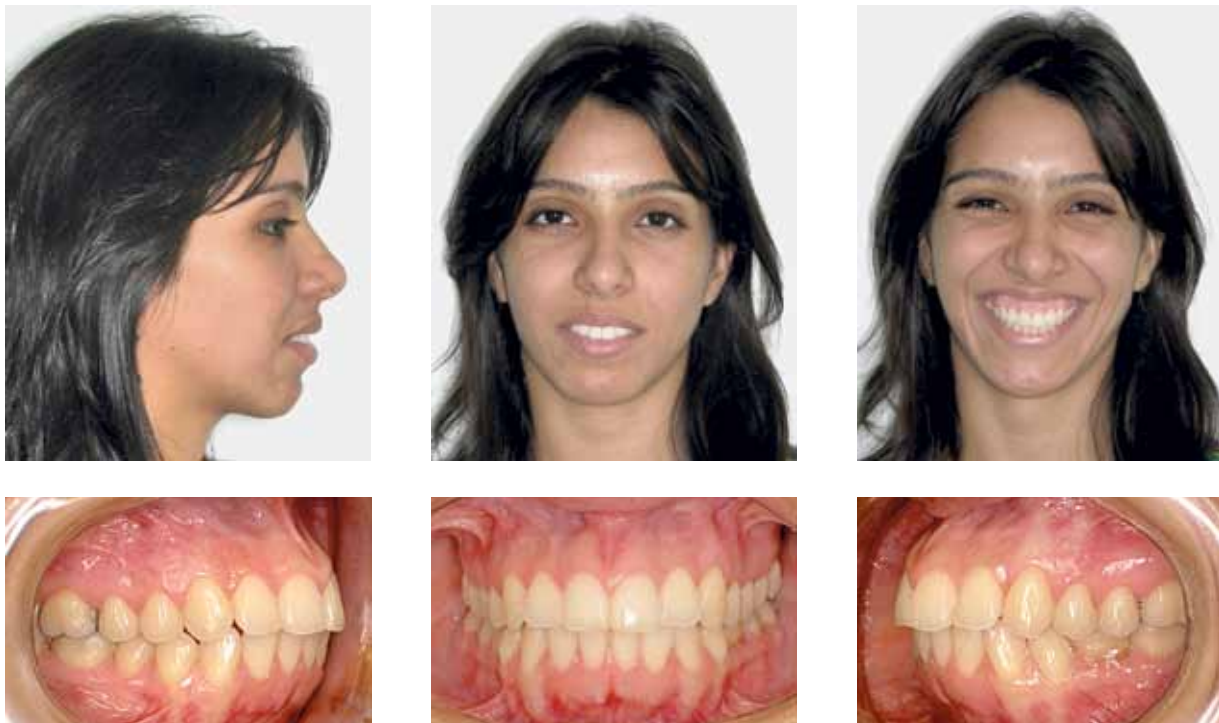

FIGURE 42 - Clinical case 5 – Initial facial and dental aspects.




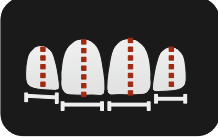

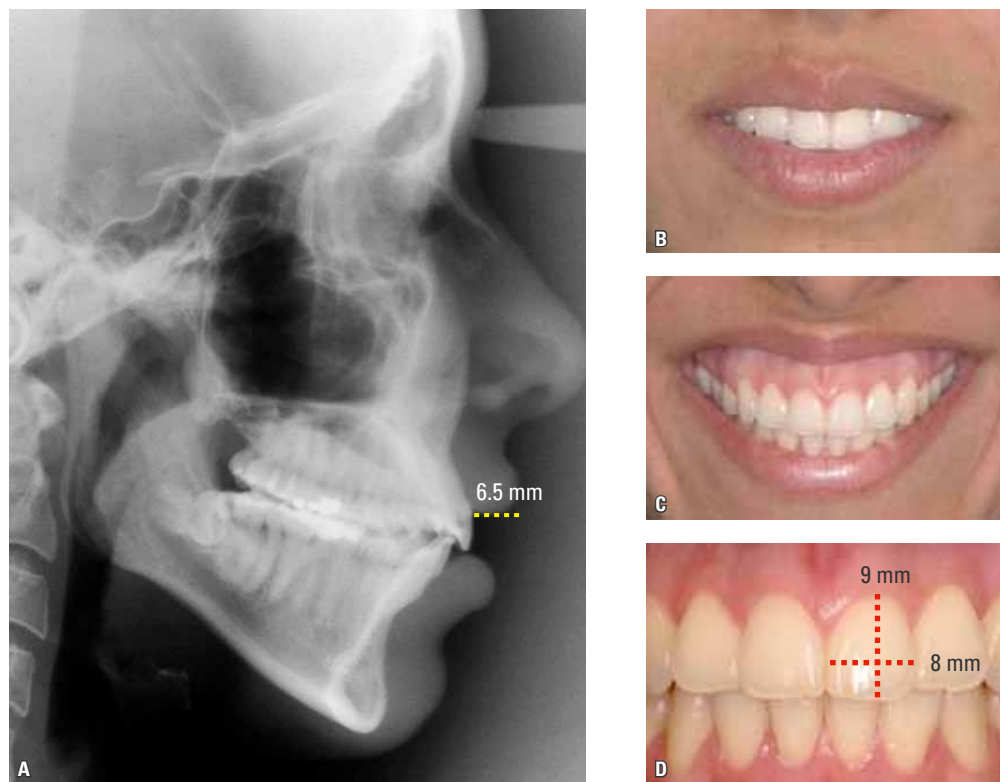
Interlabial Distance at rest	Exposure of upper incisors at rest	Smile arc	W/L ratio of maxillary incisors	Morphofunctional features of upper lip
				
1-3 mm <input type="checkbox"/>	<1 mm <input type="checkbox"/>	Pleasant <input type="checkbox"/>	<65% <input type="checkbox"/>	Short <input checked="" type="checkbox"/>
>3 mm <input checked="" type="checkbox"/>	1-4.5 mm <input type="checkbox"/>	Flat <input checked="" type="checkbox"/>	75-80% <input checked="" type="checkbox"/>	Thin <input type="checkbox"/>
	>4.5 mm <input checked="" type="checkbox"/>	Reverse <input type="checkbox"/>	>85% <input type="checkbox"/>	Hypermobility <input checked="" type="checkbox"/>

FIGURE 43 - Clinical case 5 checklist.

FIGURE 44 - Checklist features evaluated: **A)** Exposure of upper incisors at rest; **B)** interlabial distance at rest and morphological characteristics of upper lip; **C)** smile arc and functional characteristics of upper lip; **D)** Width/Length ratio of upper incisors.

with hypermobility, flat smile arc and adequate width/length ratio of maxillary central incisors, although there was disparity between the size of the central and lateral incisors (Fig 44).

The upper alveolar protrusion—present in Angle Class II, Division 1 malocclusions, and

Angle Class I bimaxillary protrusion—may be related to the gummy smile, a fact long reported in the literature.²⁹ The alveolar “plateau” formed by the maxillary incisors was overly inclined labially, which seemed to cause the muscle of the upper lip to stretch further, pulling the upper

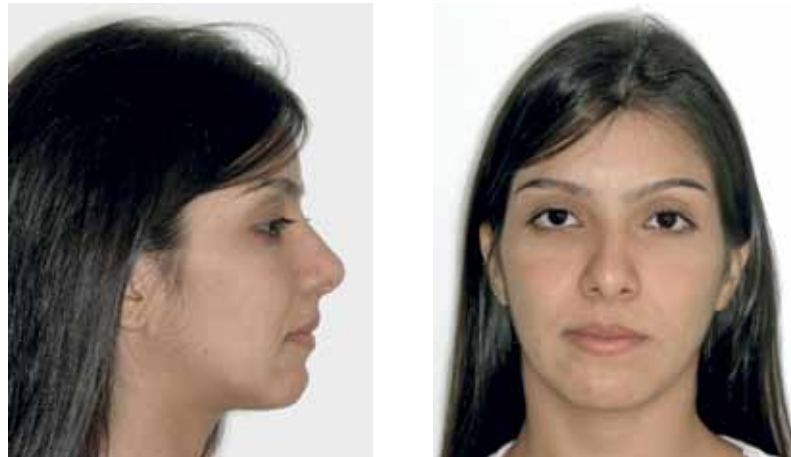

FIGURE 45 - Facial and occlusal appearance after treatment with restoration of incisal edges of teeth 11 and 21.

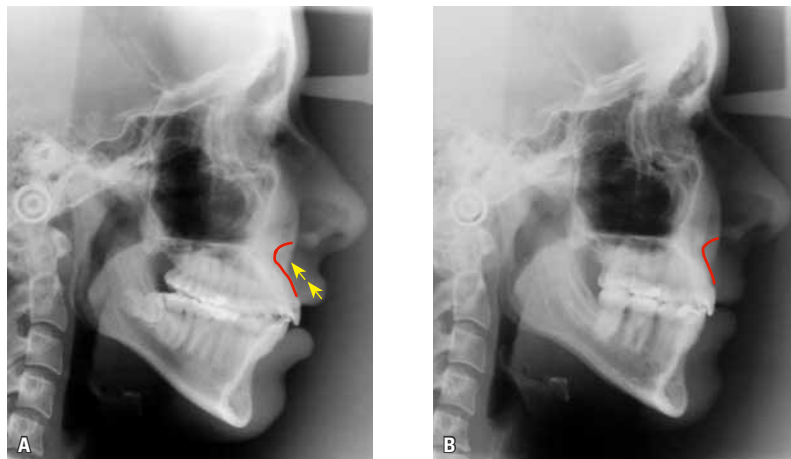


FIGURE 46 - **A**) Presence of deep anterosuperior alveolar sulcus resulting from alveolar protrusion. Arrows indicate direction of displacement of upper lip during smile. Comparison between initial **(A)** and final **(B)** cephalometric radiographs, showing change in anterior alveolar contour due to upper incisor retraction.

TABLE 2 - Comparison between initial and final cephalometric measurements (Case #5).

	Initial	Final
SNA	76°	76°
SNB	72°	74°
ANB	4°	2°
GoGn-SN	45°	42°
IMPA	98°	88°
1-NA	21°	14°
1-NB	37°	23°
1-NA	11 mm	6 mm
1-NB	12 mm	6.5 mm
Ls - S Line	-1 mm	-2.5 mm
Li - S Line	2 mm	-1 mm

lip upward and backward, as it settles in the deepest region of the alveolar process (Fig 46A).

Since the correction of maxillary protrusion often reduces excessive gingival display on smiling, this issue should always be addressed when

planning GS treatment.^{29,30}

Although this is a classic case of vertical maxillary excess with an indication for surgery the patient rejected this option. The only other option would be to reduce gingival display through

orthodontic treatment by reducing the bimaxillary protrusion and the anterosuperior dentoalveolar "plateau." Total corrective treatment was performed with extraction of teeth 14, 24, 75 and 44, incisor retraction and maximum vertical control (Figs 45 and 46, and Table 2).

Correction of bimaxillary protrusion benefited facial esthetics (Fig 45), improved lip competence (Figs 45 and 46) and decreased apical displacement of the upper lip during smile (Fig 47B). A closer view reveals some major changes: Behavior change of upper lip muscles on smiling (evidenced by the elimination of the horizontal sulcus formed between the upper lip and nose base), and improved relationship between the

smile arc and the lower lip (afforded by the fact that the latter was repositioned superiorly and posteriorly) (Fig 47).

With the purpose of improving the leveling of the anterosuperior gingival contour teeth 11 and 21 were intruded and their incisal edges enlarged with composite. To further establish a proportional relationship between upper central and lateral incisors, teeth 12 and 22 underwent interproximal stripping and cosmetic remodeling by rounding of the distolabial angle.

The amount of gingival display still present after treatment completion did not affect the degree of patient satisfaction in terms of dento-facial benefits (Fig 48).

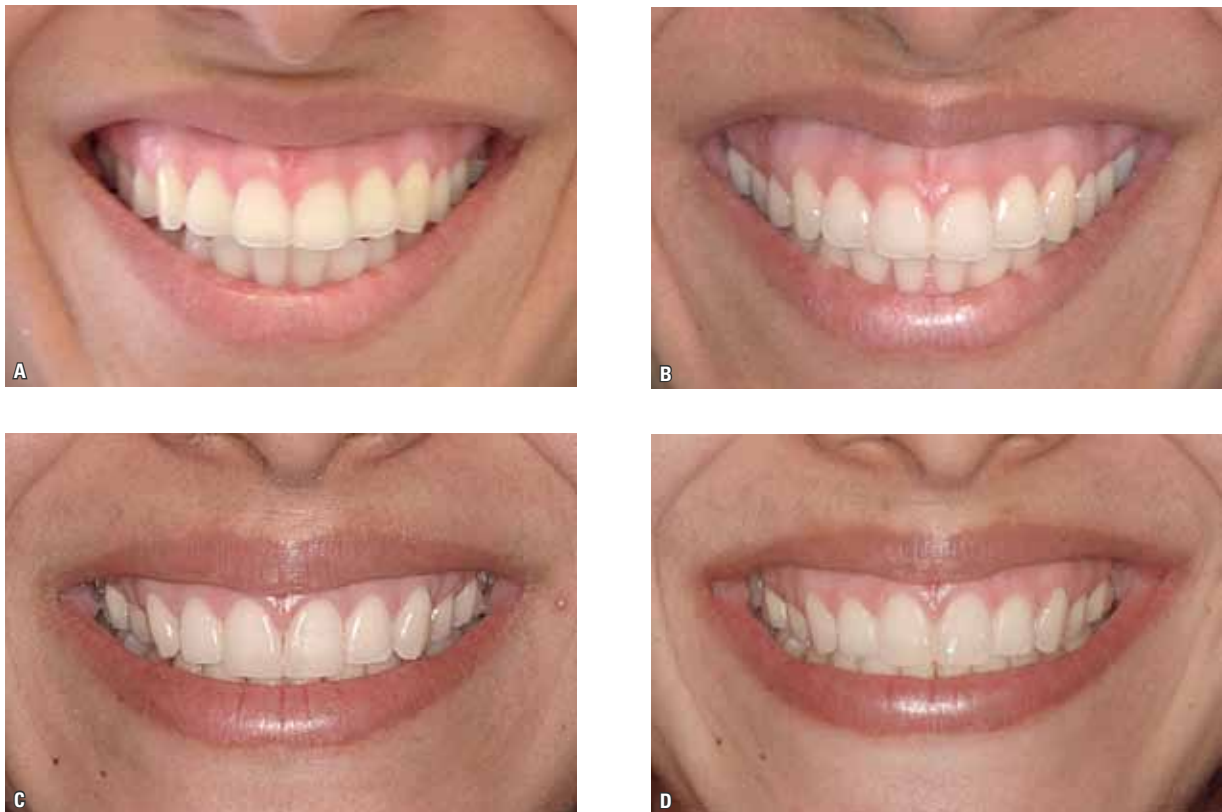

FIGURE 47 - Initial voluntary (A) and spontaneous (B) smiles: Poor ratio between size of upper central and lateral incisors, exposure of lower incisors, pronounced upper gingival display, presence of horizontal sulcus between upper lip and nasal base. Final voluntary (C) and spontaneous (D) smiles: Dominance of upper central incisors, reduction in gingival display and horizontal labial sulcus, reduction in exposure of lower incisors, improvement in relationship between smile arc and lower lip curvature.



FIGURE 48 - Change in smile esthetics between initial and final phases of treatment. Reduction in gingival display resulting from correction of bimaxillary protrusion and decrease in lip hypermobility.

FINAL CONSIDERATIONS

Excessive gingival display on smiling is considered a cosmetic issue that often leads patients to seek orthodontic treatment. Addressing this problem can prove challenging as it involves a wide range of etiological factors which, in most cases, work in concert. To evaluate these cases, orthodontists should analyze the patient's static and dynamic smile, as well as their speech and lip position at rest. In this analysis it is mandatory that the following factors be observed: (a) Interlabial distance, (b) exposure of upper incisors during rest and speech, (c) smile arc, (d) width/length

ratio of maxillary central incisors and (e) morphofunctional characteristics of the upper lip. The checklist advanced in this article can assist in GS diagnosing and planning and may lead to the GS correction within the scope of today's orthodontic treatment paradigm.

ACKNOWLEDGEMENTS

The authors wish to thank Drs. Edmália Barreto (periodontics), Eutímio Torres (prosthodontist), Maria Cândida Teixeira and Alessandra Mattos (restorative dentistry), for their contribution to the clinical cases presented in this study.

REFERENCES

1. Legan HL, Burstone CJ. Soft tissue cephalometric analysis for orthognatic surgery. *J Oral Surg.* 1980 Oct;38(10):744-51.
2. Levine RA, McGuire M. The diagnosis and treatment of the gummy smile. *Compend Contin Educ Dent.* 1997 Aug;18(8):757-62,64.
3. Marckley RJ. An evaluation of smiles before and after orthodontic treatment. *Angle Orthod.* 1993 Fall;63(3):183-9.
4. Arnett GW, Bergman RT. Facial keys to orthodontic diagnosis and treatment planning. Part I. *Am J Orthod Dentofacial Orthop.* 1993 Apr;103(4):299-312.
5. Fowler P. Orthodontics and orthognatic surgery in the combined treatment of an excessive gummy smile. *New Zealand Dent J.* 1999 Jun;95:53-4.
6. Zachrisson BU. Esthetic factors involved in anterior tooth display and smile: vertical dimension. *J Clin Orthod.* 1998;32(7):432-45.
7. Kokich VO Jr, Kiyak HA, Shapiro PA. Comparing the perception of dentists and lay people to altered dental esthetics. *J Esthet Dent.* 1999;11(6):311-24.
8. Cosendey VL. Avaliação do relacionamento entre o lábio superior e incisivos durante a fala e o sorriso [dissertação]. Rio de Janeiro (RJ): Universidade do Estado do Rio de Janeiro; 2008.
9. Vig RG, Brundo GC. Kinetics of anterior tooth display. *J Prosthet Dent.* 1978 May;39(5):502-4.
10. Desai S, Upadhyay M, Nanda R. Dynamic smile analysis: changes with age. *Am J Orthod Dentofacial Orthop.* 2009; Sep 3(136):310.e1-10.
11. Peck S, Peck L, Kataja M. The gingival smile line. *Angle Orthod.* 1992;2(62):91-100.
12. Cohen M. Interdisciplinary treatment planning: principles, design, implementation. 1st ed. Seattle: Quintessence; 2008.
13. Pascotto RC, Moreira M. Integração da Odontologia com a Medicina Estética: correção do sorriso gengival. *RGO.* 2005 jul-set;53(3):171-5.
14. Sarver DM, Ackerman MB. Dynamic smile visualization and quantification: Part 1. Evolution of the concept and dynamic records for smile capture. *Am J Orthod Dentofacial Orthop.* 2003;124(1):4-12.
15. Sarver DM. The importance of incisor positioning in the esthetic smile: The smile arc. *Am J Orthod Dentofacial Orthop.* 2001 Aug;2(120):98-111.
16. Frush JO, Fisher RD. The dysesthetic interpretation of the dentogenic concept. *J Prosthet Dent.* 1958;8:558.
17. Sarver DM. Principles of cosmetic dentistry in orthodontics: Part 1. Shape and proportionality of anterior teeth. *Am J Orthod Dentofacial Orthop.* 2004;Dec 6(126):749-53.
18. Levin EL. Dental esthetics and golden proportion. *J Prosthet Dent.* 1978 Sep;40(3):244-52.
19. Kokich VG, Nappen DL, Shapiro PA. Gingival contour and clinical crown length: their effect on the esthetic appearance of maxillary anterior teeth. *Am J Orthod.* 1984 Aug;86(2):89-94.
20. Borghetti A. Cirurgia plástica periodontal. 1^a ed. Porto Alegre: Artmed; 2002.
21. Garber DA, Salama MA. The aesthetic smile: diagnosis and treatment. *Periodontology 2000.* 1996 Jun;11(1):18-28.
22. Rubin LR. The anatomy of a smile: its importance in the treatment of facial paralysis. *Plast Reconstr Surg.* 1974 Apr;53(4):384-7.
23. Burstone CJ. Lip posture and its significance in treatment planning. *Am J Orthod.* 1967 Apr;53(4):262-84.
24. Simon Z, Rosenblatt A, Dorfman W. Eliminating a gummy smile with surgical lip repositioning. *J Cosmetic Dentistry.* 2007 Spring;1(23):100-8.
25. Pessoa TJJ, Freitas RS, Lida AC, Beck PT. Liberação do músculo depressor do septo nasal para tratamento do sorriso gengival. *Rev ImplantNews.* 2010;7(6):777-83.
26. Polo M. Botulinum toxin type A in the treatment of excessive gingival display. *Am J Orthod Dentofacial Orthop.* 2008 Feb;133(2):195-203.
27. Rubinstein A, Kostianovsky A. Cosmetic surgery for the malformation of the laugh: original technique. *Prensa Med Argent.* 1973;60:952-4.
28. Rubin LR, Mishriki Y, Lee G. Anatomy of the nasolabial fold: the keystone of the smiling mechanism. *Plast Reconstr Surg.* 1989 Jan;83(1):1-10.
29. Jacobs JD. Vertical lip changes from maxillary incisor retraction. *Am J Orthod.* 1978 Oct;74(4):396-404.
30. Bilodeau JE, Lane JA. Dilemmas in treating a patient with severe bialveolar protrusion and a hyperdynamic lip. *Am J Orthod Dentofacial Orthop.* 2007 Oct;132(4):540-9.

Submitted: December 2010
Revised and accepted: March 2011

Contact address

Máya Reis Seixas
Rua Leonor Calmon Bittencourt, n° 44, sala 1301 – Cidade Jardim
CEP: 40.296.210 - Salvador / BA, Brazil
E-mail: mayraorto@yahoo.com.br